

Case study

Neovascular Glaucoma Secondary to Bloch-Sulzberger Syndrome Documented by Retinography and Wide Field Angiography

ABSTRACT

Aims: To describe a Neovascular Glaucoma Secondary to Bloch-Sulzberger Syndrome

Presentation of Case: A.B.F. female, 23 years old, claimed significant pain sensation and hyperemia in the left eye (LE) for 45 days, without triggering factors. She came to the consultation with a previous diagnosis of Bloch-Sulzberger Syndrome with pigmented lesions in the lower limbs since childhood, being followed up by dermatology since then.

Discussion: The diagnosis of IP (incontinentia pigmenti) is complex because it mimics other dermatoses. The impairment in other systems, such as the ophthalmic system, with the possibility of loss of vision and functional disability is a reality. The natural history of retinal lesions is not fully understood. Vascular changes seem to start in the first weeks of life and progress after birth for weeks or months, and may stabilize at any stage, leaving numerous sequelae.

Conclusions: Incontinentia pigmenti is difficult to diagnose and, at each evolutionary stage, presents many differential diagnoses. Eye injuries can lead to blindness as a consequence of ischemic events that can start soon after birth.

Keywords: Genodermatosis; Pigment Incontinence; X Chromosome; Ocular Manifestations.

1. INTRODUCTION

PI (Block-Sulzberger Syndrome) is a rare X-linked genodermatosis. It has an autosomal dominant character, caused by a mutation in the NEMO gene (essential modulator of nuclear factor $\kappa\beta$) located on chromosome Xq28. Distal Xq duplications refer to chromosomal disorders resulting from involvement of the long arm of the X chromosome (Xq). Clinical manifestations vary widely depending on the sex of the patient and the gene content of the duplicated segment. Other denominations: incontinentia pigmenti, (IP) melanoblastosis cutis linearis and pigmented dermatosis, Siemens-Bloch type. 1,2,3

The incidence is being more common in Caucasians, and is 1 case per 40,000 individuals. Affected male fetuses, and generally do not survive, with the majority (97%) of affected living individuals being female. It has high penetrance, with most people expressing the phenotype months after birth. Family history appears to be the only known risk factor for PI. 2,3,4

Patients with suspected PI have a family history of the disease. Parents describe characteristic skin lesions that begin months after birth^{1,3,5}

A complete dermatological, neurological, ophthalmological and dental examination should be performed.

Skin lesions go through four stages, starting at birth and persisting into adulthood, being characterized by vesicular and verrucous phases, presence of hyperpigmented lesions that later become hypopigmented due to cutaneous atrophy present in early adulthood.^{2,5,6} Lesions occur mainly on the lateral portion of the trunk and usually spare the face. They are practically pathognomonic, as they occur in almost 100% of cases.^{3,5,6,7}

Neurological findings are present in 30% of cases and are characterized by, spastic paralysis, convulsive disorders, motor and mental retardation. Seizures and developmental delays are the most common. Significant Central nervous system manifestations in neonates with PI denote a poor long-term prognosis. Imaging methods may show ischemia, edema and brain atrophy^{4,5,6,8}

Ophthalmologic involvement is seen in 35-40% of people with PI, and include, neovascularization, hemorrhages, avascular ischemic areas, absence of foveal pit, and exudative and tractional detachments, optic nerve atrophy^{2,3,6,9} Retinal detachment is the most commonly diagnosed ocular finding in IP and, when present, almost always occurs in childhood. Due to the vaso-occlusive nature of PI, a cherry-red foveal spot may be observed. Avascular peripheral retina with anomalous neovascularization at its edge is characteristic of PI.^{5,6,8,10}

Fluorescein angiography is important to investigate an increase in the foveal avascular zone, avascular areas and neovessels in any part of the retina. Other ocular manifestations include uveitis, cataract, conjunctival pigmentation, strabismus, optic atrophy and nystagmus, with Pthisis bulbi being the end result of PI in many cases^{5,6,8,10}

Dental alterations occur in almost 70% of cases, evidencing anodontia, small or abnormally shaped teeth^{4,9,11}

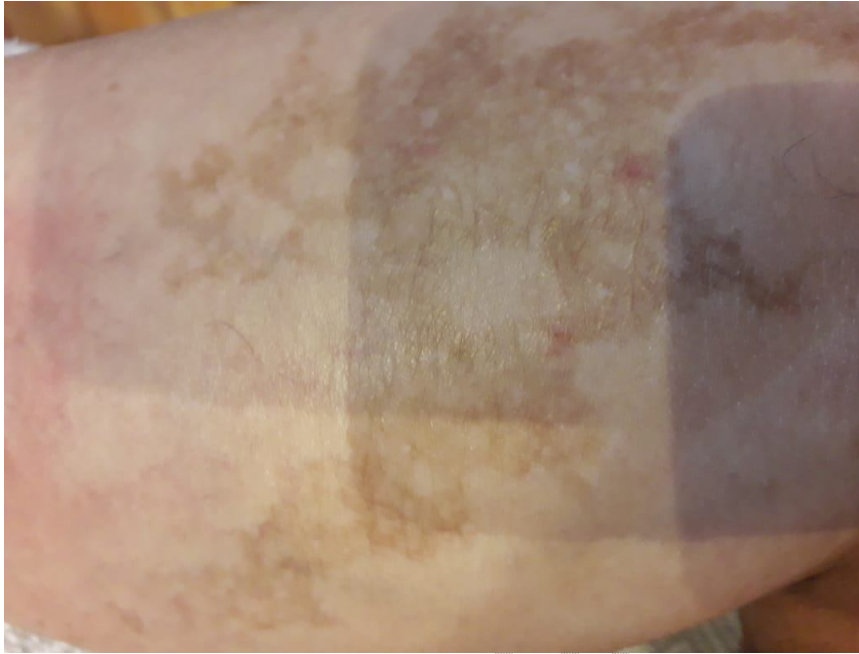Histopathological examination is useful in identifying eosinophilic infiltrations or extracellular melanin granules, which confirms the diagnosis when molecular genetic testing has not recognized a disease-causing mutation.^{1,8,12,}

As PI is genetically based, there is currently no cure and treatment is limited to supportive measures. The approach to the ophthalmologic condition, especially when there is retinal involvement, should be performed with laser photocoagulation or cryotherapy of avascular areas.^{5,6,8,11} Retinal detachments should be monitored with regular ophthalmologic exams and, if present, vitrectomy via pars plana often becomes mandatory.^{9,12,13}

If PI is identified, clinical examination of family members and genetic testing of the mother are necessary. Prenatal diagnosis of fetuses with a family history of IP is possible through DNA analysis obtained by chorionic villus sampling or amniocentesis.^{7,8,14}

2. Case Report

A.B.F. female, 23 years old, claimed significant pain sensation and hyperemia in the left eye (LE) for 45 days, without triggering factors. She came to the consultation with a previous diagnosis of IP with pigmented lesions in the lower limbs since childhood, being followed up by dermatology since then. (Figures 1 and 2)



. Figure 1. Pigmented lesions on the anterior surface of the left lower limb.

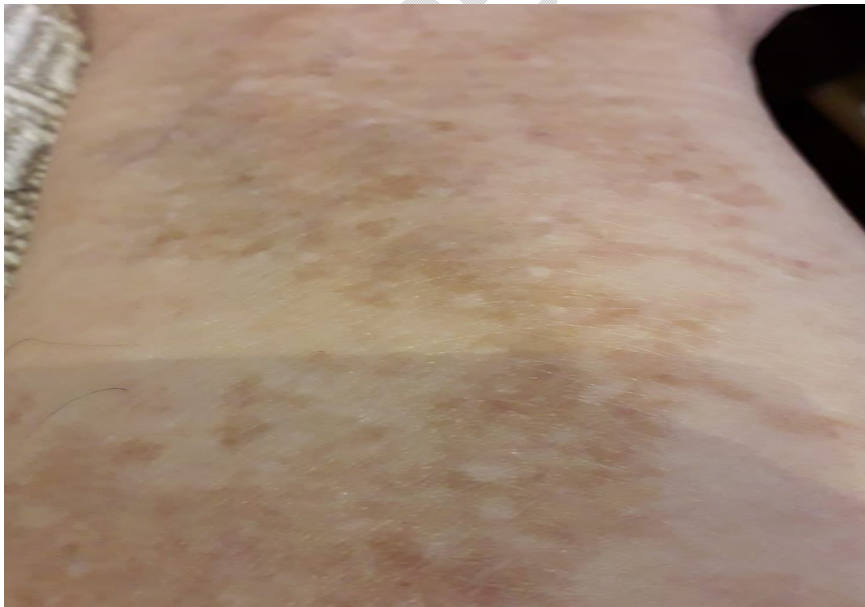

Figure 2. Pigmented lesions on the anterior surface of the left lower limb.

On ophthalmologic examination, visual acuity (VA) of 20/20 in the right eye (RE) and no light perception in the left eye (LE). Intraocular pressure: 15/32mmHg (16h).

Biomicroscopy showed no changes in the right eye (RE). On the other hand, the LE presented with 3+/4+ stromal corneal edema, 1 mm hyphema and 360° iris border and stroma neovessels.

Color and anerythral retinography of the RE showed discrete pigmentary and vascular alterations similar to telangiectasias in the inferior temporal periphery. (Figures 3 and 4) The LE examination showed significant exudative detachment, with nasal and temporal retinal folds.

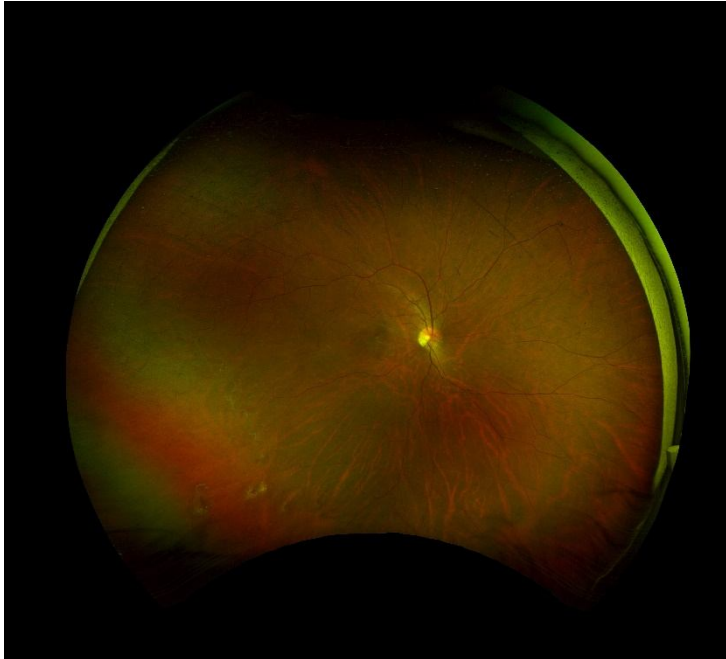


Figure 3 : Colored and anerythral wide-angle retinographies, showing pigmentary and telangiectatic changes in the inferior temporal periphery of the RE.

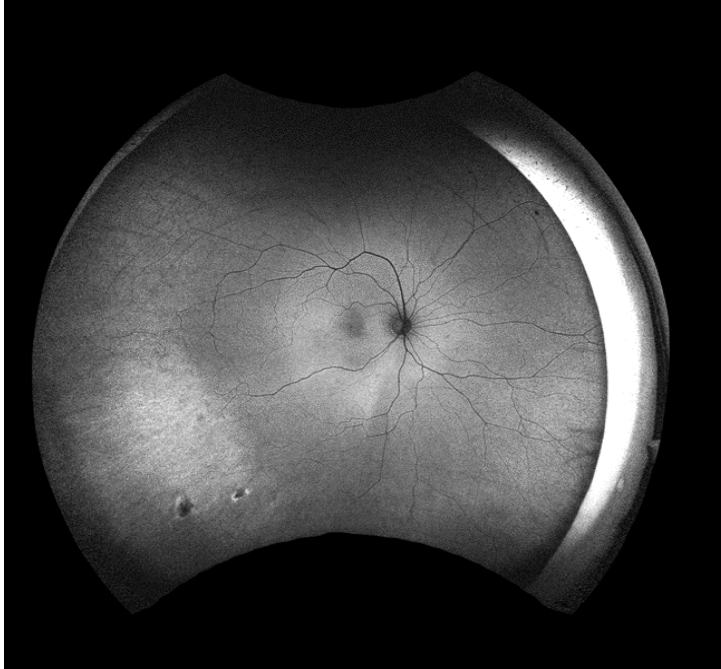


Figure 4 : Colored and anerythral wide-angle retinographies, showing pigmentary and telangiectatic changes in the inferior temporal periphery of the RE.

Wide-angle fluorescein angiography showed peripheral vascular changes with an area of capillary exclusion and retinal non-perfusion in the inferior and temporal region of the RE (Figures 5 and 6). EO was impractical due to media opacity.

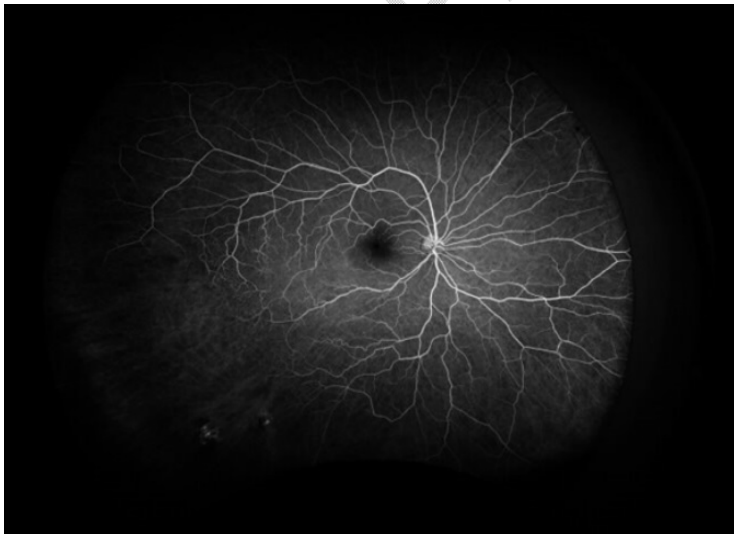


Figure 5: Wide-angle fluorescein angiography showing hyperfluorescence associated with telangiectatic regions and areas of hypoperfusion in the inferior temporal periphery of the RE.

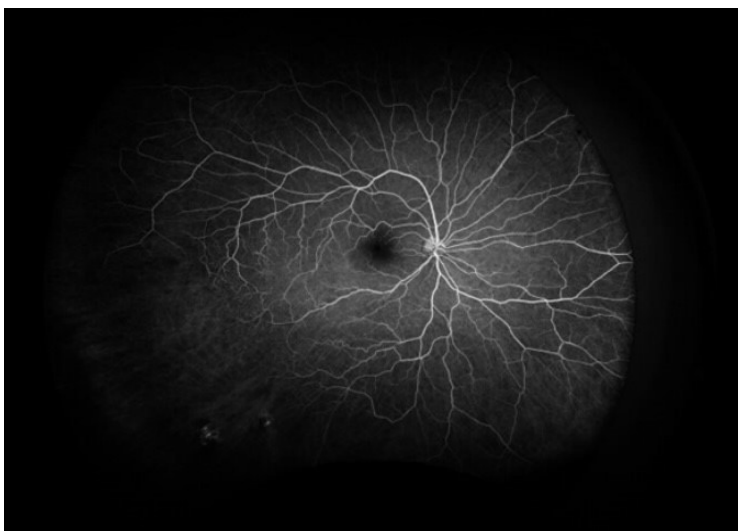


Figure 6: Wide-angle fluorescein angiography showing hyperfluorescence associated with telangiectatic regions and areas of hypoperfusion in the inferior temporal periphery of the RE.

Topical hypotensive eye drops, prednisolone and atropine were prescribed in EO, in addition to laser photocoagulation in the ischemic areas of EO. Laser photocoagulation was performed in the inferior temporal region of the RE, where the ischemic retinal areas were located. The patient remains under regular follow-up in the retina sector with her baseline condition stabilized without progression of the systemic disease of ocular involvement.

3. Discussion

The diagnosis of PI is complex because it mimics other dermatoses. The impairment in other systems, such as the ophthalmic system, with the possibility of loss of vision and functional disability is a reality.^{9,11,14} The natural history of retinal lesions is not fully understood. Vascular changes seem to start in the first weeks of life and progress after birth for weeks or months, and may stabilize at any stage, leaving numerous sequelae.^{3,7,13,14}

Fluorescein angiography allows the diagnosis and determination of the site of retinal ischemia, as performed on the patient. Angiographic signs may represent a typical change in the retinal pigment epithelium and dye diffusion at the level of neovascularization and pathological arteriovenous anastomoses.^{4,8,11,12}

Retinal ocular manifestations are related to vaso-occlusive phenomena with a compensatory vasoproliferative response that can be complicated by neovascular glaucoma (NVG) and exudative retinal detachment, outcomes that occurred in the patient's LE. The approach can be done with laser photocoagulation in the ischemic retinal areas and symptomatic medications for NGV, with such therapeutic measures being performed, but, however, the prognosis still remained reserved.^{4,11,15}

The cutaneous findings evolve in four classic phases characterized by the presence of vesicular, verrucous lesions, which later evolve into hyper/hypopigmented lesions resulting

from the cutaneous atrophy present in early adulthood^{5,8,12,14} The patient in the present report had only hyperpigmented lesions on the anterior surface of the left lower limb. The initial management of cutaneous and systemic changes in PI is done with medications to relieve symptoms and supportive measures, since the pathology is self-limited and there is no specific treatment. Skin lesions generally regress spontaneously.^{8,10,12,13}

4. Conclusion

PI is difficult to diagnose and, at each evolutionary stage, presents many differential diagnoses. Eye injuries can lead to blindness as a consequence of ischemic events that can start soon after birth.

Its recognition allows the child and the family an adequate orientation regarding the subsequent phases and possible systemic changes. Therefore, early recognition of this pathology, multidisciplinary follow-up and genetic counseling are necessary

COMPETING INTERESTS DISCLAIMER:

Authors have declared that they have no known competing financial interests OR non-financial interests OR personal relationships that could have appeared to influence the work reported in this paper.

Consent

All authors declare that 'written informed consent was obtained from the patient (or other approved parties) for publication of this case report and accompanying images. A copy of the written consent is available for review by the Editorial office/Chief Editor/Editorial Board members of this journal.

References

- 1- Chang JT, Chiu PC, Chen YY, Wang HP, Hsieh KS. Multiple clinical manifestations and diagnostic challenges of Incontinentia pigmenti--12 years' experience in 1 medical center. *J Chin Med Assoc.* 2008;71(9):455-60.
- 2- Clemons E, Clemons D, Lee JA, Berne S. Incontinentia pigmenti in three generations: A case report. *J Am Acad Dermatol.* 2008;58:AB80.
- 3- Lee Y, Kim S, Kim K, Chang M. Incontinentia pigmenti in a newborn with NEMO mutation. *J Korean Med Sci* 2011; 26: 308-11.
- 4- Pereira MA, Mesquita LA, Budel AR, Cabral CS, Feltrim Ade S. X-linked pigment incontinence or Block-Sulzberger syndrome: report of a case. *AnBras Dermatol* 2010; 85(3):372-5.

- 5- Minic S, Obradovic M, Kovacevic I, Trpinac D. Ocular anomalies in incontinentia pigmenti: Literature review and meta-analysis. *Srp Arh Celok Lek.* 2010 July-August; 138 (7-8): 408-13.
- 6- Nasser N, Nasser Filho N, Rosa TSC. Pigmentary incontinence: case report. *Arq Catarin Med.* 2012;41(4):83-6.
- 7- O'Doherty M, McCreery K, Green AJ, Tuwir I, Brosnahan D. Incontinentia pigmenti ophthalmological observation of a series of cases and review of the literature. *Br J Ophthalmol.* 2011;95(1):11-6
- 8-Castro-Rodríguez Yuri, Cósar-Quiroz Jose, Julcamoro-Grados Elizabhet. Oral manifestations of pigmentary incontinence (Bloch-Sulzberger syndrome). Case report. *Dentistry.* 2019; 21(34): 56-64.
- 9- Cernichiaro-Espinosa LA, Patel NA, Bauer MS, Negron CI, Fallas B, Pogrebniak A, Berrocal AM. Revascularization after intravitreal bevacizumab and laser therapy of bilateral retinal vascular occlusions in pigmentary incontinence (Bloch-Sulzberger syndrome). *Ophthalmic Surg Lasers Imaging Retina.* February 01, 2019; 50(2):e33-e37.
- 10- Mühlentstädt E, Eigelshoven S, Hoff NP, Reifenberger J, Homey B, Bruch-Gerharz D. Bloch-Sulzberger syndrome. *Hautarzt.* 2010; 61(10): 831-3
- 11- Gómez VR, Juárez M, Plascencia GA, Reyes MG, Saénz CC, Káram M et al. Incontinentia pigmenti. Review article. *Dermat Cosmet Méd Quir.* 2010; 8(2): 104-9
- 12- Romero A, Tufiño M, Villacís A, Salazar M. Pigmentary incontinence or Bloch-Sulzberger syndrome. *Dermatol Rev Mex.* 2014; 58 (6): 539-43
- 13- Tamari AN, Solorzano GS. Incontinentia pigmenti (Bloch-Sulzberger syndrome) in a male patient. Report of a case. *Rev Med Hered.* 2015; 26 (4): 238-41.
- 14- Pinheiro A, Mathew MC, Thomas M, Jacob M, Srivastava VM, Cherian R, et al. The clinical profile of children in India with blaschko-like pigment abnormalities and central nervous system manifestations. *Pediatr Dermatol.* January to February 2007; 24(1):11-7.
- 15- Rani, PK, Sen, P., Sahoo, NK et al. Results of neovascular glaucoma in eyes with moderate to good visual potential. *Int Ophthalmol* 41, 2359–2368 (2021).