

Case study

The Importance of Optical Coherence Tomography and Autofluorescence in the Documentation of Papillary Colobomatous Fosse.

ABSTRACT

Aims: TO DESCRIBE THE IMPORTANCE OF OPTICAL COHERENCE TOMOGRAPHY AND AUTOFLUORESCENCE IN THE DOCUMENTATION OF PAPILLARY COLOBOMATOUS FOSSETTE

Presentation of Case: F.D.O. A 14-year-old male student is referred for evaluation of the fundus of the eye due to an alteration in the optic disc noticed by another professional who did not feel safe in the follow-up. The patient was completely asymptomatic at the time of the consultation and did not claim previous visual complaints.

She denied systemic and ocular comorbidities and did not use any systemic and topical medication.

Discussion: THE CONGENITAL OPTIC DISC PIT IS A RARE AND TYPICALLY UNILATERAL CONGENITAL ANOMALY, CONSISTING OF A RETINAL HERNIATION THAT EXTENDS INTO THE SUBARACHNOID SPACE THROUGH A LAMINA CRIBROSA DEFECT. 8,13,15,16

Although this condition, in most cases, does not present complications and remains asymptomatic, it can sometimes worsen with a significant decrease in visual acuity. This more serious condition can be characterized by important macular alterations, such as serous retinal detachment, cystic degenerations and degenerative pigmentary alterations. 14,16,17,18 The patient in the present report did not have any visual complaints and did not present severe structural and functional retinal damage, which highlights the importance of early diagnosis.

Conclusions: The colobomatous papilla pit is characterized by the presence of isolated cavities in the optic disc head secondary to a developmental disorder of the primitive epithelial papilla.

Its incidence is 1:10,000 people without sexual or racial predilection. It presents, in most cases, asymptomatic, unilateral in 85-95% of cases and rarely with more than one pit per disc.

Keywords: optic disc pit, macular retinoschisis, optical coherence tomography, autofluorescence, pars plana vitrectomy.

1. INTRODUCTION

The congenital pit of the optic disc (Optic pit) consists of an anomalous excavation of congenital etiology in the head of the optic nerve. It is characterized by a more commonly grayish coloration, with average dimensions of 500 μm , oval and located predominantly in the inferotemporal region of the optic disc.^{1,2,3}

In most cases, the optic disc affected by the pit is larger than the contralateral. This pathology may be associated with other optic nerve alterations, such as papilla colobomas, which suggests that it is secondary to an incomplete closure of the fetal fissure or incomplete differentiation from the primitive epithelial papilla.¹⁻⁴

Clinically, it progresses asymptomatic until a central serous retinal detachment appears, a complication that occurs in approximately 25 to 75% of patients. The median age at diagnosis is around the third decade of life, but complicated clinical cases with retinal detachment at pediatric ages may also be present.^{2,4,5,6}

Retinal detachment, when present, occurs mainly in the temporal region, being contiguous with the optic disc. Optical coherence tomography (OCT) reveals a bilaminar, "schisis-like" structure between the inner and outer retinal layers and a central sensorineural detachment.^{2,4,5,6}

Any retinal layer can be affected, but the most affected is the external nuclear layer. The pathophysiological explanation for the appearance of macular detachment remains uncertain, and it may originate from the cerebrospinal fluid and liquefied vitreous. In addition, the presence of vitreous-retinal tractions can facilitate the entry of fluid into the subretinal space.^{3,5,7,8}

Most cases that do not present relevant symptoms can only be followed up with conservative treatment and periodic imaging tests to monitor the progression of the disease. 5,8,9,10 However, several therapeutic approaches are described for this entity, which, due to its low incidence, does not present an exact consensus on the best surgical technique to be used. Pars plana vitrectomy with subretinal fluid drainage, gas tamponade and endolaser has been the most used technique in the management of this pathology.¹⁰⁻¹⁴

2. CASE REPORT

F.D.O. A 14-year-old male student is referred for evaluation of the fundus of the eye due to an alteration in the optic disc noticed by another professional who did not feel safe in the follow-up. The patient was completely asymptomatic at the time of the consultation and did not claim previous visual complaints.

She denied systemic and ocular comorbidities and did not use any systemic and topical medication.

Visual Acuity: 20/20 in both eyes (AO).

Biomicroscopy: no relevant changes that could suggest any diagnostic clue.

Intraocular pressure: 11 mmHg AO (9h).

Fundoscopy:

Optic disc (OD) with excavated lesion on the inferior temporal border in the left eye.

Retinal periphery with areas of lattice degeneration, areas of white without temporal pressure in both eyes and presence of atrophic retinal holes at 10 h in the right eye.

Documented frame with color, anerythral, autofluorescence and optical coherence tomography (OCT) retinographies. (Figures 1 and 2)

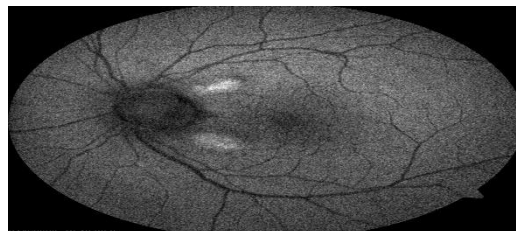


Figure 1. Autofluorescence showing two alterations corresponding to the areas of small schisis, one superior temporal and the other inferior.

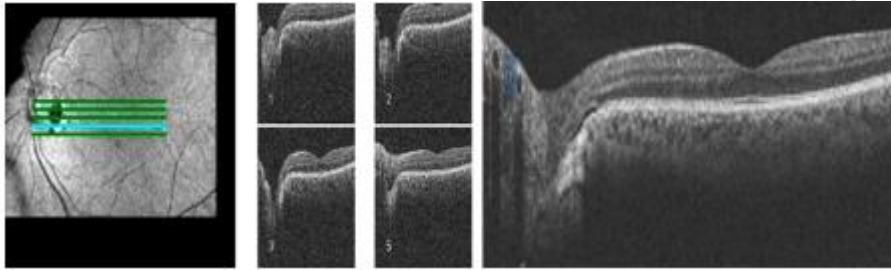


Figure 2. Optical coherence tomography showing a small temporal serous detachment in the inferior region of the optic disc.

The patient has been under regular clinical ophthalmological follow-up since diagnosis, and a conservative approach was chosen, since his vision was preserved and he did not need a surgical approach secondary to his clinical condition.

3. DISCUSSION

The Congenital optic disc pit is a rare and typically unilateral congenital anomaly, consisting of a retinal herniation that extends into the subarachnoid space through a lamina cribrosa defect.^{8,13,15,16}

Although this condition, in most cases, does not present complications and remains asymptomatic, it can sometimes worsen with a significant decrease in visual acuity. This more serious condition can be characterized by important macular alterations, such as serous retinal detachment, cystic degenerations and degenerative pigmentary alterations.^{14,16,17,18} The patient in the present report did not have any visual complaints and did not present severe structural and functional retinal damage, which highlights the importance of early diagnosis.

In the present report, we demonstrate the findings of autofluorescence and optical coherence tomography (OCT) that did not show significant macular involvement, but the presence of a small area of temporal serous detachment inferior to the optic disc.

Surgical management is usually performed at the time of diagnosis if there are retinal involvements that justify such an approach. Most of the cases that present with good visual acuity and without significant serous detachment, only a conservative approach with regular consultations with imaging exams proves to be sufficient.^{14,18,19,20}

However, if complications arise that threaten the patients' vision, surgical treatment with pars plana vitrectomy associated with drainage of subretinal fluid and gas tamponade seem to be effective measures to control these cases. The removal of the internal limiting membrane can be justified by the anteroposterior traction it exerts on the retina, which facilitates the transmission of fluid from the optic pit to the macular region.^{15,17,19,20} Surgical approach was

not necessary in the patient in the present report, see the early diagnosis, the mild retinal involvement and the absence of ocular symptoms, with follow-up being carried out with annual consultations and imaging exams.

4. CONCLUSION

The colobomatous papilla pit is characterized by the presence of isolated cavities in the optic disc head secondary to a developmental disorder of the primitive epithelial papilla.

Its incidence is 1:10,000 people without sexual or racial predilection. It presents, in most cases, asymptomatic, unilateral in 85-95% of cases and rarely with more than one pit per disc.

The colobomatous pit is asymptomatic most of the time, but if there is a secondary macular serous detachment, the prognosis becomes reserved for those who do not receive treatment and, when chronic, it can lead to a vision worse than 20/200 in 80% of cases.

Autofluorescence and OCT are valuable for the study of macular alterations related to pits, being essential in the treatment of these cases in order to avoid late diagnoses with more important and often irreversible ophthalmological repercussions.

CONSENT

All authors declare that 'written informed consent was obtained from the patient (or other approved parties) for publication of this case report and accompanying images. A copy of the written consent is available for review by the Editorial office/Chief Editor/Editorial Board members of this journal.

ETHICAL APPROVAL

Not applicable

REFERENCES

- 1- Georgalas I, Ladas I, Georgopoulos G, Petrou P. Optic disc pit: a review. *Graefes Arch Clin Exp Ophthalmol.* 2011; 249 (8): 1113-22.
- 2- Moisseiev E, Moisseiev J, Loewenstein A. Optic disc fossa maculopathy: when and how to treat? A review of pathogenesis and treatment options. *Int J Retin Vitreous.* 2015; 1: 13.
- 3- Mohammed OA, Pai A. Inverted autologous internal limiting membrane for treatment of optic disc fossa with macular detachment. *Middle East Afr J Ophthalmol.* 2013; 20 (4): 357-9.
- 4- Hirakata A, Inoue M, Hiraoka T, McCuen BW. Vitrectomy without laser treatment or gas tamponade for macular detachment associated with optic disc pit. *Ophthalmology.* 2012; 119 (4): 810-8.
- 5- Shukla D, Kalliath J, Tandon M, Vijayakumar B. Vitrectomy for optic disc pit with macular chisis and external retinal dehiscence. *Retina.* 2012; 32 (7): 1337-42
- 6- Spaide RF, Fujimoto JG, Waheed NK. Image artifacts in optical coherence tomography angiography. *Retina.* 2015; 35 (11): 2163-80.

- 7- Novelli FJ, Maia Júnior OO, Nobrega MJ, Garrido Neto T, Takahashi WY. Clinical and tomographic aspects of macular microholes. *Arch Bras Ophthalmol*. 2009;72(1):33-8.
- 8- Maia OO Jr, Soriano DS, Takahashi WY, Susuki H. Surgical treatment of macular detachment secondary to congenital pit of the optic disc: case report. *Arq Bras Oftalmol*. 2008;71(6):874-7.
- 9- Moreira Neto CA, Moreira Junior CA. Vitrectomy and gas-fluid exchange for the treatment of serous macular detachment due to optic disc pit: long-term evaluation [Vitrectomy and gas-fluid exchange for the treatment of serous macular detachment due to optic disc pit: long-term evaluation]. *Arch Bras Ophthalmol*. 2013 May-Jun;76(3):159-62.
- 10- Kováčová M, Meliška M, Kalvodová B. OCT Findings and Long-term Follow-up Results of Vitrectomy in Patients with Optic Disc Pit and Associated Maculopathy. *Cesk Slov Ophthalmol*. 2018 Spring;73(5-6):171-177.
- 11- Avci R, Yilmaz S, Inan UU, Kaderli B, Kurt M, Yalcinbayir O, et al. Long-term outcomes of pars plana vitrectomy without internal limiting membrane peeling for optic disc pit maculopathy. *Eye (Lond)*. 2013 Dec;27(12):1359-67.
- 12- Bottoni F, Cereda M, Secondi R, Bochicchio S, Staurenghi G. Vitrectomy for optic disc pit maculopathy: a long-term follow-up study. *Graefes Arch Clin Exp Ophthalmol*. 2018 Apr;256(4):675-682.
- 13- Ooto S, Mittra RA, Ridley ME, Spaide RF. Vitrectomy with inner retinal fenestration for optic disc pit maculopathy. *Ophthalmology*. 2014 Sep;121(9):1727-33.
- 14- Sanghi G, Padhi TR, Warkad VU, Vazirani J, Gupta V, Dogra MR, et al. Optical coherence tomography findings and retinal changes after vitrectomy for optic disc pit maculopathy. *Indian J Ophthalmol*. 2014 Mar;62(3):287-90.
- 15- Kumar A, Gogia V, Nagpal R, Roy S, Gupta S. Minimal gauge vitrectomy for optic disc pit maculopathy: Our results. *Indian J Ophthalmol*. 2015 Dec;63(12):924-6.
- 16- Mete A, Türkçüoğlu P, Kimyon S, Güngör K. The results of 25-gauge vitreoretinal surgery for optic disc pit-associated maculopathy: a report of three cases and mini-review of the literature. *Int Ophthalmol*. 2017 Aug;37(4):1057-1063.
- 17- Rayat JS, Rudnisky CJ, Waite C, Huang P, Sheidow TG, Kherani A, et al. Long-Term Outcomes For Optic Disk Pit Maculopathy After Vitrectomy. *Retina*. 2015 Oct;35(10):2011-7.
- 18- Soni A, Singh SR, Chhablani J. Fibrin glue for treatment of optic disc maculopathy. *Saudi J Ophthalmol*. 2021 Feb 27;34(3):227-229.
- 19- D'souza P, Verghese S, Ranjan R, Kumarswamy K, Saravanan VR, Manayath GJ, et al. Optic Disc Pit Maculopathy: One-Year Outcomes of Pars Plana Vitrectomy with Foveal Sparing Inverted Internal Limiting Membrane Flap. *Cureus*. 2021 Mar 23;13(3):e14057
- 20- Pastor-Idoate S, Gómez-Resca M, Karam S, Copete S, Kyriakou D, García-Arumí Fusté C, et al. Efficacy of Internal Limiting Membrane Flap Techniques with Vitrectomy for Macular Detachment Associated with an Optic Disc Pit. *Ophthalmologica*. 2019;242(1):38-48.