

Original Research Article

Effects of Letrozole on trabecular diameter of long bone: mouse model

ABSTRACT

Background: Letrozole, a commonly prescribed Neoadjuvant endocrine therapeutic drug in hormone receptor positive breast cancer females, causes osteoporosis along with several other debilitating effects. The objective of this study was to observe the changes in trabecular diameter of femur of mice after exposure to Letrozole.

Material and Methods: This Laboratory based experimental study was carried out at Pakistan Council of Scientific and Industrial Research Centre (PCSIR) Peshawar and Khyber Medical University (KMU) Peshawar from 1st of June 2018 till 30th of July 2018. Thirty-three female albino mice were divided into control and experimental groups. The experimental group was given Letrozole drug at a dose of 1mg/kg/day for 28 days. Weight of these thirty-three mice was measured before and after administration of the drug. The animals were then sacrificed. Femurs were dissected and processed to find out changes in its gross morphology, weight, and trabecular diameter.

Results: The overall weight of mice, weight of femur and its trabecular diameter was greater in control Group as compared to experimental Group.

Conclusion: Use of Letrozole can cause significant reduction in trabecular diameter of long bones.

Key words: Breast cancer, estrogen receptor, Letrozole, osteoporosis

INTRODUCTION

Breast cancer is one of the most common cancers all over the world. More than 250,000 breast cancers are diagnosed in the United States every year(Hanker et al., 2020). More than two million cases were reported in 2018, with more than six hundred thousand deaths(Khan et al., 2021). Among Asian countries, Pakistan has the highest prevalence rates of breast cancer: one in every nine women has a lifetime risk of being diagnosed with breast cancer(Saha Roy & Vadlamudi, 2012). Approximately 80% of the newly diagnosed cases of breast cancer are positive for Estrogen receptors (ER)(Hanker et al., 2020). Estradiol (active metabolite of Estrogen) plays a pivotal role in the initiation and progression of breast cancer. Estrogen hormone exerts its effects by binding to its receptors namely ER α and ER β (Jameera Begam et al., 2017). For early-stage breast cancer, treatment is given with curative intent, while for metastatic disease, the intention is to improve presentation of disease and quality of life. Different treatment modalities such as surgery, radiations, endocrine therapy, and chemotherapy are employed for patients with breast cancer(Anjum et al., 2017). The choice of therapy for individual patient depends upon the presentation of disease, its grade and stage, and metastases among others(Anjum et al., 2017). Clinical trials have shown that endocrine therapy has a positive impact on minimizing cancer recurrence risk, and thus decreasing mortality(Hanker et al., 2020). The endocrine

therapies are often suggested as first line management for the Estrogen receptor positive (ER+) or Progesterone receptor positive (PR+) cancers with only bone or soft tissue metastases, or with limited and asymptomatic visceral metastases(Anjum et al., 2017). Letrozole therapy in selected patients with ER+ and HER2-negative early breast cancer results in modest clinical and pathological response(Skriver et al., 2018). Estrogen is converted to estradiol and estrone in body by the action of an enzyme called Aromatase. This enzyme is synthesized by ovaries, liver, muscle, brain, and in normal breast tissue. It is also produced in some breast cancers(Jameera Begam et al., 2017). Letrozole is an oral reversible nonsteroidal Aromatase inhibitor. In postmenopausal women, Letrozole not only suppresses circulating estrogen levels by approximately >95%, but also inhibits production of autocrine and paracrine estrogen by peri-tumoral stromal cells located in both primary and metastatic sites of the tumor(Jameera Begam et al., 2017). Thus Letrozole, an FDA approved drug, is used as an effective anti-cancer agent for such patients(Charehbili et al., 2014). One of the major side effects of Aromatase Inhibitors, like Letrozole, is depletion of residual estrogen which results in several debilitating effects in body(Miyashita et al., 2020). The risk of osteoporosis is significantly increased in postmenopausal patients with hormone receptor positive breast cancer receiving aromatase inhibitors(Kalam et al., 2017). Letrozole use increases the risk of osteoporosis and fracture, (It affects the metabolic pathways involved in bone formation and remodeling resulting in osteoporosis. Letrozole and other aromatase inhibitors can decrease bone mineral density by more than 5% per year leading to doubling of lifetime risk of fracture(Miyashita et al., 2020). This study was designed to determine and quantify the effects of aromatase inhibitor, Letrozole, on trabecular diameter and weight of long bones in mice.

MATERIAL AND METHODS

A laboratory based experimental study design was implemented which included thirty-three female healthy albino mice, purchased from Directorate of Veterinary Research Institute, Peshawar. Female albino mice aged 04-06 weeks were included in the study. Exclusion criteria included diseased, inactive, and unhealthy mice. These mice were grouped as control(A) and experimental (B). The mice included in group A were labelled as A1-A6 while those included in group B were labelled as B1-B27. The mice in both groups were weighed before and after the experiment as shown in Figure 4. The experimental group was given Letrozole in dose of 1mg/kg/day for 28 days while the control group was given standard food and water as shown in Table 1. The animals in both group A and group B were observed for 28 days. Then the animals were sacrificed. Each mouse was positioned in a supine position and affixed by pinning all four legs through the mouse paw pads below the ankle joint followed by Spraying these with 70% ethanol, thoroughly dousing the legs(10). A small incision was made on the right side of midline in the lower abdomen just above the hip and then extended down the leg and past the ankle

Table 1. Grouping of Mice

Groups	Number of Mice	Dose (mg/kg body weight)
Group A (A1-A6)		

Control	6	Standard food and tap water
Group B (B1-B27) Experimental	27	Letrozole 1mg/kg/day

Joint, as shown in figure 1. The skin was pulled back and quadriceps muscles were cut to expose anterior femur and



Figure 1: Dissection of Mouse; incision given, skin was pulled and quadriceps muscles were cut to expose the anterior femur, in mice laying in a supine position

pinning it out at 45-degree angle from the board. The hamstrings were then cut with the blade posteriorly and were pulled back to expose posterior side of femur in the same manner and angle as anterior side of femur. Femoral shaft was then exposed by holding the femur in forceps and using scissors blade on both sides of shaft. The femur was than dislocated and released from acetabulum and knee joint. **All the connective tissue was carefully dissected.** The dissected right femur was fixed in 10% neutral buffered formalin (NBF) and transported to histopathology laboratory, Khyber medical university. Liquid Nitrogen was poured in each bottle for cryo-fracturing. After cryo-fracturing, these bones were decalcified by pouring few drops of 5% Nitric acid in each specimen container and kept for 3 days(11). After decalcification, right femur bone was washed for removal of traces of nitric acid and subjected to automatic tissue processor. After processing, paraffin embedded blocks were prepared and labelled accordingly as A1-A6 and B1-B27. Blocks were cut at 3-5 microns through Microtome (Cu cut SRM, Sakura). The cut tissue was taken very carefully and put in water bath (Sakura 1450) and then was put on glass slide. These slides were stained with Haematoxylin and Eosin (H & E) stain. Prepared slides were than examined under microscope (Olympus CX-31). Trabecular diameter was measured microscopically by using ocular graticule and stage micrometre. Data were entered and analysed using SPSS version 22. Mean and standard deviation were calculated for weight of mice, weight of femur and trabecular diameter. Independent sample t test was applied to compare the continuous variable among two groups. P value ≤ 0.05 was considered as statistically significant.

RESULTS

The mice in both groups were observed for general features like Health, activity, and response to external stimuli like sound and light. The group A mice were observed to be active, healthy, and responsive to external sounds and light, while group B mice were observed to be less active and their response to external stimuli was very weak or negative. Moreover, group B mice were anorexic and suffered from chronic diarrhea from start till end of experiment.

Before starting the experiment and after end of the experiment, mice from both groups A and B were weighed as described elsewhere in the text. A significant weight loss was seen in Group B treated with Letrozole as compared to Group A treated with standard food and water as shown in Figure 2.

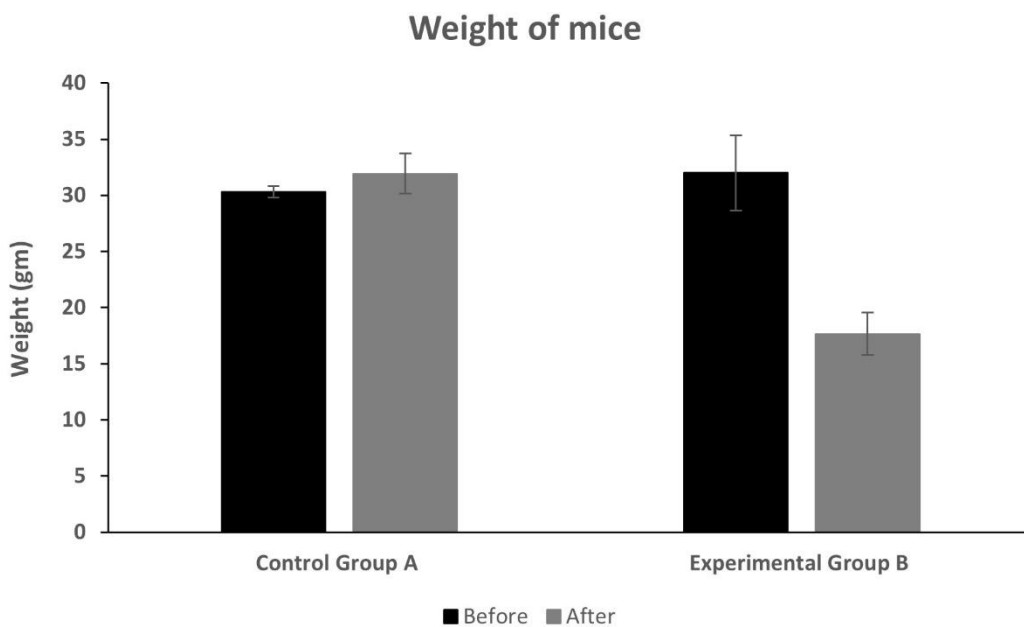


Figure 2: Mean Weight of mice: In Control Group A, before and after the experiment was 30.33 ± 0.51 and 32.10 ± 1.7 , and that of Experimental Group B was 31.92 ± 3.35 and 17.66 ± 1.88 respectively.

After dissection, femur bone from both groups (A, B) was weighed. The weight of the femur from experimental Group B is significantly less than that control group A as depicted in Figure 3. Moreover, the gross features of the dissected femurs were observed. Femurs from mice in group B were thin, had a rough dark brown surface, while those from group A were thick, glistening and had a smooth surface.

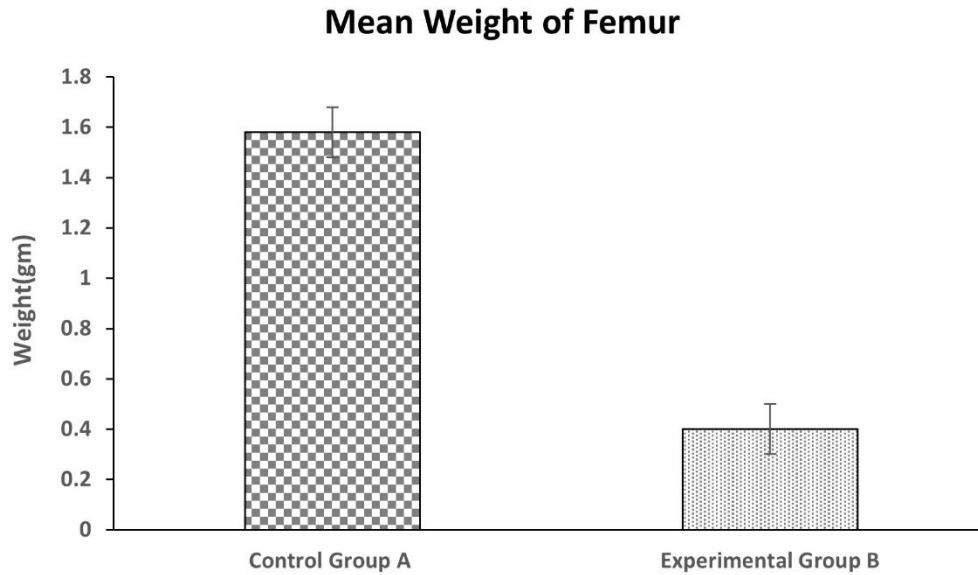


Figure 3: Comparison of mean weight of femur in grams of Group A (1.58 +/-0.1) and Group B (0.4+/-0.12) after the experiment.

The bony tissue from femur of mice in both the groups was examined microscopically. Trabeculi of femur of mice in group A were thick and showed well-formed lacunae along with prominent osteoblastic activity while trabeculi of femur, in group B mice, were thin and showed mostly osteoclastic activity as shown in Figure 4. Micrometric measurements were then performed to determine the trabecular diameter in both groups. A significant difference in mean trabecular diameters of Group A and Group B was found as shown in Figure 5.

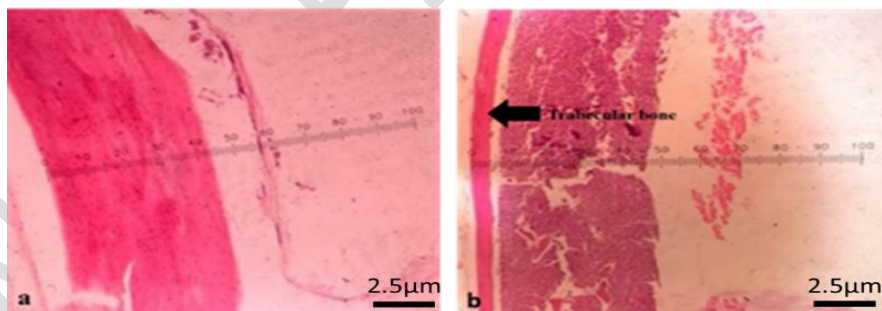


Figure 4: H&E stain showing measurement of trabecular diameter of femur bone at 74 10x. (a) Trabecular diameter of femur in Group A (Control), (b) Trabecular diameter of femur in Group B (Experimental)

DISCUSSION

Osteoporosis is a chronic, progressive bone metabolic disorder that is characterized by reduced bone mineral density (BMD), with deterioration of bone microarchitecture, leading to increased skeletal fragility and risk of fracture (Mazocco & Chagas, 2017). According to National Bone Health Alliance (NBHA) Working Group recommendations, postmenopausal women and men

over 50 years of age, should be diagnosed to have osteoporosis if Bone mineral density (BMD) on dual energy X-ray absorptiometry (DXA) is 2.5 or more standard deviations below the mean for young adults of the same sex and race (denoted as T-score ≤ -2.5) (Cipriani et al., 2018). The risk of osteoporosis and subsequent fracture is significantly increased in patients receiving long term Letrozole treatment (Kamdem et al., 2019). The primary aim of this study was to examine the effects of letrozole drug, an aromatase inhibitor, commonly prescribed by oncologists in Estrogen receptors positive breast cancer patients, on trabecular diameter of long bones. For this study the mice were grouped into control and letrozole (experimental) groups and were treated for 28 days with standard food and oral Letrozole (1mg/kg/day), respectively as outlined in methodology. The study results showed that administration of letrozole drug caused significant decrease in trabecular diameter of femur bone in mice, resulting in osteoporosis. Trabecular thinning in osteoporosis is also investigated by FL. Marcu et al (Marcu et al., 2011). They have emphasized upon aging, loss of horizontal trabecular lamellae, trabecular anisotropy, trabecular connectivity diminution and bone resorption as the key factors in osteoporosis (Marcu et al., 2011).

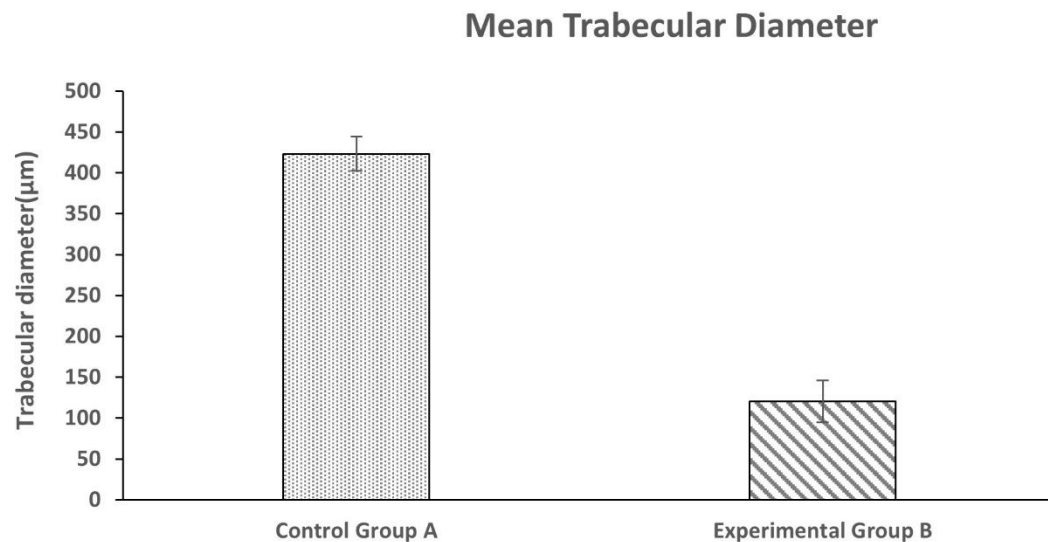


Figure 5: Mean trabecular diameter in both group A (Control) and group B (Letrozole), $P \leq 0.001$, Independent sample t test. The mean diameter of Control group A ($423.33 \mu\text{m} \pm 21.2$) is significantly higher than that of the group B ($120.37 \mu\text{m} \pm 25.81$) treated with Letrozole.

Anna Pulitun et al have argued that long-term administration of aromatase inhibitors like letrozole causes reduction in bone mass with altered collagenization, decreased cortical thickness and significantly reduced whole volume of humerus bone (Pulitun et al., 2020). This is in concordance with our work. Our findings are also in agreement with Kalam A et al and Collin A et al who have described the deleterious effects of letrozole treatment on different bones in mice (Kalam et al., 2017) (Collin et al., 2021). Similarly, Torres et al have also emphasized upon the role of letrozole in causing reduction in mass and thickness of bones in male rats (Torres et al., 2019). Our results showed a significant weight loss in experimental (Letrozole) group as

compared to control group. This finding contrasts with the results of a trial undertaken by various researchers, where weight gain was noted after treatment with letrozole (Skarra et al., 2017). Weight loss in mice, in current study, may be attributed to diarrhea and anorexia which started after letrozole treatment in experimental group and continued till the end of experiment.

Conclusion

The results of this study have led to the conclusion that use of Letrozole can cause significant reduction in the trabecular diameter of femur in mice.

Ethical Approval:

As per international standard or university standard written ethical approval has been collected and preserved by the author(s).

Recommendation

It is recommended that a natural source of therapy against estrogen, be sought which would not decrease the concentration of residual hormone to minimal levels, thereby not disturbing the metabolic effects of estrogen.

COMPETING INTERESTS DISCLAIMER:

Authors have declared that no competing interests exist. The products used for this research are commonly and predominantly use products in our area of research and country. There is absolutely no conflict of interest between the authors and producers of the products because we do not intend to use these products as an avenue for any litigation but for the advancement of knowledge. Also, the research was not funded by the producing company rather it was funded by personal efforts of the authors.

References

- Anjum, F., Razvi, N., & Masood, M. A. (2017). Breast Cancer Therapy: A Mini Review. *MOJ Drug Design Development & Therapy*, 1(2). <https://doi.org/10.15406/mojddt.2017.01.00006>
- Charehbili, A., Fontein, D. B. Y., Kroep, J. R., Liefers, G. J., Mieog, J. S. D., Nortier, J. W. R., & Van de Velde, C. J. H. (2014). Neoadjuvant hormonal therapy for endocrine sensitive breast cancer: A systematic review. *Cancer Treatment Reviews*, 40(1), 86–92. <https://doi.org/10.1016/j.ctrv.2013.06.001>
- Cipriani, C., Pepe, J., Bertoldo, F., Bianchi, G., Cantatore, F. P., Corrado, A., Di Stefano, M., Frediani, B., Gatti, D., Giustina, A., Porcelli, T., Isaia, G., Rossini, M., Nieddu, L., Minisola, S., Girasole, G., & Pedrazzoni, M. (2018). The epidemiology of osteoporosis in Italian postmenopausal women according to the National Bone Health Alliance (NBHA) diagnostic criteria: a multicenter cohort study. *Journal of Endocrinological Investigation*, 41(4), 431–438. <https://doi.org/10.1007/s40618-017-0761-4>
- Collin, A., Vein, J., Wittrant, Y., Pereira, B., Amode, R., Guillet, C., Richard, D., Eschalier, A., & Balayssac, D. (2021). A new clinically-relevant rat model of letrozole-induced chronic nociceptive disorders. *Toxicology and Applied Pharmacology*, 425, 115600. <https://doi.org/10.1016/J.TAAP.2021.115600>

- Hanker, A. B., Sudhan, D. R., & Arteaga, C. L. (2020). Overcoming Endocrine Resistance in Breast Cancer. *Cancer Cell*, 37(4), 496–513. <https://doi.org/10.1016/j.ccell.2020.03.009>
- Jameera Begam, A., Jubie, S., & Nanjan, M. J. (2017). Estrogen receptor agonists/antagonists in breast cancer therapy: A critical review. *Bioorganic Chemistry*, 71(February 2017), 257–274. <https://doi.org/10.1016/j.bioorg.2017.02.011>
- Kalam, A., Talegaonkar, S., & Vohora, D. (2017). Effects of raloxifene against letrozole-induced bone loss in chemically-induced model of menopause in mice. *Molecular and Cellular Endocrinology*, 440, 34–43. <https://doi.org/10.1016/J.MCE.2016.11.005>
- Kamdem, L. K., Xi, J., Clark, B. L., Gregory, B. J., Kidwell, K. M., Storniolo, A. M., Stearns, V., Hayes, D. F., Gersch, C. L., Rae, J. M., Henry, N. L., & Hertz, D. L. (2019). Exemestane may be less detrimental than letrozole to bone health in women homozygous for the UGT2B17*2 gene deletion. *Breast Cancer Research and Treatment*, 175(2), 297–303. <https://doi.org/10.1007/s10549-019-05158-3>
- Khan, N. H., Duan, S.-F., Wu, D.-D., & Ji, X.-Y. (2021). Better Reporting and Awareness Campaigns Needed for Breast Cancer in Pakistani Women. *Cancer Management and Research*, Volume 13, 2125–2129. <https://doi.org/10.2147/CMAR.S270671>
- Marcu, F., Bogdan, F., Muțiu, G., & Lazăr, L. (2011). The histopathological study of osteoporosis. *Romanian Journal of Morphology and Embryology*, 52(SUPPL. 1), 321–325.
- Mazocco, L., & Chagas, P. (2017). Association between body mass index and osteoporosis in women from northwestern Rio Grande do Sul. *Revista Brasileira de Reumatologia (English Edition)*, 57(4), 299–305. <https://doi.org/10.1016/j.rbre.2016.10.002>
- Miyashita, H., Satoi, S., Kuno, T., Cruz, C., Malamud, S., & Kim, S.-M. (2020). Bone modifying agents for bone loss in patients with aromatase inhibitor as adjuvant treatment for breast cancer; insights from a network meta-analysis. *Breast Cancer Research and Treatment*, 181, 279–289. <https://doi.org/10.1007/s10549-020-05640-3>
- Pilutin, A., Misiakiewicz-Has, K., Kolasa-Wołosiuk, A., Trybek, G., Urban, F., Marchlewicz, M., Leszczyński, B., Wróbel, A., & Wiszniewska, B. (2020). Morphology and serum and bone tissue calcium and magnesium concentrations in the bones of male rats chronically treated with letrozole, a nonsteroidal cytochrome P450 aromatase inhibitor. *Connective Tissue Research*, 1–10. <https://doi.org/10.1080/03008207.2020.1771329>
- Saha Roy, S., & Vadlamudi, R. K. (2012). Role of Estrogen Receptor Signaling in Breast Cancer Metastasis. *International Journal of Breast Cancer*, 2012, 1–8. <https://doi.org/10.1155/2012/654698>
- Skarra, D. V., Hernández-Carretero, A., Rivera, A. J., Anvar, A. R., & Thackray, V. G. (2017). Hyperandrogenemia induced by letrozole treatment of pubertal female mice results in hyperinsulinemia prior to weight gain and insulin resistance. *Endocrinology*, 158(9), 2988–3003. <https://doi.org/10.1210/en.2016-1898>
- Skriver, S. K., Laenkholm, A. V., Rasmussen, B. B., Handler, J., Grundtmann, B., Tvedskov, T. F.,

Christiansen, P., Knoop, A. S., Jensen, M. B., & Ejlersen, B. (2018). Neoadjuvant letrozole for postmenopausal estrogen receptor-positive, HER2-negative breast cancer patients, a study from the Danish Breast Cancer Cooperative Group (DBCG). *Acta Oncologica*, 57(1), 31–37. <https://doi.org/10.1080/0284186X.2017.1401228>

Torres, P. J., Skarra, D. V., Ho, B. S., Sau, L., Anvar, A. R., Kelley, S. T., & Thackray, V. G. (2019). Letrozole treatment of adult female mice results in a similar reproductive phenotype but distinct changes in metabolism and the gut microbiome compared to pubertal mice. *BMC Microbiology*, 19(1). <https://doi.org/10.1186/s12866-019-1425-7>

UNDER PEER REVIEW