

HISTOLOGICAL CHANGES IN TESTIS OF ADULT WISTAR ALBINO RATS - NICOTINE-INDUCED TESTICULAR DAMAGES AND THE PROTECTIVE EFFECTS OF METHANOLIC EXTRACT OF SPHAERANTHUS AMARANTHOIDES

ABSTRACT

Nicotine which is the most dynamic substance present in tobacco is the vital cause of damaging the tissues and oxidative stress that in turn is the principal cause of numerous diseases. The succession and severity of nicotine toxicity which may be adjourned by the natural antioxidants may cause serious health, knock. We have scrutinized the consequences of methanolic extract of *Sphaeranthus amaranthoides* (SAE) on nicotine-induced reproductive toxicity, oxidative damage, and hepatotoxicity in adult Wistar male albino rats. In four groups 24 rats were contingently split up. Control, Nicotine N (0.4 mg/kg. i.p) methanolic extract of *Sphaeranthus amaranthoides* (SAE) and (N+ SAE) group. In order to compute the levels of testosterone and to measure the hematological and oxidative stress parameters, blood samples were collected after 48 days wherein the reproductive organs were weighed for semen analysis and histopathology. We could see downswings in the levels of testosterone, weights of reproductive organs, and even in the characteristic features of sperms due to reproductive toxicity of Nicotine. On histological examination, testis showed atrophy, degenerative alterations of spermatogenesis in numerous seminiferous tubules together with increased interstitial spaces and a decrease in the number of Leydig cells. SAE played a defensive role against nicotine which persuaded the reproductive effects by enhancing the spermatogenesis, semen quality, and testicular histological damage.

Keywords: Nicotine, Rats, Reproductive toxicity, Tobacco, Male infertility and spermatogenesis, *Sphaeranthus amaranthoides*, antioxidants

1. INTRODUCTION

Every year, more than 8 million people die from tobacco use. Over 80% of the world's 1.3 billion tobacco users live in low- and middle-income countries (WHO2020). While smoking prevalence has

declined in many developed countries, it remains high in others and is increasing among women and in developing countries (1). Smoking cigarettes and chewing tobacco create a great impact on humanity by causing various diseases. Nicotine which is available in large amounts is taken after drying the stems and leaves of *Nicotiana tobaccum* and *Nicotiana rustica* are subjected to evaporate at normal temperature. Among the 4000 chemicals in tobacco products, Nicotine is the most prominent one (2). Nicotine is the most poisonous ingredient of cigarette smoking causing male and female reproductive systems. The toxic component of cigarette smoking, with damage to DNA genotoxin, immunotoxin and also causes adverse effects on the functioning of local and systemic immune systems and affects both as well as reproductive effects in both sexes. Pulmonary absorption of Nicotine is extremely rapid, occurring at a rate similar to that after intravenous administration (3). Since it can deplete into the skin with more ease and into the moist inner lining of the lungs and the respiratory tract and it reaches its highest level in the brain and bloodstream very fastly.

Since it is the principle compound of the nervous system it attaches easily to the chromaffin cells of the adrenal medulla, nicotinic cholinergic receptors in autonomic ganglia, the neuromuscular junctions, and the brain (4). By lessening the intratesticular concentrations of testosterone Nicotine destroys the germ cells which is most important for maintaining the structure and normal functions of seminiferous tubules. (5) From an appreciable number of human studies it is revealed that smoking cigarette has detrimental mutagens and carcinogens which in turn results in flawed sperm quality, DNA damage of spermatozoa and lessens the chances of pregnancy. From an appreciable number of human studies, it is revealed that smoking cigarettes has detrimental mutagens and carcinogens which in turn results in flawed sperm quality, DNA damage of spermatozoa and lessens the chances of pregnancy (5).

Sphaeranthus amaranthoides is rich in flavonoids, phenolics, alkaloids, steroids, saponins, and tannins. This plant is predominantly known for its medicinal value, especially in the treatment of filarial fever, blood disorder, and eczema. It is also familiar in healing all major types of skin diseases too (8)

Due to its promising health benefits in treating cancer, action on inflammation, action against microbes and anti-oxidant property *sphaeranthus amaranthoides* has an excellent deal of attraction. It is not clear about its property of reducing the adverse effects of toxicants as of now.

Free oxygen radicals were generally produced from Nicotine and *sphaeranthus amaranthoides* forages free oxygen radicals and gob peroxy, hydroxyl and superoxide anion radicals since it contains flavonoids. In adult Wistar albino male rats we conducted a study to find out the defensive role of methanolic extract of *sphaeranthus amaranthoides* against the reproductive toxicity which was induced by nicotine.

2. MATERIALS AND METHODS

2.1. Methanolic excerpt of *sphaeranthus amaranthoides* and Nicotine

(-)- 1-Methyl-2-(3-pyridyl) pyrrolidine, (s)-3-(1-Methyl-2-pyrrolidinyl) pyridine ($C_{10}H_{14}N_2$, Purity $\geq 99\%$) nicotine was purchased from Sigma-Aldrich. The dose and the administration route were selected according to previous studies [9] The plant *S. amaranthoides* was collected from the Salem Dist., Tamil Nadu, India. The primary works like washing, drying. etc were done. The plant materials were identified and authenticated by DR.P. Murugan M.Sc., Ph.D., Department of Medicinal Botany, Sri Sairam Siddha Medical College & Research center. The collected plant material was free from disease and also free contamination of other plants.

2.2. Preparation of plant extract

100 g of *S. amaranthoides* air-dried and coarsely powdered plant material was extracted with 500 ml methanolic solvent by using a Soxhlet extractor. After extraction, the sample was kept in dark for 72 h with intermittent shaking. Then the solvent was evaporated under reduced pressure using Rota-vapor to obtain viscous semi-solid masses.

2.3. Experimental design

24 adult male Wistar albino rats weighed between 150-240 g were obtained and acclimatized for 1 week before the experiment. The animals were housed in cages and maintained in an air-

conditioned animal house at a controlled room temperature ($22\pm 2^{\circ}\text{C}$) and relative humidity ($60\pm 10\%$) with a photoperiod of 12h light/ 12h dark with free access to pellet feed and fresh tap water.

Category I – Control (C)

Category II – Received nicotine 0.4mg /kg b.w intraperitoneally (i.p) for 48 days

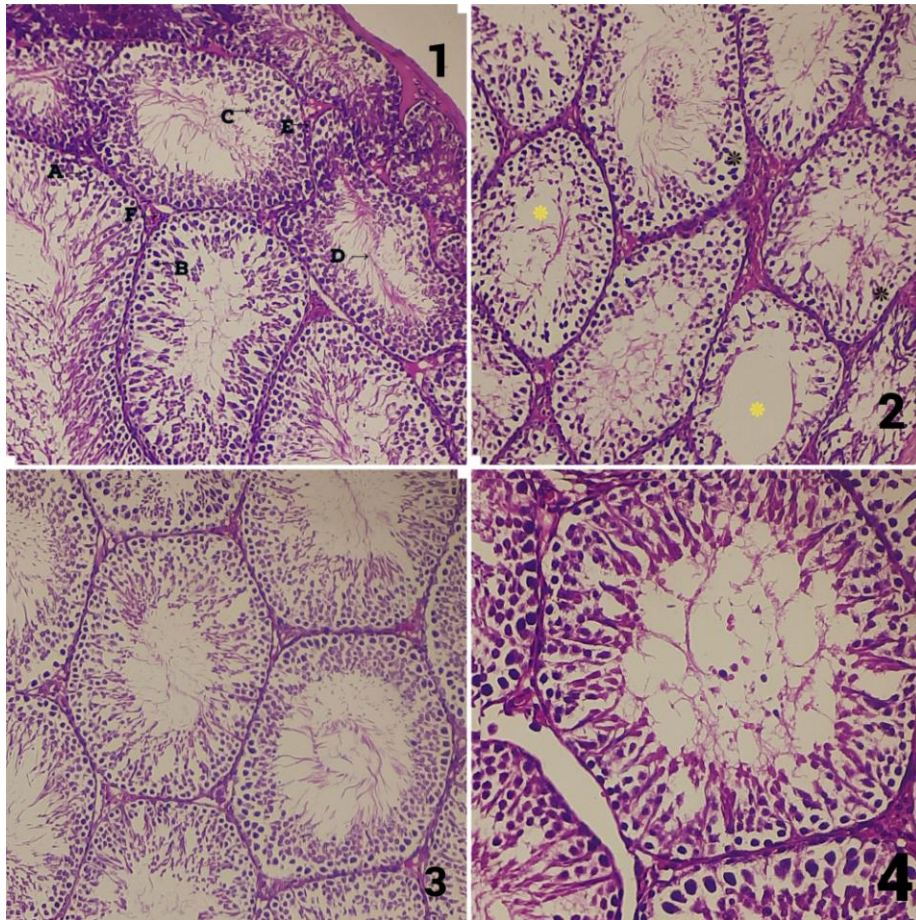
Category III – Received nicotine 0.4mg /kg b.w and 250 mg of methanolic extract of *Sphaeranthus amaranthoides* Ad libitum (low dose) for 48 days

Category IV - Received nicotine 0.4mg /kg b.w and 500 mg of methanolic extract of *Sphaeranthus amaranthoides* Ad libitum (high dose) for 48 days

3. RESULTS

Testes were collected and immersed in bouin's fluid. After fixation for 48 hrs, tissues were dehydrated through a graded series of ethanol, cleared in xylene, and embedded in paraffin. Sections of 5 μm thickness were obtained by using a rotatory microtome. The sections were mounted, stained with hematoxylin-eosin (HE) and observed under light microscopy.

On examining the testis of control (Fig 1. A) displayed a usual tissue structure and configuration of the spermatogenic cycle, whereas nicotine treated rats (Fig. 1.B) displayed obvious signs of testicular injury like deterioration and degeneration of seminiferous epithelium, Sertoli cells are lost in seminiferous tubules and also broadening of interstitial spaces with the reduction in Leydig cells. No considerable changes were present in the Nicotine and methanolic extract of *Sphaeranthus amaranthoides* in both doses group (Fig. .1C – Low dose & 1D High dose).



A - Spermatogonium; B- Sertoli cell; C- Spermatid; D- Sperms; E- Leydig cells; F- Blood vessels;

*Deterioration of the germinal epithelium * Absence of spermatozoa in the lumen

Fig. 1 Showing the cross-section of testes in H&E., 10X.

1. Control group revealing normal structure and arrangement of seminiferous tubules with progression cells and the interstitium have a normal distribution of Leydig cells.
2. Nicotine group revealing deterioration of the germinal epithelium with the absence of spermatozoa in the lumen, presence of cell debris, and loss of the Sertoli cells in some seminiferous tubules, with a reduction in the number of the Leydig cells
3. Animals treated with nicotine and a low dose of methanolic extract of *sphaeranthus amaranthoides*, revealing limited seminiferous tubules and deteriorated tubules with change in the shape of Sertoli cells.

4. Animals treated with nicotine and a low dose of methanolic extract of *Sphaeranthus amaranthoides*, showing seminiferous tubules with numerous spermatozoa in the lumen and the reserved Leydig cells

4. DISCUSSION

On the whole, with the findings of this study, we could clearly derive that, Methanolic extract of *Sphaeranthus amaranthoides* could prevent or reverse the deteriorating changes produced by nicotine on the male reproductive parameters. Chronic induction of Methanolic extract of *Sphaeranthus amaranthoides* prevented and even repaired the changes caused by Nicotine, like reduction in the number of Sertoli cells and Leydig cells. In animal groups treated with nicotine alone, significant deformity of seminiferous tubules along with signs of necrosis was evident. In addition, the Leydig cells and Sertoli cells were also affected. (Fig.1 B) When given in low dose, Methanolic extract of *Sphaeranthus amaranthoides* along with nicotine resulted in an increased number of early spermatids as evidence of sperm rejuvenation. (Fig. 1 C) When given in high dose Methanolic extract of *Sphaeranthus amaranthoides* along with nicotine one could appreciate prominent histology of Sertoli cell development on the basement membrane properly with oval dome-shaped nucleus along. (Fig.1 D).

The micrographs of the testis section have signs of sperms at different proliferative phases with hypertrophic swollen seminiferous tubules. Moreover, many animals exhibited severe edema in interstitial connective tissue with reduced Leydig cells allocation. A few animals possessed diminished tubular diameters observed in the study of Maryam Mosadegh et al., 2017(11). Nicotine administration affects the production of spermatozoa which results in reduction of spermatogenic sequence and a fall in sperm count in several seminiferous tubules. Reduction in the number of spermatocytes and Sertoli cells is accompanied by thickening of Tunica propria as observed by W Y Wong et al (12). From the same study, it is revealed that nicotine is a central nervous system depressor that can inhibit the neural stimulus essential for the release of pituitary gonadotropins. The structural changes observed in the seminiferous tubules of the current study could be explained by the work done by Ahmadnia et al. (13) who attributed these changes to the vascular insufficiency resulting from nicotine toxicity.

Numerous experimental and epidemiological studies show effects same to those observed in various studies (Azza M Gawish et al 2010, Rachid Mosbah et al 2015) (14, 15). It is observed that

low sperm counts are the cause of more than 90% of male infertility (15). Steroidogenesis in Leydig cells is mainly regulated by the Luteinizing hormone which binds with specific membrane receptors and activates the adenylate cyclase system (16). Cotinine is a major degradation product of nicotine. Because of its specificity and detectable concentrations in a range of human body fluids, such as serum, urine, saliva, follicular fluid, and seminal plasma, it is regarded as a valid biomarker of tobacco smoking. (17). From the same study, it is revealed that nicotine could effectively depress the central nervous systems which in turn inhibit the neural stimulus essential for the release of pituitary gonadotropins.

According to Ahmadnia et al Reduction in the number of Sperm cells, Leydig cells, and Deteriorated Sertoli cells could be due to hypoxemia induced by the nicotine present in the smoke of cigarettes. [13]. This Hypoxemia in turn results in vascular insufficiency to the testicular tissue. It is commonly observed, the reduction or absence of Leydig and Sertoli cells in the testis of Nicotine treated rats was because of defective androgen synthesis. Nicotine also causes hemorrhage and thus seminiferous tubules to become irregular in shape. (18) Testicular biopsy score could provide a clear picture of spermatogenesis. (19) Nicotine can cross the blood-testis barrier. Significant decreases in semen quality reported with reduced sperm viability and altered morphology are because of notable levels in seminal plasma of humans (20). The increased testicular lipid peroxidation, hydrogen peroxide, and hydroxyl radical generations, as well as decreased glutathione level, reduced antioxidant enzymes activities, and mitochondrial membrane potential of the testis, were reported nicotine-treated rats (21). The toxic changes produced by nicotine are reversible always as in a study it is proved that decreasing the number of cigarettes per day improves the seminal profile (22). From previous studies, it was evidenced that nicotine produces oxidative stress and causes damage to the male reproductive system. Antioxidants can search these reactive oxygen species formed within the male reproductive organs, leading to the proper functioning of the system (23).

In the present study, the combined treatment of nicotine and methanolic extract of *Sphaeranthus amaranthoides* reversed the histological changes in testicular tissue induced by nicotine. When extract of the low dose is administered active sperm proliferation is seen with mild signs of edema along with congestion of interstitium. In a high dose of the extract normal appearance of

spermatogenic layers and sperm in the seminiferous tubules could be appreciated. It reduces apoptosis and vacuolization. The interstitial spaces and Leydig cells appeared in normal shape. The micrograph is more or less as similar as the control animals. The presence of mature somatic cells project the perfect histomorphological of testicular cells. Primary spermatocytes with large nuclei and dense chromatin were also observed. The ameliorating effect of methanolic extract of *Sphaeranthus amaranthoides* in the present study may be attributed to its antioxidant properties. In the future the presence of (ZnO) Zinc oxide nanoparticles and method of extraction of such nanoparticles from *Sphaeranthus amaranthoides* could be evaluated, as these nanoparticles induce steroidogenesis well (24).

5. CONCLUSION

Methanolic extract of *Sphaeranthus amaranthoides* may condense nicotine-induced histopathological changes. It may also have a shielded effect against nicotine haematotoxicity in animals exposed to experiments. On taking the decoctions of *Sphaeranthus* may be observed to enhance numerous unfavorable effects on health in cases that have been manifested to nicotine through passive or active smoking or other ways of exposure such as intake. Methanolic extract of *Sphaeranthus amaranthoides* may reverse all the deformities seen in seminiferous tubules and Leydig cells.

Ethical Approval

The study was conducted after having approval from the Institutional Ethical and Scientific committee, Sathyabama Institute of Science and Technology, Tamilnadu, India. Animals used in this study were not subjected to any unnecessary painful and frightening situations [15]. All the procedures were carried out by a well-trained person. The animals were protected from pathogens and placed in an appropriate environment.

6. REFERENCES

1. WHO. Warning, the tobacco industry is targeting women. World no tobacco. WHO; 2010 (day 31 May 2010).

2. Rustemeier K, Stabbert R, Haussmann HJ. Evaluation of the potential effects of ingredients added to cigarettes. Part 2: Chemical composition of mainstream smoke. *Food Chem Toxicol* 2002;40:93–104.
3. Russell MAH, Jarvis MJ, Devitt G, Feyerabend C: Nicotine intake by snuff users. *Br Med J*, 1981, 283, 814–817.
4. Tundulawessa Y, Yongchaiyud P, Chutrthong W, Tundulawessa K. The bioequivalent and effect of nicotine formulation gum on smoking cessation. *J. Med. Assoc Thai* 2010; 93 (5):574–9.
5. S.Kanimozhi et.al Protective effects of plants against nicotine induced reproductive toxicity in male animal models – a literature review *Indian Journal of Public Health Research & Development*, December 2019, Vol. 10, No. 12 doi: 10.37506/v10/i12/2019/ijphrd/192236
6. Elshal MF, El-Sayed IH, Elsaied MA, El-Masry SA, Kumosani TA (2009) Sperm head defects and disturbances in spermatozoal chromatin and DNA integrities in idiopathic infertile subjects: Association with cigarette smoking. *Clin Biochem*42: 589-594.
7. Somnath De et al., Phytochemical and GC-MS analysis of bioactive compounds of *Sphaeranthus amaranthoides* *Burm Pharmacognosy Journal* 5(2013)265e268 <http://dx.doi.org/10.1016/j.phcgj.2013.09.005>
8. V. Thanigavelan et al., Pharmacological Study of a Siddha Holistic Herb Sivakaranthai -*Sphaeranthus Amaranthoides* *Burm* for Analgesic and Anti-Inflammatory activities *Journal of Applied Pharmaceutical Science* 02 (01); 2012: 95-101 ISSN: 2231-3354
9. Shannon G. et al., Guidelines on nicotine dose selection for in vivo research *Psychopharmacology* (2007) 190:269–319 DOI 10.1007/s00213-006-0441-0
10. Azza M Gawish et al., Morphometrical, Histopathological, and Cytogenetical Ameliorating Effects of Green Tea Extract on Nicotine Toxicity of the Testis of Rats *Journal of Cytology & Histology* doi:10.4172/2157-7099.1000105
11. Maryam Mosadegh, Nicotine-induced damages in testicular tissue of rats; evidences for bcl-2, p53 and caspase-3 expression *Iran J Basic Med Sci.* 2017 Feb; 20(2): 199–208. doi: 10.22038/ijbms.2017.8249
12. Reddy S, Londonkar R, Ravindra, Reddy S, Patil SB (1998) Testicular changes due to graded doses of nicotine in albino mice. *Indian J Physiol Pharmacol* 42:276-280
13. Ahmadnia H, Ghanbari M, Moradi MR, Khaje-Dalouee M (2007) Effect of Cigarette Smoke on Spermatogenesis in Rats. *Urol J* 4: 159-163.
14. Rachid Mosbah et al., Nicotine-induced reproductive toxicity, oxidative damage, histological changes and haematotoxicity in male rats: The protective effects of green tea extract *Experimental and Toxicologic Pathology* <http://dx.doi.org/10.1016/j.etp.2015.01.001>

15. AM Gawish et al., Sperm abnormality toxicity due to cyclosporine A and the ameliorative effect of royal jelly in male rats *The Journal of Basic & Applied Zoology* doi.org/10.1016/j.jobaz.2016.12.001
16. Patterson TR, Stringham JD, Meikle AW. Nicotine and cotinine inhibit steroidogenesis in mouse Leydig cells. *Life Sci* 1990;46:265–72.
17. W Y Wong et al., Cigarette smoking and the risk of male factor subfertility: minor association between cotinine in seminal plasma and semen morphology *Fertil Steril* .2000Nov;74(5):930-5. doi: 10.1016/s0015-0282(00)01567-3.
18. Bashir Sobhani et al Histopathological Analysis of Testis: Effects of Astaxanthin Treatment against Nicotine Toxicity *Iranian Journal of Toxicology* Volume 13, No. 1, February 2019; <http://www.ijt.ir>
19. Svend G.Johnsen , Testicular Biopsy score count – A method for registration of spermatogenesis in Human Testis: Normal values and results in 335 Hypogonadal males *Hormones* 1 : 2-25 (1970)
20. Lewin, A., Gonen, O., Orvieto, R. and Schenker, J.G. (1991) Effect of Smoking on Concentration, Motility and Zona-Free Hamster Test on Human Sperm. *Archives of Andrology*, 27, 51-54.
21. Sandhya Vijayam Gopalakrishnan Nair et al ., The Role of Coconut Water on Nicotine-Induced Reproductive Dysfunction in Experimental Male Rat Model *Food and Nutrition Sciences* Vol.5 No.12(2014), Article ID:47351,10 pages DOI:10.4236/fns.2014.512122
22. Jain et al., , Effects of Cigarette Smoking on Adult Male Seminal Fluid: A Retrospective Study *International Journal of Scientific Study* DOI: 10.17354/ijss/2015/389
23. Mahsa Nazar-Zadeh, et al., Royal-jelly-based apitherapy can attenuate damages to male reproductive parameter following nicotine administration doi.org/10.1002/ame2.12217
24. ParitaBasnet et al., A review on bio-synthesized zinc oxide nanoparticles using plant extracts as reductants and stabilizing agents *Journal of Photochemistry and Photobiology B: Biology* doi.org/10.1016/j.jphotobiol.2018.04.036