

Organophosphorous compounds in assessment of histomorphological alterations of natural tooth

ABSTRACT:

Background: Pesticide poisoning has indeed been recognized as a significant global health problem, and it is the most common cause of morbidity and mortality. Organophosphorus compounds (OP) are extensively used in agriculture, domestic pest control, and biological agents. Each year, an estimated 25 million farmers in developing countries are poisoned by pesticides, commonly OP, which is known to cause serious health ill effects. **Aim:** The aim of this study is to assess the histomorphological alterations in natural tooth due to exposure to different organophosphorous compounds. **Materials & methods:** This research was carried out with organophosphorous compound - ANUFURAN 3G, carbofuran 3% CG purchased from local commercial market. The OP was available as solid crystals which made into a solution by adding 1g of OP compounds to 100ml of distilled water. The natural tooth was immersed in the respective solution for an hour and assessed for morphological & histological alterations through ground sections (200µm). **Results:** Visually, there were very mild purplish tint on the cervical and apical 1/3rd of the tooth. Histologically, there were increased enamel lamellae which may have propagated to crack. The dentinal tubules were prominent and the pulpal tissue was completely dissolved. **Conclusion:** The OP compounds did not prove to show any morphological or histological alterations to natural tooth.

Keywords: Histomorphological alterations; Natural tooth; Organophosphorus compounds

INTRODUCTION:

Organophosphorus compounds (OPs) are a diverse group of chemicals which are phosphoric, phosphonic or phosphinic acid derivatives ⁽¹⁾. These OPs are broad group of organic compounds primarily used as pesticides which are highly effective insecticides, although some are extremely toxic to humans. Serious poisonings due to misuse of OP insecticides have been reported for more than four decades. OP compound poisoning continues to be a frequent reason for suicides in developing countries ⁽²⁾. The complete diagnosis of poisoning is usually a collaborative diagnosis of a forensic pathologist and toxicologist ⁽³⁾. There should be a complete internal and external examination of the body in suspected case of poisoning which provides more required data ⁽³⁾. In OP poisoning, the conventional approach to

clinical features has focused on the muscarinic, nicotinic and central nervous system (CNS) that result in different symptoms and signs⁽²⁾. One different approach is the identification of morphological alterations observed in natural tooth which are exposed to OPs for a specified time span. Teeth are the most enduring human structure which acts as an indication in evaluating the age and sex in forensic sciences⁽⁴⁾. In anthropological, genetic, odontological and forensic investigations, teeth are considered to be important organs in both living and non-living populations. This is due to the dental tissues' hardness and high resistance to decay and putrefaction, allowing the teeth to survive for longer periods than other human tissues⁽⁵⁾.

There are few similar studies that have performed to evaluate the morphological alterations in natural tooth which are exposed to different acids. One author identified the use of acids in the crimes and analyzed the morphological changes in the teeth⁽⁵⁾. Also, another author identified the morphological alterations in natural tooth exposed to 37% hydrochloric acid (conc. HCl), 65% nitric acid (conc. HNO₃) and 96% sulfuric acid (conc. H₂SO₄) at different time span⁽⁴⁾. No other studies have been performed to evaluate the morphological alterations in natural tooth which are exposed to different organophosphorous compounds.

The aim of this study is to assess the histomorphological alterations in natural tooth due to exposure to organophosphorous compounds.

MATERIALS AND METHODS:

This study was conducted in the department of Oral & Maxillofacial Pathology, Saveetha dental college & hospitals, Chennai. The samples were randomly collected from the department of Oral & Maxillofacial Surgery, Saveetha dental college & hospitals, Chennai. The ethical approval for this study was obtained from Institutional Review Board (IRB). The organophosphorous compound used in this research was purchased from local commercial market [ANUFURAN 3G, carbofuran 3% CG]. This ANUFURAN 3G is available as solid purple crystals; of which 1g is measured and dissolved in 100ml of distilled water to facilitate the solution form. Initially the tooth samples were immersed in concentrated organophosphorous compound solution and after a time span of 1 hour, the exposed teeth were recovered, washed in distilled water, cleaned, photographed, and 200µm ground parts were rendered with a hard tissue microtome. Under light microscopy, the ground sections were examined for morphological changes in enamel, dentin, pulp, and cementum.

Sample selection:

Inclusion criteria: Teeth free of any defects, preferably orthodontic tooth extraction and impacted tooth were included in the study.

Exclusion Criteria: Carious teeth, teeth with pulpal, periapical or periodontal diseases, teeth with physiological wear, developmental defects were excluded from the study.

Results:

Organophosphorous compound: ANUFURAN 3G, carbofuran 3% CG was available as solid purple crystals and it had a very strong pungent odor; in which the odor sustained until the entire process of tooth immersion (figure 1a & 1b).



Figure 1a: The commercially available OP compound used in this assessment

Figure 1b: The OP compound solution – 1g in 100ml of distilled water; purple color

Alterations in the morphology of the tooth: The natural teeth immersed in OP compound were retrieved after an hour and then examined under a light microscope for morphological changes.

Visual changes: Very mild color changes were observed in the cervical region and the apical 1/3rd of the tooth after an hour. Visually or physically the tooth's structure and morphology have not been altered except for the color (figure 2).

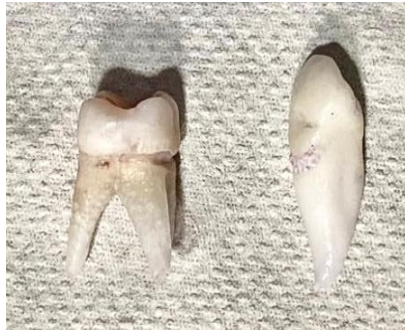

Figure 2 shows a newly extracted natural tooth that was exposed to an OP compound solution for an hour. The cervical region and the apical 1/3rd of the tooth have a slight purplish tint.

Morphological changes: After 1-hour,

Enamel: The hypocalcified structures of the enamel were more prominent and more in number compared to the natural tooth that are not exposed to the OP compound. The enamel lamellae were more than the enamel tufts and spindles (figure 3).

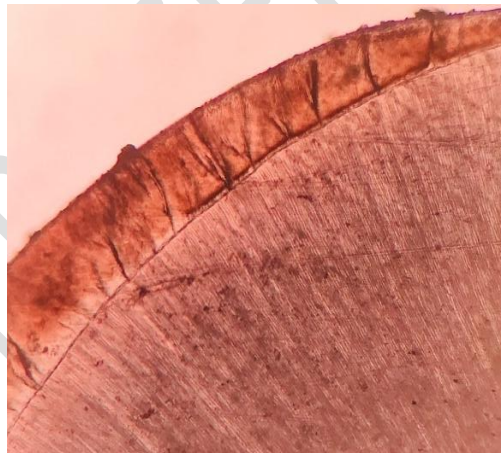


Figure 3: 10X magnification - ground section of the OP compound immersed natural tooth showing prominent hypocalcified enamel structures.

Dentin: The dentinal tubules are more prominent but unfortunately no other changes noted in dentin in ground sections (figure 4).

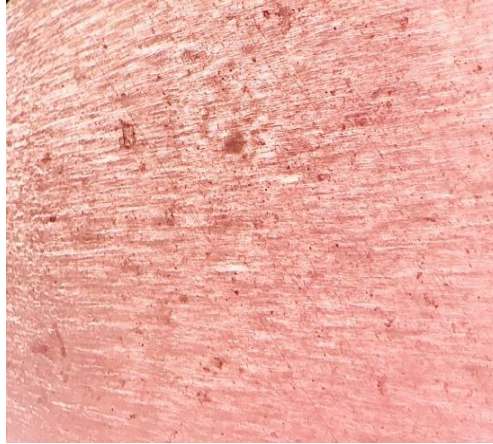


Figure 4: 40X magnification - ground section of the OP compound immersed natural tooth showing prominent dentinal tubules.

Pulp: The pulp was completely lost in OP compound exposed tooth, hence couldn't be assessed.

Discussion:

For several decades, OP compounds have been commonly used in agriculture for sustainable agriculture, pest control, and veterinary. These OPs are usually classified as high, intermediate and low depending on its toxicity⁽⁶⁾. The precise compound, amount, route of exposure, and rate of metabolic degradation also determines the toxicity of the OP compounds^(6, 7). The oral cavity was studied and the most common signs found were thickening of the oral mucous membranes with slight whitish discoloration and moderate to severe white discoloration with the attached gingival. White spots may also be found on the tongue. Most OP compounds are highly lipid soluble compounds and absorbed better through skin, oral mucous membranes, and conjunctiva^(7, 8). Previous evidences reveal that OP compounds are proven to have effects of the oral soft tissues yet the effect on the oral hard tissues have not been proved.

The visual changes noticed in the tooth are very mild color change on the surface. These changes are noticed particularly on the cervical region and apical 1/3rd of the tooth. The purplish color tint on the surface is very mild, that the possibilities of not noticing it are high. This could be due to the different concentrations of dyes that are used in the OP compounds. There are no previous literatures to prove the influence of dye on the surface of the tooth.

The number of hypocalcified structures, notably the enamel lamellae, was significantly higher in teeth immersed in OP compounds than in teeth not exposed to OP compounds. More than enamel tufts and spindles made up the enamel lamellae. Caries-causing bacteria can enter the dentine-enamel junction via the enamel lamellae, which have been shown to be permeable. Because of the presence of lamellae, caries may develop within the tooth without leaving visible signs on the surface. When there are disruptions during enamel formation, as well as when external forces are more at play at a later stage of life, these lamellae propagate to form a crack^(9, 10). The lamellae may have cracked as a result of the OP compound.

The dentinal tubules were prominent in the ground sections of the tooth exposed to OP compounds. The prominence in dentinal tubules is normal histological structure of a tooth. This does not signify any positive alterations in the tooth due to OP compounds.

In the ground sections, there is no evidence of pulp. This may be due to the soft tissue or pulp dissolving through the apical foramen, or it may be due to wear off during ground sectioning, but the methodological fault might not be apparent in all of the samples examined. There is no evidence in the literature to support this pulp dissolution due to OP compounds.

CONCLUSION:

Unfortunately, we couldn't positively conclude that the OP compounds have produced noticeable changes to the tooth structures, so further individual identification in suicidal or homicidal crime investigation using these changes is not possible.

COMPETING INTERESTS DISCLAIMER:

Authors have declared that no competing interests exist. The products used for this research are commonly and predominantly use products in our area of research and country. There is absolutely no conflict of interest between the authors and producers of the products because we do not intend to use these products as an avenue for any litigation but for the advancement of knowledge. Also, the research was not funded by the producing company rather it was funded by personal efforts of the authors.

References:

1. Bosak A. [Organophosphorus compounds: classification and enzyme reactions]. *Arh Hig Rada Toksikol* . 2006 Dec;57(4):445–57. Available from: <https://www.ncbi.nlm.nih.gov/pubmed/17265684>
2. Peter JV, Sudarsan TI, Moran JL. Clinical features of organophosphate poisoning: A review of different classification systems and approaches. *Indian J Crit Care Med* . 2014 Nov;18(11):735–45. Available from: <http://dx.doi.org/10.4103/0972-5229.144017>
3. Chandravanshi LP. Assessment and Diagnosis of Poisoning with Characteristics Features in Living or Dead . *Journal of Forensic Sciences & Criminal Investigation*. 2018. Vol. 10. Available from: <http://dx.doi.org/10.19080/jfsci.2018.10.555796>
4. Raj M, Boaz K, Srikant N. Are teeth evidence in acid environment . *Journal of Forensic Dental Sciences*. 2013. Vol. 5. p. 7. Available from: <http://dx.doi.org/10.4103/0975-1475.114536>
5. Seethapathy T, Shylaja S, Sekhar MSM, Manthapuri S, Ramanand OV, Reddy SK, et al. Effect of Acids on Teeth and Restorative Materials: An Aid in Forensic Odontology ., *Journal of Hard Tissue Biology*. 2019. Vol. 28.p. 21–30. Available from: <http://dx.doi.org/10.2485/jhtb.28.21>
6. Bajracharya SR, Prasad PN, Ghimire R. Management of Organophosphorus Poisoning. *J Nepal Health Res Counc* . 2016 Sep;14(34):131–8. Available from: <https://www.ncbi.nlm.nih.gov/pubmed/28327676>
7. Oral Manifestations of Poisons in View of Forensic Odontology-A Review . *Medico-Legal Update*. 2020.Vol. 20. Available from: <http://dx.doi.org/10.37506/mlu.v20i4.1753>
8. Sethi S, Goel P, Bhalla S. Oral Cavity: An insight to forensic diagnosis . *Asian Pacific Journal of Health Sciences*. 2015. Vol. 2. p. 142–7. Available from: <http://dx.doi.org/10.21276/apjhs.2015.2.2.22>
9. Walker BN, Makinson OF, Peters MC. Enamel cracks. The role of enamel lamellae in caries initiation. *Aust Dent J* . 1998 Apr;43(2):110–6. Available from: <http://dx.doi.org/10.1111/j.1834-7819.1998.tb06099.x>
10. Bodecker CF. Enamel lamellae and their origin. *J Dent Res* . 1953 Apr;32(2):239–45. Available from: <http://dx.doi.org/10.1177/00220345530320021301>