

Case study

“Direct Sinus augmentation procedure for rehabilitation of severely atrophic posterior maxilla with sticky bone – A case report”

ABSTRACT

Aim: Rehabilitation of atrophic maxilla using sticky bone and simultaneous implant placement.

Presentation of cases. Sinus augmentation along with simultaneous implant placement prevents the additional surgery. This often benefits both the patient and the dentist. This case report highlights the sinus augmentation procedure for rehabilitation of a severely atrophic posterior maxilla using Sticky bone, a combination of Xenograft and Platelet rich fibrin with simultaneous dental implant placement.

Discussion : Pneumatization of posterior maxilla often complicates dental implant surgery. Various sinus lift surgical procedures have been developed over the years, to increase residual alveolar ridge height. Implant placement is made easier by enhancing the posterior maxilla by various sinus augmentation procedure

Conclusion: Direct sinus augmentation procedure using sticky bone for rehabilitation of severely atrophic posterior maxilla with simultaneous implant placement provides a reliable and predictable outcome.

Keywords: Atrophic maxilla, direct sinus lift, Pneumatization, Sinus augmentation, Sticky bone.

1. INTRODUCTION

The posterior maxilla is usually difficult for implant placement due to pneumatization of the maxillary sinus, poor quality of alveolar bone, and higher occlusal forces. Pneumatization usually occurs due to an increase in positive intra-antral pressure and osteoclastic activity with decrease in bone remodeling. This pneumatization is difficult to manage which has led to innovation of “Sinus lift procedures”.

In the posterior maxilla, vertical alveolar ridge augmentation is frequently required. Augmentation is usually done by elevating the sinus membrane and placement of bone graft material beneath it. Implant can be placed simultaneously after grafting or can be delayed after the healing period. Tatum proposed this technique in the year 1977. It was then published by Boyne and James¹.

There are two main techniques of sinus elevation:

- Lateral window (direct) sinus augmentation technique
- Transcrestal (indirect) sinus augmentation technique.

Indirect sinus technique involves elevation of floor of sinus membrane indirectly from the crest of alveolar ridge, when vertical residual bone height is more than 5mm. On contrary when the vertical residual bone height from the crest of alveolar ridge to the floor of sinus membrane is less than 5mm lateral window technique of sinus membrane elevation is followed. Over the years various direct sinus augmentation technique have been used as Summers's crestal approach, lateral bony window osteotomy using piezoelectric surgery, lateral membrane balloon elevation etc.¹

Although the direct sinus lift procedure is reliable and predictable it is also technique sensitive procedure. Posterior maxilla often challenges the operator for implant placement. Maxillary bone is a porous bone (spongy in nature). For healthy functioning of dental implants the bone surrounding it should be stress bearing in nature for transferring the stresses to the underlying bone. Maxillary sinus has a volume of about 15ml air space. As the patient gets edentulous the alveolar bone reduces thus making it unsuitable for implant placement. Thus various sinus augmentation procedures are required for simultaneous placement of implant.²

Various bone augmentation procedures using bone graft materials, platelets and fibrinogen have been introduced in cases of severely resorbed ridges to create sufficient bone quantity. The use of growth factor enriched fibrin glue known as sticky bone, has shown promising results as it stabilizes bone graft preventing bone loss and accelerating tissue healing.³ Thus, this case report elucidates the direct sinus lift procedure performed in the posterior maxilla along with the grafting procedure using sticky bone to increase the amount of available bone and preparing it for simultaneous implant placement using conventional lateral window preparation.

2. PRESENTATION OF CASE

3. A 40-year-old female patient reported to Department of Prosthodontics and Crown and Bridge KAHER KLE's V.K. Institute of Dental Sciences, Belagavi with the chief complaint of missing teeth in upper left back region of the jaw. On examination there were missing tooth number #15, #16 and #17. (Figure 1a and 1b) On detailed examination, all the posterior teeth in the right posterior back region were lost due to poor periodontal condition and tooth mobility. Patient had no related systemic conditions. A detailed blood investigation was performed followed by radiographic examination. A single view orthopantomograph (OPG) was advised to check for the available bone quantity at the area of interest. (Figure 2) On radiographic evaluation, there was insufficient bone height present for implant placement using a conventional approach. On careful examination and consideration of the distortion factor of the OPG, approximately 11 mm of bone in height was present in #15 region, 3mm of bone at #16 region and 12mm at #17 region radiographically. The width of the bone in #15 - #17 region was measured using a graduated bone caliper, measuring approximately 6-7mm.
4. Patient was informed about the best possible treatment modalities using removable denture prosthesis and fixed denture prosthesis using dental implants with simultaneous sinus floor elevation using a lateral window approach. After careful consideration, patient opted for the fixed denture prosthesis option using dental implants and direct sinus elevation procedure. An informed consent was obtained from the patient, explaining the total time duration and cost involved in the treatment. Presurgical diagnostic impressions and cast were made (Figure 3). A partially limiting stent of autopolymerizing clear acrylic resin was made according to the bone mapping done at the #15, #16 and #17 region (Figure 4). On radiographic and clinical evaluation, a sand blasted and acid etched (SA) OSSTEM TSIII implant of size 4*10 mm was selected.

5. SURGICAL PHASE:

Prior to the surgery, patient was administered prophylactic antibiotics and analgesics. The maxillary posterior region was anesthetized by buccal and palatal infiltrations using 2% lignocaine with 1:80,000 adrenaline solution (Xicaine). Once the surgical site was anesthetized, a crestal incision was made with no.15 surgical blade extending from distal surface of #14 till the maxillary tuberosity. A vertical releasing incision was made extending in the buccal vestibule. A full thickness muco periosteal flap was raised till the zygomatic buttress. The approximate boundaries of lateral window were outlined. (Figure 5) A straight handpiece and round carbide bur no #8 under copious irrigation at 30,000rpm was used and the outline of lateral window was scored. The lateral window was carefully detached and stored in normal saline and the lateral wall of the sinus membrane was exposed.(Figure6)

6. Careful and safe instrumentation was carried using sinus curettes along the margin of the window at 360 degrees along the entire lateral window out to detach the sinus membrane from the host bone. The patency of the sinus membrane was checked and confirmed for any perforation. On confirmation of the patency, a resorbable collagen membrane, soaked in saline was introduced into the lateral window over the detached sinus membrane. (Figure7) The osteotomy site was prepared and widened gradually using simultaneous twist drills in the #15 and #17 region

and implants with size 4*10 were motor driven at 25rpm into the osteotomy, achieving a primary stability of 40N. (Figure8)

7. STICKY BONE PREPARATION

8. Around 20 ml peripheral venous blood of the patient was collected in a non-coated tube without any anticoagulant for extracting Platelet rich fibrin (PRF). The tubes were centrifuged at 2,700 rpm for 10 minutes.⁴ After separation of the plasma and packed red blood cells, PRF was extracted from the tube and mixed with xenograft and allowed to stay in a dish until it formed sticky bone. It was then packed in the lateral window and closed using a PRF membrane followed by placement of a synthetic collagen membrane which was stabilized using membrane stabilizing sutures.(Figure9a&b) Flaps were then approximated and passive primary closure was achieved using 3-0 black braided silk sutures. Post implant placement, an IOPA and OPG was taken to assess the position of the implant (Figure 10). Postoperative instructions and medications were given and the patient was recalled after 6months for follow up at regular intervals for evaluation of healing process.

3. DISCUSSION

Prolonged tooth loss and edentulism promotes increased bone insufficiency in height, width, and density. The most common type of bone in the edentulous posterior maxilla consists of D3/D4 type. Poor bone quality and quantity often cause setbacks in the placement of dental implants in the posterior maxillary region using conventional approach, necessitating accessory augmentation procedure.² According to Avichai Stern et al, sinus augmentation is usually indicated when there is excess bone loss post extraction and pneumatization of the sinus which results in poor quality of bone for implant placement. The author stated various condition which classified the edentulous maxilla with remaining alveolar bone. If there is remaining bone of 0-4mm, an open sinus lift with delayed implant placement can be planned. If the remaining alveolar bone of 5-10 mm an open sinus lift surgery with immediate implant placement is carried out. The advantage of simultaneous placement being the less psychological stress, less fear of extra surgery, and less postoperative pain management.⁵

In the present case, only 2-3 mm of bone was available in the right posterior molar region. Since the period of edentulism was more than a year that resulted in loss of bone height and density which further led to pneumatization of the sinus. Pulkit Khandelwal reported when the vertical height is less than 5mm a lateral window technique with bone grafting is recommended. Thus taking into consideration the bone contour, the sinus anatomy as well as remaining amount of residual alveolar bone, a direct sinus lift was performed.¹

Bone augmentation is usually required when there is insufficient available bone. A recent concept is introduced of creating growth factors-enriched bone graft matrix commonly known as "sticky bone." Sticky bone offers stabilization of bone graft in the defect, and consequently, accelerates tissue repair and decreases bone loss during healing period. Using autogenous graft along with growth factor has an advantage of faster tissue regeneration. Osseograft is a xenogenic demineralized bone matrix, it consist of collagen type 1 that is prepared from bovine cortical bone samples.⁶ According to the study done by Rajan Gupta et al osseograft showed bone gain of 56.5% at 6 months in all patients at all test sites.⁷

Elevation of sinus membrane is a technique sensitive procedure. The most common complication involved is the perforation of "Schniderian Membrane". It can occur while preparing or while instrumentation of separating it from the host bone.² In order to prevent many such complications a proper design and order was followed for direct lift procedure. According to Misch et al, creating a window helped in easy access, direct vision and proper instrumentation at the site.

Misch, in 1987 developed four categories, as treatment option for the amount of remaining available bone in posterior maxilla. He proposed a classification on sinus augmentation and surgical approach, bone graft material, and a time table for healing before prosthetic reconstruction as shown in (Figure11).⁸ The present case was categorized accordingly as SA-3, requiring direct sinus lift and grafting with immediate placement of implants.

Platelet rich fibrin (PRF) is a healing biomaterial which acts as a scaffold at the site. It is an autologous leukocyte-platelet-rich fibrin matrix comprising cytokines, platelets, and stem cells that works as a biodegradable scaffold and promotes micro-vascularization and epithelial cell migration to its surface.⁹ According to study performed by Antonio Cortese et al, PRF has been a safe, reliable procedure, that has drastically improved the clinical outcome of the patient with horizontal bone defects.³

This case was challenging as there was lot of pneumatization of maxillary sinus and less amount of vertical available bone. Adoption to the conventional technique with addition of tissue generation growth factors to the bone graft material will expedite the healing and promote bone growth. However, the present technique and procedure is technique sensitive, possibility of schneiderian membrane tear/perforation requiring additional surgical intervention. Although, various other techniques other than the conventional technique can be used to reduce the surgical tear caused to the delicate membrane. Other methods, like the use of piezoelectric technique offer a better patient compliance, thereby reducing

discomfort with greater precision and integrity of membrane thus reducing the intraoperative bleeding.¹⁰ Over the years an upgradation of surgical techniques can be performed for the successful evaluation and benefits of the patients.

4. CONCLUSION

Direct sinus lift is a good predictable treatment option where there is less amount of vertical bone available. Bone augmentation procedure along with the autologous fibrin glue (sticky bone) will further enhance the tissue regeneration and bone growth. Simultaneous implant placement with an aided advantage of sticky bone deaccelerates the bone loss. Lastly it depends upon the skills of the operator, compliance of the patient in successful integration of implant in the bone. Proper postoperative evaluation is a key for a reliable and predictable outcome.

CONSENT (WHERE EVER APPLICABLE)

"All authors declare that 'written informed consent was obtained from the patient (or other approved parties) for publication of this case report and accompanying images. A copy of the written consent is available for review by the Editorial office/Chief Editor/Editorial Board members of this journal."

REFERENCES:

- 1) Khandelwal P, Dhupar V, Akkara F, Hajira N. Direct maxillary sinus floor augmentation and simultaneous implant placement for rehabilitation of the severely resorbed posterior maxilla: A prospective clinical study. *Indian Journal of Dental Research*. 2020 May 1;31(3):449.
- 2) Garg AK. Augmentation grafting of the maxillary sinus for placement of dental implants: anatomy, physiology, and procedures. *Implant dentistry*. 1999 Jan 1;8(1):36-46.
- 3) Purushotham S, Raveendran AM, Kripalani BK, D'Souza ML. Direct sinus lift and immediate implant placement using piezosurgical approach-A case report. *Journal of clinical and diagnostic research: JCDR*. 2016 Jan;10(1):ZD20.
- 4) Cortese A, Pantaleo G, Amato M, Howard CM, Pedicini L, Claudio PP. Platelet-rich fibrin (PRF) in implants dentistry in combination with new bone regenerative flapless technique: evolution of the technique and final results. *Open Medicine*. 2017 Jan 1;12(1):24-32.
- 5) Stern A, Green J. Sinus lift procedures: an overview of current techniques. *Dental Clinics of North America*. 2012 Jan 1;56(1):219.
- 6) Sohn DS, Kim J. Utilization of Autologous Concentrated Growth Factors (CGF) Enriched Bone Gra Matrix (Sticky Bone) and CGF-Enriched fibrin membrane in implant dentistry *J Periodontol Implant Dent*. 2015 Dec (10):11-29
- 7) Gupta R, Pandit N, Malik R, Sood S, Sood S. Clinical and radiological evaluation of an osseous xenograft for the treatment of infrabony defects. *Journal of the Canadian Dental Association*. 2007 Jul 1;73(6).
- 8) Randolph Resnik et al , contemporary implant dentistry, elsevier 4th edition 987-53 2021

- 9) Hartshorne J, Gluckman H. A comprehensive clinical review of Platelet Rich Fibrin (PRF) and its role in promoting tissue healing and regeneration in dentistry. *Int. Dentistry Afr. Ed.* 2016;6(5):14-24.
- 10) Bathla SC, Fry RR, Majumdar K. Maxillary sinus augmentation. *J Indian Soc Periodontol.* 2018 Nov-Dec;22(6):468-473

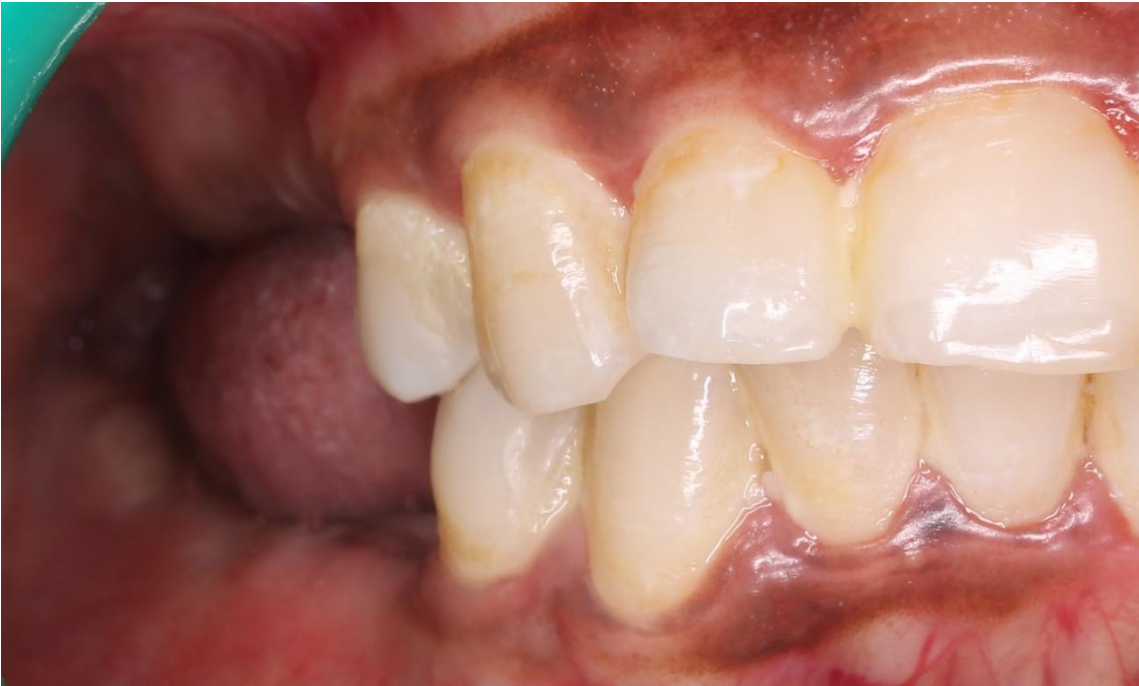

Figure 1a: Pre-operative photographs. Intra-oral photograph showing missing right maxillary first molar.

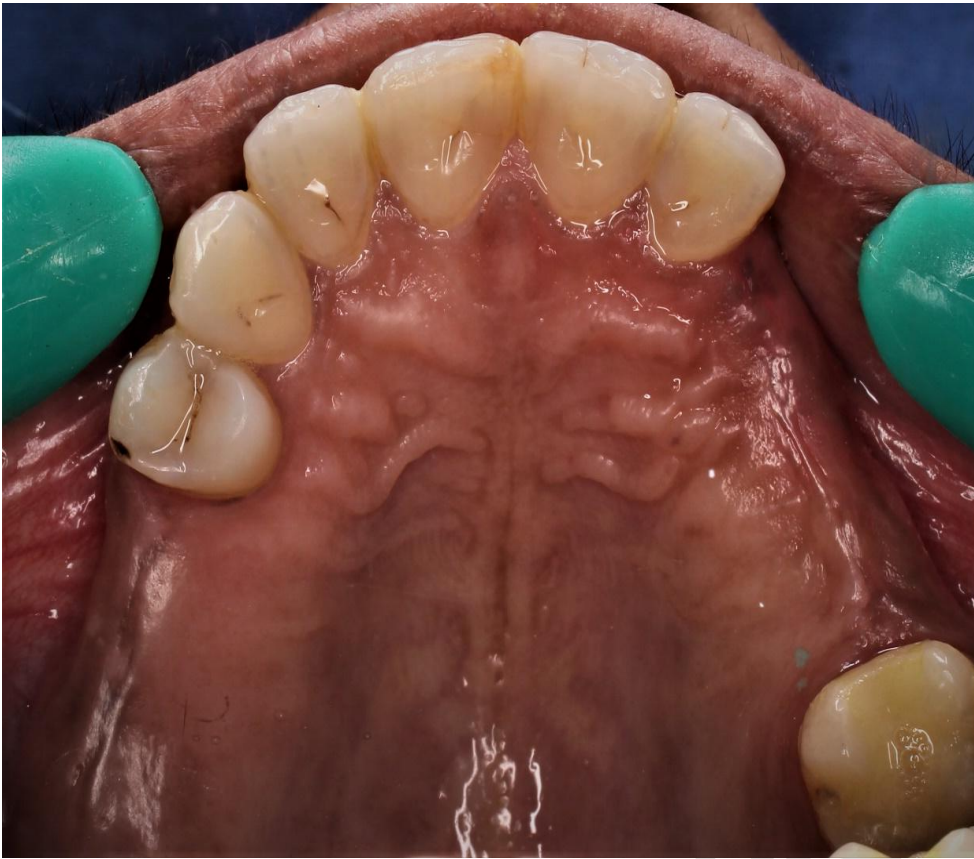

Figure1b: occlusal photographs showing missing #15, #16 and #17

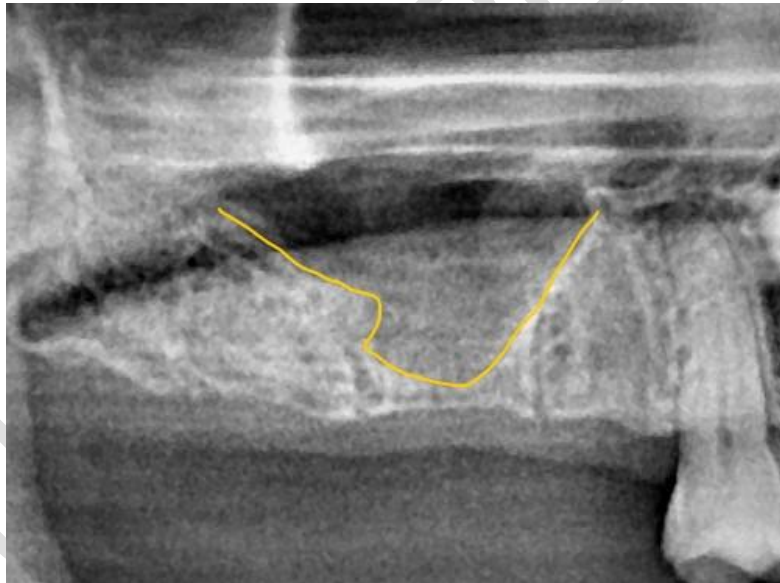

Figure 2: Preoperative radiograph showing pneumatisation of maxillary sinus in the region of #15, #16,#17

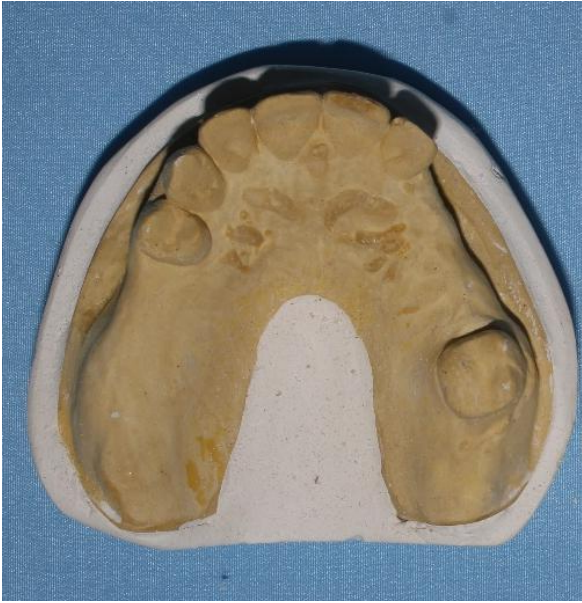

Figure 3: Diagnostic cast

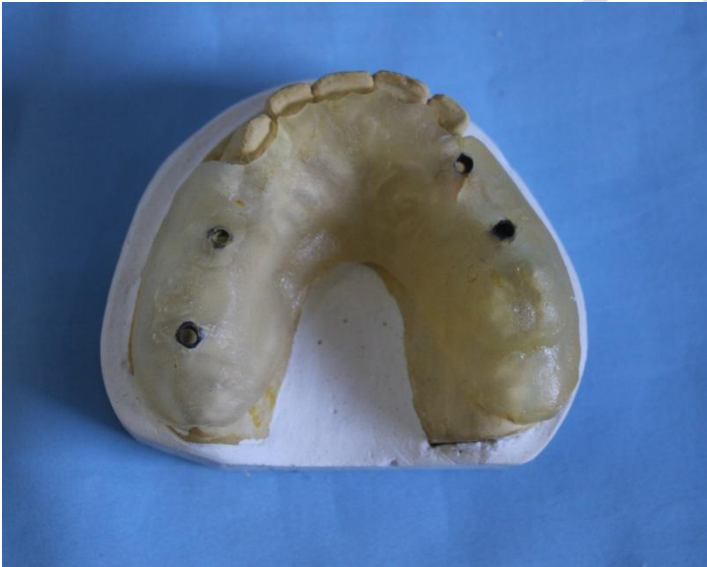

Figure 4: Partially limiting autopolymerising surgical stent

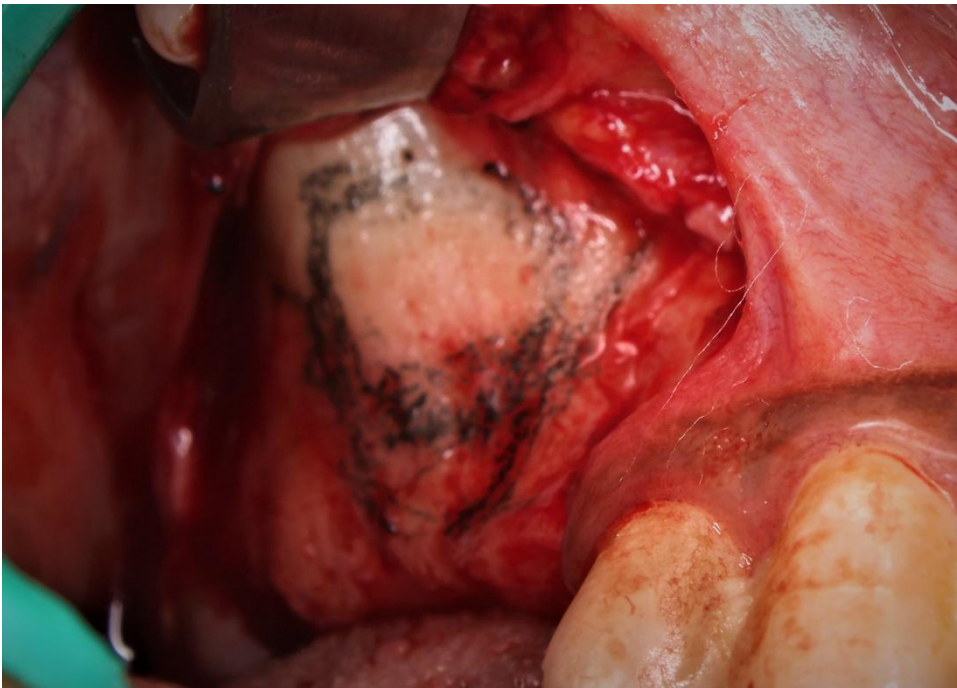


Figure 5: Delineation of maxillary sinus and lateral window

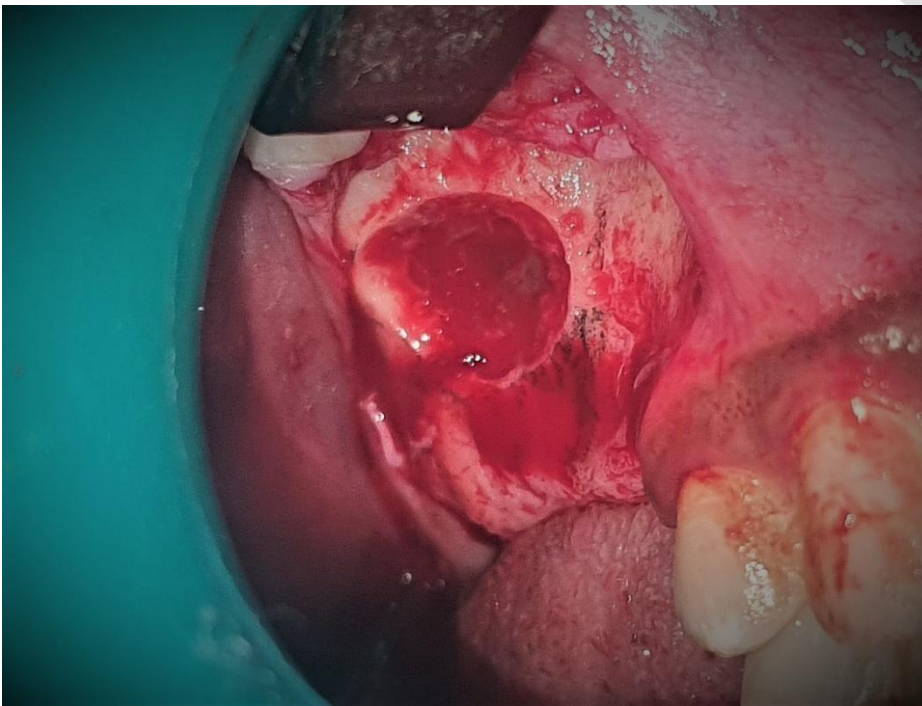

Figure6: Intact sinus membrane

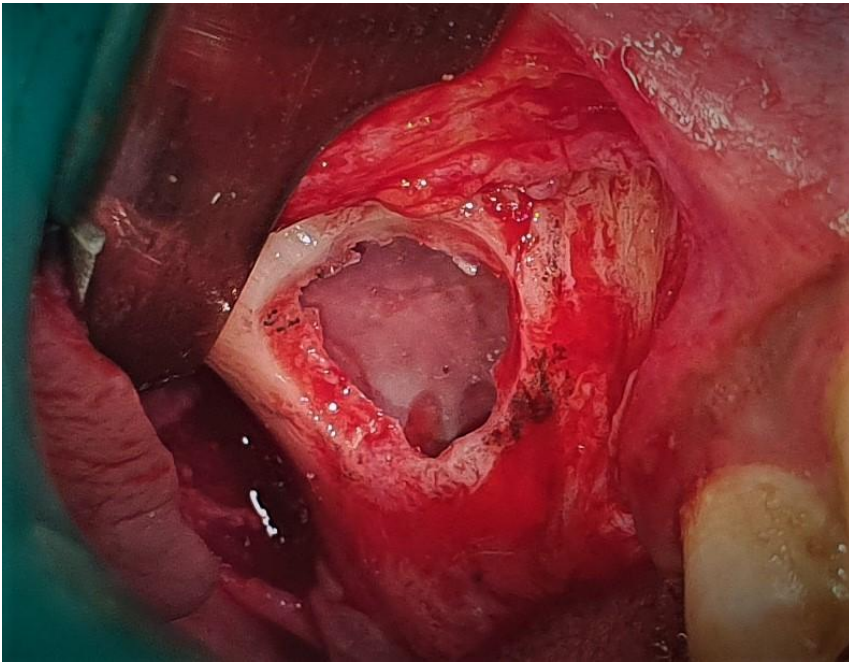


Figure 7: Introduction of Resorbable collagen membrane in the sinus

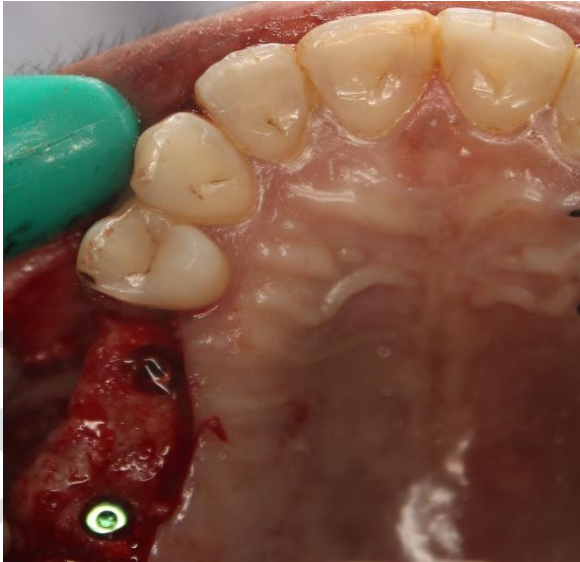


Figure 8: simultaneous implant placement at the region of #15 and #17

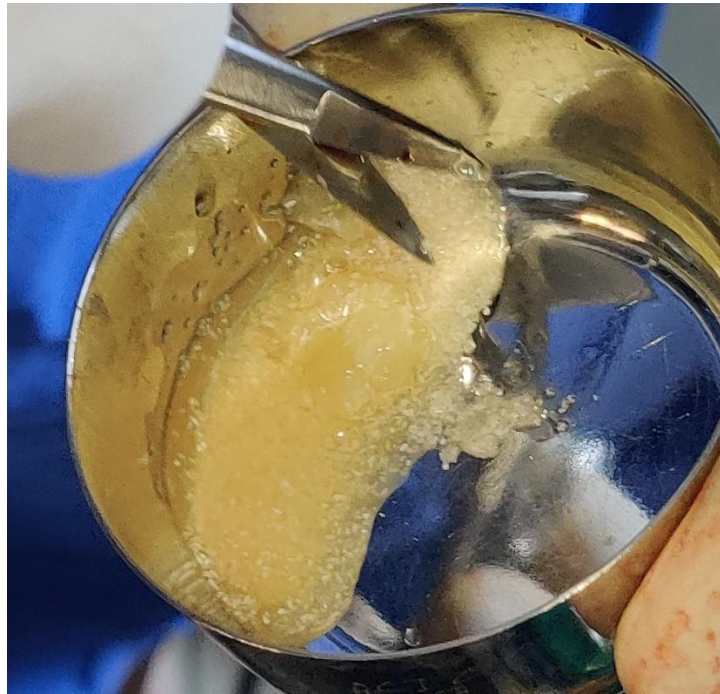


Figure 9a: preparation of sticky bone

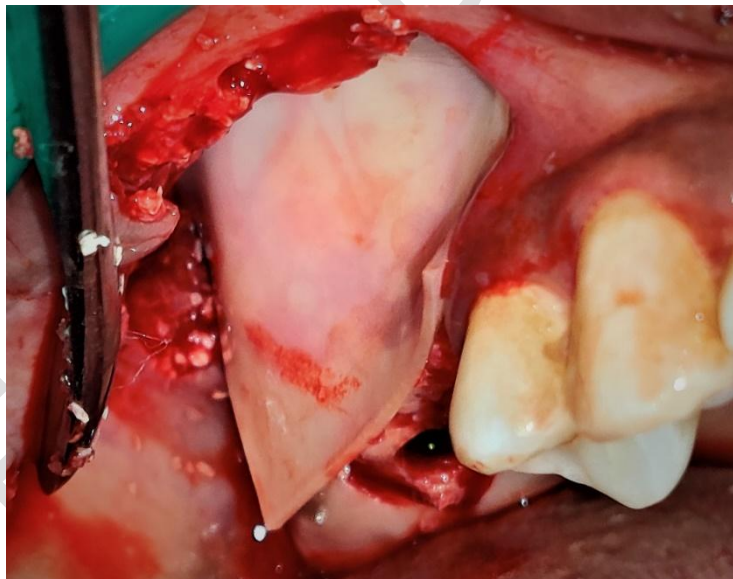


Figure 9b: Placement of collagen membrane for stabilization of sticky bone

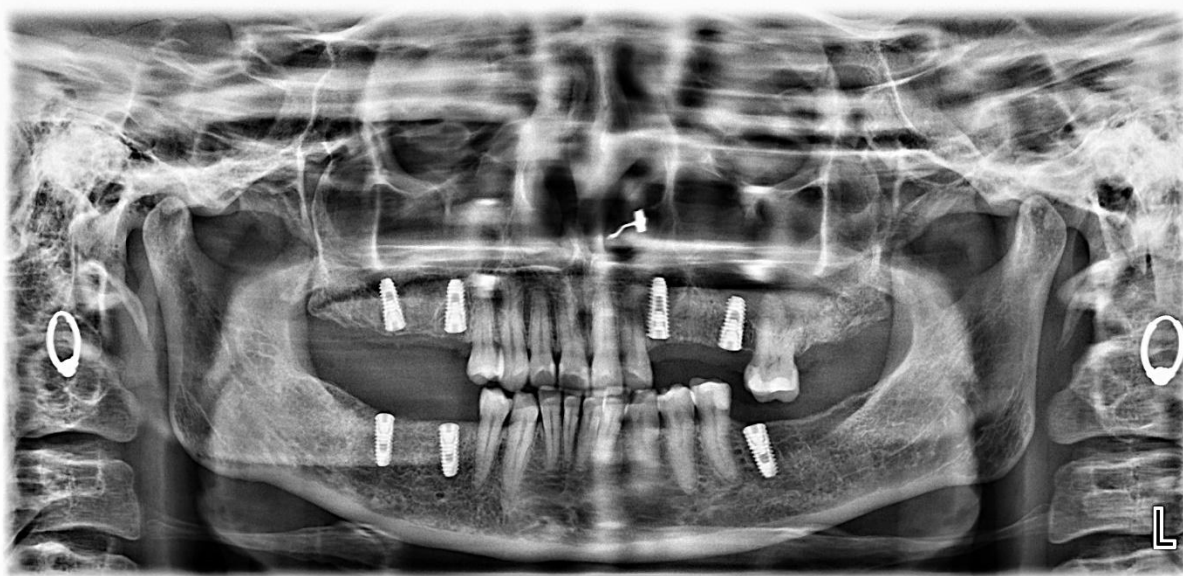


Figure 10: Post-operative OPG showing implant placement at region of #15 and #17

FIGURE 11: MISCH CLASSIFICATION FOR SINUS AUGMENTATION: SUBANTRAL APPROACH

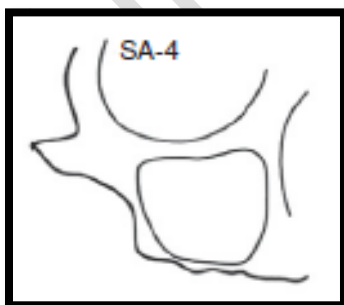
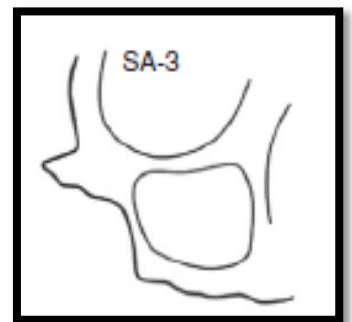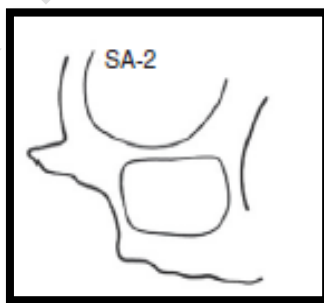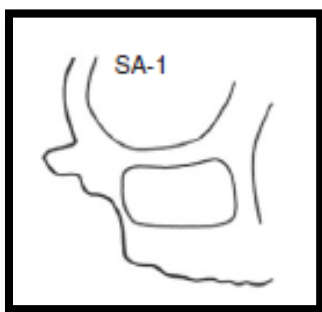(SA)

SA 1: Conventional Implant Placement

SA2: Sinus Lift and Simultaneous Implant Placement

SA3: Sinus Graft with Immediate or Delayed Endosteal Implant Placement

SA4: Sinus Graft Healing and Extended Delay of Implant Insertion



UNDER PEER REVIEW