

A randomized control trial of clinical success and acceptability of the Hall Technique and Resin-modified Glass Ionomer Cement restorations in sealing carious primary molars

Abstract:

Background: A paradigm shift in the caries management propelled interest in techniques for sealing caries and restorations with selective caries removal. Prefabricated Metal Crowns (PMCs) and Resin-modified Glass Ionomer Cement (RMGIC) have been preferred choices of restorations for carious primary molars. This is the first study from India on the Hall Technique used to seal carious primary molars.

Objective: To compare the clinical success and acceptability of the Hall Technique and RMGIC restorations in sealing carious primary molars.

Methods: Sixty 7–8-year-old children having caries with ICDAS scores 3-5, requiring two or more restorations; a total of 140 teeth were randomized into Group A: HT ($n_1 = 73$ teeth) or Group B: RMGIC ($n_2 = 67$ teeth). A single calibrated operator assessed the ‘Major’ failures (abscess, secondary caries, new caries) and ‘Minor’ failures (dislodgement) over a period of 15 months. Children, parents, and operator rated the acceptability. The average time taken for each procedure was recorded.

Results: ‘Major’ failures were statistically significantly higher in the RMGIC group ($p=0.008$). At the 12-month follow-up, the HT outperformed RMGIC restorations. Additional failures were seen in Group B: RMGIC restorations at 15-month follow-up, whereas no failures were seen with HT. The result was statistically not significant. Children, parents, and the operator preferred the Hall Technique, which was statistically significant ($p < 0.001$).

Conclusion: HT is a successful and acceptable technique and superior to RMGIC restorations with partial excavation of caries in primary molars but with mild post-operative discomfort.

Keyword(s): Dental Caries, Hall Technique, primary molars, ICDAS, randomized clinical trial, Resin-Modified Glass Ionomer Cement, stainless steel crowns.

Introduction

Dental caries in children is a public health concern affecting 60-90% of school children in industrialized countries [1]. A recent study assessed the trend in caries prevalence and the mean decayed, missing, filled/Decayed, Missing, Filled (dmf/DMF) index score among Indian children for the past 25 years. In the 2-5, 6-10, and 11-15 year, of age group, the prevalence of dental caries was 48.9%, 69.1%, and 52.1%. This review suggests that one out of two children in all the regions of India are affected by dental caries [2].

Traditionally, the extent of carious lesion and its progress has influenced the treatment decision [3]. The modern approach in caries management focuses on arresting the lesions and disturbing or modifying the plaque [4]. Restorations have finite success, and the repeat restoration cycle often reduces the survival of a tooth [5]. The rationale for complete caries removal is debated in the existing literature and considered as “potentially damaging even to attempt to remove all infected dentin in a symptomless, vital tooth” [6]. It may not be possible or essential to remove all caries, and moreover, a properly placed restoration that seals the cavity, can stop the progress of lesion without jeopardizing pulpal vitality. Once the cariogenic bacteria are isolated from the nutrient source, i.e., the oral environment, it can bring about successful treatment outcomes [6].

A Cochrane Review summarized that stepwise and partial excavation reduced the incidence of pulp exposure in symptomless, vital, carious primary as well as permanent teeth and can be

considered clinically advantageous over complete caries excavation [7].The researchers concluded that removal of infected dentin was not important for caries arrestment since the carious dentin tended to reorganize in a short period when properly sealed, and the remineralization process continued thereafter. Proper prior assessment of pulp status appears to be an important determinant for the success of this practice[8].In addition, evidence-based research summarizes that the crowns fitted using HT or following pulp therapy are less likely to have a risk of major failure or pain in the long term compared to fillings [9].

It is understood that no restorative material can be regarded as truly permanent and may be potentially damaging either to the tooth structure or the restoration in the event of its failure [3]. Only in case of loss of surface integrity and cavitation, a surgical intervention is desirable for eliminating surface cavitation, placement of a suitable restorative material with an ability to seal the margins to prevent the microleakage, and preventing further plaque accumulation [3,10].

Resin-modified Glass Ionomers (RMGICs) have an annual failure rate that is lesser as compared to conventional glass ionomers, and comparable to compomers and composites [11,12]. RMGICs have been recommended for primary teeth for occlusal as well as proximal restorations[13].Authors have concluded that the survival rates were similar regarding the number of restored surfaces and the caries removal technique (partial or complete) [14].A retrospective study by Webman (2018) reported an annual failure rate of RMGICs to be 0.86% including small to moderate sized Class II restorations[15].

Hall technique of stainless steel crown placement has proved to be a viable restorative option for carious primary molars resulting in its successful exfoliation. The rising evidence based on pragmatic clinical trials exhibits successful outcomes in terms of clinical performance and acceptability to Hall technique crown. It involves no local anesthesia, no removal of caries, no

preparation of tooth to receive crown (only separation of teeth at the contacts, if necessary) [16]. A randomised trial found that the HT and non-restorative caries treatment (NRCT) have greater acceptability than the conventional restorations (CR) [17]. A retrospective analysis reported that sealing caries using Hall technique significantly outperformed standard restorations over 10 years, both clinically and statistically [18].

However, there is scarcity of literature from India evaluating Hall technique and comparing the same with commonly used restorative alternatives in primary molars based on approaches such as partial excavation and sealing of caries. Therefore, a study was planned with the objective of assessing and comparing the acceptability and clinical success of two different caries excavation techniques and two dissimilar restorations in sealing carious primary molars. The null hypothesis was stated as a no difference statement between the two interventions, the Hall Technique and RMGIC restorations in carious primary molars.

Materials and Methods

The study was a randomized controlled clinical trial set in the Department of Pediatric and Preventive Dentistry in a Dental College located in Navi Mumbai, India. Before initiation, approval from the Institutional Ethics Committee and the hospital/institution authorities was obtained. New patients presenting to the Department of Pediatric and Preventive Dentistry for their first oral health examination were recruited by the investigator to participate if they met the eligibility criteria. Information sheets were given to parents (available in English, Hindi and Marathi languages), along with verbally informing complete details about the study and their rights of participation and withdrawal. Written and verbal consent was obtained from the parents prior to starting the study. All documents were available in three different languages. The study

protocol was written following the CONSORT (Consolidated Standards of Reporting Trials) guidelines (including 25 checklist points) for reporting a randomized trial.

For all the participants, eligible teeth were allocated to one of the two intervention groups to compare different treatment options for sealing carious primary molars. The inclusion criteria were:

- 7–8-year-old children requiring two or more restorations [with caries thresholds (International Caries Detection and Assessment System) ICDAS3-5],
- Clinical and radiographic assessment of the extent and activity of a carious lesion ruling out pulpal involvement (\leq or \geq $\frac{1}{2}$ way through dentin such that 2-3mm of dentinal band was visible in between the carious lesion and pulp).

The exclusion criteria were:

- Children suffering from systemic diseases or requiring endocarditis prophylaxis.
- Local contraindications for the placement of the restorations like malposed/ malformed /non restorable teeth.

A full history and clinical examination including a pre-operative radiograph (of the included teeth) was recorded for each child. Children were divided into two groups (as described in the inclusion criteria), Group A - Hall Technique, Group B - RMGIC restorations. Group B children required routine clinical sessions for restorations. An additional session was required for a few children from Group A in whom separators had to be placed.

Participants were recruited from April 2015 through July 2015. The follow-up period was from April 2015 through August 2016. The study duration for each participant was approximately 12-18 months. A minimum period of fifteen months was chosen considering the academic course duration of the postgraduate program. A single calibrated operator carried out the immediate and

follow-up evaluations at an interval of three months after all the initially needed restorations were completed. A reminder phone call was made for follow-ups.

All carious primary molars with caries thresholds based upon the ICDAS criteria 3-5 were carefully assessed and included. Respective manuals were referred, and training was given by the trained and calibrated supervisor. The operator underwent two weeks of training with children, using the two interventions before starting the study.

Based on simple randomization, each tooth received one of the two interventions. HT was employed as per the protocol by Innes et al described in “The Hall Technique - A Minimal Intervention” [19]. No local anesthesia was used as per standard HT protocol. In this study, Korea Shinhung Kids Crown Stainless Steel Primary Molar Kit was used. The placement of RMGIC restoration was in accordance with the protocol for caries removal by Mount (2009) [3] and the manufacturer’s instructions for the handling of the material. GC Fuji LC 2 Light Cure Gold Label Restorative Glass Ionomer Dental (available in powder liquid form) was used. The method of isolation used for both the restorations included a high vacuum evacuator, cotton rolls and small, plain dri-angle.

The sample size estimation was based on the expected difference (based on the mean failure ratio from the available reference articles) [20], α (Type I error) fixed at 5%, and the power of the study ($1 - \beta$) fixed at 80%. Based on the above estimates, a sample size of 140 teeth (including approximately 10% over recruitment) was deemed sufficient to assess the objectives of study. All the statistical tests will be performed as per the above analysis. The p value < 0.05 was statistically significant.

Each tooth was randomly assigned to either crowns (using HT) or RMGIC restorations with a simple randomization method. Due to the nature of the intervention, complete blinding/ masking

was not possible, participants and the operator could not be blinded. The statistician was however, blinded. The data sheet provided to the statistician included descriptions as: Group A and Group B in place of HT and RMGIC restoration, respectively.

Assessment of the acceptance and clinical parameters was done as follows:

Acceptance Parameters:

- Acceptance to children - A Frankl behavior rating scale [21] was employed to describe the behavior during treatment as Definitely Negative (1), Negative (2), Positive (3), Definitely Positive (4).
- Acceptance to parents - A single question 5-point (0-4) Likert scale was employed to assess the response to treatment of the parent/s.
- Ease of performance for the operator - A self-rated 5-point (0-4) Likert scale was employed for the assessment of operator's comfort with respect to both the groups.
- Time - The average time taken in minutes to perform the procedure, was recorded with respect to both the groups.

Clinical Parameters:

- Immediate post-operative clinical signs and symptoms - This was recorded as a categorical variable, symptoms present if any, such as pain, swelling, gingival bleeding, others (like mild discomfort) or absent (none) for both the groups.
- Related to progress of carious lesion - The major failure criteria were recorded as presence or absence of pain, swelling, sinus and/or pathological mobility at the time of periodic assessment. For the RMGIC group, two additional categories assessed were secondary caries and new carious lesion. In case of a major failure (such as abscess), pulpectomy/extraction was performed.
- Related to dislodged restoration - The minor failure criterion was recorded as

restoration dislodged completely/ dislodged partially/ intact. In such cases, restorations were repaired/ replaced.

Statistical Methods

All findings were recorded using a study tool and the data were compiled using a Microsoft Office Excel (version 2007) spreadsheet. Data were subjected to statistical analysis using Statistical Package for Social Sciences (SPSS v 22.0, IBM). Both descriptive and inferential statistics were used for measurement of variables. Since, the acceptance was coded on an ordinal scale, non-parametric tests like Mann-Whitney U test were used to compare across both the groups. The clinical variables as mentioned above were compared using Chi-square test.

Results

One hundred forty teeth (of 60 children) were recruited for the study and allocated to either of the intervention groups after randomization. Hence, the analysis for intra-operative i.e., acceptance, and immediate post-operative parameters was done for 140 teeth. The outcome measures (clinical success) at the 15-month follow-up are reported for a total of 117 teeth (of 45 children) [as described in the CONSORT FLOW DIAGRAM 'Figure 1'].

Out of the forty-five patients, three patients missed the follow-up at nine month and four patients at twelve-month, whereas eight patients missed the fifteen-month follow-up. Partial Loss to follow-up was reported of fifteen children (included 23 teeth); 12 teeth from Group A and 11 teeth from Group B of 140 teeth.

60 children (140 teeth) were enrolled and randomized such that Hall PMCs were placed in 73 teeth and RMGIC restorations in 67 teeth. The mean age of patient was 7 years 6 months. Fifty-two percent (52%) of the children were females. In 140 teeth, including both primary first and second molars, occlusal or proximal lesions, caries removal was incomplete (partial/ no

removal). In 73 teeth (of Group A) no caries removal followed by Hall PMC's and in 67 teeth (of Group B) partial caries removal followed by RMGIC restorations.

Baseline patient demographics and the distribution of study teeth for both the groups are summarized in 'Table 1'.

The mean treatment time for the Hall PMCs was 6 minutes 29 seconds (SD \pm 1.19), comparatively less than for the RMGIC restorations group, with a mean time of 12 minutes 53 seconds (SD \pm 25.16). The time difference was statistically significant ($p = 0.032$).

In 13 teeth (9%) patients reported of "mild discomfort". Out of which 12 teeth with Hall PMC's and in one tooth with partial caries excavation followed by RMGIC restoration. The remaining 127 study teeth (91%) did not show any immediate post operative symptoms i.e., symptoms were completely absent. The difference was statistically significant (Chi-square test, $p = 0.002$). No pain, swelling or gingival bleeding was reported in either of the groups. The data distribution is shown in 'Figure 2'.

In this study, operator rated the child's response to treatment (Frankl score). Also, the ease of performance (Likert score) in terms of time required, the quality of isolation attained, child's behavior and self-rated comfort in performing the procedure. Here, parents rated both interventions (Likert score) depending on the child's response to treatment, their preference for technique used, the quality (longevity) of restoration and its color. Mann Whitney U test showed a significant difference in the acceptance scores of children, parents, and the operator for HT and RMGIC groups ($p < 0.001$), with higher acceptance for Hall PMCs. The distribution of this data is shown in 'Figure 3', 'Figure 4' and 'Figure 5'.

During the 15-month follow-up, 13% (18 teeth) 'Major' failures were recorded. It included 1% in Group A at 9 months, failure category was abscess ($n = 1$). 12% (17 teeth) in

Group B, at failure times 3 (n = 1), 6 (n = 1), 12 (n = 7) and 15 months (n = 2). The failure categories were secondary caries (n = 2) and new caries (n = 15). A statistically significantly higher risk (Chi-square test, $p = 0.008$) of 'Major' failures was observed in Group B, only at the 12-month follow-up.

We observed six minor failures in Group A (4%) at 3- and 9-month follow-up. These patients reported of mild occasional pain in the Hall PMC tooth. This failure category was discovered in the follow-ups. It was experienced once in the day or after eating some hard food which lasted for few minutes and never recurred. One Hall PMC was dislodged at nine months. No "Minor" failures were observed in Group B in which partial excavation of caries was performed. There was no statistically significant difference in the dislodgment of restoration between the two groups (Chi-square test, $p = 0.298$) 'Table 2' and 'Figure 6' and 'Figure 7' show the analyses of major and minor failures of restorations at follow-ups in the two groups.

We observed that 8 study teeth (7%), of which five teeth from Group A and three teeth from Group B had exfoliated successfully till the 18-month follow-up (see 'Figure 8' for example) In this study, intention to treat analysis was not performed. The usual drop-out reason is children moving out of the study area. Here, prior to randomization, children unavailable during the follow-up period were excluded.

In this study, we reject the null hypothesis that there is no difference in between the two interventions. We accept the alternate hypothesis that the clinical performance of HT was superior to RMGIC restorations in terms of other clinical parameters suggesting lesion progression (pain, swelling, sinus, pathological mobility) and dislodgement of restoration, assessed periodically (significant difference at the 12-month follow-up with respect to lesion progression).

Discussion

Successfully managing caries in the pediatric population has been a persistent problem involving several challenges, comprising of access to care, assessment and diagnosis, behavior management and the choice of definitive treatment until tooth exfoliation [22]. With the changing disease patterns and the advances in the understanding of the dentin remineralization and caries risk, the full cycle of caries process has somewhat been established [23]. Consequently, the biological approach involves minimal/non-invasive intervention to bring about a reversal of the process (active lesion converted to an inactive one) [6, 23]. Most of the evidence related to managing caries in primary molars using newer options has been obtained from clinical trials conducted in the Western countries [24]. In addition, the child's and parents' perspective of restorative care has rarely been considered sufficiently in Indian literature.

The age group of 7-8 years received the two interventions from a single operator. The reasons for selection of this age group were as follows:

- In the younger age groups, pulpal diagnosis becomes challenging due to the underdeveloped mechanism of reparative dentin formation leading insufficient deposition after the local insults. Studies have proved that remaining dentin thickness (RDT) is the most crucial variable that has an impact on the vitality of the dentin-pulp complex [25].
- It is amongst the most accessible population of school children [20].
- By this stage, children show an improved ability to reason; the ability to see other's point of view develops [26].

Only one study has reported the time taken for the procedures that included the time required to explain and complete each procedure. It was reportedly 12 minutes for the HT

procedure [20]. The treatment time for the HT procedure in the present study was 6.29 minutes. The acceptance scoring was done by the operator and parents for this study. In the study by Innes et al (2007) the dentists' judgement was checked for validity against the Venham and State-Trait scores of the children's anxiety. It was reported that the dentists correctly identified most children with high and low anxiety [20].

In some cases, distal surface of the crown was festooned and flattened before fitting due to the partial eruption of first permanent molar, to prevent ectopic eruption. In one case, the clinical crown being large, the PMC had to be modified. If the occlusion was raised by more than 2 mm, festooning, and crimping of the cervical surface of the PMCs was performed. In our study, most of the Hall PMCs had a satisfactory fit. Orthodontic separators were used for sixteen teeth (11%) and proximal disking was performed in seven teeth (5%) out of the 73 teeth with Hall PMCs. It was performed only if participants could not come for the second appointment after 3-4 days. The study by Innes (2007) found no evidence of association between the use of separators and satisfactory Hall PMC fit [20]. In contrast to this, Ludwig et al (2014) recommended a proximal slicing instead of using separators for physiologic movement allowing the clinician to deliver treatment in one appointment without the need for local anesthetic, and with no evident change in overall success [27].

There are studies with supporting evidence on the acceptance parameters favoring the HT, Innes (2007), reported that 77% children, 83% of the carers and 81% of the dentists preferred the no dentinal caries removal over CR followed by SSCs in both the groups [20]. Similar results were obtained by van Bochove and van Amerongen (2006) and Bell (2010), representing the biological approach of caries management to be pain-free, thus reinforces a positive attitude towards dentistry [28,29].

In this study, immediate post operative symptom was 'mild discomfort' in Group A, which lasted for few minutes to few hours. In some children, analgesics were prescribed, if required. However, anecdotal evidence from general dental practitioners was that it was often related to the taste of the excess GI extruded through from the margins of the seated crown. Innes (2007), Luther (2007), V. van der Zee (2010) concluded that significant reduction in bite (equilibration of occlusion) was observed after maximum 30 days of crown placement. Rosenblatt (2008) reported that none of the children or parents reported any signs or symptoms of occlusal dysfunction, or any difficulty with eating or symptoms of temporomandibular joint dysfunction syndrome when they were directly questioned by their dentist at the one-year or at two-year recall [20,30,31].

We observed one major failure for Hall PMC at the nine-month follow-up. The child reported with pain and dentoalveolar abscess, clinical examination revealed that the tooth was vital. Radiographic assessment showed interradicular radiolucency. The crown was removed and pulpectomy was performed followed by the replacement of PMC. The pre-operative radiograph was re-evaluated, and it was noticed that the band of dentin in between the extent of lesion and the pulpal floor was less than 3mm as shown in 'Figure 9'. This might be the reason for the failure of the restoration using HT. In Group B, secondary caries or new caries were recorded (depicted in 'Figure 10'). Restorations/re-restorations were performed for the same.

The 10-year follow-up by Innes (2015) showed that the combined data of Phase 1 and Phase 2, according to which 50% CR (conventional restorations) teeth (48/96) and 91% HT teeth (88/97 including three censored as extracted under general anesthesia (GA) successfully exfoliated over the lifetime of the teeth. Failures were reported in both HT and CR, but HT eminently outperformed the CR with most failures in the first 30 months.¹⁸ This confirms that

there are no long-term adverse events from sealing in the biofilm. Repeat restorations in CR have time and cost-effective implications for children, parents, and the dental team [18]. Similar conclusions have been reported by Ludwig (2014), Yenogopal (2015) and few recent case reports across the globe[9,27]. Overall, these results support the biological approach which seems to be a logical management of caries. Subsequently, a positive attitude was instilled, and anxiety was fairly suppressed [9].

There was no control group of complete excavation so its comparison with the other two techniques could not be assessed. The two interventions being dissimilar, the blinding of the subjects and the operator was not possible in the study. Therefore, only the statistician was blinded. The changes in occlusion as well as the gingival status were not recorded in the present study. Additional radiographs were taken only in case of failed restorations. Dr Suni Plus Dental RVG Intraoral Sensor Size 1 or 2 Digital X-ray Metal Casing was used for radiographs.

There was loss to follow-up at timely intervals. As the study was performed in academic settings wherein the children received free treatments, the cost implications could not be studied. However, this study being the only of its kind in the Indian population, helps establish grounds for further research.

In this study, a convenient sample was drawn from the children visiting the Department of Pediatric and Preventive Dentistry. This sample may not represent the general population in terms of socioeconomic class and the treatment need. Therefore, the findings from the study can only be extrapolated to similar settings.

Conclusion

In our study, at the 12-month follow-up, the HT outperformed RMGIC restorations. Additional failures were seen in Group B: RMGIC restorations at 15-month follow-up, whereas no failures were seen with HT. The result was statistically not significant. HT was preferred to RMGIC restorations by children, parents, and the operator, which was statistically significant. HT also took less time compared to performing the RMGIC restorations.

Our results strongly support conservative caries management approach. We recommend that proper case selection will confer successful outcomes of sealing carious primary molars. The treatment plan must facilitate the use of an evidence-based disease management protocol.

Why this paper is important for pediatric dentists

- HT has proved to be a viable restorative option for carious primary molars resulting in its successful exfoliation. The evidence is that the HT is an effective addition to the clinician's range of treatment option for caries control as a convenient, child-friendly, and less invasive method for the carious primary molars, albeit with a mild post-operative discomfort.
- RMGIC restorations with partial excavation are successful too, but to a lesser extent as compared to HT.

Abbreviations

PMCs - Preformed Metal Crowns

RMGIC – Resin Modified Glass Ionomer Cement

HT – Hall Technique

ICDAS – International Caries Detection and Assessment System

NRCT - Non-Restorative Caries Treatment

RD - Remaining Dentin Thickness

CR - Conventional Restorations

GA - General Anesthesia

COMPETING INTERESTS DISCLAIMER:

Authors have declared that no competing interests exist. The products used for this research are commonly and predominantly use products in our area of research and country. There is absolutely no conflict of interest between the authors and producers of the products because we do not intend to use these products as an avenue for any litigation but for the advancement of knowledge. Also, the research was not funded by the producing company rather it was funded by personal efforts of the authors.

References

1. Petersen PE. The World Oral Health Report 2003: Continuous improvement of the oral health in the 21st century – the approach of the WHO Global Oral Health Programme. Community Dent Oral Epidemiol 2003. 31(Suppl 1): 3-24.
2. Mehta A. Trends in dental caries in Indian children for the past 25 years. Indian J Dent Res. 2018 May-Jun;29(3):323-328.

3. Mount GJ. Minimal intervention dentistry: cavity classification & preparation. *J Minim IntervDent* 2009; 2: 150-62.
4. Frencken et al, de Amorim RG, Leal SC. Survival of atraumatic restorative treatment (ART) sealants and restorations: a meta-analysis. *Clin Oral Investig* 2012 Apr;16(2):429-41.
5. Elderton RJ. Clinical studies concerning re-restoration of teeth. *Adv Dent Res* 1990 Jun; 4:4-9.
6. Kidd EA. Clinical threshold for carious tissue removal. *Dent Clin North Am* 2010 Jul;54(3):541-9.
7. Ricketts D1, Lamont T, Innes NP, Kidd E, Clarkson JE. Operative caries management in adults and children. *Cochrane Database Syst Rev* 2013 Mar 28;3. Update of *Cochrane Database Syst Rev* 2006;(3).
8. Chibinski AC, Reis A, Kreich EM, Tanaka JL, Wambier DS. Evaluation of primary carious dentin after cavity sealing in deep lesions: a 10- to 13-month follow-up. *Pediatr Dent* 2013 May-Jun;35(3).
9. Innes NP, Stewart M. Hall Technique, a Simplified Method for Placing Stainless Steel Crowns on Primary Molars may be as Successful as Traditionally Placed Crowns. *J Evid Based Dent Pract* 2015 Jun; 15(2):70-2.
10. Kidd E. The implications of the new paradigm of dental caries. *J Dent* 2011 Dec;39 Suppl 2: S3-8.
11. Petersen PE, Baez R, Kwan S, Ogawa H. Future use of materials for dental restoration: report of the meeting convened: WHO HQ, Geneva, Switzerland 2009 Nov.

12. Gdos PS, Oliveira LJ1, Romano AR2, Schardosim LR3, Bonow ML2, Pace M3 et al. Longevity of posterior restorations in primary teeth: Results from a pediatric dental clinic. *J Dent* 2014 Oct;42(10):1248-54.
13. Berg JH. The continuum of restorative materials in pediatric dentistry-a review for the clinician. *Pediatr Dent* 1998 Mar-Apr;20(2):93-100.
14. Casagrande L, Dalpian DM, Ardenghi TM, Zanatta FB, Balbinot CE, et al. Randomized clinical trial of adhesive restorations in primary molars. 18-month results. *Am J Dent* 2013 Dec;26(6):351-5.
15. Webman M, Mulki E, Roldan R, Arevalo O, Roberts JF, Garcia-Godoy F. A Retrospective Study of the 3-Year Survival Rate of Resin-Modified Glass-Ionomer Cement Class II Restorations in Primary Molars. *J Clin Pediatr Dent* 2016 Winter; 40(1):8-13.
16. Innes N, Hall N. The Hall Technique for managing carious primary molars. *Dent Update* 2009; 36:472-478.
17. Santamaria RM1, Innes NP, Machiulskiene V, Evans DJ, Alkilzy M, Splieth CH. Acceptability of different caries management methods for primary molars in a RCT. *Int J Pediatr Dent* 2014 Mar 7.
18. Innes NP, Stewart M. The Hall Technique; retrospective case-note follow-up of 5-year RCT. *BDJ* 2015 Oct; 395-400.

19. Nicola Innes and Evans. The Hall Technique- A minimal intervention, child centered approach to managing the carious primary molar: A User's Manual. University of Dundee. 3rd ed; 2010.
20. Innes NP, Evans, Stirrups DR. The Hall Technique; a randomized controlled clinical trial of a novel method of managing carious primary molars in general dental practice: acceptability of the technique and outcomes at 23 months. *BMC Oral Health* 2007, 7:18.
21. McDonald R, Avery D, Dean J. *Dentistry of Child and Adolescent. Nonpharmacologic Management of Children's Behaviour*. 9th ed. Mosby Elsevier; 2011. 27-40.
22. Hariri M, Ramdi H, El Alloussi M, Chhoul H. The Hall Technique: A Nonconventional Method for Managing Carious Primary Molars. *Dentistry* 2016; 6:385.
23. Fejerskov O, Larsen MJ. 2015. Demineralization and remineralisation: the key to understanding clinical manifestations of dental caries. In: Fejerskov O, Nyvad B, Kidd E, editors. *Dental caries: the disease and its clinical management*. 3rd ed. Oxford (UK): Wiley Blackwell; 2015. p.160–169.
24. McDonald and Avery's *Dentistry for the Child and Adolescent*. 2015. 10th Ed; 204-205.
25. Fuks AB, Peretz B. *Paediatric Endodontics: Current Concepts in Pulp Therapy for Primary and Young Permanent Teeth*. Springer; 2016.
26. American Academy of Pediatric Dentistry. *Guideline on Behavior Guidance for the Pediatric Dental Patient*. Reference manual. 2015; 37(6):15/16.

27.Ludwig K, Fontana, Vinson L, Platt J, Dean J. The success of stainless steel crowns placed with the Hall technique. A retrospective study. JADA 2014 Dec; 145(12):1248–1253.

28.Bell SJ, Morgan AG, Marshman Z, Rodd HD. Child and parental acceptance of preformed metal crowns. Eur Arch Pediatric Dent 2010 Oct; 11(5):218-24.

29.van Bochove JA, van Amerongen WE. Influence of restorative treatment approaches and the use of local analgesia, on the children’s discomfort. Eur Arch Pediatric Dent 2006; 7:11-16.

30.Luther F: TMD and occlusion part II. Damned if we don't? Functional occlusal problems: TMD epidemiology in a wider context. Br Dent J 2007; 202(1):E3; discussion 38-E3; discussion 39.

31.Sadowsky C, BeGole EA. Long-term status of temporomandibular joint function and functional occlusion after orthodontic treatment. Am J Orthod 1980; 78(2):201-212.

Table 1. Mean age of children on entry to trial and distribution of study teeth in the two groups: HT and RMGIC.

Distribution	Subjects		
	Boys	Girls	Total
Mean Age	7.66	7.68	7.62

HT	35	38	73
RMGIC	32	35	67
Total	67	73	140
Percent	47.9	52.1	100.0

Table 2. ‘Major’ and ‘Minor’ failure categories and its corresponding time interval for both the groups: HT and RMGIC.

Type of failure	Group	Category	Number of teeth	Follow-up interval
‘Major’	A	Abscess	1	9 months
	B	Secondary caries	2	6-12 months
	B	New caries	15	3, 12, 15 months
‘Minor’	A	Dislodged	1	9 months
	B	None	-	-

Figure 1 The CONSORT Flow Diagram. Enrolment, follow-up, and analysis of the two groups.

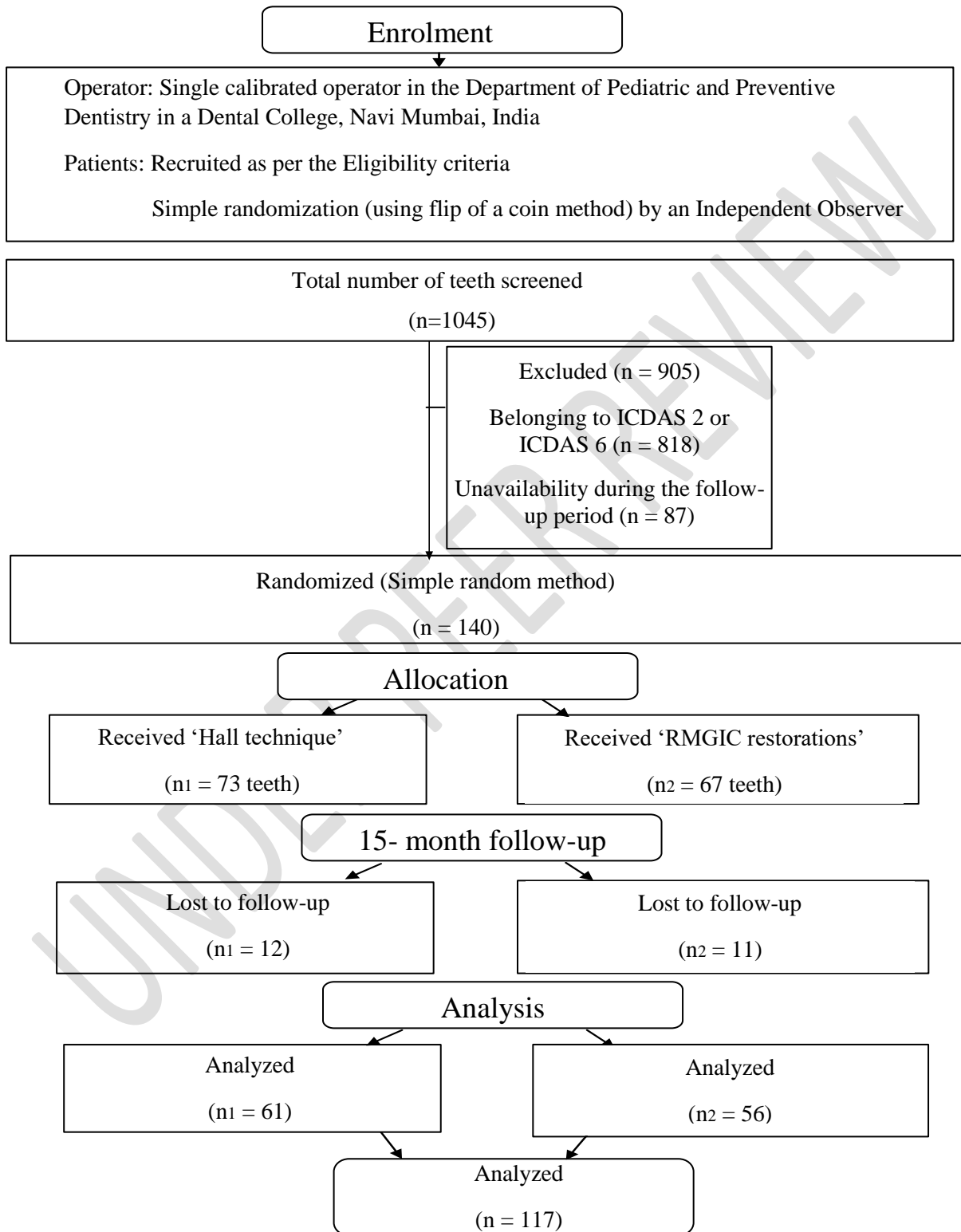


Figure 2 Immediate post-operative symptoms in the two groups: HT and RMGIC.

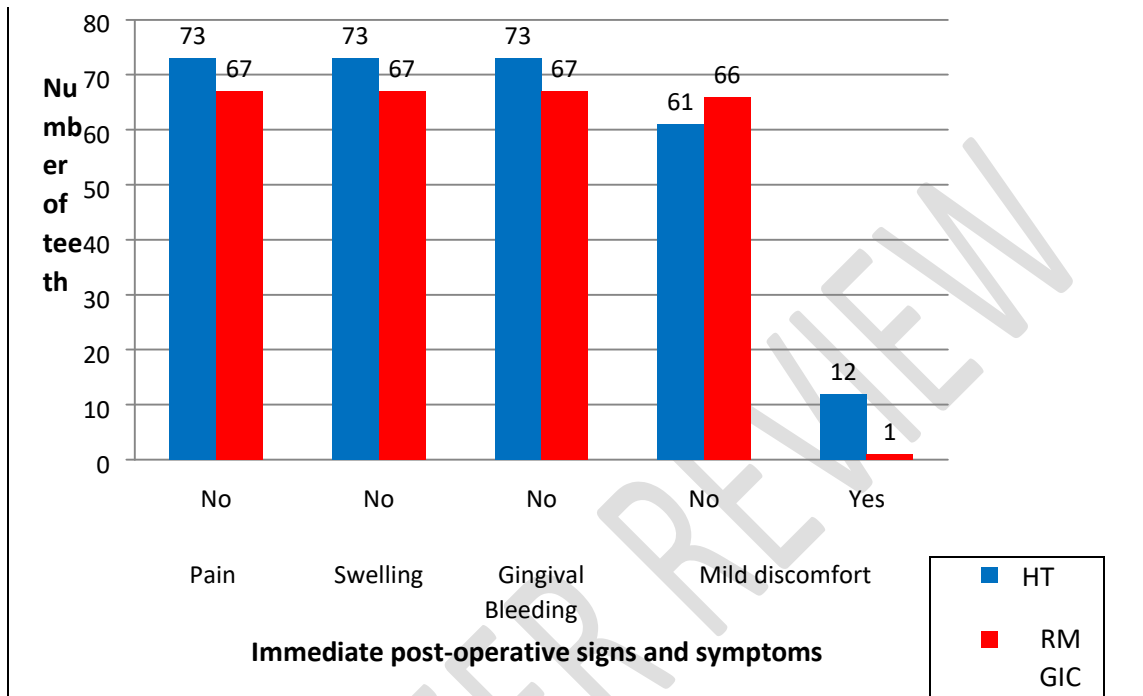


Figure 3 Acceptance scores of Children (Frankl Rating: FR) for the two groups: HT and RMGIC

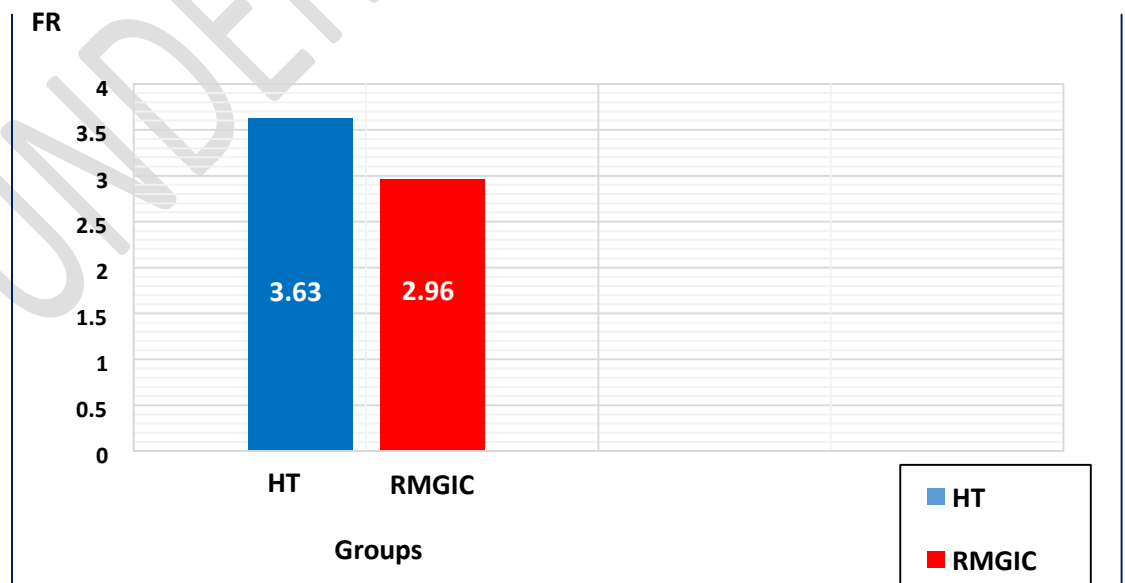


Figure 4 Acceptance scores of Parents (Likert Rating: FR) for the two groups: HT and RMGIC

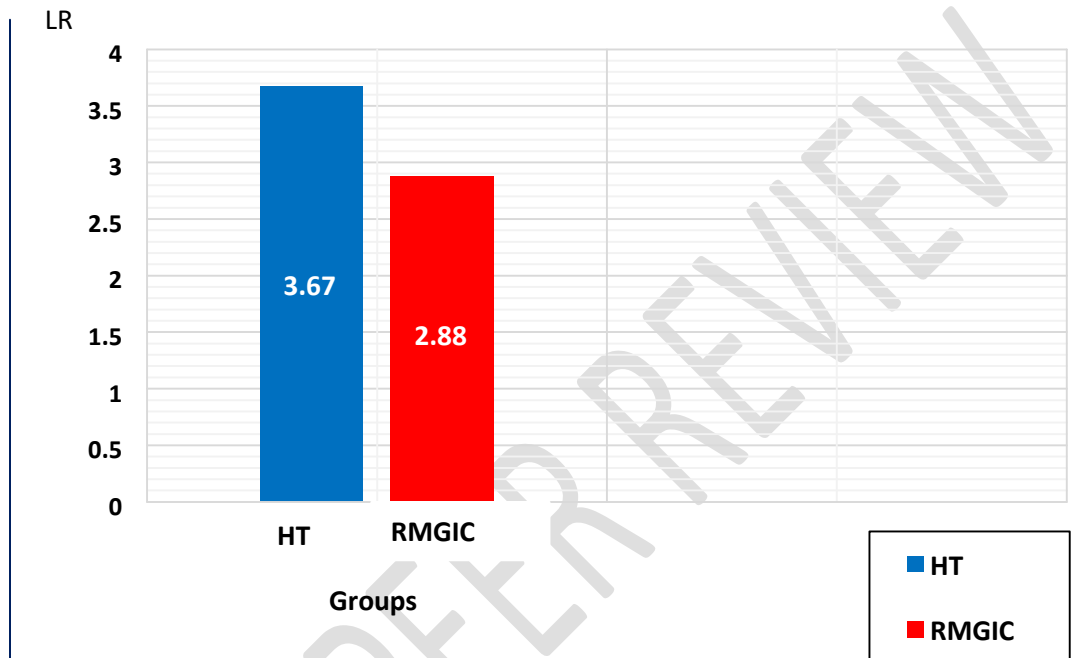


Figure 5 Acceptance scores of the Operator (Likert Rating: FR) for the two groups: HT and RMGIC

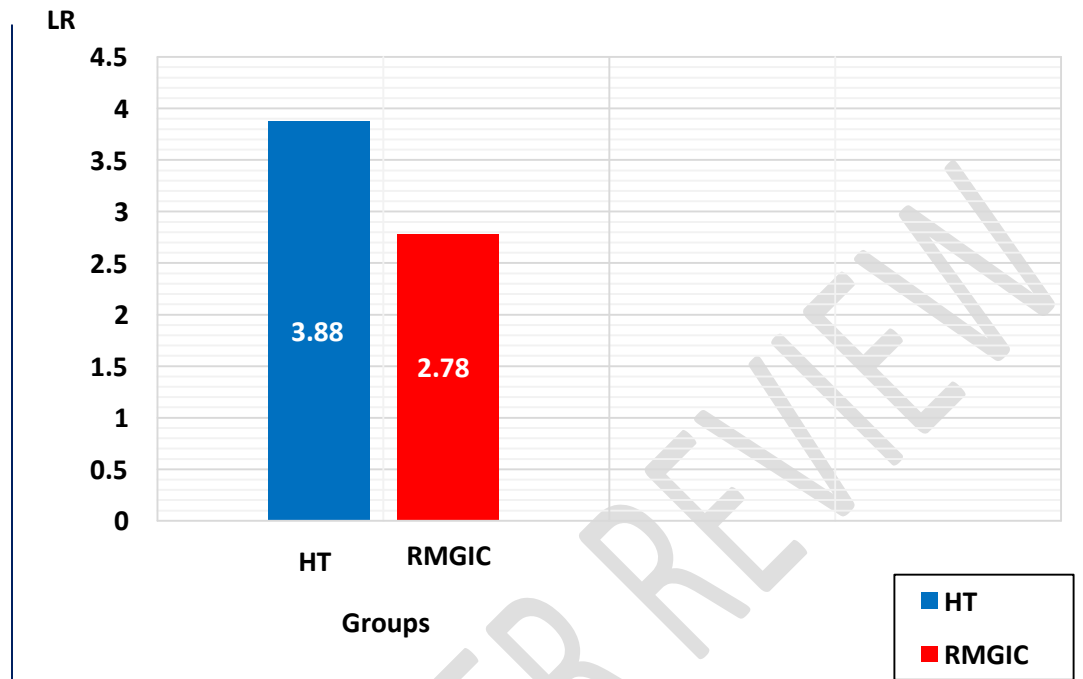


Figure 6 Presence of other signs and symptoms at follow-ups in the two groups: HT and RMGIC.

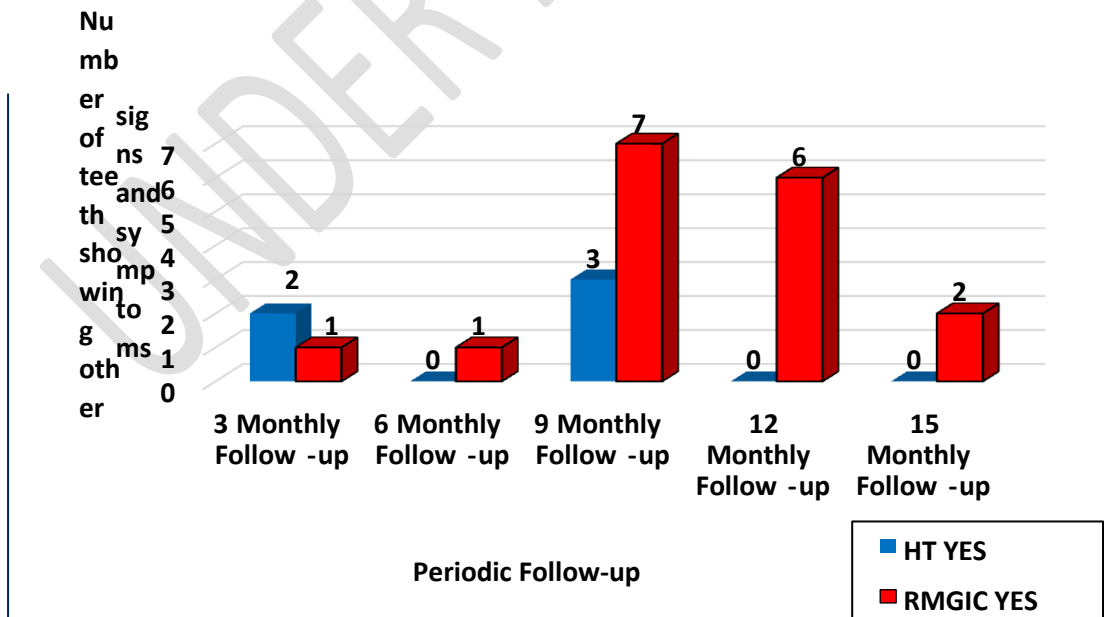


Figure 7 Dislodgement of restoration at follow-ups in the two groups: HT and RMGIC.
Clinical failure only (No. of dislodged teeth Vs Follow-up period).

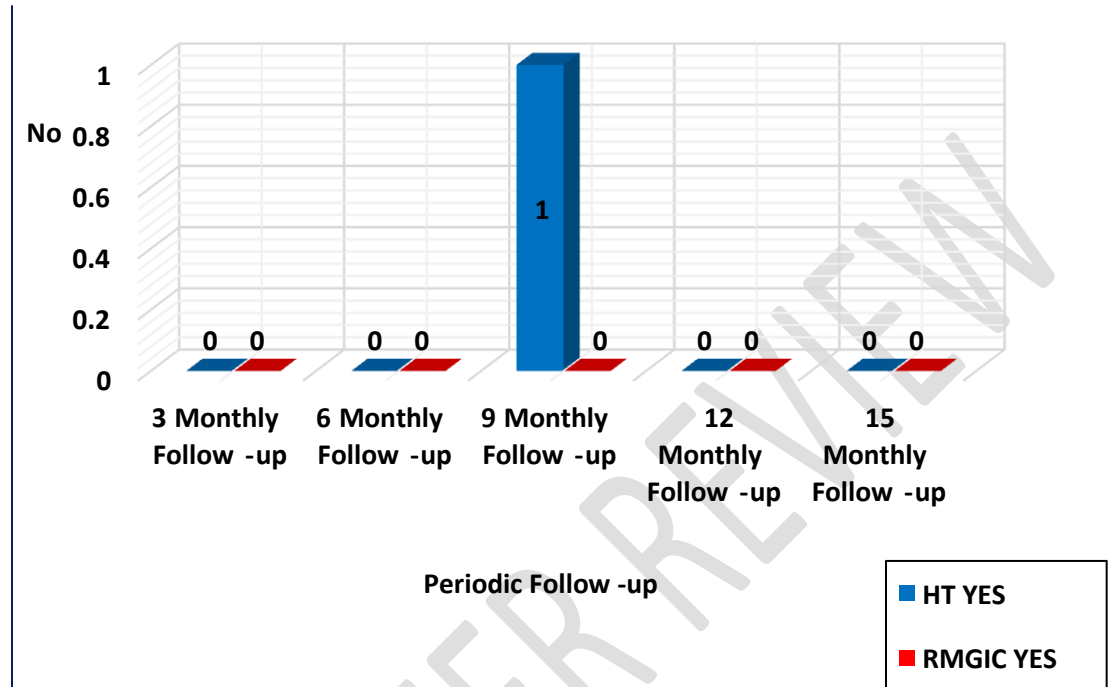
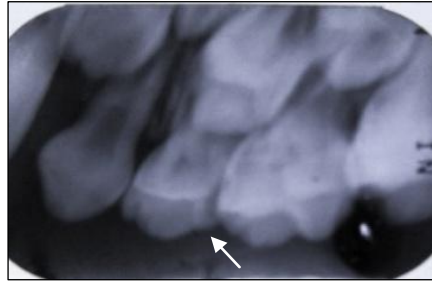
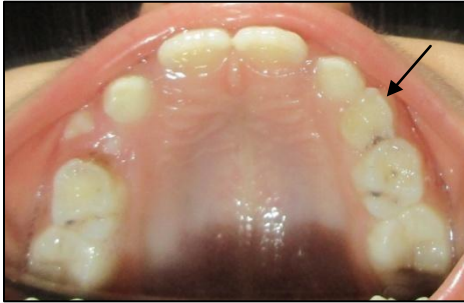

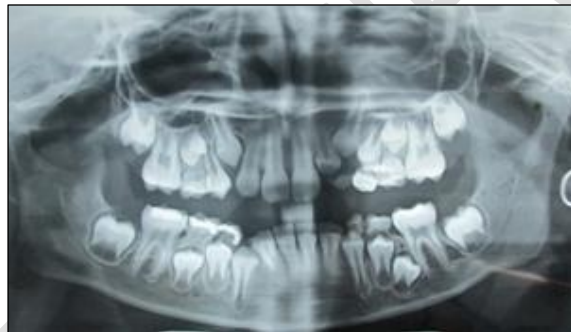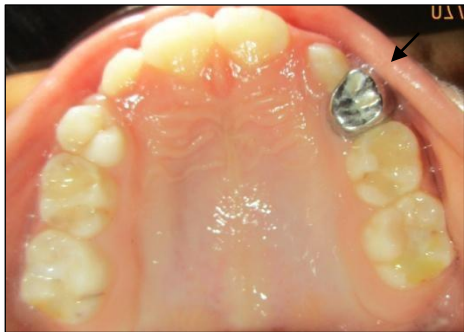FIGURE 8

- a** – Clinical and radiographic photographs of a patient with 55 64 65 showing ICDAS II Code3
- b** – At the 15-month follow-up, intact Hall PMC restoration w.r.t 64 and RMGIC restoration w.r.t 55 65
- c** – At the 18-month follow-up, successful exfoliation of Hall PMC restoration w.r.t 64

PRETREATMENT INTRAORAL PHOTOGRAPHS AND RADIOGRAPHS



AT 15 - MONTH FOLLOW-UP, asymptomatic and intact Hall PMC restoration



AT 18 - MONTH FOLLOW-UP, successful exfoliation of Hall PMC restoration

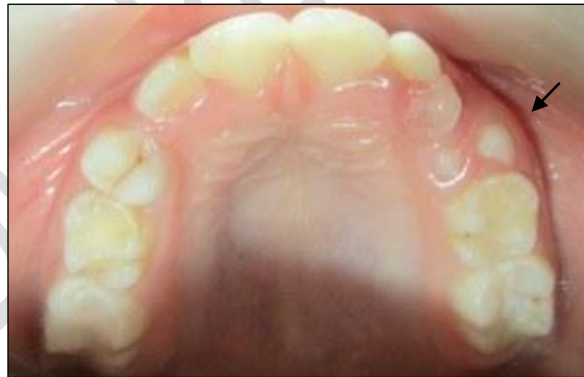
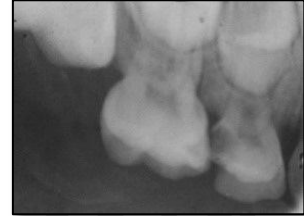
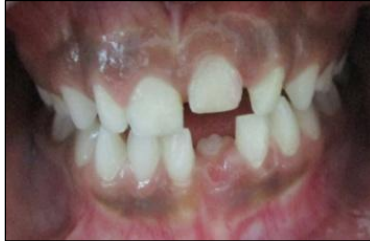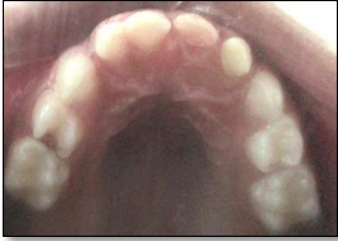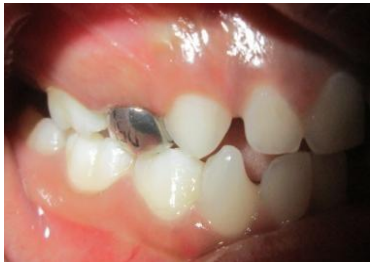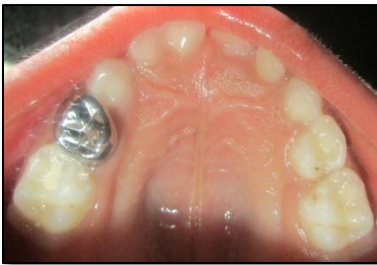Figure 9 Photographs showing ‘Major’ failure with the Hall Technique at the 9-month follow-up

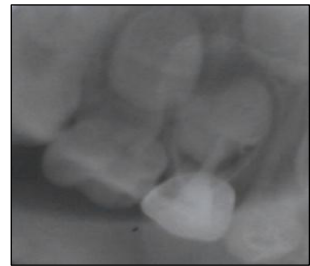
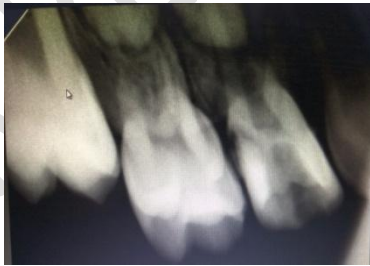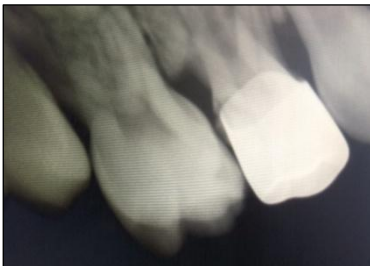PRETREATMENT INTRAORAL PHOTOGRAPHS AND RADIOGRAPHS



POST TREATMENT INTRAORAL PHOTOGRAPHS



RADIOGRAPHS SHOWING MAJOR FAILURE (DENTOALVEOLAR ABSCESS) WITH HT IN RELATION TO 54 FOLLOWED BY ENDODONTIC TREATMENT



15-MONTH FOLLOW-UP INTRAORAL PHOTOGRAPHS AND RADIOGRAPHS

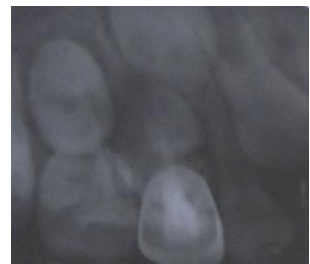
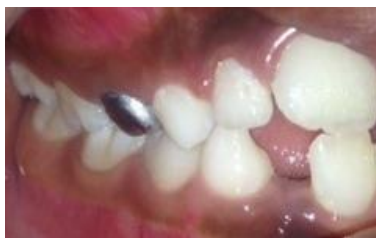
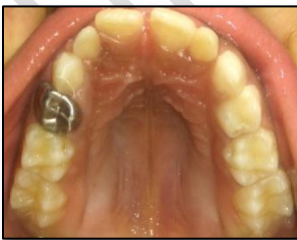Figure 10

a – Clinical photograph of 'Minor' failure of RMGIC restoration in tooth 74; new caries lesion (on the distal surface) at the 9-month follow-up.

b - Clinical photograph of 'Minor' failure of RMGIC restoration in tooth 64; restoration lost and secondary caries (on the distal surface) at the 12-month follow-up.

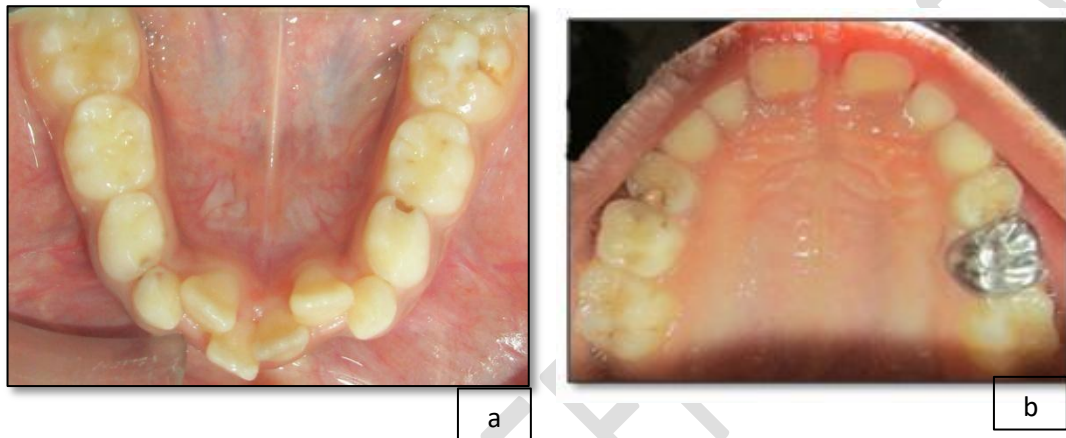


Figure Legend

'Figure 1'	The CONSORT Flow Diagram. Enrolment, follow-up, and analysis of the two groups.
'Figure 2'	Immediate post-operative symptoms in the two groups: HT and RMGIC
'Figure 3'	Acceptance scores of Children for the two groups: HT and RMGIC

<p>‘Figure 4’</p>	<p>Acceptance scores of Parents for the two groups: HT and RMGIC</p>
<p>‘Figure 5’</p>	<p>Acceptance scores of the Operator for the two groups: HT and RMGIC</p>
<p>‘Figure 6’</p>	<p>Presence of other signs and symptoms at follow-ups in the two groups: HT and RMGIC.</p>
<p>‘Figure 7’</p>	<p>Dislodgement of restoration at follow-ups in the two groups: HT and RMGIC. Clinical failure only.</p>
<p>‘Figure 8’</p>	<p>Photographs showing successful exfoliation of Hall PMC restoration at the 15-month follow-up.</p>
<p>‘Figure 9’</p>	<p>Photographs showing “Major” failure with the Hall Technique at the 9-month follow-up.</p>
<p>‘Figure 10’</p>	<p>Clinical photographs of ‘Minor’ failure of RMGIC restorations</p>