

Case study

CYSTITIS GLANDULARIS WITH INTESTINAL METAPLASIA

ABSTRACT

Cystitis glandularis (CG) is an unusual proliferative disorder of the urinary bladder, which is characterized by transitional cells that have undergone glandular metaplasia. Cystitis glandularis has occasionally been proposed as a precursor of adenocarcinoma by various studies. Also, the intestinal subtype of cystitis glandularis has been described as premalignant. Here, we report a case of 37 year old female presenting with hematuria and acute retention of urine with cystoscopy revealing a pedunculated growth arising from the anterior wall of the bladder. Transurethral resection of the bladder tumour was performed and histopathology suggested cystitis glandularis with intestinal metaplasia.

Immunohistochemical study was done using CDX2 and CK20 which showed nuclear and cytoplasmic positivity respectively and hence the diagnosis was confirmed. . Intestinal metaplasia is a risk factor and a putative precursor of adenocarcinoma. Hence the ,proper evaluation of the histological features and immunohistochemical studies of cystitis glandularis, especially intestinal type helps in correct categorization of this lesion.

Due to the increased occurrence of adenocarcinoma in patients with cystitis glandularis, it is recommended to have a close follow up of the patients diagnosed with cystitis glandularis with intestinal metaplasia because it may turn malignant.

INTRODUCTION

A wide spectrum of glandular epithelial metaplastic changes may be seen in the bladder.

In 1761, Morgagni first described cystitis glandularis as a benign proliferative disorder of the bladder for which the pathogenesis was thought to be either congenital due to partial origin of the bladder from embryonal cloaca or due to longstanding irritation causing metaplasia of the urothelium(1).

Cystitis glandularis occurs as a reactive process in response to chronic irritation, infection, calculi, outlet obstruction, catheterization.

Two types of cystitis glandularis have been identified on microscopy - the usual type and intestinal type. Cystitis glandularis of intestinal type is a relatively rare condition and has often been misdiagnosed as bladder tumour (1). With similar clinical features as other bladder tumours, It has an unclear pathogenesis and its role as a precursor of adenocarcinoma has long been debated.

Therefore we report a case of Intestinal type of Cystitis Glandularis in a 37 year old female patient.

CLINICAL DETAILS

37 year old female patient presented with acute retention of urine . She also gave a history of total painless hematuria associated with passing of clots since 2 weeks. Microscopic examination of urine revealed presence of plenty of RBCs/HPF. Patient is a known case of Type 2 Diabetes mellitus on treatment with oral hypoglycaemic drugs. Other lab investigations like CBC and RFT were within normal limits.

Helical CECT study of urinary bladder showed an enhancing soft tissue density lesion arising from antero-lateral wall of urinary bladder measuring 3.0x1.1 cm with associated focal wall thickening and minimal peri-vesical fat stranding.

Cystoscopy was performed which revealed a 2x2cm pedunculated growth on the anterior wall suggestive of inflammatory or neoplastic aetiology. The rest of the mucosa had catheter related cystitis changes. Transurethral resection of the bladder tumour was done.

Informed consent was obtained from the patient for this study.

GROSS AND MICROSCOPIC FEATURES

The specimen was received in 10% buffered neutral formalin. It was allowed to fix for 24 hours. After formalin fixation, macroscopic examination of the specimen was done.

On gross examination there were two grey white irregular, mamillated soft tissue masses larger one measuring 1x1x0.5cm and the other one measuring less than 1cc. Cut section was fleshy. (Figure-1). The specimen was all embedded.

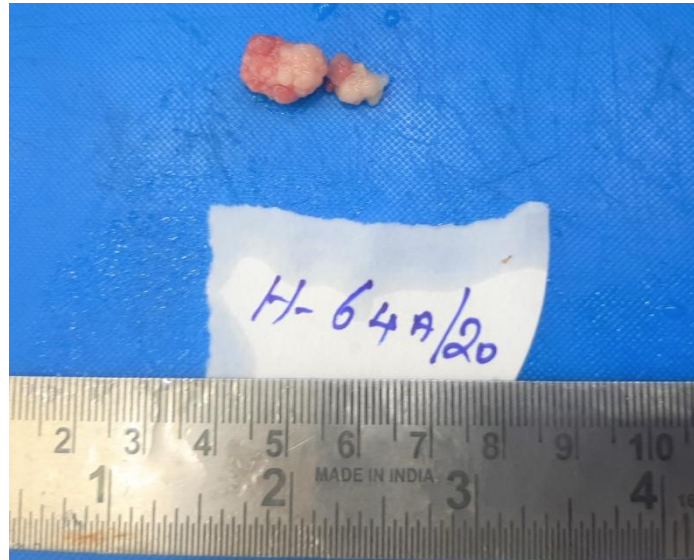


Figure-1: E/S showing two irregular soft tissue masses

Tissue sections were processed for histopathological examination by 14- hour automated processing schedule followed in our laboratory. Sections were embedded in paraffin wax and paraffin blocks were made. Sections was cut from blocks at 4-micron thickness. Primary Hematoxylin & Eosin staining were performed.

After H & E staining, all slides were viewed under 10x, 40x and 100x magnifications using Lawrence & Mayo LM-52-1706 upright light phase contrast microscope.

Microscopy showed a polypoidal lesion covered by by transitional epithelium with underlying lamina propria showing glandular and cystic spaces lined by basal urothelial cells with superficial layer of vacuolated tall columnar cells interspersed with occasional goblet cells. Some of the cystic glands showed central mucin collection. Sub epithelial stroma showed marked oedema with scattered lymphoplasmacytic infiltrate (Figure 2,3).

PAS stain showed positivity in luminal secretions and tall columnar cells (Figure 4 and 5).

A diagnosis of Cystitis glandularis of intestinal type was made on histopathological examination.

Further, formalin-fixed, paraffin-embedded tissue samples were subjected to immunohistochemical analysis with CDX2 and CK20 markers.

Immunohistochemical study done using CDX2 and CK20 showed nuclear and cytoplasmic positivity respectively and hence the diagnosis was confirmed (Figure 6,7).

UNDER PEER REVIEW

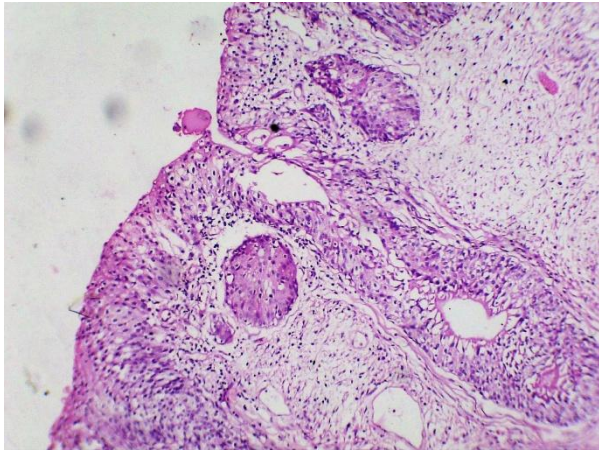


Figure-2: H & E, 4X showing glandular spaces lined by goblet cells in continuity with superficial epithelium

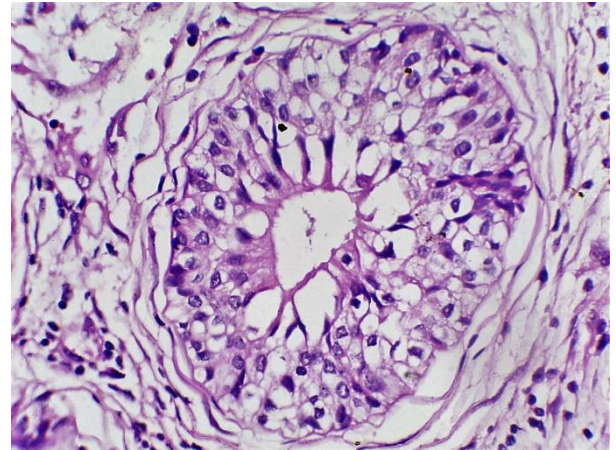


Figure-3: H & E, 10X showing glands lined by basal urothelial cells with inner tall columnar cells with goblet cell metaplasia

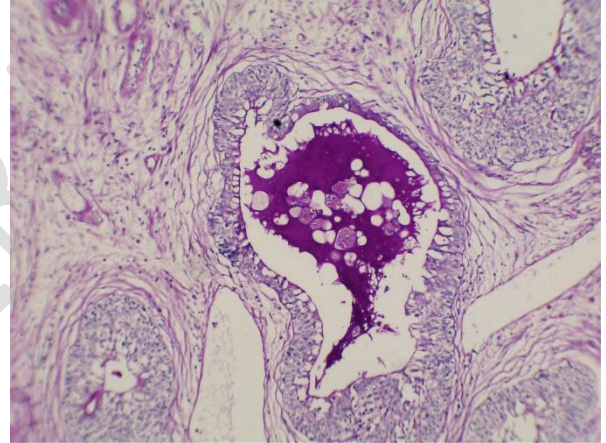
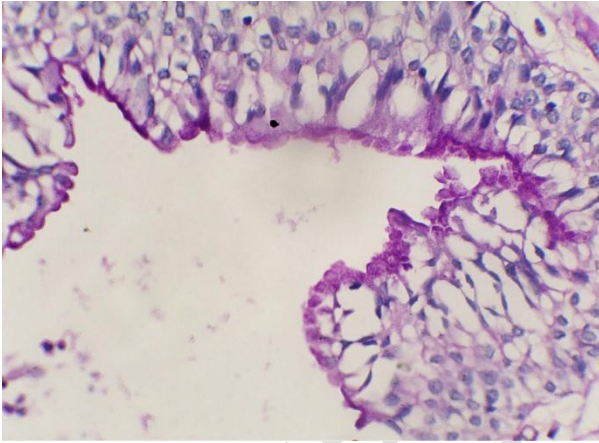


Figure-4 and 5 : H & E, 40X and 10X showing PAS positivity in goblet cells and luminal secretions

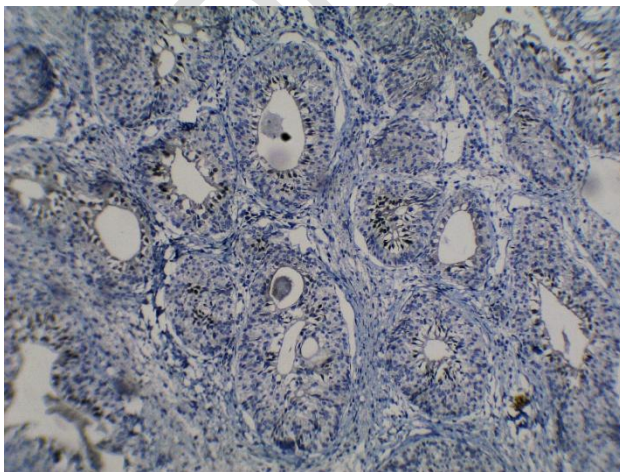


Figure- 6 : 10x showing nuclear positivity for CdX2

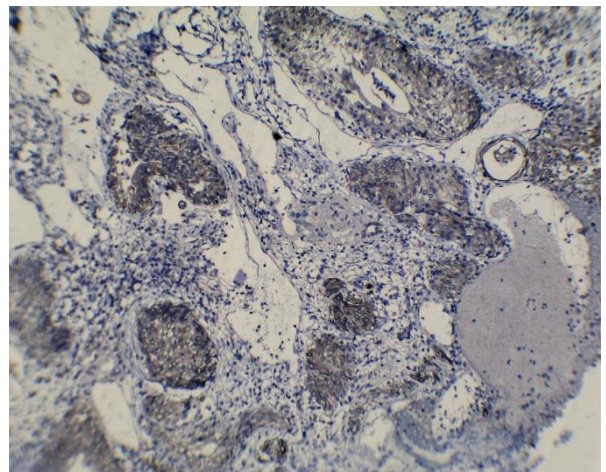


Figure- 7 : 10x showing cytoplasmic positivity for CK20

DISCUSSION

Cystitis glandularis is a [epithelial lesion](#) which shows a male preponderance, with peak incidence in the age of 50 years(1). However, our patient is a female who presented at the age of 37 years.

Even though patients are usually asymptomatic, some may present clinically with dysuria, urgency and frequency which are symptoms arising from bladder irritation and also haematuria or [pelvi-abdominal](#) pain (2). Our patient also presented with haematuria and acute retention of urine.

In a study done by Mohamed A et al (9), it was reported that hematuria and polyuria were the dominant symptoms in patients with cystitis glandularis.

Two subtypes of cystitis glandularis are recognised with distinct morphology(2). The first type i.e. the typical type is characterised by glands lined by inner columnar or cuboidal epithelium with overlying layers of urothelial epithelium. The second type i.e. the intestinal type, also referred to as cystitis glandularis with intestinal metaplasia is characterised by glands lined with mucinous columnar epithelium with basally located nuclei and frequent goblet cells (2). Cystitis glandularis of intestinal type appears to be much less common than the typical type (2).

In the urinary bladder, intestinal type of cystitis glandularis has been proposed to be a precursor lesion of adenocarcinoma(3).Also, florid cystitis glandularis of intestinal type may sometimes resemble adenocarcinoma. (3)

Clinically and radiologically, it is difficult to differentiate cystitis glandularis from other tumourous conditions, especially when they manifest as a mass like lesion which mimics a neoplasm(2,4) such as in our case.

Hence, evaluation of the histological features and correct categorization of such lesions is necessary to differentiate it from adenocarcinoma of the bladder (4).

The main differential diagnosis is low grade adenocarcinoma of the urinary bladder. Intestinal type of cystitis glandularis especially when extensive may present as exophytic masses and mimic well differentiated adenocarcinoma (4). Another differential diagnosis is endocervicosis of urinary bladder which is a benign glandular lesion seen in urinary bladder of women in reproductive age group (4). Haphazard proliferation of irregularly shaped endocervical type mucinous glands is seen in the bladder wall in endocervicosis.

Intestinal metaplasia is characterized by reactivity for CDX2 and CK20, a reflection of the regulatory role of CDX2 in intestinal differentiation and the frequent expression of CK20 by intestinal-type tissue. Cystitis glandularis with intestinal metaplasia shows nuclear staining for CDX2, but is not characteristic of typical cystitis glandularis. Absence of CK7 and expression of CK20 typifies most cases of intestinal metaplasia.

CDX2 has a critical role in regulating intestinal metaplasia in cystitis glandularis. It is a homeobox gene that encodes an intestine-specific transcription factor, expressed in the nuclei

of epithelial cells throughout the intestine(5). CDX2, a master regulator of intestinal phenotype, was shown to play a tumor-suppressive role in colon cancer. However, it was reported to be expressed in nearly all gastric intestinal metaplasia. (6)

In a study done by Lin ME et al (8), it was found that higher mRNA levels of CDX2 were detected in intestinal cystitis glandularis compared to normal bladder and typical cystitis glandularis, thereby helping to differentiate between the three entities (8).

Expression of CK20 is present in majority of cases of cystitis glandularis with intestinal metaplasia. CK20 is one of the cytoskeletal-associated intermediate filaments and its immunohistochemical expression has been reported in gastrointestinal epithelium, as well as in superficial urothelium, and to a lesser extent, intermediate urothelium. It is also regarded as a useful marker in the diagnosis of metastatic urothelial carcinomas (7).

A study done by Sung et al showed that CK20 was expressed in 80 percent of cases of intestinal metaplasia while CK20 was expressed in only 4 percent of cases of typical cystitis glandularis showing that they have distinctly different immunoprofiles which help in making the distinction between the two entities.

In our case, immunohistochemical study was done using CDX2 and CK20 which showed nuclear and cytoplasmic positivity respectively and hence the diagnosis of cystitis glandularis with intestinal metaplasia was confirmed.

A study done by Morton et al (10) using quantitative fluorescent in situ hybridization (FISH) to measure telomere length found that intestinal metaplasia in the urinary bladder is associated with significant telomere shortening when compared to telomere length in adjacent normal urothelial cells. They found that these lesions with intestinal metaplasia also occasionally showed cytogenetic abnormalities associated with telomere shortening. Their findings support the hypothesis that intestinal metaplasia is a precursor lesion to and could be a marker in the development of adenocarcinoma of the urinary bladder.(10)

Transurethral resection of the mass is the treatment of choice in cystitis glandularis however, the disease has a tendency to recur (2).

CONCLUSION

Cystitis Glandularis of intestinal type is a very rare proliferative disorder of the urinary bladder which can mimic a neoplasm. It appears to represent a different part of the metaplastic spectrum, with morphologic and immunohistochemical characteristics that are markedly different from those of typical cystitis glandularis.

Florid cystitis glandularis of intestinal type may at times resemble adenocarcinoma. Intestinal metaplasia is a risk factor and a putative precursor of adenocarcinoma. Hence the proper evaluation of the histological features and immunohistochemical studies of cystitis glandularis, especially intestinal type helps in correct categorization of this lesion.

Due to the increased occurrence of adenocarcinoma in patients with cystitis glandularis, it is recommended to have a close follow up of the patients [with](#) cystitis glandularis because it may [turn malignant](#).

REFERENCES:

1. Sukriti, Loungani L, Roplekar PM, Mukharji S. Intestinal Type of cystitis glandularis mimicking bladder tumor- case report and review of literature. Trop J Path Micro 2017;3(1):09-12.doi: 10.17511/jopm.2017.i1.02.
2. Song YS, Jang KS, Jang SH, Min KW, Na W, Song SY, Moon HS, Lee TY, Paik SS. The Intestinal Type of Florid Cystitis Glandularis Mimics Bladder Tumor. The Korean Journal of Pathology. 2007;41:116-8.
3. Sung MT, Lopez-Beltran A, Eble JN, MacLennan GT, Tan PH, Montironi R, Jones TD, Ulbright TM, Blair JE, Cheng L. Divergent pathway of intestinal metaplasia and cystitis glandularis of the urinary bladder. Modern pathology. 2006 Nov;19(11):1395-401.
4. Rau AR, Kini H, Pai RR. Morphological evaluation of cystitis glandularis. Indian Journal of Pathology and Microbiology. 2009 Apr 1;52(2):203.
5. - Werling RW, Yaziji H, Bacchi CE, Gown AM. CDX2, a highly sensitive and specific marker of adenocarcinomas of intestinal origin: an immunohistochemical survey of 476 primary and metastatic carcinomas. The American journal of surgical pathology. 2003 Mar 1;27(3):303-10.
6. Liu Q, Teh M, Ito K, Shah N, Ito Y, Yeoh KG. CDX2 expression is progressively decreased in human gastric intestinal metaplasia, dysplasia and cancer. Modern Pathology. 2007 Dec;20(12):1286-97.
7. Akhtar M, Rashid S, Gashir MB, Taha NM, Al Bozom I. CK20 and CK5/6 Immunohistochemical Staining of Urothelial Neoplasms: A Perspective. Advances in Urology. 2020 Nov 4;2020.

8. Lin ME, Huang D, Deng BH, Lv YS, Rong L, Yao YS. Expression and functional role of Cdx2 in intestinal metaplasia of cystitis glandularis. *The Journal of urology*. 2013 Sep;190(3):1083-9.
9. Mohamed A, Nfifakh A, Rahmani M. The Cystitis Glandularis: Report of 4 Cases.
10. Morton MJ, Zhang S, Lopez-Beltran A, MacLennan GT, Eble JN, Montironi R, Sung MT, Tan PH, Zheng S, Zhou H, Cheng L. Telomere shortening and chromosomal abnormalities in intestinal metaplasia of the urinary bladder. *Clinical cancer research*. 2007 Oct 15;13(20):6232-6.
11. Newbould M, McWilliam LJ. A study of vesical adenocarcinoma, intestinal metaplasia and related lesions using mucin histochemistry. *Histopathology*. 1990 Sep;17(3):225-30.

UNDER PEER REVIEW