

Original Research Article

THE SIGNIFICANCE OF NIGELLA SATIVA ON HISTOMORPHOLOGICAL VARIATIONS OF SEMINIFEROUS TUBULES IN DOXORUBICIN TREATED ALBINO RATS

ABSTRACT

Objective: To analyze the impact of *nigella sativa* on Histomorphological changes in doxorubicin treated albino rats.

Research design: experimental research.

Abode of study: Anatomy Department, BMSI, Karachi, Pakistan

Materials and Methods: Piloted on 40 albino rats for 35 days in the Anatomy Department of BMSI. They were 3-4 months old and about 221 to 238 gm in weight. Rats were separated into 4 groups, Ao, Bo, Co & Do. Ao represented as control, Bo received Doxorubicin (DOX) 0.003g/1000g/ at 7TH day intraperitoneally, Co received *Nigella sativa* 1000mg/1000g everyday oral along with Doxorubicin 0.003g/1000g/ at 7TH day intraperitoneally and Do received *Nigella sativa* 1000mg/kg everyday oral. At the end of experiment, rats were dissected and conserved slides for staining.

Results: Bo showed loss of normal architecture of seminiferous tubules and diverse level of atrophy while condition was improved in Co which were given Doxorubicin with extract of *Nigella sativa*.

Conclusion: our results tells us that *Nigella sativa* amended the histomorphological changes.

Key words: NG (*Nigella sativa*), malondialdehyde (MDA), histomorphological, ROS (reactive oxygen species), plasmalemma.

PERIOD OF RESEARCH WORK:

The duration of research was one month and 7 days.

INTRODUCTION

In spite of injurious effects of doxorubicin on somatic and gonadal cells, it is commonly used as an anticancer drug in previous years.¹ It decreases testicular size, sperm count & raise the luminal diameter of seminiferous tubules by reducing spermatogonia, spermatocytes and Sertoli cell count due to oxidative stress activity.² This shows that it causes male infertility but improves the lifespan of young cancer patients.³

Doxorubicin is an antimicrobial drug which belongs to anthracycline group and found in fungus *Streptomyces peucetius* and act as a chemotherapeutic agent against numerous malignant tumors. It speed up cell cycles in bone marrow, gonads and lymphoid tissues by oxidative stress causing production of ROS, lipid peroxidation and cell death.⁴ Testis is commonly impaired due to its proliferative ability, thus causing oligozoospermia, azoospermia and permanent infertility in patients of prepubertal age.⁵ It inhibits DNA replication by inhibition of topoisomerase II enzyme and by separating histones from chromatin network.^{6,7} Topoisomerase II alters the stereochemical organization of the DNA helix by negative supercoiling of DNA. It is cardiotoxic, hepatotoxic, nephrotoxic as well as it causes testicular toxicity due to raised proinflammatory cytokines levels, oxidative stress causing protein oxidation & lipid peroxidation in plasmalemma. Although reactive oxygen species (ROS) are necessary for sperm maturation & capacitation, fertilization

but raised levels of ROS reduces sperm motility and sperm apoptosis.^{8,9} It causes genotoxicity by cellular apoptosis and DNA fragmentation due to its high affinity towards chromosomal DNA.¹⁰ It causes Interruption in spermatogenesis, decreases testosterone level as well as interrupt the antioxidant activity.¹¹

Nigella sativa also known as Shouneez in Iran is associated with Ranunculaceae group cultivated in South of Mediterranean, Eastern Europe, Western Asia and Middle East, having antioxidant, diuretic, antipyretic, antimicrobial, antidiabetic & digestive properties. It also improves sperm count in cauda epididymis and testicular ducts, viability and motility.¹² Spermatogenesis increases at the primary and secondary spermatocyte and decreases abnormalities of sperm whereas reduces the serum level of MDA and raises glutathione and catalase actions.¹³ It is used to treat numerous health problems because it contains thymoquinone, flavonoids, anthocyanins, alkaloids, and essential fatty acid thus it helps in wound healing.¹⁴ It is potent against malignancy, immunological ailments, inflammation and osteoporosis and act as antimicrobial, anti-schistosomiasis, spasmolytic, immunomodulatory and bronchodilator and antiallergic agent. It increases the spermatogenesis activity both morphologically and functionally. Thymoquinone, present in *Nigella Sativa* improves male fertility through its antioxidant defense mechanism.¹⁵ It is present in Tibb-e- Nabvi, Unani Tibb, and Indian traditional medicine and used as an antihypertensive, liver tonic, spice and carminative.¹⁶ It can augment the spermatozoal development, improve the testicular diameter as well as enhanced semen physical features and reduced the free radicals in seminal plasma.¹⁷ *Nigella sativa* protects testis against oxidative stress due to Thymoquinone and tocopherols present in it which inhibits lipid peroxidation and improves spermatogenesis at primary and secondary spermatocyte level.¹⁸ It also raise the serum

testosterone level, seminal quality, sperm count, percentage fertility, decreased sperm abnormalities and improve accessory sexual glands activity through its antioxidative properties.^{19,20} It promotes the human wellbeing beside common ailments like hyperglycemia and hypercholesterolemia and interrupts the oxidative process of lipids.²¹ *Nigella sativa* acts as gastroprotective, nephroprotective, & genoprotective due to Thymoquinone and tocopherols constituent present in it.²²

The research was therefore piloted to estimate the positive effects of *Nigella sativa* on histomorphometric changes of doxorubicin induced testes with emphasis on sperm production index and compare the outcomes with previous researches.

Material and Methods

This experiment was conducted on forty young adult albino rats, 3-4 months old & 221-238gm weight, in department of Anatomy, in BMSI, Karachi for 35 days. 7 days prior to study rats were kept underneath observation to assess their well-being and kept on standard laboratory diet.

Rats were divided into four groups, comprises of ten animals per group.

Ao = Control.

Bo= Doxorubicin (DOX) 0.003g/1000g/at 7TH day intraperitonealy.²³

Co= *Nigella sativa* 1000mg/kg everyday oral along with Doxorubicin 0.003g/1000g/at 7TH day intraperitonealy.²⁴

Do= *Nigella sativa* 1000mg/kg everyday oral. (purchased from bazaar of Karachi and re-identified from Karachi university).

Nigella Sativa seeds cleaned, crushed and powder stored in cool place. Injection Doxorubicin (Pfizer Pak) 50mg/25ml was used.

Rats were daily observed for their wellbeing. After completion of research rats were dissected by midline incision. Bouin's fluid used as fixative for testis & fixation done for 24 hours, then sliced vertically into two equal halves on next day. For dehydration done through alcohol (70 to 100 %) and cleared by xylene. Infiltration and embedding done in Paraffin wax & sections were obtained by rotatory microtome and mounted on glass slides. Sections were stained by periodic Acid Schiff & H&E stain to see morphological and micrometric changes.

GROUP A₀

MORPHOLOGICAL OBSERVATIONS

Rats were in good physical condition & spontaneously react to external stimuli. Both testes were oval in shape, pink colored and soft in consistency.

MICROSCOPIC OBSERVATIONS

4µm thick testicular sections of left testis stained with H&E revealed that testicular parenchyma was composed of circular or oval seminiferous tubules. (Fig-1a) PAS stain revealed that every seminiferous tubules was lined by stratified columnar epithelium having spermatogenic and sertoli cells. (Fig-1b) (Fig-5) Spermatogonia were resting on basement membrane and primary spermatocytes were located in between spermatogonia. Then secondary spermatocytes were located and superior to them spermatids were present. Vacuolization and detached basement

membrane were absent. (Fig-5) Between tubules interstitial spaces were present containing Leydig cells & blood vessels. Leydig cells are polygonal cells having spherical nucleus. (Fig-1c)

GROUP B₀

MORPHOLOGICAL OBSERVATIONS

Rats of this group develop alopecia & looked lethargic & testis became reddish in color.

MICROSCOPIC OBSERVATIONS

H&E stained tissues showed loss of architecture of seminiferous tubules and diverse level of atrophy seen. Some of them were irregularly arranged and some were distorted in shape. PAS stained slides show basement membrane was detached in many parts of various seminiferous tubules and became thin in various sections. (Fig-6a&b) Lumen of seminiferous tubules was full of slough and cellular debris whereas no visible spermatozoa seen. (fig2a) Germinal epithelium was destroyed. There was depletion of germ cell and Sertoli cell in various tubules and in many seminiferous tubules there was loss of germ cell line, marked vacuolization seen in many parts of this epithelium. Multinucleated formation of round spermatids was seen in many places. Sertoli cell was not visible clearly in some places multinucleated formation and pyknotic nucleus in place of Sertoli cell. (fig2b) Marked vacuolization & wide interstitial spaces observed (fig2c)

GROUP C₀

MORPHOLOGICAL OBSERVATIONS

Rats were fit, active and spontaneously responding to stimuli. Testicular tissue remains pink in color with blood vessels on surface.

MICROSCOPIC OBSERVATIONS

H&E stained tissues showed most of seminiferous tubules were round & regularly arranged with their normal architecture some vacuoles present in few tubules. PAS stain revealed intact basement membrane in almost every tubule. (Fig-7) Lumen of seminiferous tubules showed spermatozoa without slough and cellular debris. (Fig-3a&b)

GROUP D₀

MORPHOLOGICAL OBSERVATIONS

Rats were fit and in best of their health. Testicular tissue were soft & pink in color with blood vessels on surface.

MICROSCOPIC OBSERVATIONS

H&E stained sections revealed that each seminiferous tubules was bounded by basal lamina lined by stratified germinal epithelium. Sertoli cells interposed between spermatogenic cell layers were long, extending from basal membrane to the lumen of seminiferous tubules with triangular or ovoid nucleus. (Fig-4) spermatogenic cells present in the sections of this group showed energetic germ cell with enhanced mitotic activity than control. Interstitial spaces were composed of polygonal Leydig cells with spherical nucleus. Marked recovery in germ cell lining of seminiferous tubules sertoli cell Interposed between developing spermatogonia cell with triangular or ovoid nucleus, no pyknotic nuclei and no any multinucleated formation but here also some vacuolization observed. (fig-4)

fig-1a: Photomicrograph of an adult rat testis of control group showing seminiferous tubules (S), germinal epithelium(GE)basement membrane (BM)cut in various planes of section completely bound by basal membrane and lined by germinal epithelium (H&E 10x).

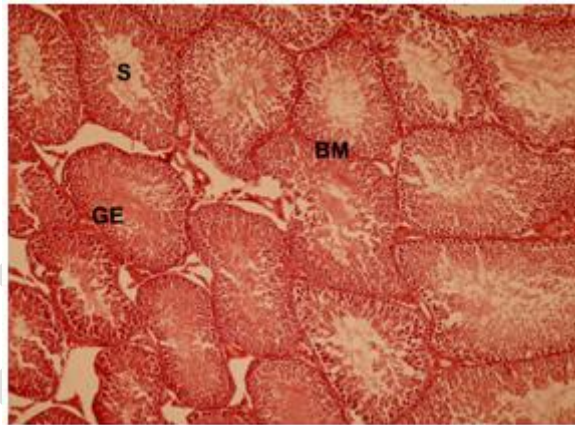


Fig-1b: Photomicrograph control group showing seminiferous tubules (S) with intact basement membrane and lined by epithelium containing leydig cell (L.C) in interstitial spaces (IS) H&E 40x)

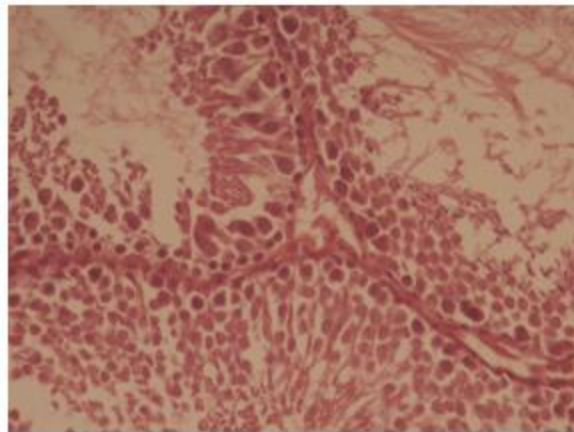


fig1c: Photomicrograph of control group showing seminiferous tubules (S), showing spermatogonia (S.G) primary spermatocytes (P.S) secondary spermatocytes (S.S) and spermatids (S.T) H&E 100x)

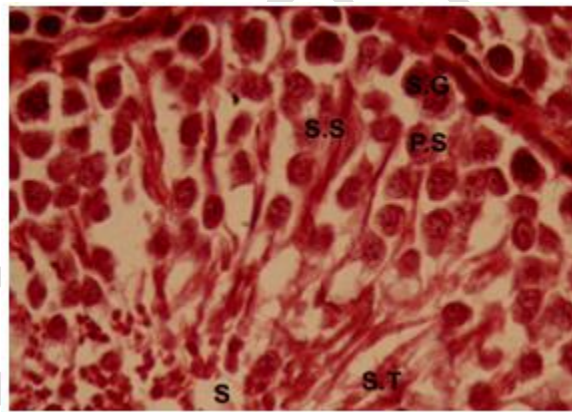


fig2a: Photomicrograph of an adult rat testis, treated with Doxorubicin showing seminiferous tubules (S), cut in various planes of section nearly devoid of Germinal Epithelium (GE) with vacuolation (V) and ruptured blood vessels (BV) in the interstitial spaces (IS) (H&E 4x).

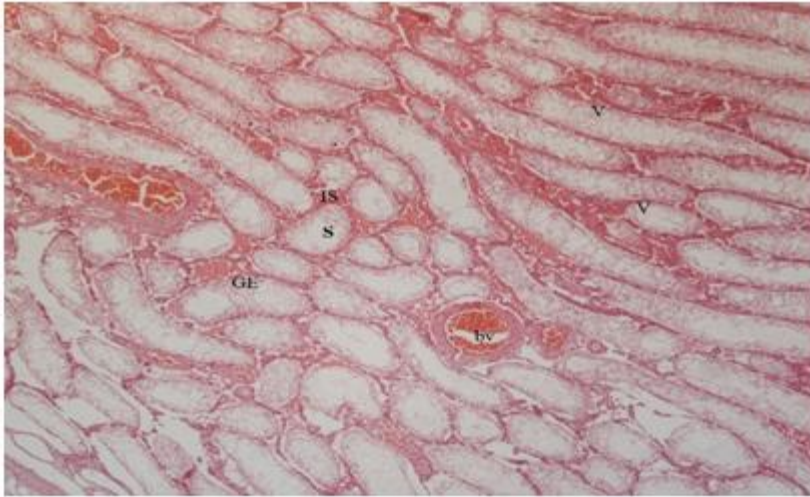

fig2b: Photomicrograph of an adult rat testis, treated with Doxorubicin showing seminiferous tubules nearly devoid of Germinal Epithelium (GE), wide interstitial spaces

(IS), with scanty leydig cell, ruptured blood vessel (b.v) and vacuolation in GE and IS (H&E 10x).

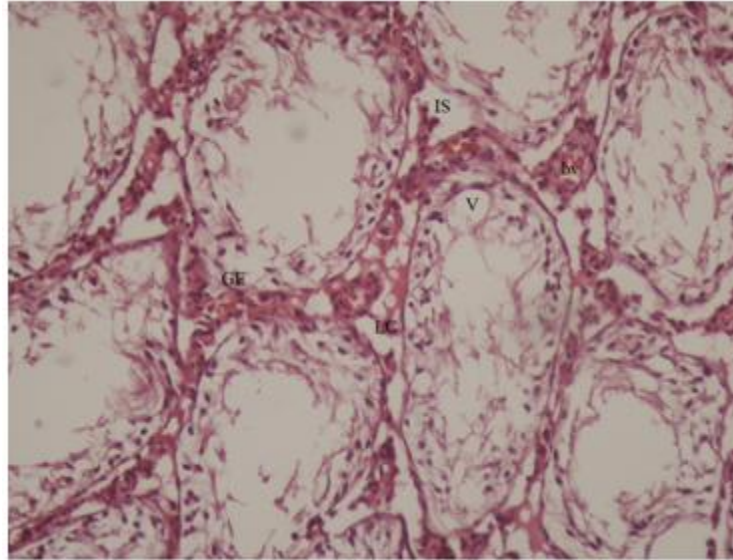


fig2c: Photomicrograph of an adult rat testis, treated with Doxorubicin showing, showing many multinucleate giant cell in one seminiferous tubules 17105132(H&E 100x)

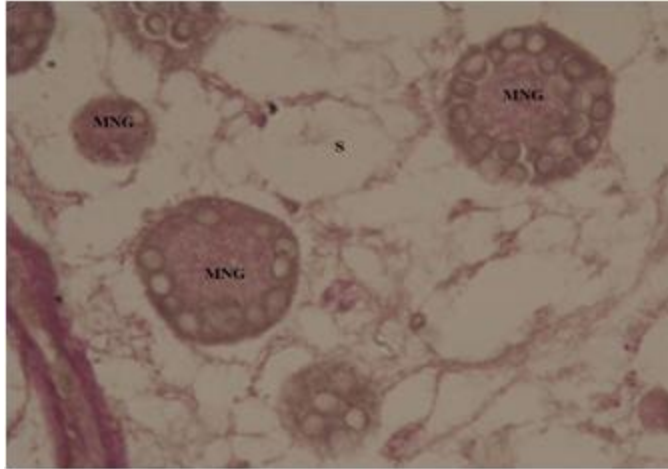


fig3a: Photomicrograph of an adult rat testis, treated with Doxorubicin and Nigella sativa showing seminiferous tubules (S), cut in various planes of section showing nearly normal cytoarchitecture of seminiferous tubules (S) and blood vessels in interstitial spaces (IS) H&E 4x).

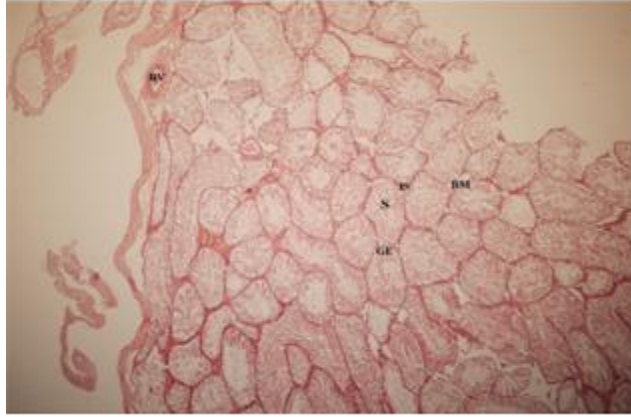


fig3b: Photomicrograph of an adult rat testis, treated with Doxorubicin and *Nigella sativa* showing marked recovery of germinal epithelium (G.E) in parts of four seminiferous tubules (S), with Leydig cell (L.C) in contacted triangular interstitial spaces (IS) H&E 40x)

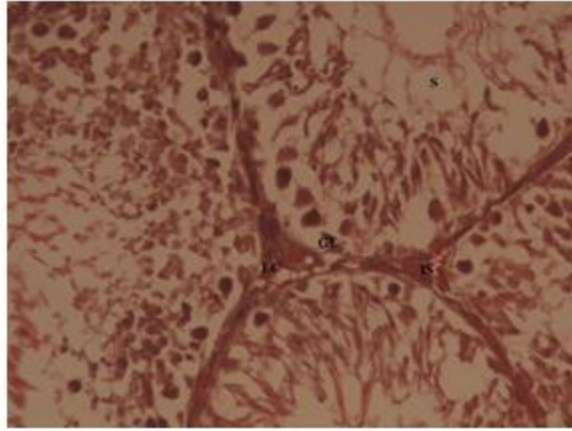


fig4:Photomicrograph of an adult rat testis, treated with *Nigella sativa*, showing seminiferous tubules (S) with enhanced mitotic activity in germinal epithelium (GE) than control (H&E 40x)

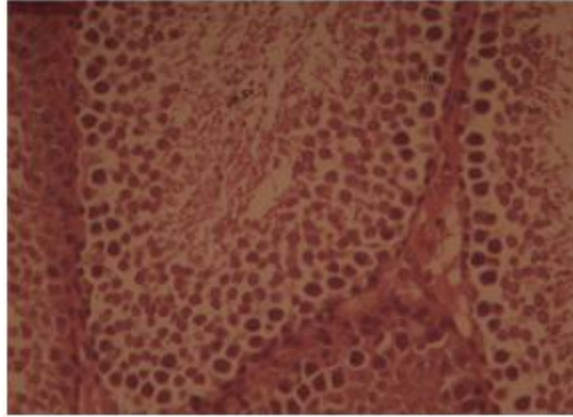


Fig 5: Photomicrograph (control group) showing seminiferous tubules (S) with intact basement membrane (BM) & stratified columnar epithelium (GE) are in layers (LC) and in triangular contacted interstitial spaced (IS) (PAS 40x).

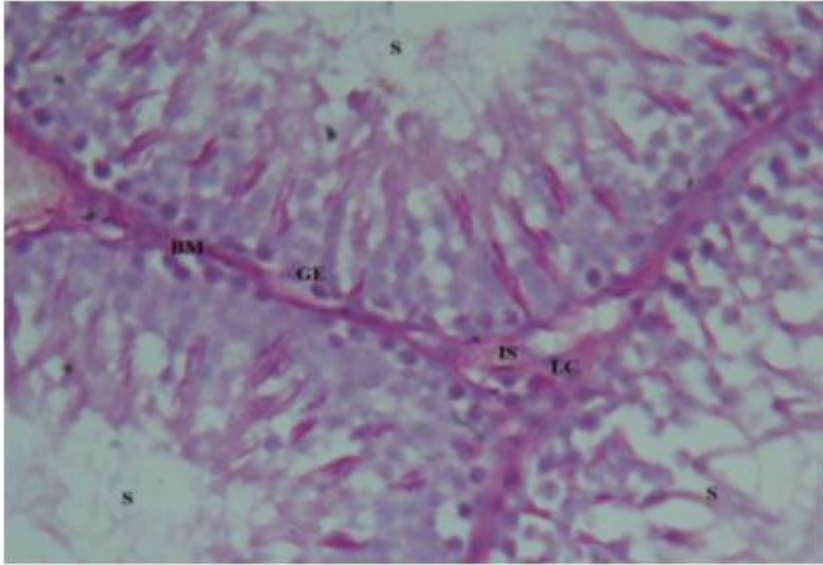


Figure 6a: Photomicrograph of an adult rat testis, treated with Doxorubicin showing seminiferous tubules (S), with detached basement membrane (DBM), wide interstitial space (IS) marked vacuolation (V) of germ and sertoli cell blood vessels (BV) in interstitial space (PAS-10x)

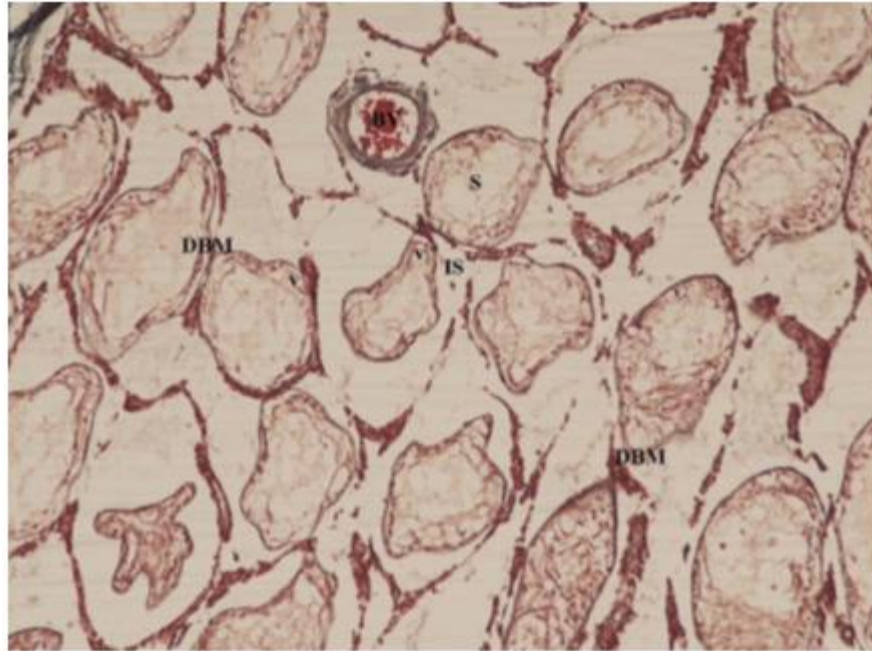


fig 6b: Photomicrograph of an adult rat testis, treated with Doxorubicin showing seminiferous tubules (S), with multinucleate giant cells and accentuated germ cell depletion (PAS-Iron Hematoxylin 100x).

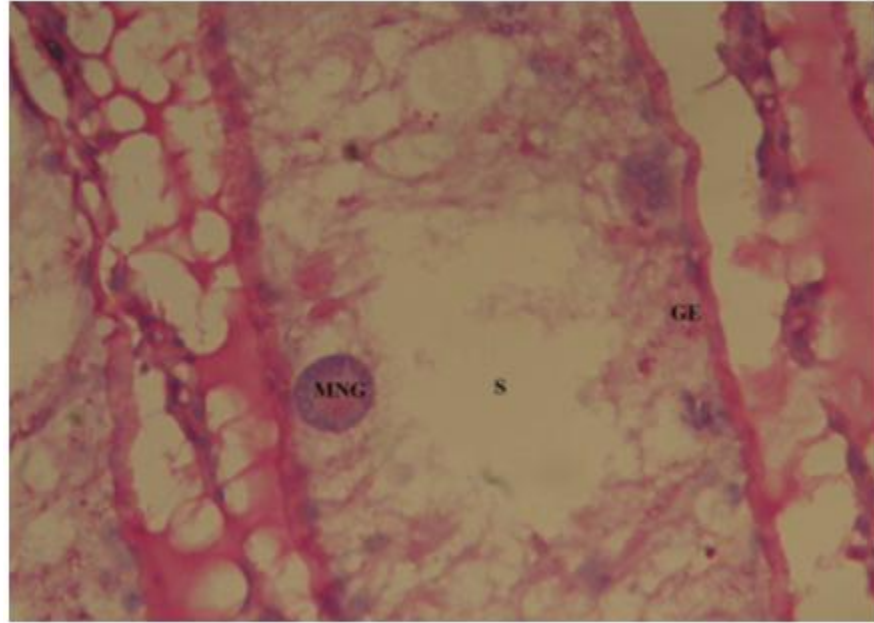
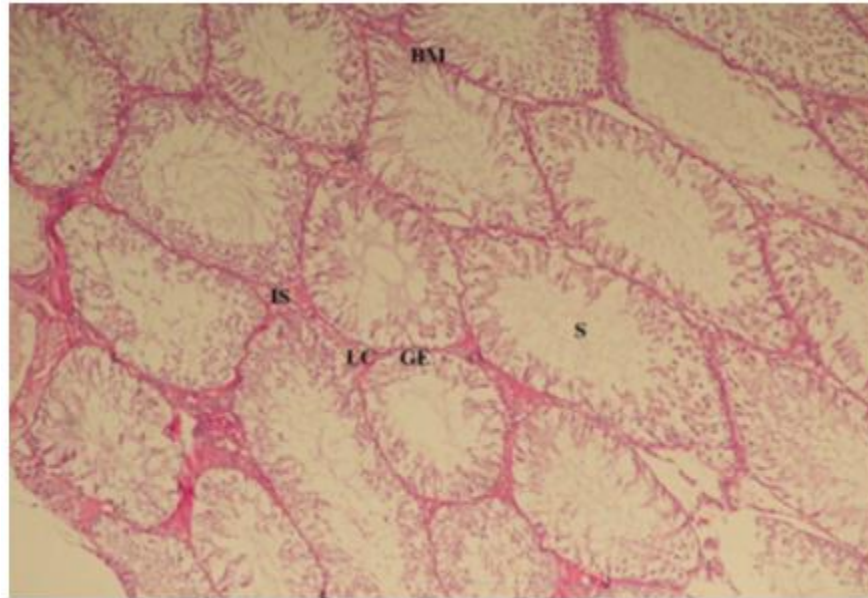


Fig 7: Photomicrograph of an adult rat testis, treated with Doxorubicin and *Nigella sativa*, showing nearly normal seminiferous tubules (S) with marked regeneration of germinal epithelium (GE), completely bounded by basal membrane (BM), with leydig cell (LC) in contacted triangular interstitial spaces (IS) (PAS-iron Hematoxylin 10x).



DISCUSSION

In spite of injurious influence of doxorubicin on normal body tissues and gonads, it is one of the commonest medications used for the treatment of various type of malignances.¹ It reduces the spermatogonia, spermatocytes & sertoli cell count, thus enlarged the luminal diameter of seminiferous tubules.² Doxorubicin mutilate DNA of malignant cell as well as normal healthy cells and causes oxidative stress and cellular apoptosis.¹¹ *Nigella sativa* is a Ranunculaceae group member, cultivated in South of Mediterranean sea and have antioxidant, diuretic, analgesic, antipyretic, antimicrobial, antidiabetic & digestive properties. It mends sperm viability, motility & contour of testis.^{12,13}

Group Bo showed loss of architecture of seminiferous tubules and diverse level of atrophy with destroyed germinal epithelium; this could be due to the toxic effects of doxorubicin on germinal epithelium of seminiferous tubules. Our findings are supported by¹¹ who reported that Doxorubicin causes damage of germinal epithelium by oxidative stress. The mechanism of

seminiferous tubule's atrophy and destruction of germinal epithelium could be due to intercalation with DNA strand mentioned by ⁴ that doxorubicin reduces the luminal seminiferous tubular diameter and widens the interstitial space. It causes abnormalities of sperms like shapeless head, microcephaly, dual headed, disengaged head & diminutive tail. Our findings are in agreement with ⁵ who reported that doxorubicin causes temporary to permanent infertility. In the present study the interstitial spaces were widened with marked vacuolation in Leydig cells, this is in agreement with findings of ²³ who state that doxorubicin with the dose, as per our study, causes marked widening of interstitial spaces and vacuolation of Leydig cells due to atrophy of seminiferous tubules.

Study observations show improvement in histopathological findings of testes in group Co (treated *Nigella sativa* and Doxorubicin). Striking retrieval of germ cell line and Sertoli cells. No multinucleate formations but there are some vacuolation seen in germ and non-germ cells. Triangular interstitial spaces consisting of Leydig cells and small blood vessels were seen. Leydig cells seen in this group were less than group Ao but more than group Bo, this is in agreement with ¹⁵ who reported that aqueous suspension of *Nigella Sativa* improves histopathological changes. Our findings are in agreement with ^{17,18,19}. Same findings were also deliberated by ²⁰ who reported that *nigella sativa* mends variations in sperm count, viability & testicular weight caused by Lead acetate.

CONCLUSION:

This experimental research work revealed that the diseased group showed loss of architecture of seminiferous tubules and diverse level of atrophy but in the treated group variations are amended. Hence our hypothesis of this research work is that *nigella sativa* will reduce the harmful effects of doxorubicin.

REFERENCES

1. Boussada M, Ali RB, Said AB, Bokri K, Akacha AB, Dziri C, El May MV. Selenium and a newly synthesized Thiocyanacetamide reduce Doxorubicin gonadotoxicity in male rat. *Biomedicine & Pharmacotherapy*. 2017 May 1;89:1005-17.
2. Farsani BE, Karimi S, Mansouri E. Pravastatin attenuates testicular damage induced by doxorubicin—a stereological and histopathological study. *Journal of basic and clinical physiology and pharmacology*. 2019 Jan 1;30(1):103-9.
3. Eleiwa NZ, Galal AA, Abd El-Aziz RM, Hussin EM. Antioxidant activity of *Spirulina platensis* alleviates doxorubicin-induced oxidative stress and reprotoxicity in male rats. *Oriental Pharmacy and Experimental Medicine*. 2018 Jun;18(2):87-95.
4. Silva RC, Britto DM, de Fátima Pereira W, Brito-Melo GE, Machado CT, Pedreira MM. Effect of short-and medium-term toxicity of doxorubicin on spermatogenesis in adult Wistar rats. *Reproductive biology*. 2018 Jun 1;18(2):169-76.
5. Abdelaziz MH, Salah EL-Din EY, El-Dakdoky MH, Ahmed TA. The impact of mesenchymal stem cells on doxorubicin-induced testicular toxicity and progeny outcome of male prepubertal rats. *Birth defects research*. 2019 Aug 1;111(13):906-19.

6. Ahmed ZA, Abtar AN, Othman HH, Aziz TA. Effects of quercetin, sitagliptin alone or in combination in testicular toxicity induced by doxorubicin in rats. *Drug design, development and therapy*. 2019;13:3321.
7. Sakai K, Ideta-Otsuka M, Saito H, Hiradate Y, Hara K, Igarashi K, Tanemura K. Effects of doxorubicin on sperm DNA methylation in mouse models of testicular toxicity. *Biochemical and biophysical research communications*. 2018 Apr 6; 498(3):674-9.
8. Aksu EH, Kandemir FM, Yıldırım S, Küçükler S, Dörtbudak MB, Çağlayan C, Benzer F. Palliative effect of curcumin on doxorubicin-induced testicular damage in male rats. *Journal of biochemical and molecular toxicology*. 2019 Oct;33(10):e22384.
9. Öztürk E, Kaymak EM, Akin AT, Karabulut DE, Ünsal HM, Yakan Bİ. Thymoquinone is a protective agent that reduces the negative effects of doxorubicin in rat testis. *Human & experimental toxicology*. 2020 Oct;39(10):1364-73.
10. El-Maddawy ZK, Abd El Naby WS. Protective effects of zinc oxide nanoparticles against doxorubicin induced testicular toxicity and DNA damage in male rats. *Toxicology research*. 2019 Sep 1;8(5):654-62.

11. Belhan S, Özkaraca M, Özdek U, Kömüroğlu AU. Protective role of chrysin on doxorubicin-induced oxidative stress and DNA damage in rat testes. *Andrologia*. 2020 Oct;52(9):e13747.
12. Sapmaz HI, Yıldız A, Polat A, Vardı N, Köse E, Tanbek K, Çuğlan S. Protective efficacy of *Nigella sativa* oil against the harmful effects of formaldehyde on rat testicular tissue. *Asian Pacific Journal of Tropical Biomedicine*. 2018 Nov 1;8(11):548.
13. Assi MA, Hezmee MN, Abba Y, Rajion MA, Wahid H, Yusof MS. Assessment of therapeutic effects of *Nigella sativa* against chronic lead acetate-induced reproductive dysfunction in male Sprague-Dawley rats. *Comparative Clinical Pathology*. 2017 Jan 1;26(1):87-97.
14. Ethaeb AM, Al-Shaeli SJ, Ahmed TH. Histopathological and hormonal evaluation of interaction effects of ethidium bromide, *Nigella sativa*, and silver nanoparticle on male rat fertility. *Research Journal of Pharmacy and Technology*. 2021 Jun 1;14(6):3184-90.
15. Kohestani Y, Kohestani B, Shirmohamadi Z, Roushandeh AM, Faghani M. The protective properties of hydro-alcoholic extract of *Nigella sativa* on male reproductive system in type 2 diabetes rats. *Health Biotechnology and Biopharma*. 2019; 3(1):45-56.

16. Tavakkoli A, Ahmadi A, Razavi BM, Hosseinzadeh H. Black seed (*Nigella sativa*) and its constituent thymoquinone as an antidote or a protective agent against natural or chemical toxicities. *Iranian journal of pharmaceutical research: IJPR*. 2017;16(Suppl):2.
17. Umar Z, Qureshi AS, Rehan S, Ijaz M, Faisal T, Umar S. Effects of oral administration of black seed (*Nigella sativa*) oil on histomorphometric dynamics of testes and testosterone profile in rabbits. *Pak J Pharm Sci*. 2017 Mar 1;30:531-6.
18. Sangi SM, Bawadekji A, Alotaibi NM, Aljalous NA. Preventive and Curative Effects of Metformin, *Nigella sativa*, *Punica granatum* and *Zingiber officinale* on Male Reproductive Dysfunction in Diabetic Rats. *International Journal of Pharmaceutical Research & Allied Sciences*. 2019 Apr 1;8(2).
19. Abd-Elkareem M, El-Rahman A, Mokhless AM, Khalil NS, Amer AS. Antioxidant and cytoprotective effects of *Nigella sativa* L. seeds on the testis of monosodium glutamate challenged rats. *Scientific Reports*. 2021 Jun 29;11(1):1-6.
20. Assi MA, Hezmee MN, Abba Y, Yusof MS, Haron AW, Rajion MA, Al-Zuhairy MA. Prophylactic effect of *Nigella sativa* against lead acetate induced changes in spermogram, reproductive hormones and gonadal histology of rats. *Veterinary world*. 2016 Nov;9(11):1305.

21. Elshama SS. The preventive and curative role of *Nigella sativa* in poisoning cases. *J Clin Exp Tox*. 2018; 2 (2): 18-24. DOI: 10.4066/2630-4570.015. *J Clin Exp Tox* 2018 Volume 2 Issue. 2018;2.
22. Hashem MA, Mohamed WA, Attia ES. Assessment of protective potential of *Nigella sativa* oil against carbendazim-and/or mancozeb-induced hematotoxicity, hepatotoxicity, and genotoxicity. *Environmental Science and Pollution Research*. 2018 Jan;25(2):1270-82.
23. Patil, L., & Balaraman, R. Effect of melatonin on doxorubicin induced testicular damage in rats. *International Journal of PharmTech Res*, 2009,1, 879-884.
24. Elsharma, S. S., Shehab, G. M., El-Kenawy, A. E., Osman, H. E. H., & Farag, M. M. Role of *Nigella Sativa* Seeds on modulation testicular toxicity of colchicine repeated use in adult albino rats. *Life Science Journal*, 2013, 10 (4), 1629-1639.