

Original Research Article

A Radiographic Study on Prevalence and Distribution of Accessory ossicles and Sesamoids of the Foot in Indian population

Abstract

Background: The prevalence of accessory ossicles and sesamoid bones are variable in distribution. The accessory ossicles and sesamoids are usually asymptomatic, normal variants, and misdiagnosed or overlooked. **Objective:** The primary objective is to estimate the prevalence and distribution of accessory ossicles and sesamoid of the foot by radiographic study in the Indian population. **Materials and methods:** A retrospective study of 1034 radiographs of the foot (anteroposterior and oblique view) performed—the prevalence of accessory ossicles and sesamoids—descriptive statistics used for data analysis. **Results:** One thousand thirty-four radiographs did, in which 68% of male and 32% of female patients. In our study, the prevalence of sesamoid bone hallux sesamoid, another sesamoid, and accessory ossicles are 100%, 9.2%, and 25.9%, respectively. The hallux sesamoid visualized in all individuals, (a) medial bipartite, (b) lateral bipartite, and (c) absent medial hallux are (3.38%), (0.58%), (1.16%) respectively. Our study group has three accessory ossicles location: forefoot, midfoot, and hindfoot. The prevalence of accessory ossicles found to be forefoot, midfoot, and hindfoot are (2.03%), (20.5%), (3.3%) respectively. **Conclusion:** Diagnosis of accessory ossicles and common sesamoids of the foot helps avoid the common pitfall in clinical practice. Accessory ossicles often misdiagnosed as fractures; further imaging is required to confirm the clinical suspicion and decision-making for different management.

Keywords: Prevalence, Foot, Sesamoid Bones, Radiography, accessory ossicles

INTRODUCTION

Sesamoids are ossification occurs in the few focal areas of the tendons, which helps to alter the tendon direction and modify the pressure to prevent the frictional injury to the tendons.^[1-6]

Accessory ossicles are well-cortical smooth bones formed by primary or secondary ossification centers fused or unfused with adjacent bones.^[2,4,5] Therefore, it remains a separate bone. These bones are partially embedded in tendons, and these are normal variants with unknown functions.

Both accessory ossicles and sesamoids are usually incidental with variable imaging findings. These bones are generally asymptomatic and may involve various diseases, including fractures, dislocations, degenerative changes. Others include osteoarthritis, osteonecrosis, avascular necrosis, osteochondral lesion, and impingement syndromes.^[1,4] A frequent false interpretation of the presence of ossicles as fracture occurs commonly because of their variable morphological characteristic features.^[2]

Differential includes the fracture in many situations (Alajoulin et al., 2021). The knowledge of the ossicles of the foot is essential to avoid unnecessary confusion with the fracture.^[4] We aimed to estimate the prevalence and distribution of accessory ossicles and sesamoid of the foot by radiograph.

MATERIALS AND METHODS

The convenient sampling method used and retrospectively examined X-ray at a tertiary care Saveetha hospital, Chennai, from June 2020 to May 2021. Totally 1034

radiographs of the foot (anteroposterior and oblique views). The study group includes both genders (male and female) in the age group between 12 to 80 years. Since the secondary ossification center appears between 7 to 12 years, <12 years children are excluded. These radiographs were acquired from the Medsynapse PACS system with an individual age, gender, and hospital identification number to examine the prevalence and sex distribution of sesamoid and accessory ossicles of the foot. Exclusion criteria include foot deformity or known diseases, improper positioning, and metatarsal and tarsal bone fracture. The data was collected and analyzed by reading of foot anteroposterior and oblique radiographs view.

STATISTICAL ANALYSIS

Statistical analyses were performed using Statistical Package for the Social Science (SPSS). A p value <0.05 was considered to be statistically significant. For gender distribution, the chi-square test was used.

RESULTS

Totally 1034 radiographs of foot were examined, out of which 68% of male (702/1034) and 32% of female (332/1034) patients.

In our study, the prevalence of sesamoid bone is 9.2%, and accessory ossicle is 25.9% {**Table 1 and 2, Bar Diagram 6**}. This study has three groups regarding the location for accessory ossicles: forefoot, midfoot, and hindfoot. The prevalence of

accessory ossicles found to be a forefoot (2.03%), midfoot (20.5%), and hindfoot (3.3%) **{Table 2, Bar Diagram 5}**.

Among the study group for sesamoid, hallux sesamoid is seen in all individuals, while IP joint sesamoid of the great toe and 5th lesser metatarsal sesamoid found to be second and third most common respectively. The hallux sesamoid shows wide variability. It includes medial bipartite (3.38%), lateral bipartite (0.58%), and absent medial hallux (1.16%) **{Table 1, Bar Diagram 1, 2}**.

Among all accessory ossicles, the common ossicles are accessory navicular (13.06%), os peroneum (7.16%), and os trigonum (2.32%) **{Table 2, Bar Diagram 3}**.

The accessory navicular is the most common ossicle in the foot and has type I (5.32%), type II (6.58%), and type III (1.16%) **{Table 2, Bar Diagram 4}**.

DISCUSSION

Sesamoid bones of the foot:

Hallux sesamoids are seen in all individuals^[7,9] and as medial (tibial) and lateral (fibular) sesamoids which are usually located at the plantar aspect of the first metatarsal head.^[5,6] The prevalence of hallux sesamoid is 100% by Umile et al.^[7] and it is similar to our study result. These bones are generally medial sesamoid and oblong in shape and are larger than the lateral sesamoid. Hallux sesamoid is seen in all individuals.^[6] The hallux sesamoid includes medial bipartite, lateral bipartite, and absent medial hallux (3.38%), (0.58%), (1.16%) respectively **{Table 1, Figure 1 (a, b, c)}**. Differential for Bipartite hallux is the fracture hallux.^[3,6]

A lesser metatarsal sesamoid is located in the plantar aspect of the metatarsal head^[4,5] embedded within the joint capsule. 2nd and 5th sesamoids are seen frequently among the four lesser metatarsal sesamoids. Usually, sesamoids are asymptomatic, but sometimes infections occur that spread from the adjacent soft tissue.^[3,4] The prevalence of 2nd and 5th lesser metatarsal sesamoids was 0.4% and 4.3%, respectively, which was reported by Nigar et al.^[5] Our study shows a majority of 0.39% and 3.68% **{Table 1, Figure 1 (d, e)}**, similar to the Nigar's study on the Turkish subject.

The interphalangeal joint sesamoid of the great toe is located in the plantar aspect and embedded within the joint capsule.^[4,5] Usually, asymptomatic, severe associated pathology is irreducible dislocated IP standard due to its interposition.^[3,4] The prevalence of interphalangeal joint sesamoid was ~ 2% reported by Nigar et al.^[5]. Our study shows a 5.2 % **{Table 1, Figure 1 (f)}** prevalence higher than the reported prevalence in Nigar study done in Turkish subjects. Reported prevalence in literature is ~ 2-13%.^[9]

The differential for forefoot pain syndromes is Sesamoid disorders. Numerous pathologic processes are associated with the sesamoid complex because of the significant mechanical stresses and anatomic variations. Various pathologies include acute fractures, stress fractures, non-unions, osteonecrosis, chondromalacia. Others have inflammatory conditions labeled sesamoiditis. Treatment options include conservative management with orthotics and immobilization and operative interventions that range from fracture/non-union fixation to various approaches for sesamoidectomy.^[7]

Accessory ossicles of the foot:

The Accessory navicular has three types based on morphological characteristics, located within the posterior tibial tendon in the distal aspect.^[4,6,8] In the literature review, the prevalence of Accessory navicular is between 4 and 21%.^[3] Our study results show prevalence is 13.06% **{Table 2}**. East et al. estimated prevalence is 5.8%, and the frequency is higher in females than males. Our study shows prevalence is higher than the East's Turkish study population. However, it shows a similar frequency of gender distribution.

Type I Accessory navicular (otherwise called Os tibiale externum, Os naviculare secundarium). Type I Accessory navicular bone has no cartilaginous communication to the navicular tuberosity. In the literature review, the prevalence of Type I Accessory navicular was ~ 30% reported.^[3] Our study result shows 5.32%, males (5.56%) than females (4.48%). **{Table 2, Figure 2 (c)}**. Type II Accessory navicular (otherwise called Prehallux or Bifurcate hallux). In the literature review, the Type II Accessory navicular prevalence reported ~ 50-90%.^[3] Our study shows 6.58% **{Table 2, Figure 2 (a)}**, lower than the reported in the literature. It varies from triangular or heart-shaped. Bone connected by either fibrocartilage or hyaline cartilage with navicular tuberosity. Type III Accessory navicular bone (otherwise called Cornuate navicular). The prevalence of Type III Accessory navicular was ~ 30% reported in the literature review.^[3] Our study shows 1.16% **{Table 2, Figure 2 (d)}**. These bones cause pain syndrome in many conditions, and it is usually associated with pes planus. Usually, pain is exacerbated during exercise or walking and affects sports performance. Differential includes the degenerative arthritic spur, avulsion fractures, or trauma.^[6] In a case of acute pain, a

bone scan may help to differentiate one of these accessory ossicles from an acute injury.^[6]

Os intermetatarsium located between the 1st and 2nd metatarsal bases.^[4,5,8] It has different shapes, including linear, round, oval, or bean-shaped. It needs to differentiate from the 2nd metatarsal bone fracture.^[3,4] The prevalence of Os intermetatarsium in literature was 1-13%.^[9] Our study shows a result of a majority of 0.68% **{Table 2, Figure 2 (a)}**, which is lower than the reported prevalence in the literature. Differential for dorsal midfoot pain syndrome is painful os intermetatarsium syndrome, in which the os intermetatarsium compress the deep peroneal nerve. In football players, repeatedly kicking the ball causes minor trauma of the deep peroneal nerve above the os intermetatarsium. These bones may see together with hallux valgus deformity and should be differentiated from calcified dorsalis pedis artery.^[6]

Os vesalianum, proximal to the base of the 5th metatarsal, is embedded within the peroneus brevis tendon.^[4,5,8] It needs to differentiate from the base of the 5th metatarsal fracture.^[3,4] The prevalence of Os vesalianum was reported 0.1-1% in the literature review.^[3,9] Our study shows a majority of 1.35% **{Table 2, Figure 2 (b)}**, which is higher than the reported in the literature. These bones are usually asymptomatic but sometimes may associate with lateral foot pain syndromes. It is essential to differentiate os vesalianum pedis from acute avulsion fractures of the fifth metatarsal, Jones fracture, Iselin's disease, stress fractures, non-union of the fifth metatarsal base, non-united apophysis of the fifth metatarsal base, and os peroneum. Clinically, there is edema, tenderness, and sometimes ecchymosis around the fifth metatarsal base.^[6] It needs to differentiate from the base of the 5th metatarsal avulsion fracture.^[3,4] The fracture

fragment is a sharply delineated bone piece that lacks cortication at the fracture line. Conversely, these bones are surrounded by a bony cortex, and the margins are rounded.

Os peroneum is a bipartite or multipartite ossicle. It is usually asymptomatic, may be associated with various pathologies, and is located at the lateral plantar aspect of the cuboid within the peroneus longus tendon.^[4,5,6,8] It needs to differentiate from the 5th metatarsal styloid avulsion fracture.^[4,6] The prevalence of Os peroneum in Turkish population was 5.3% and 4.7%, respectively reported by East et al. and Nigar et al.^[6,10] Our study report is 7.16% **{Table 2, Figure 2 (e)}**, which is slightly higher than the prevalence reported in the literature. In our study, females have a higher frequency than males. Pain, swelling, and tenderness in the lateral aspect of the foot along the peroneus longus tendon with restricted plantar flexion of the foot signifying Os peroneum syndrome or lateral pain syndrome.^[6]

Os trigonum is located posterior to the talus bone. It has various shapes, which include round, oval, or triangular.^[4,5,8] Usually, it is an incidental finding and not associated with pathology. It needs to differentiate from the avulsion fracture of the lateral tubercle of the talus.^[2,4,6] Esta et al. report show the approximate prevalence in the Turkish study population is 2.9%.^[10] Our study estimated prevalence is approximately 2.23% **{Table 2, Figure 2 (f)}**. In our study group, females had a higher prevalence than males, contradicting the Turkish study.^[10] The approximate prevalence in the literature review is 1-25%.^[2] A flexor hallucis longus tenosynovitis or entrapment syndrome may be associated with large os trigonum. A significant and early ossification of an os trigonum

(mega os trigonum) helps differentiate progressive pseudo-rheumatoid dysplasia from juvenile rheumatoid arthritis.^[6]

Os supranaviculare is otherwise named as Piries bone, talonavicular dorsale or talonavicular ossicle, proximal and dorsal aspect of the navicular bone or talonavicular joint.^[4,5,8] The approximate prevalence in the literature review is 1-3.5%.^[9] Our study report shows 0.19% **{Table 2}**, as lesser than the literature reported prevalence. Os supranaviculare bone is 22% associated with the navicular stress fracture, and association is possibly due to pre-existing dorsal cortical notch accompanying this bone. Avulsion fractures can be differentiated from os supranaviculare by their irregular surface and lack of cortication. Differential includes osteoarthritic degeneration of the talonavicular joint from this accessory bone. A case with os supranaviculare impingement of the deep peroneal nerve is reported in the literature.

Os subtibiale is located distal to the tip of the medial malleolus.^[4,6,8] It needs to differentiate from the avulsion fracture.^[2,4] The prevalence of Os subtibiale reported in the literature is 0.9%.^[2] Our study report shows 0.19% **{Table 2}**, as lesser than the literature reported prevalence. Os subtibiale could be confused with accessory ossification centers, posttraumatic ossification, or avulsion fractures. Differential includes acute fracture is the primary diagnostic goal, although it may be necessary to differentiate it from an unfused ossification center. In addition, os subtibiale could also lead to posterior tibial tendon dysfunction.^[6]

Os subfibulare is located distal to the tip of the lateral malleolus.^[4] It needs to differentiate from the avulsion fracture.^[2,4] The prevalence of Os subfibulare reported in the literature is 0.2-6.6%.^[9] Our study report shows 0.39% **{Table 2}**, which is similar to

the literature reported prevalence. There are conflicting opinions on whether the os subfibulare is a true accessory ossicle or an old non-united avulsion fracture of the anterior talofibular ligament. It could usually be confused with an avulsion fracture of the lateral malleolus.^[2,4] It is difficult to distinguish between the acute ankle sprain and a fracture since they share the typical clinical findings. Tenderness on distal fibula with a missing part of the lateral malleolus and an uncorticated fracture line without sclerosis are diagnosing features of an acute avulsion fracture.

Os calcaneus secundarius is rare ossicles and located at the anterior calcaneal process.^[4,8] It needs to differentiate from the fracture of an anterior calcaneal process.^[2,4] The prevalence of Os calcaneus secundarius reported in literature is 0.4-11%.^[6] Our study shows a majority of 0.29% **{Table 2}**, which is lower than the reported prevalence in the literature. Differentials include an anterior process fracture of the calcaneus, fracture of the tuberosity of the calcaneus, calcaneus accessorius, cuboideum secundarium, and os sustentaculi. Usually, these bones are asymptomatic sometimes may associate with restricted subtalar motion and pain. In such patient, excision of the anterior tuberosity of the calcaneus for treatment of chronic pain.^[6]

Os supratalar is a rare ossicle at the dorsum of the talus between the ankle and the talonavicular joint.^[6,9] The prevalence of Os supratalar reported in the literature is 0.2-2.4%.^[6,9] Our study shows a majority of 0.19% **{Table 2}**, similar to the reported prevalence in the literature. It is easily confused with a non-united avulsion fracture. Although os supratalar is usually asymptomatic, it may cause a hard bump and dorsal

hindfoot pain. It can also cause pain or degenerative changes in response to overuse and trauma.^[6]

These bones are usually unnoticed and are incidental findings in many situations. The knowledge of the prevalence distribution and the pathologies of the ossicles, as mentioned earlier, could be essential to reach the correct diagnosis. Differentials include fractures, dislocations, degenerative changes, osteonecrosis, osteoarthritis. Others include avascular necrosis, osteochondral lesions, and irritation or impingement of adjacent soft tissues.^[6] Though they cause a small group of illnesses and less clinical importance, the knowledge about their pathologies helps the physician or surgeon to avoid unnecessary confusion or misdiagnosis.^[6]

CONCLUSION

Sesamoid bones and accessory ossicles of the foot are normal variants and usually remain asymptomatic. These bones may involve various pathologies, so high suspicion of these bone-related diseases is expected. Therefore, knowledge of these bones helps in the diagnosis and avoiding the common pitfalls.

Ethical Approval:

As per international standard or university standard written ethical approval has been collected and preserved by the author(s).

Consent

As per international standard or university standard, patients' written consent has been collected and preserved by the author(s).

REFERENCES

Summers, Anthony. "Accessory Ossicles and Sesamoid Bones: Recognition and Treatment." *Emergency Nurse: The Journal of the RCN Accident and Emergency Nursing Association* 22, no. 10 (March 2015): 27–32. <https://doi.org/10.7748/en.22.10.27.e1404>.

Aparisi Gómez, Maria Pilar, Francisco Aparisi, Alessandra Bartoloni, Maria Alejandra FerrandoFons, Giuseppe Battista, Giuseppe Guglielmi, and Alberto Bazzocchi. "Anatomical Variation in the Ankle and Foot: From Incidental Finding to Inductor of Pathology. Part I: Ankle and Hindfoot." *Insights into Imaging* 10, no. 1 (July 31, 2019): 74. <https://doi.org/10.1186/s13244-019-0746-2>.

Aparisi Gómez MP, Aparisi F, Bartoloni A, et al. Anatomical variation in the ankle and foot: from incidental finding to inductor of pathology. Part II: midfoot and forefoot. *Insights Imaging*. 2019;10(1):69. Published 2019 Jul 31. <https://doi:10.1186/s13244-019-0747-1>.

Bmk, Vora, and Wong Bss. "Common Accessory Ossicles of the Foot: Imaging Features, Pitfalls and Associated Pathology." *Singapore Medical Journal* 59, no. 4 (April 1, 2018): 183–89. <https://doi.org/10.11622/smedj.2018046>.

Coskun, Nigar, MehtapYuksel, MetinCevener, R. Yavuz Arican, HakanOzdemir, OguzBircan, Timur Sindel, SezginIlgi, and MuzafferSindel. "Incidence of Accessory Ossicles and Sesamoid Bones in the Feet: A

Radiographic Study of the Turkish Subjects.” *Surgical and Radiologic Anatomy: SRA* 31, no. 1 (January 2009): 19–24. <https://doi.org/10.1007/s00276-008-0383-9>.

Keles-Celik, Nigar, OzkanKose, RahimeSekerci, GunesAytac, Adil Turan, and Ferhat Güler. “Accessory Ossicles of the Foot and Ankle: Disorders and a Review of the Literature.” *Cureus* 9, no. 11 (n.d.): e1881. <https://doi.org/10.7759/cureus.1881>.

Longo, Umile Giuseppe, Andrea Marinozzi, Stefano Petrillo, Filippo Spiezia, Nicola Maffulli, and Vincenzo Denaro. “Prevalence of Accessory Ossicles and Sesamoid Bones in Hallux Valgus.” *Journal of the American Podiatric Medical Association* 103, no. 3 (May 1, 2013): 208–12. <https://doi.org/10.7547/1030208>.

Mellado, J.M., Ramos, A., Salvadó, E. *et al.* Accessory ossicles and sesamoid bones of the ankle and foot: imaging findings, clinical significance and differential diagnosis. *Eur Radiol* 13, L164–L177 (2003). <https://doi.org/10.1007/s00330-003-2011-8>

Nwawka, O. Kenechi, Daichi Hayashi, Luis E. Diaz, Ajay R. Goud, William F. Arndt, Frank W. Roemer, Nagina Malguria, and Ali Guermazi. “Sesamoids and Accessory Ossicles of the Foot: Anatomical Variability and Related Pathology.” *Insights into Imaging* 4, no. 5 (September 5, 2013): 581–93. <https://doi.org/10.1007/s13244-013-0277-1>.

Uygur, Esat, BirolAktas, Tayyar Taylan Oz, SametErinc, and Murat Koc. “Prevalence of Accessory Bones of the Foot in Turkish Patients.” *Journal of*

Alajoulin O. Prevalence and Distribution of Sesamoid Bones in the Region of the Forefoot among Jordanians. *Sch J App Med Sci.* 2021 Jun;6:904-8.

Table 1:

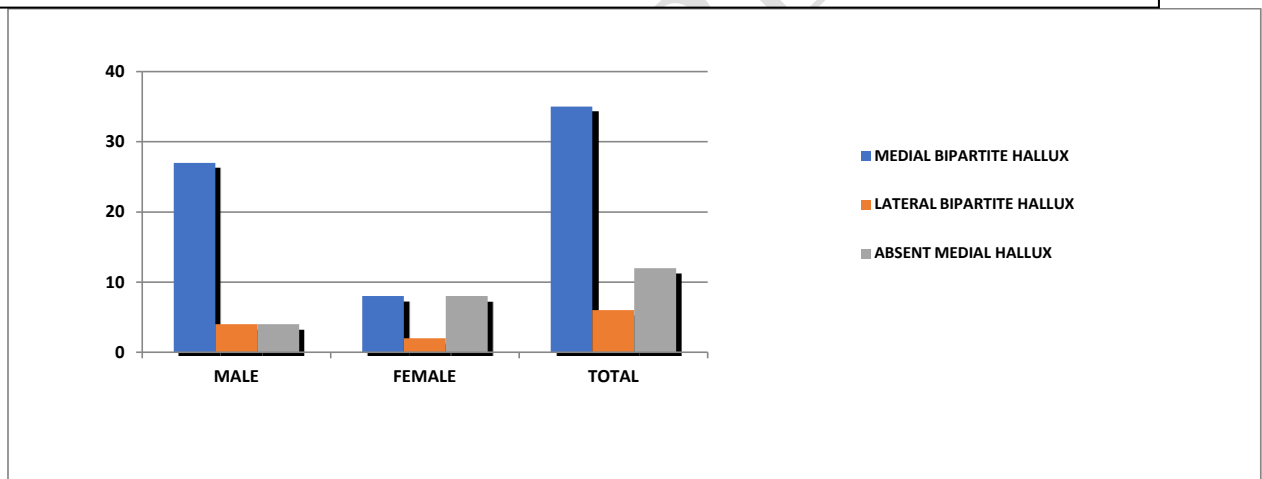
PREVALENCE OF SESAMOIDS OF THE FOOT AND THEIRS GENDER DISTRIBUTION									
S.NO.	ACCESSORY BONE	MALE		FEMALE		TOTAL		OR (CI)	
		N	%	N	%	N	%		
1.	Hallux sesamoid								
1a.	Medial bipartite	27	3.85	8	2.41	35	3.38	1.62	(0.72-3.60)
1b.	Lateral bipartite	4	0.57	2	0.60	6	0.58	0.94	(0.17-5.18)
1c.	Absent medial hallux	4	0.57	8	2.41	12	1.16	0.23	(0.06-0.77)*
2.	2 nd lesser metatarsal sesamoid	2	0.28	2	0.60	4	0.39	0.47	(0.06-3.36)
3.	5 th lesser metatarsal sesamoid	24	3.42	14	4.22	38	3.68	0.80	(0.41-1.53)
4.	IP joint sesamoid of great toe	36	5.13	18	5.42	54	5.22	0.94	(0.52-1.68)

***P value < 0.05 is statistically significant.**

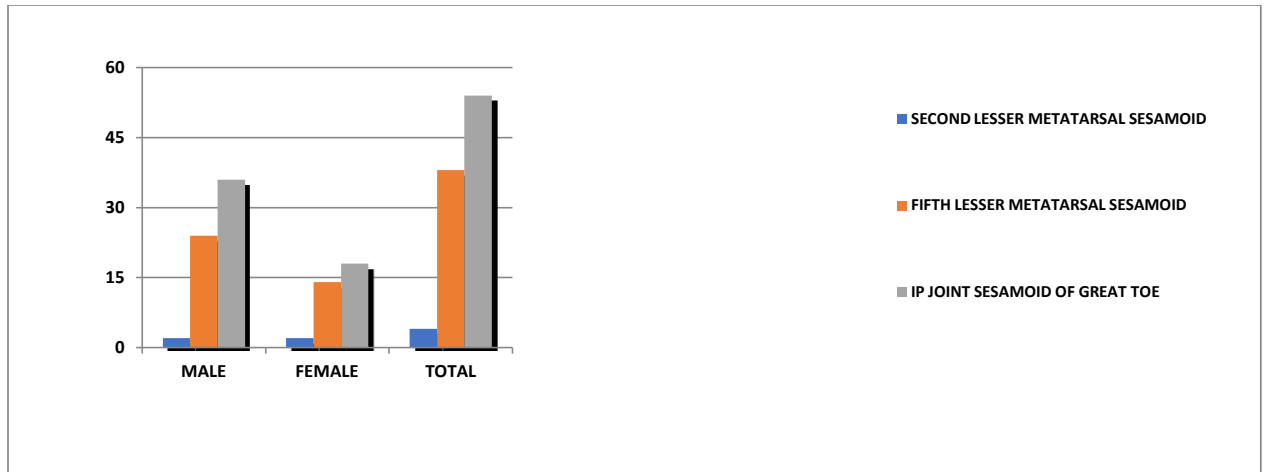
Bar Diagram 1:

UNDER PEER REVIEW

Bar Diagram 1: Prevalence of morphological variation of hallux sesamoid with gender distribution.



Bar Diagram 2:



Bar Diagram 2: Prevalence of sesamoid bones in foot with gender distribution.

Table 2:

PREVALENCE OF ACCESSORY OSSICLES OF THE FOOT AND THEIRS GENDER DISTRIBUTION

S.NO.	ACCESSORY BONE	MALE		FEMALE		TOTAL		OR (CI)
		N	%	N	%	N	%	
FOREFOOT OSSICLES								
1.	Os intermetatarsium	5	0.71	2	0.60	7	0.68	1.18 (0.22-6.13)
2.	Os vesalianum	6	0.85	8	2.41	14	1.35	0.34 (0.12-1.01)
MIDFOOT OSSICLES								
3.	Accessory navicular	69	9.83	66	19.88	135	13.06	0.43(0.30-0.63)*
3a.	Type I	39	5.56	16	4.82	55	5.32	1.16 (0.63-2.11)
3b.	Type II	28	3.99	40	12.05	68	6.58	0.30 (0.18-0.50)*
3c.	Type III	2	0.28	10	3.01	12	1.16	0.09 (0.02-0.42)*
4.	Os peroneum	36	5.13	38	11.45	74	7.16	0.41 (0.25-0.67)

5.	Os supranaviculare	1	0.30	1	0.14	2	0.19	0.41 (0.02-7.57)
----	--------------------	---	------	---	------	---	------	------------------

6.	Os intercuneiform	1	0.14	0	0	1	0.10	
----	-------------------	---	------	---	---	---	------	--

HINDFOOT OSSICLES

7.	Os trigonum	16	2.28	8	2.41	24	2.32	0.94 (0.40-2.22)
----	-------------	----	------	---	------	----	------	------------------

8.	Os subtibiale	1	0.30	1	0.14	2	0.19	0.41 (0.02-7.57)
----	---------------	---	------	---	------	---	------	------------------

9.	Os subfibulare	3	0.43	1	0.30	4	0.39	1.42 (0.14-13.7)
----	----------------	---	------	---	------	---	------	------------------

10.	Os calcaneus secundarium	2	0.28	1	0.30	3	0.29	0.94 (0.08-10.4)
-----	--------------------------	---	------	---	------	---	------	------------------

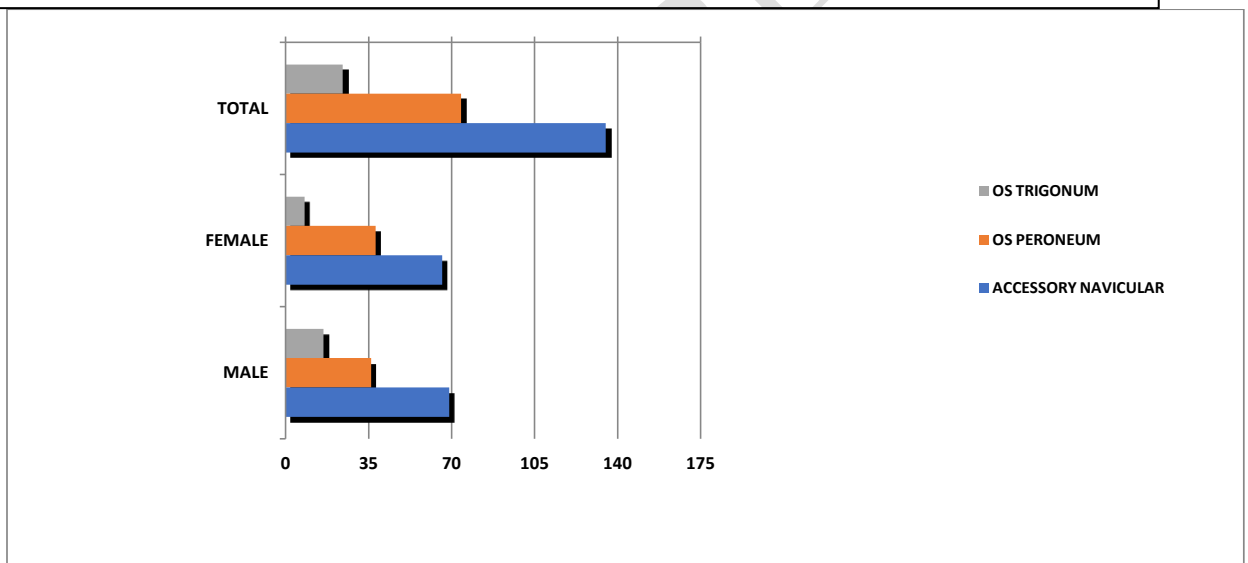
11.	Os supratolar	1	0.30	1	0.14	2	0.19	0.41 (0.02-7.57)
-----	---------------	---	------	---	------	---	------	------------------

*P value < 0.05 is statistically significant.

Bar Diagram 3:

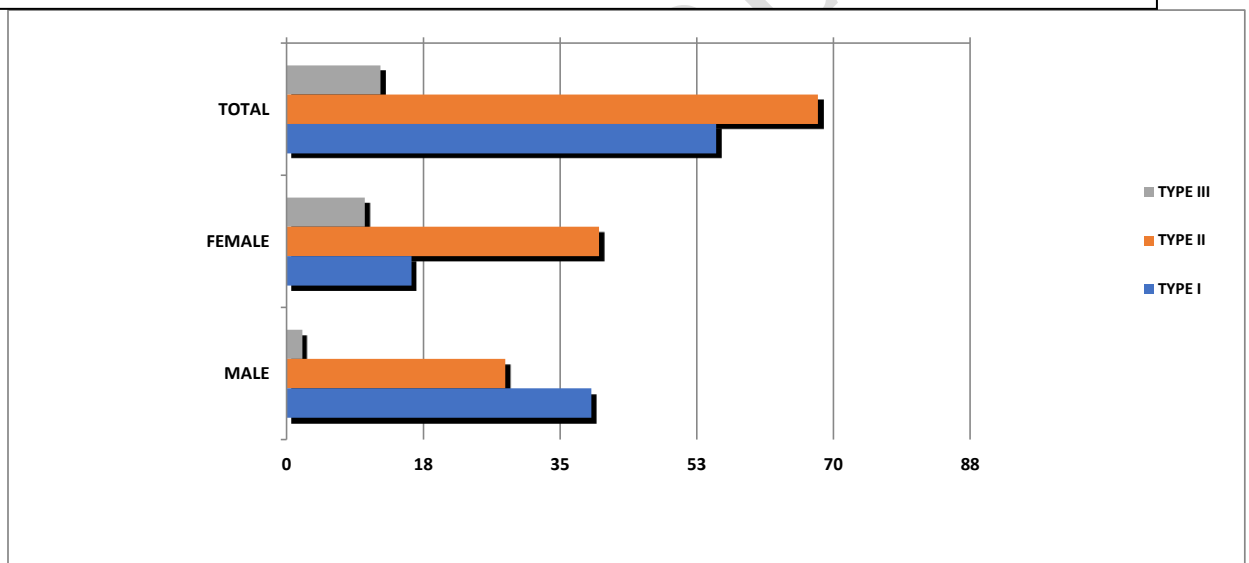
UNDER PEER REVIEW

Bar Diagram 3: Prevalence of common ossicles in the foot with gender distribution.

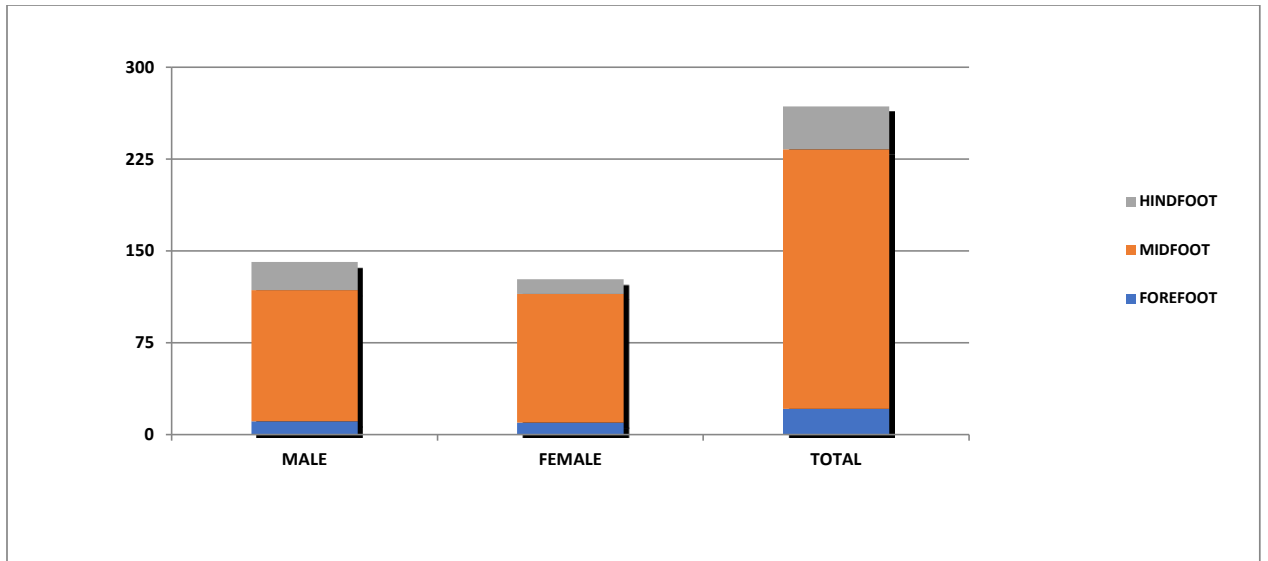


Bar Diagram 4:

Bar Diagram 4: Prevalence of types of accessory navicular with gender distribution.

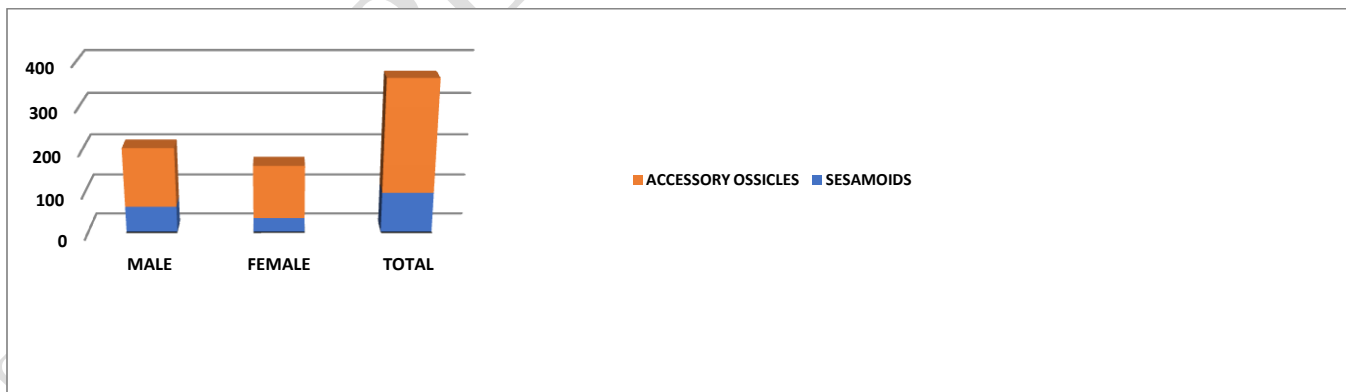

Bar Diagram 5:



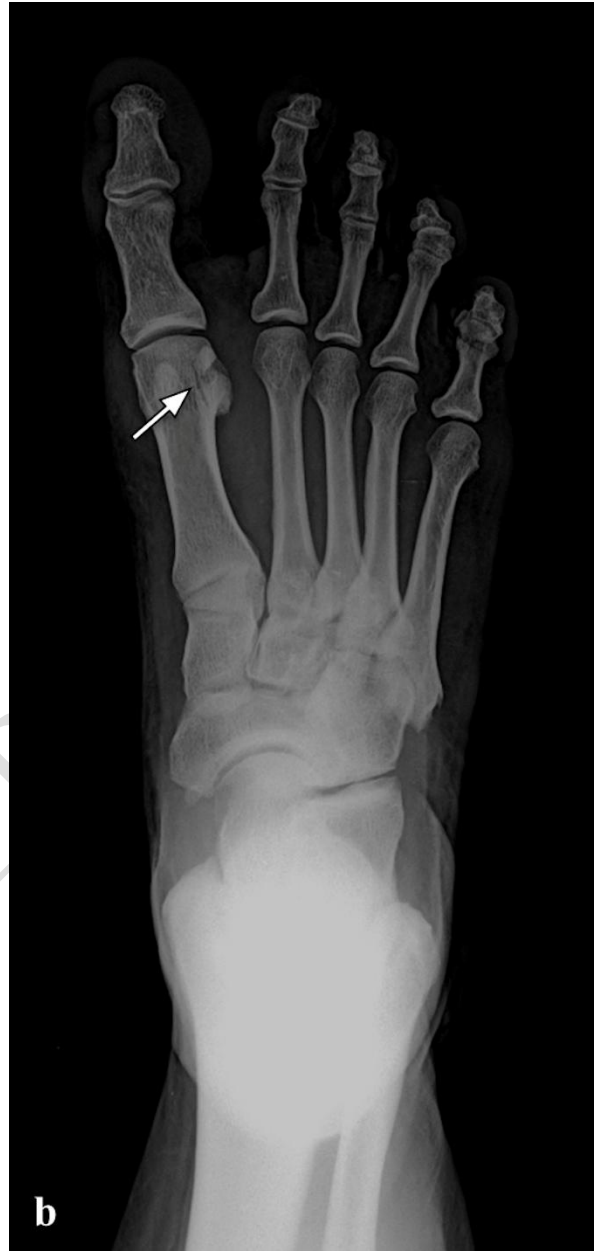
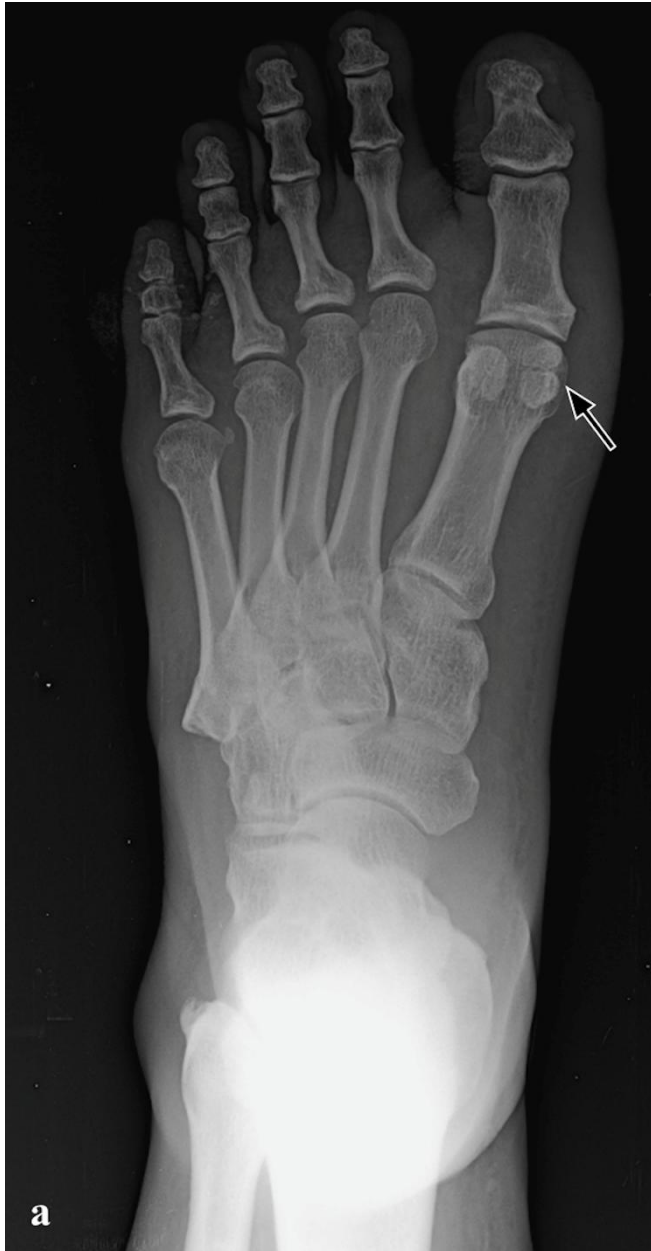Bar Diagram 5: Prevalence of accessory ossicles in the forefoot, midfoot and hindfoot with gender distribution.

Bar Diagram 6:

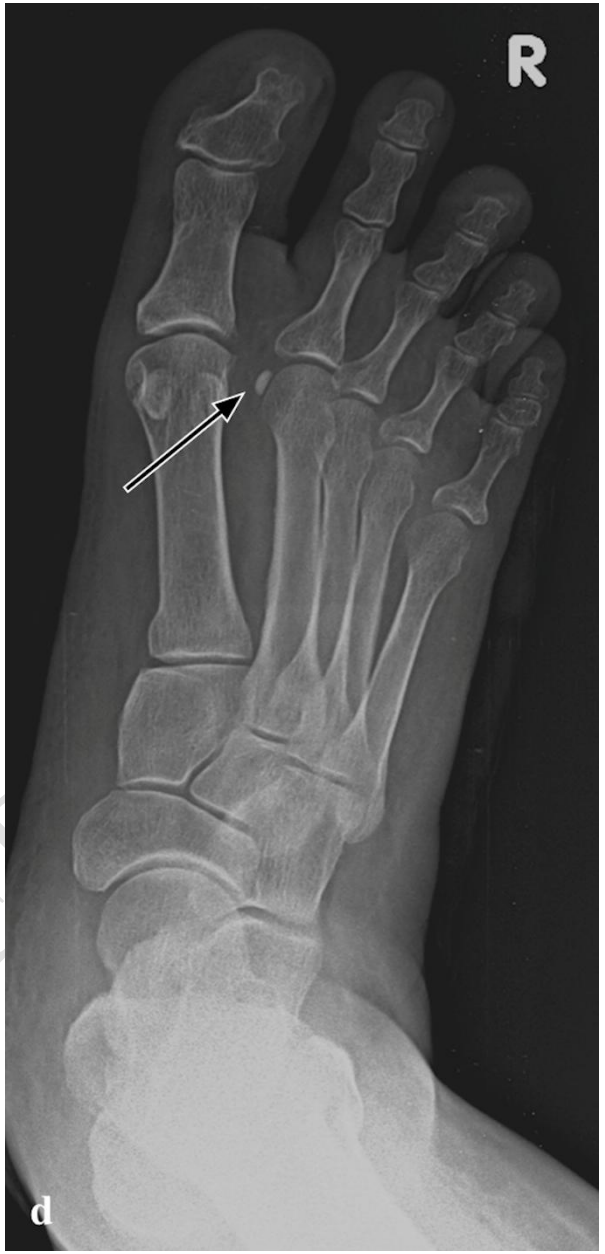
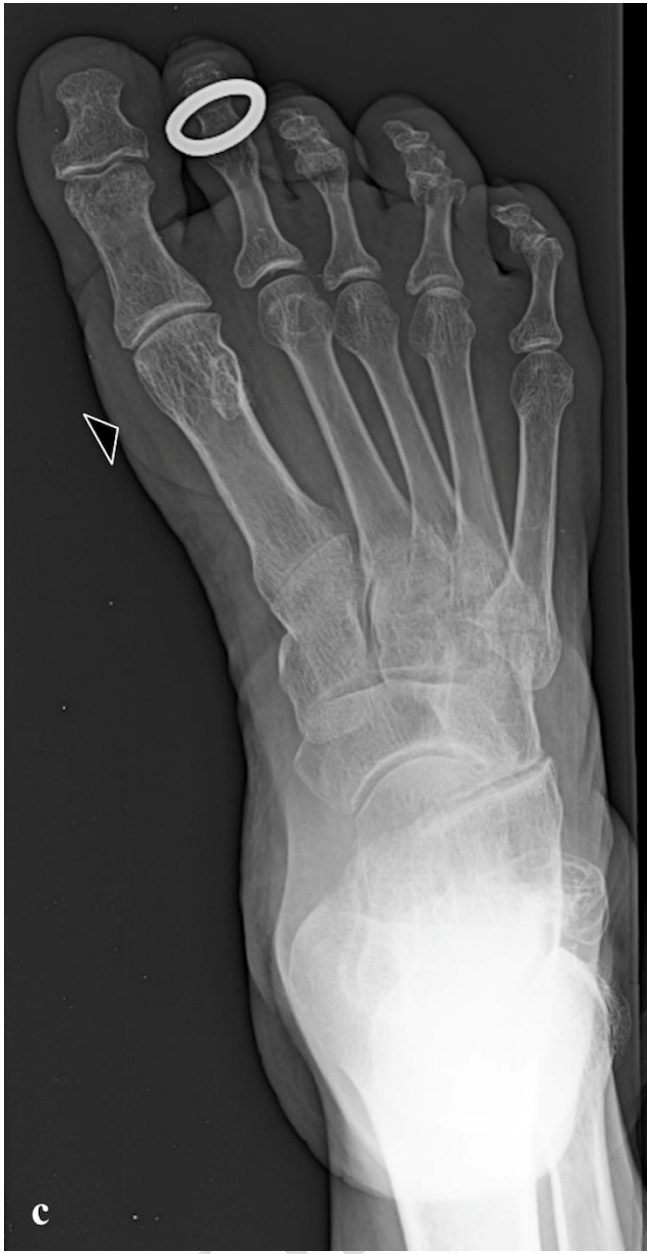
Bar Diagram 6: Prevalence of sesamoid bones and accessory ossicles in the foot with gender distribution.

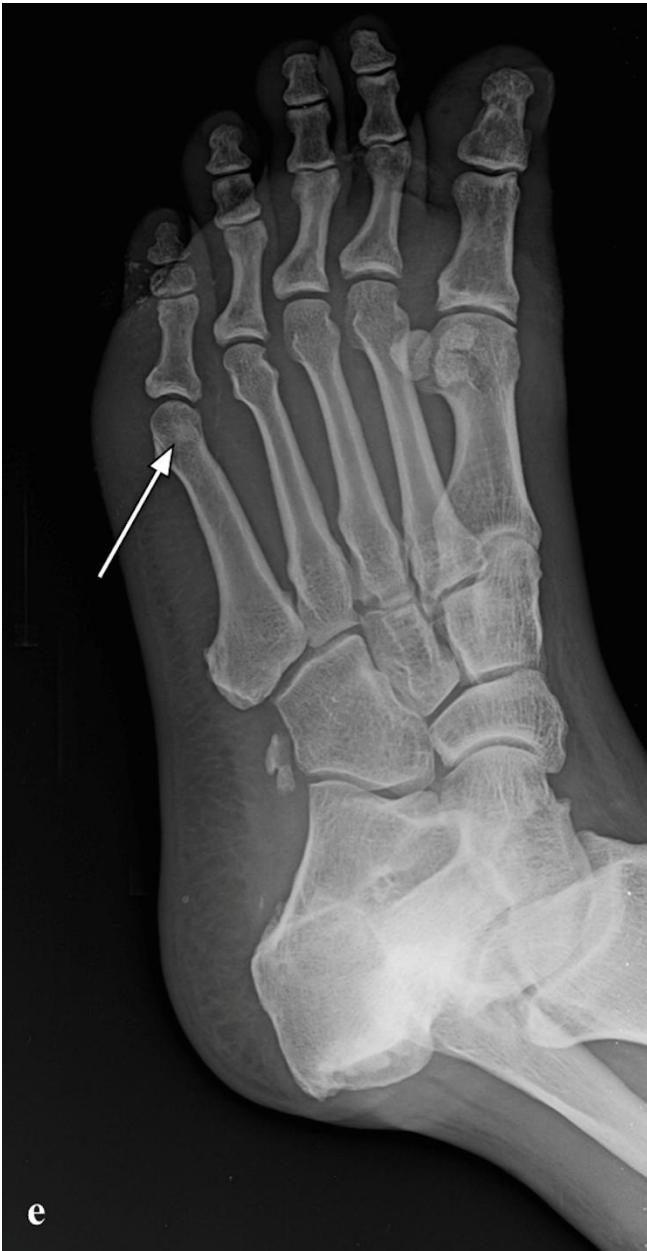Figure 1:



UNM



UNID



UNDER

REVIEW

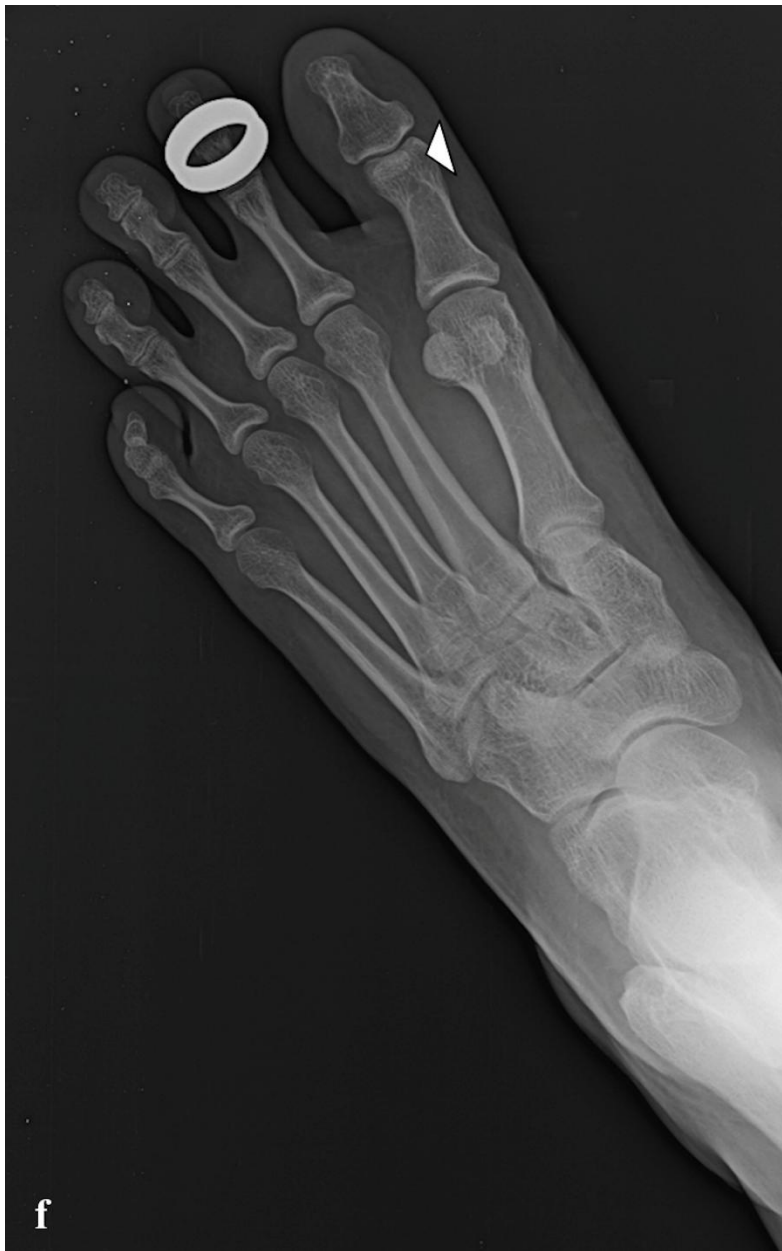
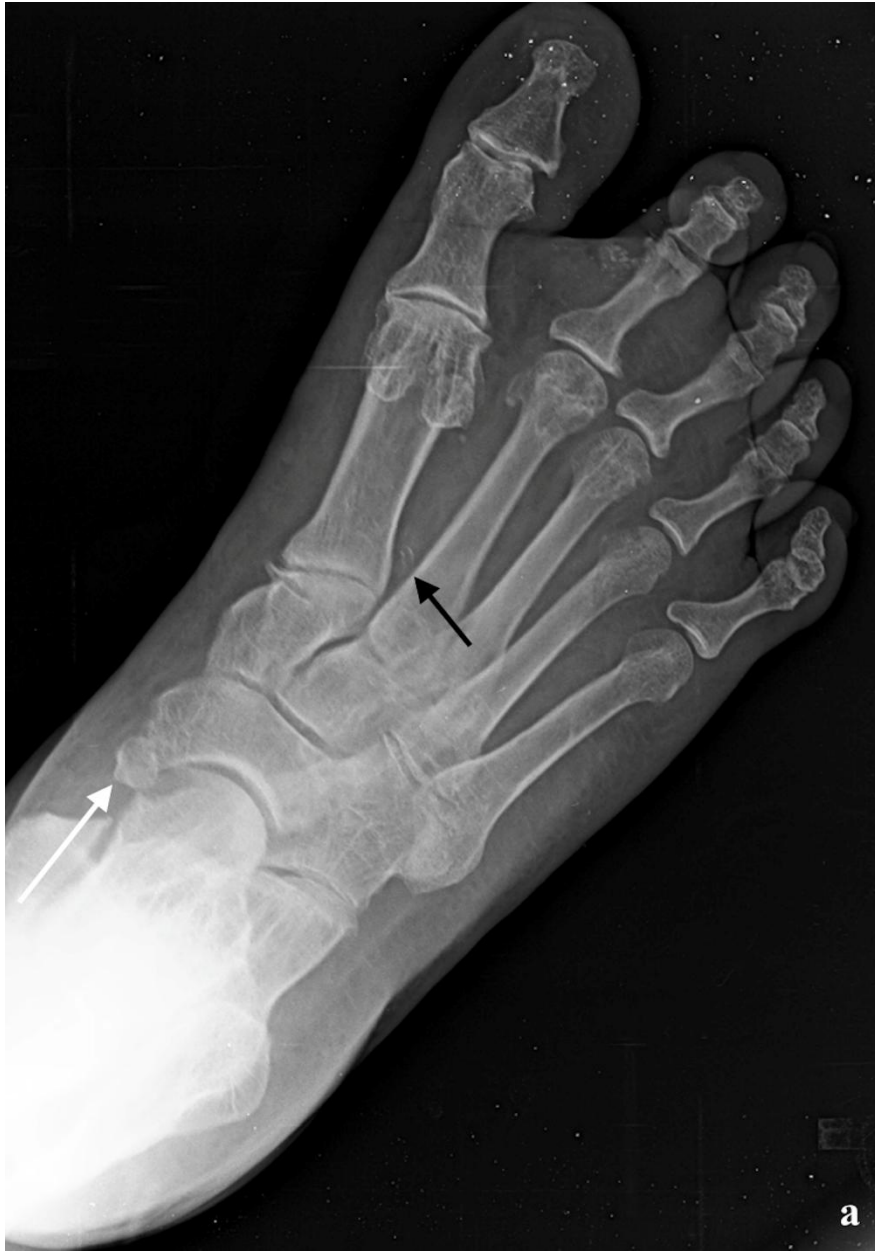
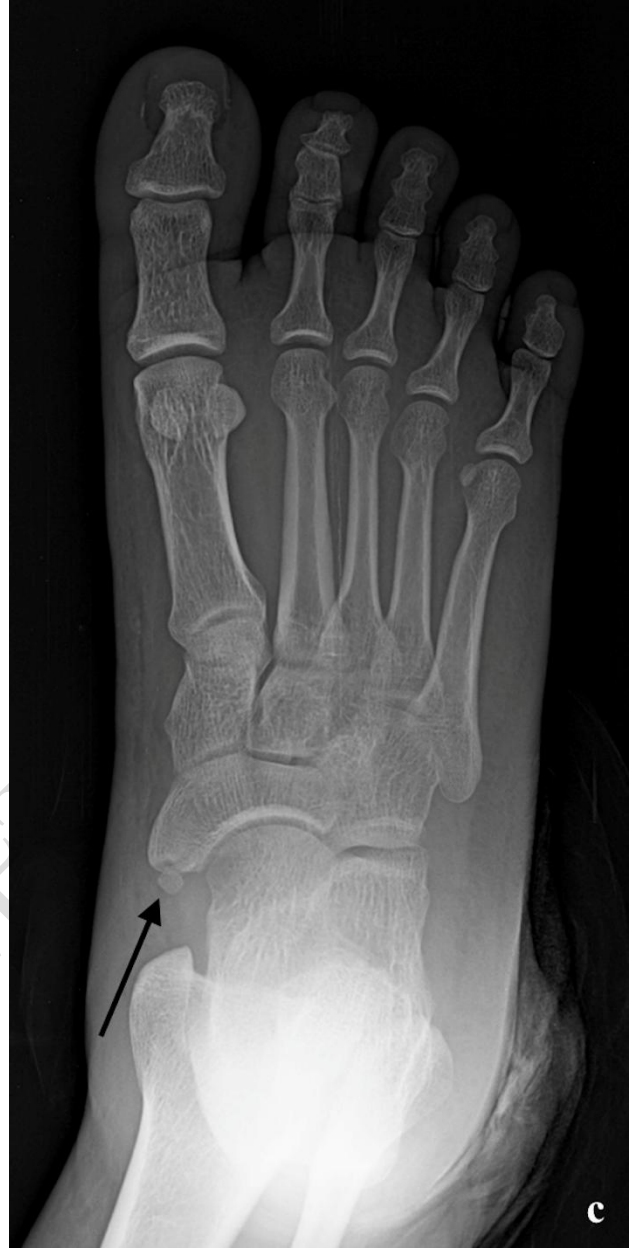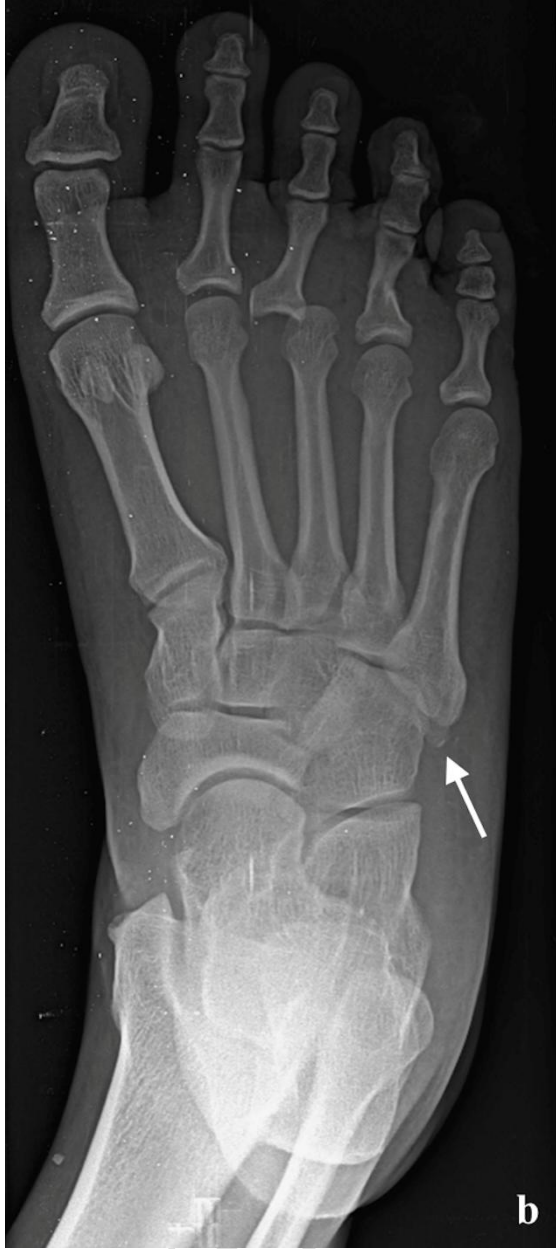Figure 1 (a, b, c, d, e, f): Sesamoids - Medial bipartite hallux sesamoid (small black arrows). Lateral bipartite hallux sesamoid (small white arrow). Absent medial hallux sesamoid (small black arrowhead). 2nd Lesser metatarsal sesamoid (large black arrow). 5th Lesser metatarsal sesamoid (large white arrow). 1st Inter-phalangeal joint sesamoid (small white arrowhead).

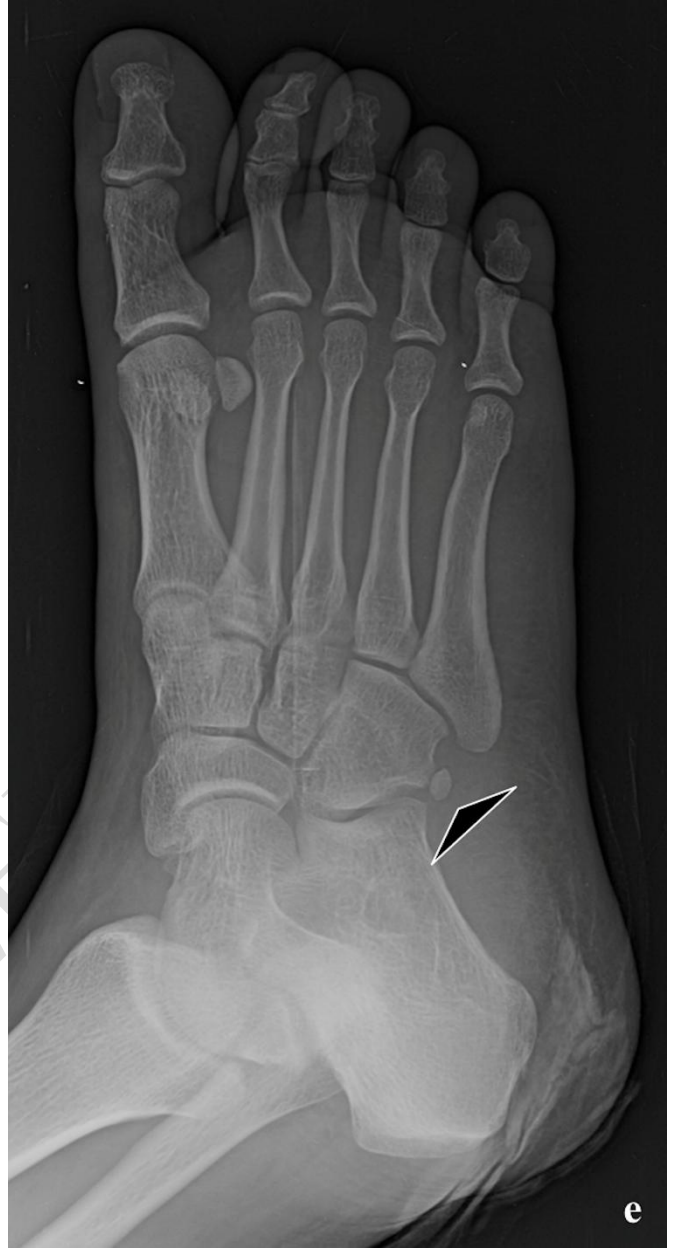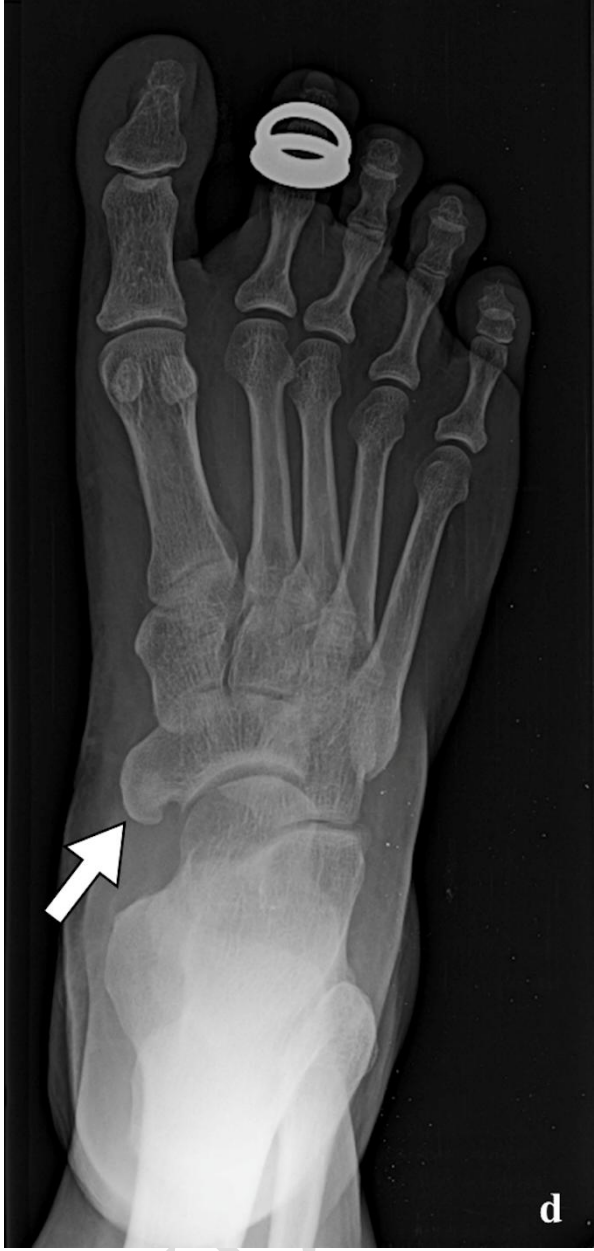Figure 2:



REVIEW

UI





UNIVERSITY OF NORTHERN IOWA

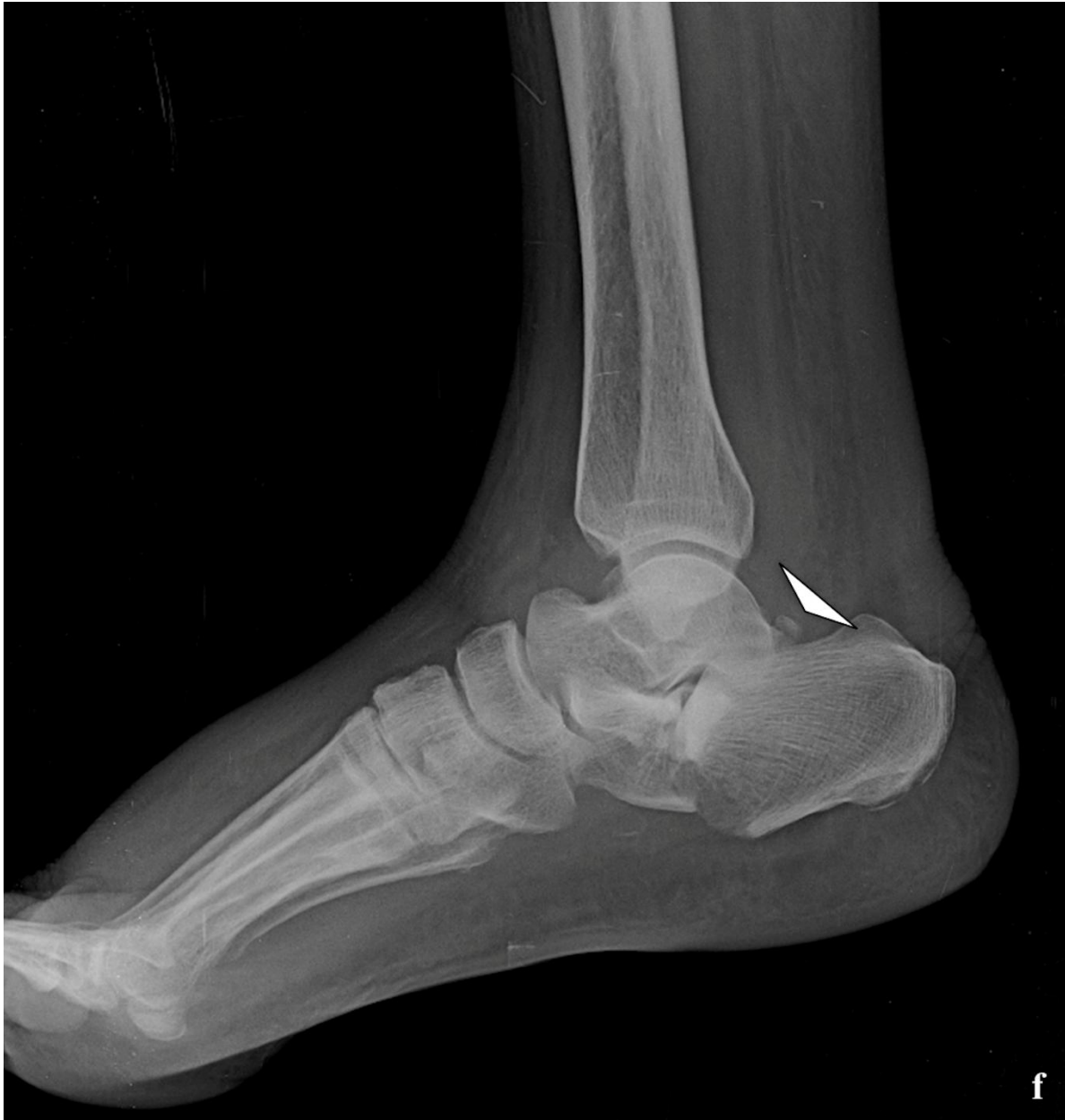

Figure 2 (a, b, c, d, e, f): Accessory ossicles - Os intermetatarsale (small black arrow). Os vesalianum (small white arrow). Type I accessory navicular (large black arrow). Type II accessory navicular (large white arrow). Type III accessory navicular (thick white arrow). Os peroneum (large black arrowhead) and Os trigonum (large white arrowhead).