

# PAN FACIAL TRAUMA FRACTURE MANAGEMENT.

## CASE REPORT & LITERATURE REVIEW

### ABSTRACT

Pan facial fractures involve the mandible, maxilla, and zygomatic complex at the same time, and are frequently associated with NOE and frontal bone fractures. Reconstruction of multiple facial fractures including the top and lower face should be handled as a jigsaw. To accomplish this, two common management sequences for Pan facial fractures have been proposed: "Bottom up and inside out" and "Top down and outside in." There are more sequences, but these two major ways are the most common. The proximity of the maxillofacial region to important features or senses such as vision (diplopia), olfaction, respiration (airway management), chewing or mastication (occlusion), deglutition, and aesthetics makes the scenario a little more complex for the surgeon operating in this region than in any other part of the body.

It's difficult to stick to a tried-and-true procedure for treating pan face fractures. Despite rigorous therapy, most patients with pan facial trauma may have some residual deformity, which may necessitate more surgery in the future. The care and easy procedures utilized to decrease and fix a case of pan facial trauma in a 26-year-old are described in this article.

**Keywords:** Pan facial fracture, Upper third fracture, Mid face fracture, Nasal fracture, Open reduction and internal fixation.

### INTRODUCTION

The maxilla, zygomatic complex, and nasoethmoid-orbital area are the most common bones to fracture with the mandible in pan facial fractures. Soft tissue injury, loss of the face bone framework, and malocclusion are all common complications of multiple bony injuries. The dish" face deformity is characterized by a decrease of

facial height or projection, as well as an increase in face width and enophthalmus <sup>(1)</sup>. Although there is no precise definition or classification of pan facial fractures in the literature, the terminology usually relate to the simultaneous fracture of numerous bones in the face with extensive fragmentation, making facial reconstruction challenging. The goal of pan facial fracture management is to restore function and pre-injury three-dimensional facial contour as quickly as feasible while minimizing pain and suffering for the patient at the lowest cost possible <sup>(2)</sup>.

In the recent few years, surgical methods to Pan facial fracture have evolved. Wider fracture foci exposure, the use of cava rial or iliac crest bone grafts for repair, high-resolution computed tomography, and stiff fixation techniques have all improved things. The width, anteroposterior projection, and vertical height of the face are all recreated in three-dimensional space. Persistent deformity is frequently caused by a lack of direct sight of all fractures and unstable fixations. Despite rigorous therapy, some residual post-traumatic deformity may exist, necessitating a second corrective procedure <sup>(3)</sup>. Here we describe a case report of pan facial fracture with detailed treatment protocols followed and the procedure carried over for the restoration of facial form.

## **CASE REPORT**

A 35year old male trauma victim involved in RTA sustaining to blunt facial trauma reported in the institute of KIMS Hubli with bilateral periorbital edema and ecchymosis, bilateral subconjunctival hemorrhage, enophthamosis, dish face deformity, with multiple facial fractures. Patient complains of difficulty in mouth opening, there was a history of nasal bleed and oral bleed and the patient was not under the influence of alcohol during the accident. There was no difficulty in breathing, SPO2 was maintained. Patient was subjected to hematological, biochemical and radiological investigation which was normal profile. CT report revealed displaced right Para symphysis fracture, right displaced maxillary zygomatic bone fracture, left non displaced maxillary fracture. The patient underwent open reduction and internal fixation under submental intubation under GA. The surgical procedure was carried out by placing a labial. **Vestibule mandibular incision with respect to right parasymphysis region and Stainless steel with four holed gap and two holed gaps were fixed using**

miniplates and closed with 3-0 vicryl and 4-0 ethylon suture material in layer wise suturing technique (fig 1). Upper palatal split was reduced and fixed with 2mm thick three holed plate followed by placement of arch bar and occlusion was gained. Later the knee's approach was used to explore the Le-forte fracture with respect to the right side. Right side ZMC fracture was reduced and fixed with three 2 holed with gap miniplate. (fig 2). Pyriform aperture reduced and fixed with four holed with gap miniplate and closure was done with 3-0 vicryl. The patient was watched, and antibiotics and analgesics were prescribed as postoperative treatment. After a week, the further oral sutures were removed. The patient made a full recovery and had a smooth recovery. For one month, the patient was prescribed a soft diet. To keep the occlusion, postoperative elastics were used after 4 days. With an almost unnoticeable scar, postoperative stability and functioning were good.

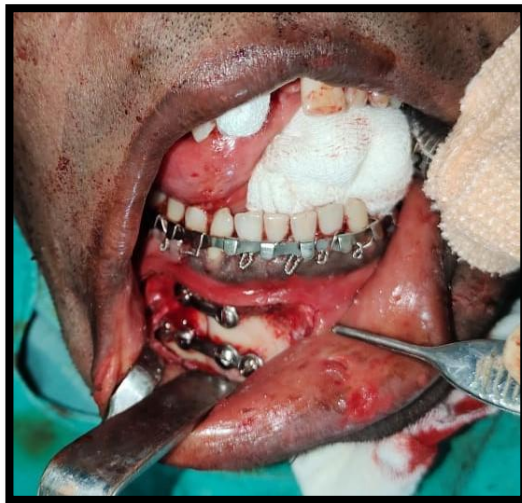

Fig 1 Morphology

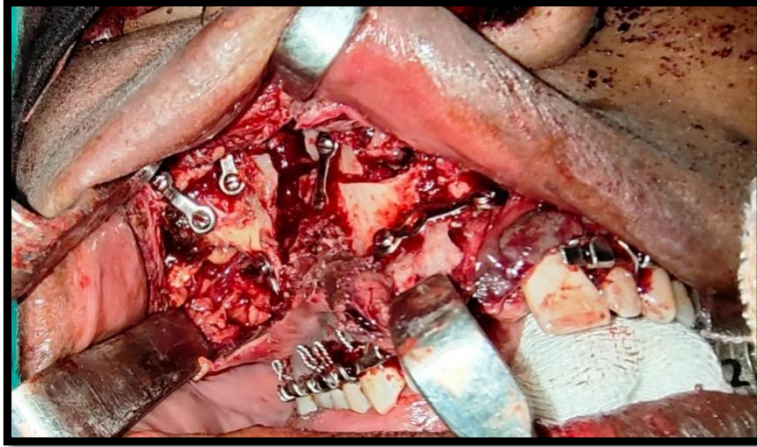


Fig 2 Dissection

## RESULTS

The sequential management of the present case was similar to Mall B et al (2) The postoperative facial shape and profile to be satisfactory and comparable to the premorbidity condition of the patient .Patient 's occlusion was satisfactory .Smooth recovery was presented with unnoticeable scar, postoperative stability and good function.

## DISCUSSION

The craniofacial skeleton is made up of 22 bones. In the craniofacial skeleton, thin bony walls are connected by thicker bony portions. Buttresses are thick bone parts that are important in the restoration of pan facial fractures. Pan facial fracture treatment is quite difficult. The buttresses support the varied dimensions of the face, and the enlargement of the facial complex is a severe problem linked with pan facial fracture. Buttresses are divided into two categories: horizontal buttresses and vertical buttresses (anterior posterior buttresses and vertical buttresses). The numerous buttresses are used to reduce and stabilize pan facial fractures. Frontal buttress, zygomatic buttress, maxillary buttress, and mandibular buttress are examples of horizontal buttresses. Nasomaxillary, zygomatic maxillary buttresses, pterygomaxillary, and condyle posterior buttresses are examples of vertical buttresses. Vertical buttresses, according to Ramus Manson et al, are responsible for the three-dimensional projection of the midface.

## **Principles in Managing Pan facial Fractures**

There are two main theories the management of pan facial fractures

1. Bottom up and inside out.
2. Top Down & Outside in

Bottom up & inside out this sequence involves reduction of all the fractures keeping the mandible as base. Mandibular fractures are first reduced and the rest of the fractures are reduced sequentially from down upwards and at each level the fixation is done from the innermost bone proceeding outwards. In top down and outside in, in this sequence the calvarium is used as a base. The fixation of other bones is done from the topmost proceeding downward. The principles of fracture repair include reduction, fixation, immobilization, early return of function. When there is pan facial fractures, reconstruction should be approached as a puzzle, known landmarks can be used to reconstruct more precisely those areas that have damaged. The landmarks such as dental arches, mandible, sphenozygomatic suture & intercanthal region help in establishing the proper positioning of facial skeleton.

## **IMAGING**

Before the advent of CT scanning, plain film radiography & linear tomography was the gold standard for imaging of facial trauma. High resolution CT scanning allows the surgeon to evaluate details of the fracture pattern. View hard soft tissue details – intracranial injuries to the globe; foreign bodies; extraocular muscle entrapment; soft tissue avulsion displaced teeth the airway. Since the pan facial trauma involves multiple bones of the face hence it is associated with a number of vital senses and organs, so often involve other speciality references too(9).

According to Markowitz the fracture of palate-alveolar bone and frontal bone make the pan facial trauma more extended one. The horizontal and vertical buttresses make the framework of the face and also helps in transmission of mastication force to

the base of the skull. The facial buttresses absorb the forces and prevent its transmission to the brain. The buttresses of the face are like pillars and hence need to be reduced and stabilized properly for complete rehabilitation of facial structure and profile. Proper alignment of the facial skeleton provides functional and anatomic stability to the middle third of the face. With all these bony structures, a complete attention is also required for nasal projection in NOE fracture as it can alter the facial profile, left uncorrected may lead to saddle nose deformity, epiphoria, telecanthus etc (7,10,1). When there are concomitant maxillary and mandibular arch fractures it is difficult to re-establish occlusion and 3D relationship of jaws. Manson and Glassman advised fixing palatal fracture first and then using the maxillary arch as a template for restoration of mandibular arch. The fracture pattern where difficulties commonly arise are those occurring in symphysis and parasymphysis regions associated with fracture of condyle(s) resulting in retrodisplacement of the mandible with widening at angles. Under such conditions all fractures should be exposed prior to reduction and fixation of anyone of them. Pressure should be applied at gonial angles to close any lingual gap to establish lower facial width and achieve correct anterior projection(11,3). The naso-orbital region plays a paramount role in facial esthetics. Surgical failures were most commonly caused by insufficient correction of telecanthus and the internal orbit, as well as insufficient skeletal support(12,3).

Fracture repair should be initiated as soon as the patient's other injuries permit particularly midfacial fracture repair Paul Manson's quote:" You never get a second chance" has to be kept in mind. Reductions fixation of complex injuries within 48 hours in ideal:management within 10days is critical because soft-tissue stiffening & interfragmentary healing make later connection very difficult.

The three treatment goals for pan facial fractures are as follows:

- To restore functional occlusion
- To stabilize the major facial skeletal supports, thereby restoring the premorbid 3-dimensional contour (height, width and projection) to the face and
- Proper restoration of the bony facial scaffold to provide a stable support upon which the overlying soft tissue matrix may heal.

The “Bottom up and inside out” approach occlusion was achieved by maxillomandibular fixation also brings maxilla in its proper position. Mini plates were used for stabilization and fixation of Nasoorbitaoethamoidal complex owing to their success as reported by Michelet (14,1).

## **CONCLUSION**

Through anatomical knowledge and expertise of the maxillofacial surgeon is essential for managing a case of pan facial trauma using either of the approaches. To conclude; a minimally invasive approach should be used to treat the pan facial fractures(9,1). Early surgical intervention to reduce and fix the fractures using miniplate osteosynthesis after stabilizing the trauma patient yields good postoperative results. Patients with complex facial injuries should be informed pre operatively regarding the need for a secondary correction surgery at a later stage(1). The surgical approach to facial fracture management should focus on attaining proper occlusal, vertical and horizontal relationships of the facial frame along with restoration of orbital, oral and nasal cavities(14,1).

### **Disclaimer regarding Consent and Ethical Approval:**

As per university standard guideline, participant consent and ethical approval have been collected and preserved by the authors

## **REFERENCE**

1. Singh A, Singh VK, Tiwari R, Thanvi G. Management of Panfacial Trauma: A Case Report.
2. Mall BB, Kandel L, Mishra R, Kandel S. Panfacial Trauma-A Flexible Surgical Approach. Journal of Universal College of Medical Sciences. 2014 Dec 31;2(3):41-4.
3. Asnani U, Sonavane S, Baig F, Natrajan S. Panfacial Trauma a Case Report. International Journal of Dental Clinics. 2010 Jun 30;2(2).

4. Michael Miloro, G.E. Ghalli, Peter E. Larsen, Peter D. Waite., Textbook of Peterson's principles of Oral & Maxillofacial Surgery, Second edition, Vol-1:547-559
5. Obuekwe ON, Ojo MA, Akpata O, Etetafia M. Maxillofacial trauma due to road traffic accidents in Benin city, Nigeria: A Prospective study. Annals of African Medicine. 2003;2:58-63
6. Sourav Sharma, Vandana Dhanasekaran, Surgical Approaches and Management of Panfacial Trauma: A Case Report, Journal of Clinical and Diagnostic Research. 2015 Aug, Vol-9(8)
7. Miloro M, Ghalli GE, Larsen PE, Waite PD. Textbook of Peterson's principle of Oral & Maxillofacial surgery. Second edition. Vol-1:547-59
8. Pau M, Reinbacher KE, Feichtinger M, Navysany K, Kärcher H. The mandibular symphysis as a starting point for the occlusal level reconstruction of panfacial fractures with bicondylar fractures and interruption of the maxillary and mandibular arches: report of two cases. J Craniomaxillofac Surg 2014;42(4): e51–e56
9. Martou G, Antonyshyn OM. Advances in surgical approaches to the upper facial skeleton. Curr Opin Otolaryngol Head Neck Surg 2011;19(4):242–247
10. Rosenberger E, Kriet JD, Humphrey C. Management of nasoethmoid fractures. Curr Opin Otolaryngol Head Neck Surg 2013; 21(4):410–416
11. Peter Ward Booth, Barry Eppley, Rainer Schmelzeisen., Textbook of Maxillofacial Trauma and Esthetic Facial Reconstruction, 247-254.
12. Gerbino, G., Ramieri, G., Bernardi, M., Berrone, S., Management of panfacial fractures: Aesthetic and Anthropometric results and Pitfalls. Int J of Oral & Maxillofac surg 28:80, 1999



13. Gruss JS, Phillips JH. Complex facial trauma: The evolving role of rigid fixation and immediate bone graft reconstruction. *Clin Plast Surg* .1989;16(1): 93-10
14. Kreutziger KL. Surgical management of complex maxillofacial fractures. *Laryngoscope*. 1982;92(2):192-98

UNDER PEER REVIEW