

Original Research Article

EFFECT OF CONCENTRATED AND DILUTE HYDROCHLORIC ACID ON TOOTH MORPHOLOGY : A FORENSIC STUDY

Abstract.

Introduction: Teeth are the most durable structure present in our human body because of the presence of enamel which persist and resist destruction more than any other bony structure. Hard nature with high amount of resistance of tissues present in the tooth prevents any destruction which increases the lifespan of the tooth.

Aim : The main aim of this study is to observe the changes in tooth morphology when immersed in dilute and concentrated hydrochloric acid.

Materials and method: Non-carries teeth extracted due to periodontal reasons were used from the department of oral and maxillofacial surgery. The tooth added to alternate dilute and concentrated hydrochloric acid was observed till 6th day and the changes were noted along with the photographs as observations.

Results: The tooth left in concentrated HCl showed rapid dissolution and was completely dissolved within 24 hours. Tooth left in dilute HCl dissolved gradually and showed less dissolution when compared to concentrated HCl.

Conclusion: Most durable teeth also undergo erosion and dissolution when placed in dilute HCl and concentrated HCl. Teeth act as a major clue in the field of forensic odontology.

Keywords: Innovative technology, Corrosion, Dental erosion, Hydrochloric acid, Tooth morphology, Novel technique,

Introduction

Teeth are the most sustainable part of a body when compared to other skeletal tissue, teeth persist any kind of destruction that happens externally or internally. Also apart from chewing, biting, tearing teeth also plays an important role in forensic odontology(1). Age estimation can also be performed from the tooth in an acidic environment(2). Present studies show that now DNA can be extracted from teeth even after decades of death. It is possible to employ these identification techniques until there has been complete destruction of the teeth. Even though they can persist many kinds of destruction, teeth do undergo corrosion or complete dissolution when exposed to certain agents.

When a tooth is immersed in an acid the tooth undergoes corrosion or complete dissolution within a certain time period(3). The corrosion or the complete dissolution also depends on the type of acid along with the time period. It acts as a major clue for forensic scientists because of its indestructible nature. Many criminals use hydrochloric acid in order to destroy the body in the crime scene by using acids to dissolve the body(4,5). So the changes in tooth morphology can help us to identify the nature of acid along with the time elapsed in the crime scene.

Teeth are taken as essential organs in both living and nonliving populations for anthropological, genetic, odontologic and forensic cases(6). This is due to the hard nature of tooth with high amount of resistance of tissues of teeth which prevents degradation, which enable the teeth to survive for longer periods than other skeletal tissue, making them more irresistible to trauma, decomposition, water immersion, chemicals and fire, serving as an invaluable evidential source. To match these natural needs, the external materials kept in the mouth by the dental practitioner like fillings, dentures, crowns, bridges and implants must be equally resistant to deep mechanical demands which decides survivability (4). Dental erosion is consequent loss of tooth structures in the tooth which are results of exposure to acids, with absence of bacteria also characterised clinically as corrosive-abrasive wear (7). Our team has extensive knowledge and research experience that has translate into high quality publications [8-27]. The main aim of this study is to observe the changes in tooth morphology when immersed in dilute and concentrated hydrochloric acid.

Materials and methods

Non-carious teeth (n = 6) extracted due to periodontal reasons were used from oral and maxillofacial surgery departments. These were cleaned with distilled water and were photographed prior to the experiment.

These teeth were added to alternate conical flasks containing dilute HCl and concentrated HCl. After every 5 hours, 24 hours, 36 hours, 48 hours, 72 hours, 96 hours, 120 hours, 144 hours tooth immersed in dilute and hydrochloric acid was observed along with which tooth was photographed and was measured using vernier callipers with proper precautions.

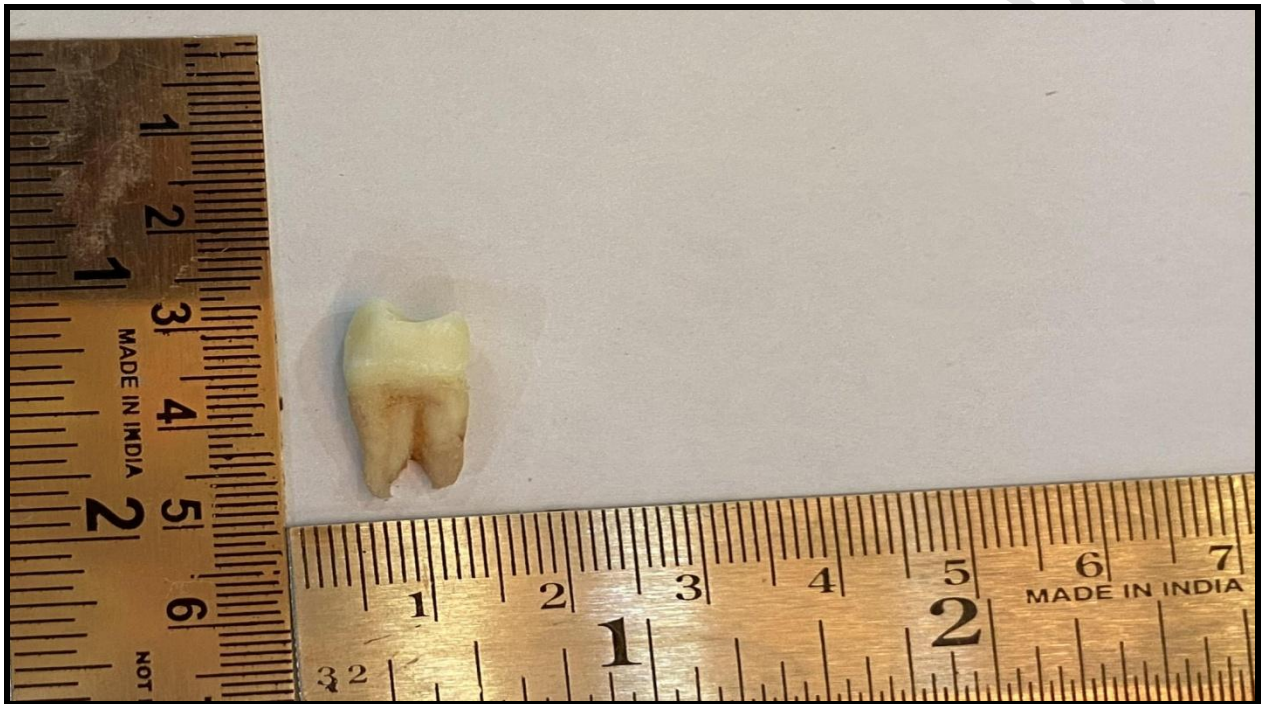

FIGURE 1: This figure shows a tooth which was cleaned with distilled water and was measured from buccal, palatal, mesial and distal sides and then was immersed into hydrochloric acid.

Statistical analysis

The data were statistically analysed using the statistical package for social sciences version 23 (SPSS). From this bar graphs were used to interpret the results.

Results

The tooth left in concentrated HCl showed rapid dissolution and was completely dissolved within 24 hours. Tooth left in dilute HCl dissolved gradually and showed less dissolution as compared to concentrated HCl.

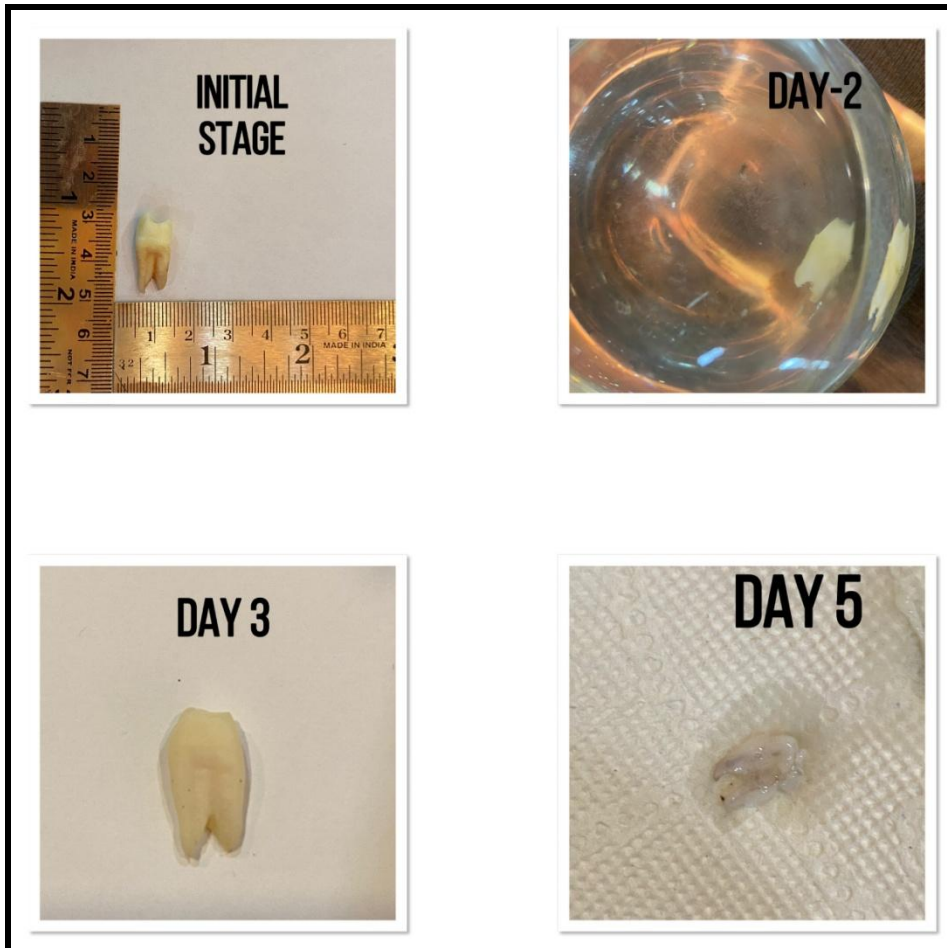


Figure 2: This figure shows sequential morphological changes observed in teeth after immersion in dilute hydrochloric acid, gradual dissolution of tooth when immersed in dilute hydrochloric acid can be observed. Also on the 5th day we can only observe remnants of tooth-like pulp.




Figure 3: This figure shows sequential morphological changes observed in teeth after immersion in concentrated hydrochloric acid, rapid dissolution of tooth which was immersed in concentrated acid. Tooth was completely dissolved within 24 hours, that is one day.

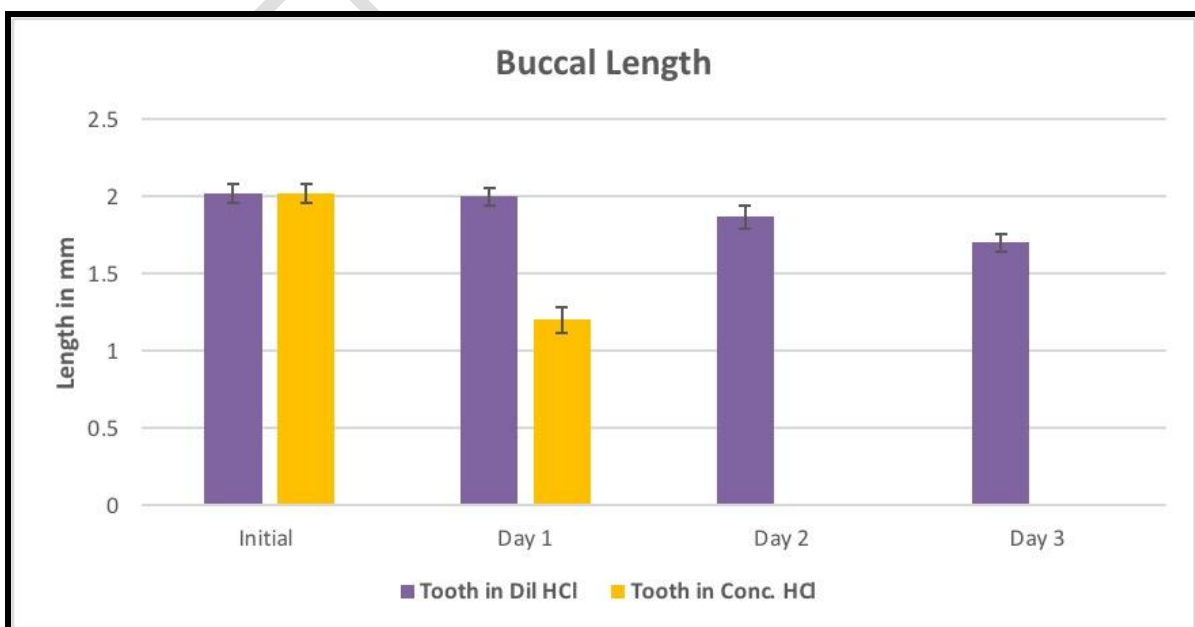


Figure 4: Figure shows the morphological changes observed in teeth after immersion in dilute and concentrated hydrochloric acid in the buccal aspect of immersed teeth. In this x-axis stands for the number of days with respect to tooth immersed and y-axis stands for length of tooth in millimeters. Violet colour represents the tooth in dilute hydrochloric acid and yellow colour represents the tooth in concentrated hydrochloric acid. A statistically significant decrease in the buccal length was observed in the teeth immersed in both concentrated and dilute hydrochloric acid.

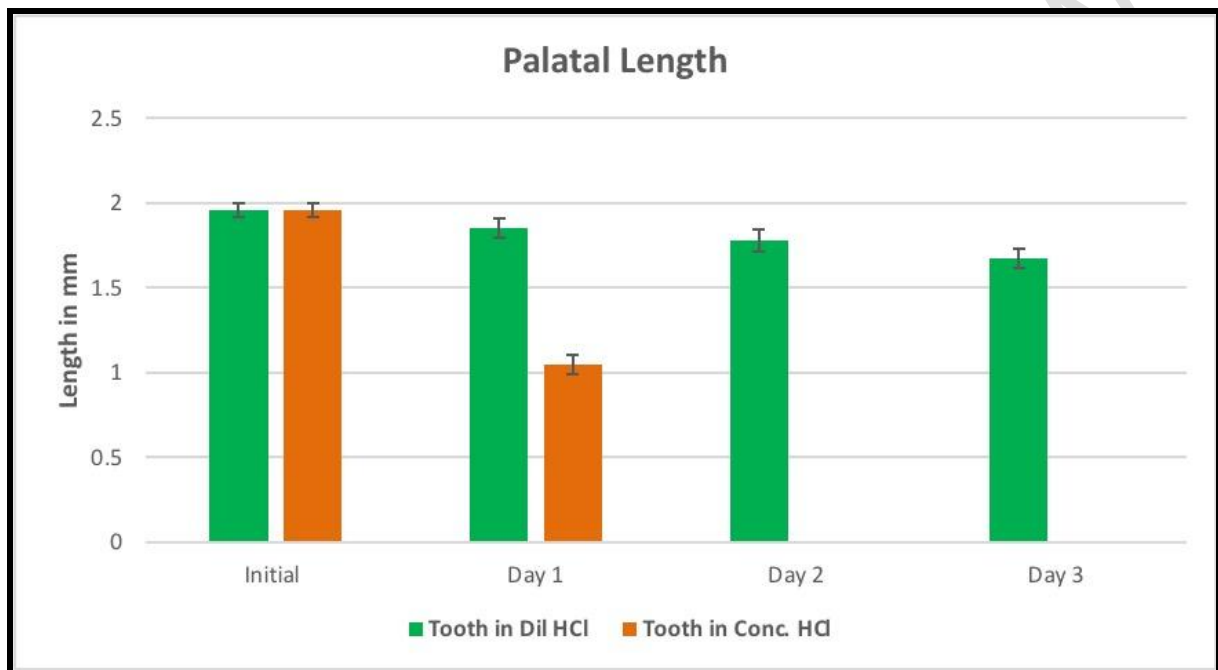


Figure 5: Figure shows the morphological changes observed in teeth after immersion in dilute and concentrated hydrochloric acid in the palatal aspect of immersed teeth. In this x-axis stands for the number of days with respect to tooth immersed and y-axis stands for length of tooth in millimeters. Green colour represents the tooth in dilute hydrochloric acid and orange colour represents the tooth in concentrated hydrochloric acid. A statistically significant decrease in the palatal length was observed in the teeth immersed in both concentrated and dilute hydrochloric acid.

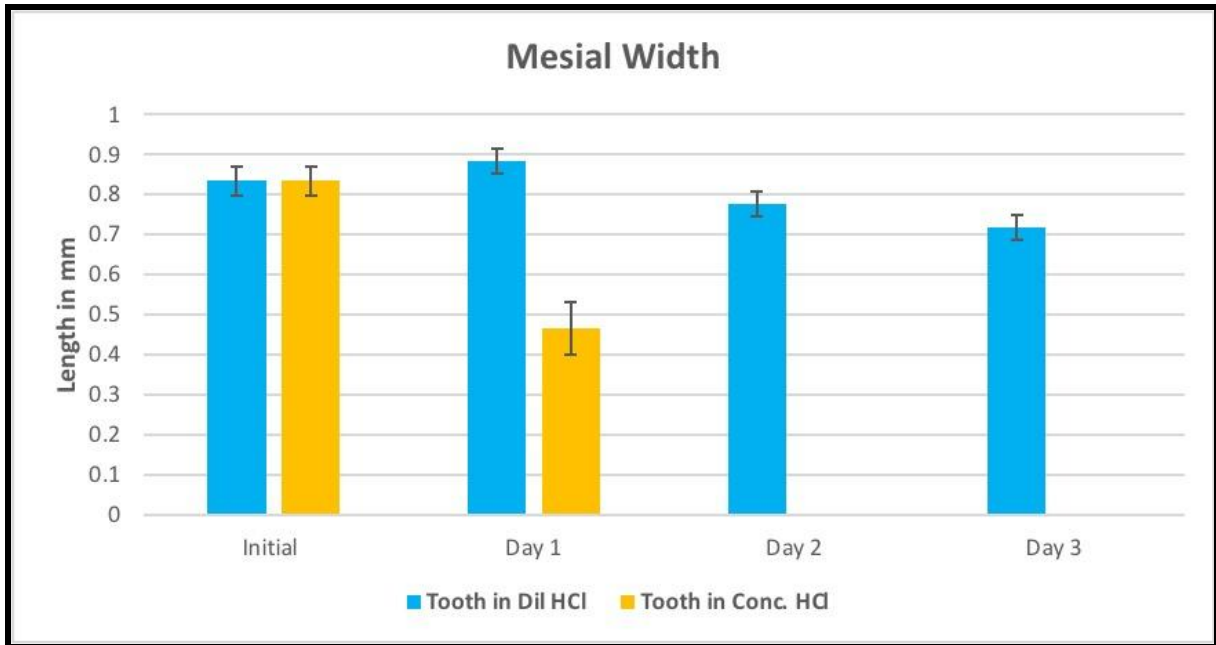


Figure 6: Figure shows the morphological changes observed in teeth after immersion in dilute and concentrated hydrochloric acid in the mesial aspect of immersed teeth. In this x-axis stands for the number of days with respect to tooth immersed and y-axis stands for length of tooth in millimeters. Blue colour represents the tooth in dilute hydrochloric acid and yellow colour represents the tooth in concentrated hydrochloric acid. A statistically significant decrease in the mesial width was observed in the teeth immersed in both concentrated and dilute hydrochloric acid.

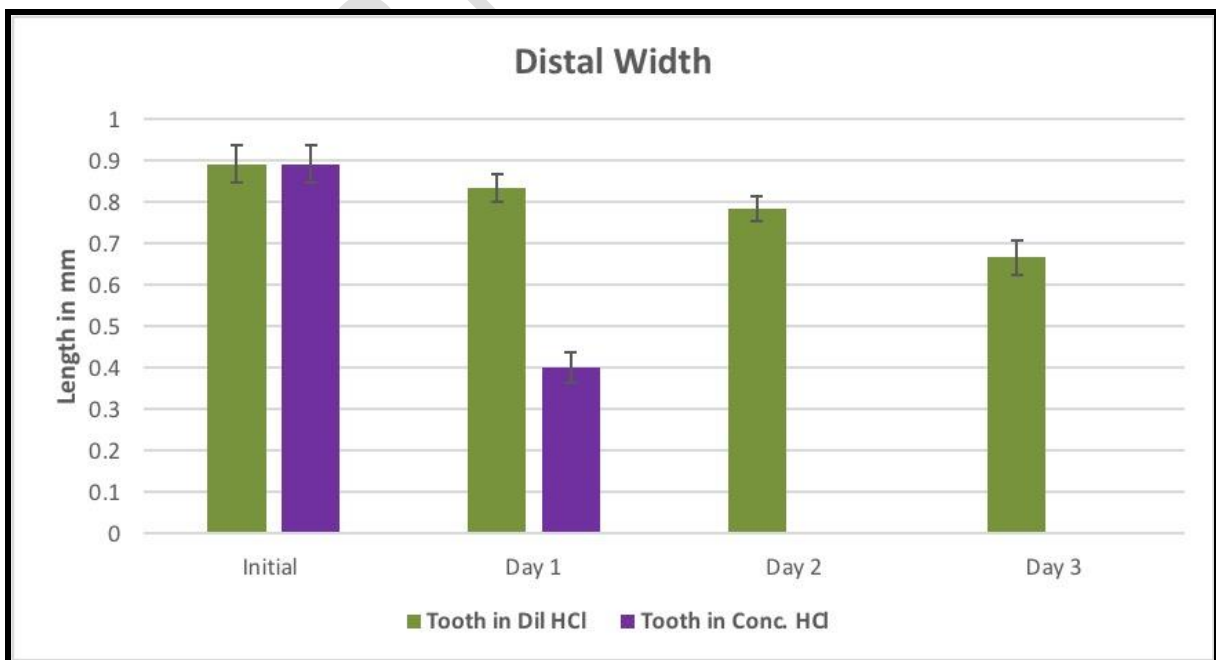


Figure 7: Figure shows the morphological changes observed in teeth after immersion in dilute and concentrated hydrochloric acid in the distal aspect of immersed teeth. In this x-axis stands for the number of days with respect to tooth immersed and y-axis stands for length of tooth in millimeters. Green colour represents the tooth in dilute hydrochloric acid and purple colour represents the tooth in concentrated hydrochloric acid. A statistically significant decrease in the distal width was observed in the teeth immersed in both concentrated and dilute hydrochloric acid.

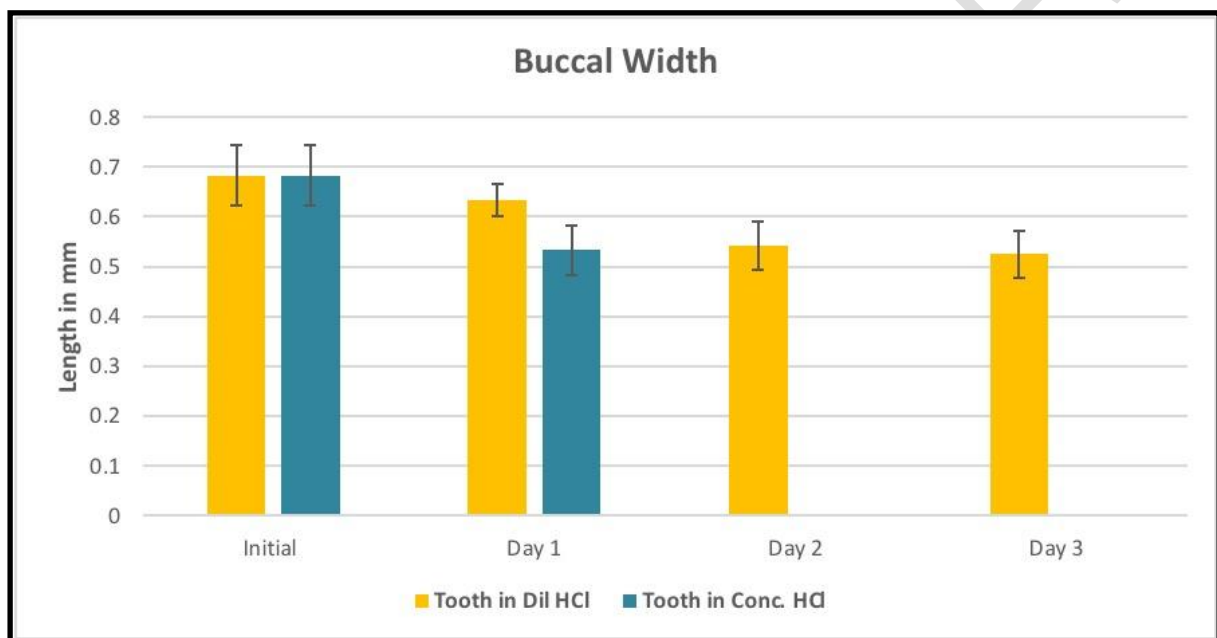


Figure 8: Figure shows the morphological changes observed in teeth after immersion in dilute and concentrated hydrochloric acid in the buccal (CEJ) aspect of immersed teeth. In this x-axis stands for the number of days with respect to tooth immersed and y-axis stands for length of tooth in millimeters. Yellow colour represents the tooth in dilute hydrochloric acid and blue colour represents the tooth in concentrated hydrochloric acid. A statistically significant decrease in the buccal width was observed in the teeth immersed in both concentrated and dilute hydrochloric acid.

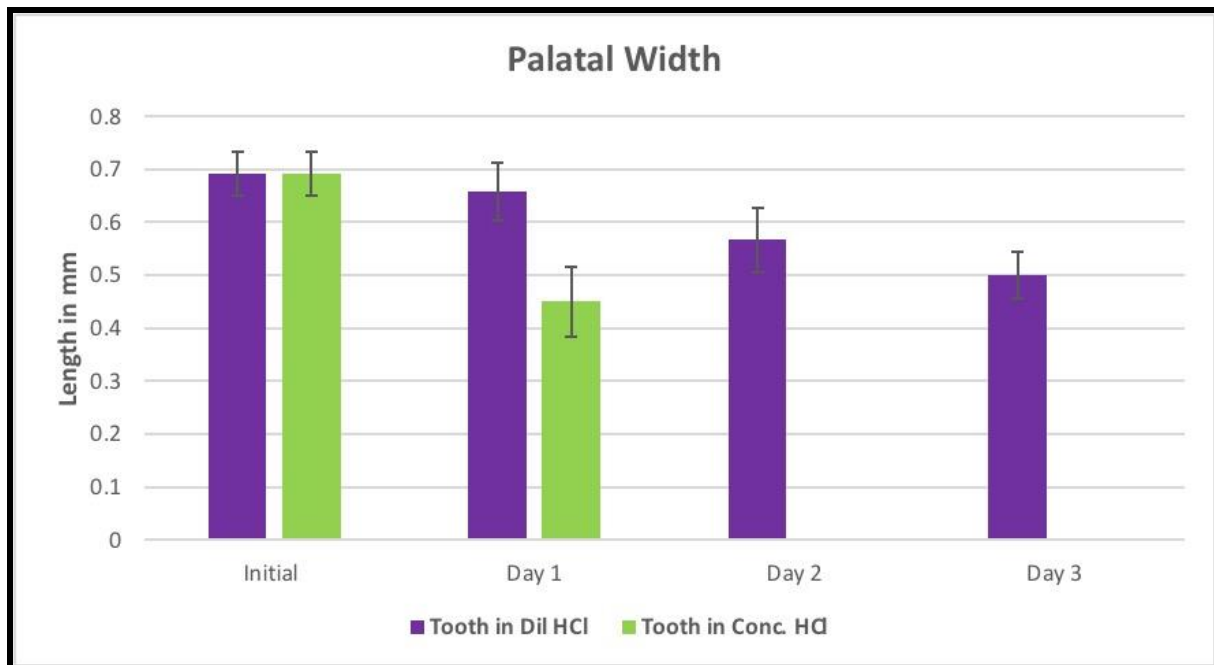


Figure 9: Figure shows the morphological changes observed in teeth after immersion in dilute and concentrated hydrochloric acid in the palatal (CEJ) aspect of immersed teeth. In this x-axis stands for the number of days with respect to tooth immersed and y-axis stands for length of tooth in millimeters. Purple colour represents the tooth in dilute hydrochloric acid and green colour represents the tooth in concentrated hydrochloric acid. A statistically significant decrease in the palatal width was observed in the teeth immersed in both concentrated and dilute hydrochloric acid.

Discussion

Identification of teeth with the help of unique characters in a population has been around for a long time like the Romans used to do. Teeth undergo erosion when the pH of the oral cavity is less than 3.5. Consumption of beverages having acid buffers cannot be produced by the mouth immediately and leads to acid erosion of the tooth (28). Erosion of enamel is of intrinsic origin (29,30). Features which are morphological assists any investigator or forensic scientist in understanding the tooth whether it is from any human or originated from animals, single rooted or multi-rooted, deciduous or permanent.

HCl solution showed that the tooth was dissolving within 3 to 5 hours itself and completely dissolved within 8 hours(1,31) showed and reported that few deep cracks developed in the tooth in around 30 minutes, and the tooth dissolution started in 1 hour, the tooth was

completely dissolved in 8 hours. Jadhav et al (2009)² used diluted acid for their study and showed that the tooth became translucent and then transparent in stages. Further breakdown of apical 3rd and adjacent to complete dissolution took place in 2 and 8 hours respectively(1)

Acids are capable of etching enamel at either high or low concentrations. Because Enamel is composed of 96% inorganic material which undergoes acid destruction. In other studies different patterns of varying depth were produced based on the type of concentration of acid taken as well as the etching time(32). Use of forensic sciences comprises person or victim identification. Destroying the evidence involving dead bodies by immersing it into concentrated inorganic acids is one of methods used by criminals(4,32). Some limitations of this study were less sample size, limited time period and usage of the limited concentrations of hydrochloric acid. This study is really helpful to the forensic odontology and other forensic departments as by observing the morphological changes in the teeth, it is possible to conclude which acid has been used by the criminals to destroy the body and the time elapsed after body immersion in acid to some extent.

Conclusion :

This study shows that most durable teeth also undergo erosion and dissolution when placed in dilute HCl and concentrated HCl. In some cases the acid that may be used by criminals for destruction of a human body and to find out the approximate time taken for total destruction of a body when immersed in an acid. This study on morphological changes helps in forensic sciences. Further studies with different types of acids on tissues and bones may be carried out to analyse its effect on the tissues, which may further be helpful in indepth forensic sciences.

References

1. Raj M, Boaz K, Srikant N. Are teeth evidence in acid environment [Internet]. Vol. 5, Journal of Forensic Dental Sciences. 2013. p. 7. Available from: <http://dx.doi.org/10.4103/0975-1475.114536>
2. Kumar P, Arshi J, Satish B, Basnaker M, Puranik S. Are teeth an adjunctive for age estimation in acid environment? [Internet]. Vol. 2, International Journal of Forensic Odontology. 2017. p. 22. Available from: http://dx.doi.org/10.4103/ijfo.ijfo_1_17

3. Jadhav K, Gupta N, Mujib AR, Amberkar V. Effect of acids on the teeth and its relevance in postmortem identification [Internet]. Vol. 1, *Journal of Forensic Dental Sciences*. 2009. p. 93. Available from: <http://dx.doi.org/10.4103/0974-2948.60381>
4. Seethapathy T, Shylaja S, Sekhar MSM, Manthapuri S, Ramanand OV, Reddy SK, et al. Effect of Acids on Teeth and Restorative Materials: An Aid in Forensic Odontology [Internet]. Vol. 28, *Journal of Hard Tissue Biology*. 2019. p. 21–30. Available from: <http://dx.doi.org/10.2485/jhtb.28.21>
5. Sankeertimala, Sankeertimala. Racial, Occupational, and Cultural Variations in Human Teeth: Teeth as Evidence in Forensic Identification [Internet]. Vol. 4, *International Journal of Forensic Odontology*. 2019. p. 7. Available from: http://dx.doi.org/10.4103/ijfo.ijfo_1_19
6. Mesquita-Guimarães KSF de, de MESQUITA-GUIMARÃES KSF, Scatena C, Borsatto MC, Rodrigues-Júnior AL, Serra MC. Effect of foods and drinks on primary tooth enamel after erosive challenge with hydrochloric acid [Internet]. Vol. 29, *Brazilian Oral Research*. 2015. Available from: <http://dx.doi.org/10.1590/1807-3107bor-2015.vol29.0096>
7. Wiegand A, Bliggenstorfer S, Magalhaes AC, Sener B, Attin T. Impact of the in situ formed salivary pellicle on enamel and dentine erosion induced by different acids. *Acta Odontol Scand*. 2008 Aug;66(4):225–30.
8. Wu F, Zhu J, Li G, Wang J, Veeraraghavan VP, Krishna Mohan S, et al. Biologically synthesized green gold nanoparticles from Siberian ginseng induce growth-inhibitory effect on melanoma cells (B16). *Artif Cells Nanomed Biotechnol*. 2019 Dec;47(1):3297–305.
9. Chen F, Tang Y, Sun Y, Veeraraghavan VP, Mohan SK, Cui C. 6-shogaol, a active constituents of ginger prevents UVB radiation mediated inflammation and oxidative stress through modulating Nrf2 signaling in human epidermal keratinocytes (HaCaT cells). *J Photochem Photobiol B*. 2019 Aug;197:111518.
10. Li Z, Veeraraghavan VP, Mohan SK, Bolla SR, Lakshmanan H, Kumaran S, et al. Apoptotic induction and anti-metastatic activity of eugenol encapsulated chitosan nanopolymer on rat glioma C6 cells via alleviating the MMP signaling pathway [Internet]. Vol. 203, *Journal of Photochemistry and Photobiology B: Biology*. 2020. p. 111773. Available from: <http://dx.doi.org/10.1016/j.jphotobiol.2019.111773>
11. Babu S, Jayaraman S. An update on β -sitosterol: A potential herbal nutraceutical for diabetic management. *Biomed Pharmacother*. 2020 Nov;131:110702.
12. Malaikolundhan H, Mookkan G, Krishnamoorthi G, Matheswaran N, Alsawalha M, Veeraraghavan VP, et al. Anticarcinogenic effect of gold nanoparticles synthesized from *Albizia lebbek* on HCT-116 colon cancer cell lines. *Artif Cells Nanomed Biotechnol*. 2020 Dec;48(1):1206–13.
13. Han X, Jiang X, Guo L, Wang Y, Veeraraghavan VP, Krishna Mohan S, et al. Anticarcinogenic potential of gold nanoparticles synthesized from *Trichosanthes kirilowii* in colon cancer cells through the induction of apoptotic pathway. *Artif Cells*

Nanomed Biotechnol. 2019 Dec;47(1):3577–84.

14. Gothai S, Muniandy K, Gnanaraj C, Ibrahim IAA, Shahzad N, Al-Ghamdi SS, et al. Pharmacological insights into antioxidants against colorectal cancer: A detailed review of the possible mechanisms. *Biomed Pharmacother*. 2018 Nov;107:1514–22.
15. Veeraraghavan VP, Hussain S, Balakrishna JP, Dhawale L, Kullappan M, Ambrose JM, et al. A Comprehensive and Critical Review on Ethnopharmacological Importance of Desert Truffles: *Terfezia claveryi*, *Terfezia boudieri*, and *Tirmania nivea* [Internet]. *Food Reviews International*. 2021. p. 1–20. Available from: <http://dx.doi.org/10.1080/87559129.2021.1889581>
16. Sathya S, Ragul V, Veeraraghavan VP, Singh L, Niyas Ahamed MI. An in vitro study on hexavalent chromium [Cr(VI)] remediation using iron oxide nanoparticles based beads. *Environmental Nanotechnology, Monitoring & Management*. 2020 Dec 1;14:100333.
17. Yang Z, Pu M, Dong X, Ji F, Priya Veeraraghavan V, Yang H. Piperine loaded zinc oxide nanocomposite inhibits the PI3K/AKT/mTOR signaling pathway via attenuating the development of gastric carcinoma: In vitro and in vivo studies. *Arabian Journal of Chemistry*. 2020 May 1;13(5):5501–16.
18. Rajendran P, Alzahrani AM, Rengarajan T, Veeraraghavan VP, Krishna Mohan S. Consumption of reused vegetable oil intensifies BRCA1 mutations. *Crit Rev Food Sci Nutr*. 2020 Oct 27;1–8.
19. Barma MD, Muthupandiyam I, Samuel SR, Amaechi BT. Inhibition of *Streptococcus mutans*, antioxidant property and cytotoxicity of novel nano-zinc oxide varnish. *Arch Oral Biol*. 2021 Jun;126:105132.
20. Samuel SR. Can 5-year-olds sensibly self-report the impact of developmental enamel defects on their quality of life? *Int J Paediatr Dent*. 2021 Mar;31(2):285–6.
21. Samuel SR, Kuduruthullah S, Khair AMB, Shayeb MA, Elkaseh A, Varma SR. Dental pain, parental SARS-CoV-2 fear and distress on quality of life of 2 to 6 year-old children during COVID-19. *Int J Paediatr Dent*. 2021 May;31(3):436–41.
22. Tang Y, Rajendran P, Veeraraghavan VP, Hussain S, Balakrishna JP, Chinnathambi A, et al. Osteogenic differentiation and mineralization potential of zinc oxide nanoparticles from *Scutellaria baicalensis* on human osteoblast-like MG-63 cells [Internet]. Vol. 119, *Materials Science and Engineering: C*. 2021. p. 111656. Available from: <http://dx.doi.org/10.1016/j.msec.2020.111656>
23. Yin Z, Yang Y, Guo T, Veeraraghavan VP, Wang X. Potential chemotherapeutic effect of betalain against human non-small cell lung cancer through PI3K/Akt/mTOR signaling pathway. *Environ Toxicol*. 2021 Jun;36(6):1011–20.
24. Veeraraghavan VP, Periadurai ND, Karunakaran T, Hussain S, Surapaneni KM, Jiao X. Green synthesis of silver nanoparticles from aqueous extract of *Scutellaria barbata* and coating on the cotton fabric for antimicrobial applications and wound healing activity in fibroblast cells (L929). *Saudi J Biol Sci*. 2021 Jul;28(7):3633–40.

25. Mickymaray S, Alfaiz FA, Paramasivam A, Veeraraghavan VP, Periadurai ND, Surapaneni KM, et al. Rhaponticin suppresses osteosarcoma through the inhibition of PI3K-Akt-mTOR pathway. *Saudi J Biol Sci.* 2021 Jul;28(7):3641–9.
26. Teja KV, Ramesh S. Is a filled lateral canal – A sign of superiority? [Internet]. Vol. 15, *Journal of Dental Sciences.* 2020. p. 562–3. Available from: <http://dx.doi.org/10.1016/j.jds.2020.02.009>
27. Theertha M, Sanju S, Priya VV, Jain P, Varma PK, Mony U. Innate lymphoid cells: Potent early mediators of the host immune response during sepsis. *Cell Mol Immunol.* 2020 Oct;17(10):1114–6.
28. McCay CM, Will L. Erosion of Molar Teeth by Acid Beverages [Internet]. Vol. 39, *The Journal of Nutrition.* 1949. p. 313–24. Available from: <http://dx.doi.org/10.1093/jn/39.3.319>
29. West NX, Hughes JA, Addy M. The effect of pH on the erosion of dentine and enamel by dietary acids in vitro [Internet]. Vol. 28, *Journal of Oral Rehabilitation.* 2008. p. 860–4. Available from: <http://dx.doi.org/10.1111/j.1365-2842.2001.00778.x>
30. Alves M do SC, Mantilla TF, Bridi EC, Basting RT, França FMG, Amaral FLB, et al. Rinsing with antacid suspension reduces hydrochloric acid-induced erosion. *Arch Oral Biol.* 2016 Jan;61:66–70.
31. Viswanathan K, Gopinath VP, Raj GD. Formulation of Newcastle disease virus coupled calcium phosphate nanoparticles: an effective strategy for oculonasal delivery to chicken. *Colloids Surf B Biointerfaces.* 2014 Apr 1;116:9–16.
32. Smith GA. The effects of acid etching on enamel, dentine and inner surface of the resin restoration: a S.E.M. study [Internet]. Vol. 6, *Journal of Dentistry.* 1978. p. 355–6. Available from: [http://dx.doi.org/10.1016/0300-5712\(78\)90176-8](http://dx.doi.org/10.1016/0300-5712(78)90176-8)