

Original Research Article

Hepatoprotective effect of *Annona squamosa* linn. leaves on isoniazid & rifampin induced hepatotoxicity in rats

ABSTRACT

The goal of this investigation was to examine if an ethanolic extract of *Annona squamosa* has any hepatoprotective benefits in rats suffering from isoniazid-rifampin-induced hepatotoxicity.

Methodology: The rats were separated in five groups (n=6): group 1, a control; group 2 administered isoniazid (100 mg/kg, I.P.) & rifampin (100 mg/kg, I.P.) in sterile water; group 3 as a control & traditional silymarin, 2.5 mg/kg, B.W., P.O.; groups 4 & 5 are treated & received 200 & 400 mg/kg, B.W., P.O., ethanolic extract of AS. All of the treatment procedures were monitored for a total of 21 days after the rats were slaughtered & Biochemical & histological investigations were performed on the blood & liver respectively.

Results: Rats (T2) treated with Rifampin (RIF) & isoniazid (INH) elevated their blood serum glutamic oxaloacetic transferase (SGOT), glutamic pyruvic transaminase (SGPT) & alkaline phosphatase (ALP) levels during a variety of ways. The consumption of ethanolic extracts of *Annona squamosa* considerably reduced Rifampin & Isoniazid induced elevations in serum diagnostic liver marker enzymes. SGOT, SGPT & ALP are the three involved enzymes. Furthermore, the medical care groups had significantly larger total macromolecule & total albumen levels. The extract result was compared thereto of Silymarin, a standard medication. The histological profile backed up the changes in biochemical markers. An ethanolic extract of *Annona squamosa* has been discovered to protect rats from oxidative liver injury caused by rifampin & isoniazid.

Conclusion: The ethanolic extract of AS protects rats from isoniazid & rifampin induced oxidative liver injury.

Keywords: *Annona Squamosa*, Hepatotoxicity, Isoniazid, Oxidative stress, Rifampin.

INTRODUCTION

Tuberculosis is a granulomatous, chronic illness causing a serious problem in developing countries. The first-line treatments for tuberculosis are isoniazid, rifampin, pyrazinamide, Ethambutol & streptomycin [1].

Drug-induced liver toxicity could be a current reason behind liver injury. It causes about half of all occurrences of acute liver failure & can be mistaken for a variety of acute & chronic illnesses [2]. Numerous medicines adore acetaminophen, chloroquine & isoniazid are illustrious to cause hepatotoxicity in humans. Isoniazid & rifampin, the first-line medications for tuberculosis treatment, have been linked to hepatotoxicity [3]. A comparable dose schedule the rate of hepatotoxicity has been reported to be significantly greater in developing nations such as, India (8 - 30%) than in developed countries (2 - 3 %) [4]. Recent investigations have found a clear link between liver damage & oxidative stress in experimental animals given anti-tuberculosis medications. Subsequently, all medications accustomed treat infectious disease are found to possess toxic effects. Natural herbal prescribed medications & or manufactured substances have been used in studies to avoid or lessen toxicity while not interfering with the therapeutic effects of the drugs.

Garlic, silymarin, N-acetylcysteine & a variety of other natural remedies have all been demonstrated to have similar effects. It's worth mentioning that CYP450, 2E1 inhibition, as well as antioxidant properties, are all important. It appears that they are linked in some way to be the most extensively used action technique for herbal medications [5].

Annona squamosa (annonaceae) is known as custard apple in English & sharifa in Hindi. [6]. This plant is said to have a variety of therapeutic qualities including insecticidal action [7], free radical scavenging activity [8], hypoglycemic & anti-diabetic activities [9]. Many bioactive components were extracted from the bark & leaves of this plant including acetogenin [10], flavonoids [11], aporphine, alkaloids [12], glycoside [13], & squamoline [14]. The purpose of this research was to recognize the preventive benefits of an ethanolic extract of *Annona squamosa* leaves (EEAS) against isoniazid & rifampin induced hepatotoxicity.

2. INGREDIENTS & PROCEDURES

2.1. Collecting plant matter & preparation of the extract

Annona squamosa leaves were obtained in Ananthapuram, (Dt.), Andra Pradesh, in February, 2021. Botanical identification of the plant was done by Dr. K. Madhava Chetty, Department of Botany, S.V. University, Tirupati. Voucher specimen (0855-02/2021) was submitted to parent department.

Leaves of custard apple were dried out, pulverized to obtain a coarse particle; 70g of dry powder were separated with ethanol using a soxhlet apparatus & continual hot permeation. On Rota fume under decreasing pressure the extract was concentrated to a maximum of 100 milliliters. The concerted rough removal (12 g) was powdered & used for this study.

2.2. Animals in Research

Male Wistar albino rats weighing between 150 & 200 grams were procured from Raghavendra Institute of Pharmaceutical Education & Research. The Animal Ethical Committee of the Institute granted the project its seal of approval (IAEC/XIV/03/RIPER/2019). Rats were kept at a temperature of 25°C & a relative humidity of 45–55 % with 12 hours of the cycles of darkness & light and received food & drinks in granulate form ad libitum.

2.4. Chemicals:

Isoniazid & rifampin were acquired in pure form from Micro Labs in India. Total albumin, Total Protein, Alkaline phosphatase (ALP), Serum Glutamic Pyruvic Transaminase (SGPT), & Serum Glutamic Oxaloacetic, transaminase (SGOT) were all measured using diagnostic kits as of Ranbaxy in New Delhi. All of the medicines, compounds, & reagents utilized in the biological estimate remained given by Sigma-Aldrich in the United States.

2.5. Apparatuses:

Spectro Photometer (Analytical systems, Model No: 2371), Electronic Balance (SCALE - TEC), Colorimeter (ESICO, Model No:1311), Homogenizer (Ever Shine, Model No: 607), Centrifuge (REMI, Model No: R – 8C).

2.6. Phytochemical screening

Trease & Evans [15] examined the resulting ethanolic extract for the incidence of several biological elements such as saponins, flavonoids, glycosides, alkaloids, tannins & reducing sugar.

2.7. Pharmacological study

2.7.1. Stimulation, of, hepatotoxicity & Bio-chemical, studies

Isoniazid & Rifampin (100, mg/kg, B.W.) were prepared in solution, separately, sterilized, distilled & water, Isoniazid was given to the rats, which along with rifampin was obtained from I.P. [16]. The doses of 200 mg/kg B.W. [17] & 400 mg/kg B.W. [18] were employed to study the effects of an ethanolic extract of Annona, Squamosa in rats.

In this investigation, silymarin (2.5 mg/kg B.W.) was used as a standard medication [19]. The protocol dictates five groups of rats:

Group 1 - Normal, control. (n=6, rats were given just normal saline),

Group 2 - Hepatotoxic, control. (n=6, rats were, given, INH+RIF, for, 21, Days)

Group 3 - Standard group (n=6, rats were given INH+RIF+Silymarin for 21 days)

Group 4 - Treated group (n=6, rats were given INH+RIF+EEAS, 200mg for 21 days)

Group 5 - Treated group (n=6, rats were given INH+RIF+EEAS, 400mg for 21 days)

The rats were given the therapy according to the protocol. Over the course of 21 days, the body weights of these rats were measured in both control & experimental animals. On day 21, rats were sacrificed one hour after injection. Retro-orbital artery bleeding was used to collect the blood. To extract the serum from the blood samples, they were centrifuged at 3000 rpm for five minutes. The values of ALP, SGPT, SGOT, Total protein & Albumin were calculated from serum using standard kits [20]. The table contains the outcomes of the biochemical analysis.

2.7.2. Histopathology

The livers were quickly removed & kept in 10% formalin before being stained with haemotoxylin & eosin & studied under a microscope for degeneration, fatty modifications, necrotic changes & any signs of hepatotoxicity.

2.8. Statistical analysis

Results were presented as a Mean \pm Standard Error of Mean (SEM). ONEWAY ANOVA & Newman-multiple Keul's tests were used to conduct the statistical analysis.

3. RESULTS

Table 1. IMPACT OF EEAS ON SERUM ENZYMES

GROUPS	SGOT [u/l]	SGPT [u/l]	ALP [u/l]	TOTAL PROTEIN [gr./dl]	TOTAL ALBUMIN [gr./dl]
GROUP 1	145.15 \pm 6.60	76.23 \pm 4.42	121.32 \pm 6.32	8.23 \pm 0.32	4.82 \pm 0.23
GROUP 2	259.12 \pm 8.62 ^a	177.23 \pm 5.92 ^a	306.56 \pm 7.50 ^a	4.33 \pm 0.31 ^a	2.23 \pm 0.11 ^a
GROUP 3	177.02 \pm 6.24 ^b	83.86 \pm 6.92 ^b	204.15 \pm 6.48 ^b	7.86 \pm 0.67 ^b	4.62 \pm 0.25 ^b
GROUP 4	209.18 \pm 7.41 ^b	123.28 \pm 6.89 ^b	265.58 \pm 8.46 ^b	6.72 \pm 0.28 ^b	3.87 \pm 0.22 ^b

4					
GROUP - 5	197.28±9.26*b	104.25±6.45*b	259.23±9.86*b	7.32±0.21*b	4.22±0.32*b

All values are provided as mean, standard deviation & standard error of the mean (n=6).

- Values are expressed as Mean ± SEM.
- * (a) At p<0.01, the values were significantly different from the typical control.
- * (b) At p<0.01, the Values were significantly different from the toxic control.

3.1. Hepatoprotective activity

3.1.1. The Effect of *Annona Squamosa* on SGOT, SGPT & ALP Levels in Serum

Due to Rifampin (RIF), Isoniazid (INH) & serum SGOT levels in group 2 were considerably higher (p<0.01) than in Group 1 (control) but these levels were considerably lower (p<0.01) in Groups 3, 4, & 5 treated with Silymarin & *Annona Squamosa* at doses of 200 & 400 mg/kg.

Rifampin (RIF) & Isoniazid (INH) significantly elevated (p<0.01) serum SGPT levels in Group 2 compared to Group 1; while these levels were considerably lower (p<0.01) in the other ones given Silymarin & *Annona Squamosa* at dosages of 200 & 400 mg/kg.

Rifampin (RIF) & Isoniazid, (INH) significantly increased (p<0.01), serum ALP level in Group - 2 compared to Group -1, however these levels were considerably lower in the other groups treated with Silymarin & *Annona Squamosa* at doses of 200 & 400 mg/kg.

3.1.2., The effects of *Annona Squamosa* on blood total protein & serum total albumin levels

The findings demonstrated that Rifampin (RIF) & Isoniazid (INH) caused a considerable decrease in the number of those who got sick (p<0.05). Serum levels, total protein, & total albumin in Group 2 compared to Group 1 by rifampin (RIF) & isoniazid (INH) were substantially, higher.

3.2. Histopathological examination

Histopathological examination of liver sections is as shown in Fig. A. The normal group showed normal cellular architecture with distinct, hepatic cells, sinusoidal spaces & central veins (Fig., C). INH & RIF poisoned rats showed a disturbance of normal liver cells with centrilobular necrosis, congestion of the central vein, cytoplasmic vacuolisation & fat degeneration. (Fig. A). The liver sections of the rats treated with ethanolic extracts of *Annona Squamosa* & silymarin followed by INH & RIF intoxication, exhibited a sign of protection as it was obvious for the absence of necrosis with

regeneration changes at the central vein in the liver tissue (Fig. B, D, & E).

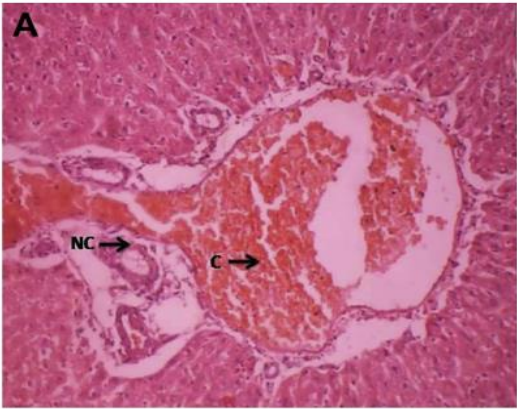


Fig. A. Hepatocytes of toxic control rat

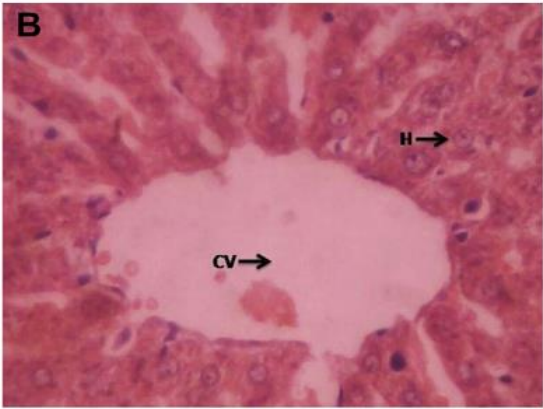


Fig. B. Hepatocytes of standard rat

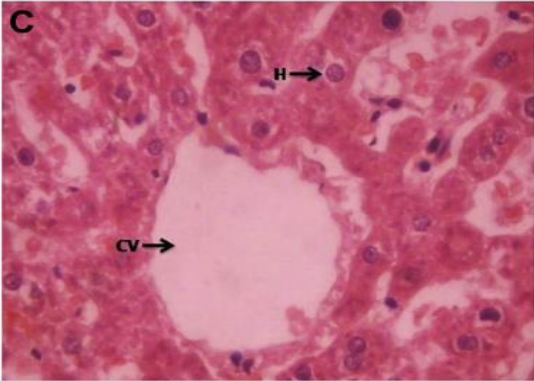


Fig. C. Hepatocytes of normal rat

- Abbreviations used in Figure 1
- CV Central vein
 - H Hepatocytes
 - N Nucleus
 - C Congestion
 - NC Necrotic Change

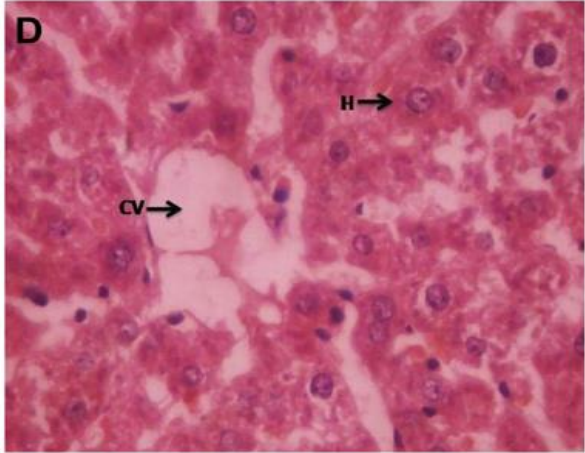


Fig. D. Hepatocytes of EEAS (Low dose)

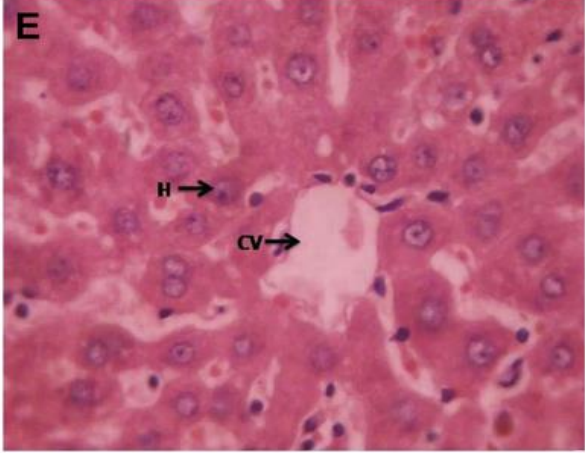


Fig. E. Hepatocytes of EEAS (High dose)

4. DISCUSSION

Anti-TB medications (isoniazid, rifampin, & pyrazinamide) are potentially hepatotoxic when used alone [21], but when used together, their toxic effect is amplified in a synergistic way. The current study employs a combination of anti-TB medications as a tool for inducing hepatotoxicity in experimental animals [22]. Although the specific mechanisms of hepatotoxicity caused by these medicines are unknown, numerous studies have postulated that hepatotoxicity is mediated by the production of reactive/toxic metabolites that bind covalently to liver cell macromolecules causing liver injury [23]. Second cytochrome P450 2E1 is involved in hepatic damage induction [24]. The third reason is oxidative stress caused by the generation of free radicals, which are a source of cell membrane breakdown & damage [25].

In this study, the hepatoprotective activity of *A. squamosa* were detected, in Rifampicin (RIF) & Isoniazid (INH) prompted hepatotoxicity in rats. Substantial increases in serum SGOT, SGPT & ALP as well as significant decreases in total protein & total albumin were reported in the second group given Rifampin (RIF) & Isoniazid (INH), compared to the first one given normal saline.

Any hepatoprotective drug's efficacy depends on its ability to either reduce the adverse effect or restore a hepatotoxin has disrupted, the normal hepatic physiology. The low dose group & the high dose group both lowered INH & RIF certain raised enzyme levels indicating the protection of hepatocytic cell membrane, structural integrity or the regeneration of wounded liver cells.

all tested groups, i.e., low & high dosage treatment, showed dose dependent hepatoprotective effect. The tested groups that included only the plant extract showed an increase in liver activity. It clearly demonstrates that *A. squamosa* possesses hepatoprotective properties.

5. Conclusion

The ethanolic extract of *Annona squamosa* has presented dose-dependent efficacy in experimental rats against INH & RIF caused hepatic damage. The custard apple's hepatoprotective effect was further confirmed by histological studies. Further, research into potential protective properties of this plant against anti tubercular drug induced hepatic injury might have a significant impression on creating therapeutically feasible strategies to treat patients with hepatotoxicity.

9. DATA AVAILABILITY: All datasets generated or analyzed during this study are included in the manuscript

NOTE:

The study highlights the efficacy of "herbal" which is an ancient tradition, used in some parts of India. This ancient concept should be carefully evaluated in the light of modern medical science and can be utilized partially if found suitable.

10. REFERENCES

1. Tripathi K D. Antitubercular drugs In: Essential of Medical Pharmacology. 8th ed. Jaypee Brothers Medical publication; 2019.p 815.
2. Kaplowitz N (2001). Drug-induced liver disorders: Implications for drug development & regulation. *Drug. Saf.*, **24**: 483-490.
3. Tasduq SA, Peerzada K, Koul S, Bhat R & Johri RK (2005). Biochemical manifestation of anti-tuberculosis drugs induced hepatotoxicity & the effect of Silymarin. *Hepatol. Res.*, **31**: 132-135.
4. Sharma SK (2004). Antituberculosis drugs & hepatotoxicity. *Infect. Genet. Evol.*, **4**: 167-170.
5. Sude E, Fikriye U & Fikret (2008). Silymarin protects liver against toxic effects of anti-tuberculosis drugs in experimental animals. *Nutr. Metb. (Lond)*. **5**: 18.
6. Morton J (1987). Sugar apple. *Fruits. Warm. Climate*, 69- 72.
7. Cheema PS, Dixit RS, Koshi T & Perti SL (1985). Insecticidal properties of the seed oil of *Annona squamosa* Linn. *J. Sci. Ind. Res.*, **17**: 132.
8. Shirwaikar A, Rajendran K & Kumar CD (2004). In vitro antioxidant studies of *Annona squamosa* Linn leaves. *Ind. J. Exp. Biol.*, **42**: 803-807.
9. Gupta RK, Kesari AN, Murthy PS, Ch&ra R, T&on V & Watal G (2005). Hypoglycemic & antidiabetic effect of ethanolic extract of leaves of *Annona squamosa* L. in experimental animals. *J. Ethnopharmacol.* **99**(1): 75-81.
10. Hopp DC, Alali FQ, Gu ZM & McLaughlin JL (1998). Mono-THF ring annonaceous acetogenins from *Annona squamosa*. *Phytochemistry*, **47**: 803-809.
11. Seetharaman TR (1986). Flavonoids from the leaves of *Annona squamosa* & *Polyalthia longifolia*. *Fitoterapia*. **57**: 189-198

12. Bhakuni DS, Tewari S & Dhar MM (1972). Aporphine alkaloids of *Annona squamosa*. *Phytochemistry*, **11**: 1819-1822.
13. Forgacs P, Desconclois JF, Provost R & Touche TA (1980). Un Nouvel Heteroside Nitre Extrait D' *Annona squamosa*. *Phytochemistry*. **19**: 1251-1252.
14. Yang TH & Chi-Ming C (1972). Structure of squamolone, a novel diazepine from *Annona squamosa* L. *J. Chin. Chem. Soc.*, **19**: 149-151.
15. Trease GE & Evans MC (1989). *Text-book of Pharmacognosy*. London: Bailliere Tindall, 200-201, 340-348, 419-423, 626-630, 765-775.
16. Jiang YUE, Ren-xiu PENG, Jing YANG, Rui KONG, Juan LIU. 2004. CYP2E1 mediated isoniazid-induced hepatotoxicity in rats. *Acta Pharmacol Sin* 25(5):699-704.
17. Gupta RK, Kesari AN, Murthy PS, Ch&ra R, T&on V, Watal G. 2005. Hypoglycemic & antidiabetic effect of ethanolic extract of leaves of *Annona squamosa* L. in experimental animals. *J Ethnopharmacol* 99(1):75-81.
18. Kaleem M, Asif M, Ahmed Q.U, Bano B. 2006. Antidiabetic & antioxidant activity of *Annona squamosa* extract in streptozotocin-induced diabetic rats. *Singapore Med J* 47(8):670-675.
19. arthasarathy R, Nivethetha M, Brindha P. 2007. Hepatoprotective activity of *Caesalpinia bonducella* seeds on paracetamol induced hepatotoxicity in male albino rats. *Indian Drugs* 44(5):401-404.
20. Rajesh KG, Achyut NK, Geeta W, Murthy PS, Ramesh C, Vibha T. 2005. Nutritional & Hypoglycemic Effect of Fruit Pulp of *Annona squamosa* in Normal Healthy & Alloxan-Induced Diabetic Rabbits. *Ann Nutr Metab* 49:407-413
21. Kaneko, Nagayama N, Kawabe Y, Shimada M, Suzuki J & Kunogi M *et al*. Drug induced hepatotoxicity caused by antituberculous drugs in tuberculosis patients complicated with chronic hepatitis, *Kekkaku*. 2008; 83: 13-9. PMID:18283910
22. Saraswathy SD, Suja V, Gurusurthy & Shyamala devi CS. Effect of Liv.100 against anti-tuberculosis drugs (isoniazid, rifampin & pyrazinamide) induced hepatotoxicity in rats. *Indian J Pharmacol*. 1998;30: 233.
23. Noda A, Hso KY, Noda H, Yamamoto Y & Kurozumi T. Is isoniazid- hepatotoxicity induced by the metabolite, hydrazine. *JUOEH*. 1983; 5: 183-90. PMID:6679629
24. Salem TSM, Christina AJM, Chidambaranathan N, Ravi V & Gauthaman K. Hepatoprotective activity of *Annona Squamosa* Linn. On experimental animal model. *Int. J. Appl. Res. Nat. Pro*. 2008; 1(3): 1-7.
25. Evans IS, Sahar ME, Mabrouka OS & Azza EB. Role of oxidative stress & nitric oxide in the protective effects of lipoic acid & aminoguanide against isoniazid –rifampin induced hepatotoxicity in rats. *Food chem. Toxicol*. 2010; 48: 1869-1875. <http://dx.doi.org/10.1016/j.fct.2010.04.026> PMID:204

UNDER PEER REVIEW