

# **“Reconstruction of Interdental Papilla in Esthetic Zone using Hyaluronic Acid Gel: A Clinical Prospective Study”**

## **Abstract**

Introduction: Interdental papilla deficiency or black triangles are considered to be one of the most challenging dilemmas in esthetic dentistry. Various invasive techniques with less success have been introduced for interdental papilla regeneration. So, to overcome the limitations a non-invasive technique with greater predictability and patient comfort has been introduced using Hyaluronic acid gel (HA). In the present study, the efficacy of 2% Hyaluronic acid gel on interdental papilla enhancement was evaluated clinically along with photographic analysis (Image J Software) and its effect on gingival fibroblast cell culture lines was observed.

Aim: To evaluate the changes in buccal triangle dimensions i.e. buccal triangle area (BTA), buccal triangle width (BTW), buccal triangle height (BTH) at baseline and 6 months using commercially available 2% HA gel and to check the effect of HA on proliferative abilities of gingival fibroblast cell culture lines.

Material and methods: 60 sites in 15 patients were selected and were randomly divided into test and control group. The Test Group received commercially available 2% HA gel and the control group received saline as a placebo. All the clinical measurements, photographs were taken at 3 weeks, 3 months and 6 months and comparisons among test and control groups were done both for clinical measurements and Image J analysis of photographs for interdental papilla enhancement. MTT assay and XTTT assay was done to check the effect of 2% HA gel on proliferative abilities of gingival fibroblast in cell culture lines.

Results: HA treated sites showed gradual and constant improvement in interdental papilla enhancement while the control sites did not show any improvement. Complete interdental papilla reconstruction was seen in 63.3% of test sites at 6 months and 365 of test sites showed partial interdental papilla reconstruction. HA gel has a positive effect on the proliferative and migratory abilities of gingival fibroblast.

Conclusion: HA is a noninvasive volumizing alternative treatment modality for interdental papilla deficiency. It is biocompatible as it does not cause an adverse reaction. HA gel has a strong effect on the migratory and proliferative abilities of gingival fibroblasts.

Key words: Hyaluronic acid gel (HA), Black Triangles, Gingival Fibroblasts, Interdental papilla

## **INTRODUCTION**

In our modern competitive society, a pleasing appearance often means the difference between success and failure in both our personal and professional lives. Dental esthetics is much of concern nowadays due to increased cosmetic demands driven by enhanced patient awareness of aesthetics. The assessment of the relationship between white and pink tissue forms the key element of diagnosis and treatment planning in cosmetic dentistry. A deficiency in interdental papillae creates problems with pronunciation, phonetics, food impaction, along other aesthetic issues. The complex anatomy of the interdental area combined with the vascular supply allows for periodontal disease to progress rapidly causing loss of interdental papilla and formation of black triangles. Several efforts have been undertaken to restore and treat the missing papilla. If the loss of the papilla is caused by severe periodontal disease with interproximal bone resorption, complete reconstruction is difficult to achieve. Complex periodontal plastic procedures along with restorative intervention can enhance outcomes but rarely can achieve ideal results. Various complex surgical techniques and flap designs have been proposed for the reconstruction of the interdental papilla with limited success.<sup>1</sup> However, these techniques are mostly invasive and they fail to achieve long-term stability and predictability. Thus the use of a non-invasive technique involving the use of Hyaluronic acid gel (HA) with immediate results has been proposed. Hyaluronic acid is a mucopolysaccharide, occurring naturally in all living organisms.

HA has been investigated as a drug delivery agent for various administration routes, including ophthalmic, nasal, pulmonary, parenteral and topical.<sup>2</sup> The most important function of hyaluronic acid is its involvement in tissue healing and repair. This material stimulates cell proliferation, migration and angiogenesis, re-epithelialization and proliferation of the basal keratinocytes.<sup>1,3</sup> It can be used as an effective medication for the treatment of gingivitis, enhancement of tooth extraction socket healing and treatment of recurrent aphthous ulcers. The potential of a Hyaluronic acid gel injection to augment the volume of interdental papilla and reduce the black

triangle has not been evaluated in a controlled clinical study.<sup>4</sup> HA is a special glycosaminoglycan and an interesting biomolecule. Biomolecules used in dental application are mainly intended to regenerate soft tissues, also used as a barrier between soft and hard tissues and wound healing. The dental procedures related to regeneration (for soft and hard tissue) and wound healing are broadly divided into two groups:

- 1) Surgical Procedures including treatment for sinus lifting, periodontitis, bone grafting, gingival recession, and socket preservation.
- 2) Non-surgical procedures including treatment for papillae regeneration, non-surgical treatment for periodontitis, mouth ulcers, and gingivitis.<sup>4</sup>

For both (surgical and non-surgical procedures) and in relation to regeneration and wound healing, four major factors are needed for optimum outcomes:

- 1) Viable cells as building blocks.
- 2) The trigger or chemical signal to start and stop the cellular processes.
- 3) Angiogenesis to supply needed nutrients and eliminate cellular waste.
- 4) Scaffold as a cast for cells to grow in 3D.<sup>5</sup>

Many commercially available preparations of HA derivatives and cross-linked HA materials have been developed for drug delivery. Today HA is widely used in many branches of medicine with interesting potential applications in dentistry for the treatment of acute and chronic inflammatory disease. To the best of our knowledge, only handful of previous studies have used both clinical measurements and image analysis software to check for IDP enhancement. To overcome the lacunae in the previous studies, the present study was conducted to evaluate interdental papilla enhancement in interdental papillary deficiency area. Another highlight of the study was to check the effectiveness of 2% HA gel on gingival fibroblast cell proliferation, migration and cytotoxicity on cell cultures.

## **MATERIAL AND METHOD**

The research was carried out on systemically healthy, highly motivated adult individuals with an average age of  $37.5 \pm 14.4$  years (range 20- 61 years) with at least one anterior site with class I or class II interdental papilla loss according to Nordland and Tarnow classification (Figure 1), which were selected from the outpatient clinic, Department of Periodontology, FODS, SGT University .

The study was approved by institutional ethical board and an informed consent was taken from all the participants. In this experimental 6 months prospective study, sixty sites were recruited with 30 sites in test group (Hyaluronic acid gel) and 30 in control group (Placebo gel). The groups of participants were created, via random allocation, to receive either hyaluronic acid gel injection or saline injection as a placebo using a distance randomization method with 1:1 allocation ratio.

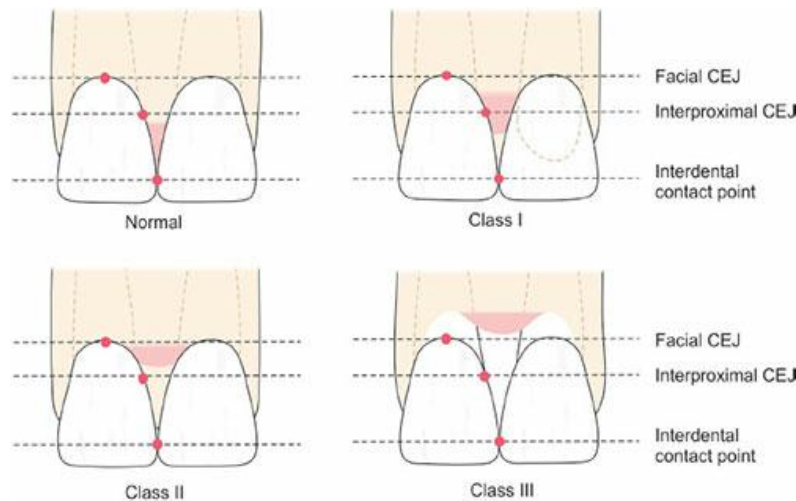
### **INCLUSION CRITERIA:**

- Possession of the maxillary anterior teeth
- Age range of 20-61 years
- At least 1 papillary deficient site in the upper anterior area
- Subjects who are non-smoker
- Non-contributory medical history
- No consumption of drugs causing gingival hyperplasia

### **EXCLUSION CRITERIA**

- Pregnant and lactating mothers
- History of allergic reaction to hyaluronic acid gel
- Parafunctional habits
- Currently receiving orthodontic treatment on the upper anterior area.

Interdental papilla was evaluated according to Nordland and Tarnow classification (**FIGURE 1**)



**FIGURE 1 Norland and Tarnow classification**

The treatment protocol was divided into 4 visits: Initial/first visit, Baseline (V1), at 3 weeks (V2) and at 3 months (V3), 6 months (V4).

**At first visit:**

A detailed case history including personal, medical and dental history was taken in the first visit of the patient. Phase I periodontal therapy was done. Patient was educated and motivated to maintain oral hygiene.

**V1/ Baseline:**

Only patients with deficient papillae were included in study. (FIGURE 2) Standardized digital photographs were taken perpendicular to the teeth of the interest. Measurement of the black triangle was done clinically from the tip of the papilla to the contact point of associated teeth using the periodontal probe and stent as a reference. (FIGURE 3) The value for 3 variables

BTA, BTW and BTH was measured from clinical photographs using image analysis software (ImageJ software). (FIGURE 4) The patient was allocated to the test group (HA) and control group (Saline) randomly.

After LA infiltration the deficient papilla was injected with 0.2 ml of HA gel in test group using a 30 gauge disposable insulin syringe (FIGURE 5) and in the control group 0.2ml of saline was administered using a 30 gauge disposable insulin syringe. Interdental papilla is a very confined space so it requires precise drug application. For this purpose, insulin syringe (BD ultrafine) 23 G needle was used. Then the papilla was massaged in the coronal direction for around 1 minute. Patient was discharged and was asked not to brush teeth on the day of injection and to resume it after 24 hours. Also patient was told not to floss in the treated area.

### **V2 at 3 weeks:**

Subsequent booster doses were given and follow up was done. Clinical photographs were taken and BTA, BTW and BTH was re-evaluated.

### **V3 at 3 months**

Subsequent booster doses were given and follow up was done. Clinical photographs were taken and BTA, BTW and BTH was re-evaluated.

### **V4/at 6 months:**

Follow up at 6 months was done to check the sustainability of the esthetic results and for final clinical measurement of black triangles and BTA, BTW, and BTH. When the final photographs were taken cases that showed no clinical signs of black triangle were categorized into CIPR (FIGURE 6) while the cases that still had a clinically observable black triangle were categorized as PIPR group (FIGURE 7). The obtained data was statistically analyzed using SPSS software.

## **CELL CULTURE**

Human gingival fibroblasts (HGF) were obtained from the repository of Maratha Mandal's NGH Institute of Dental Sciences and Research center, Belagavi, India. The cells were observed under

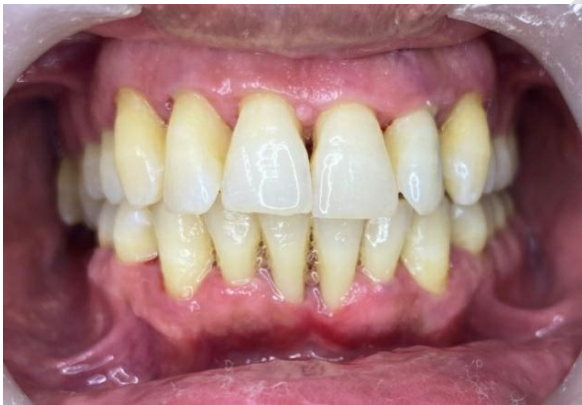microscope to check the contamination and kept in flask for overnight incubation. Next day, confluence was checked and trypsinization was performed to subculture cells in another flask. The sub cultured flask was used for MTT assay and XTT assay.

Formula: Surviving cells (%) = Mean OD of test compound /Mean OD of Negative control  $\times 100$  Using graph Pad Prism Version 5.1, we calculate the IC<sub>50</sub> of compounds.

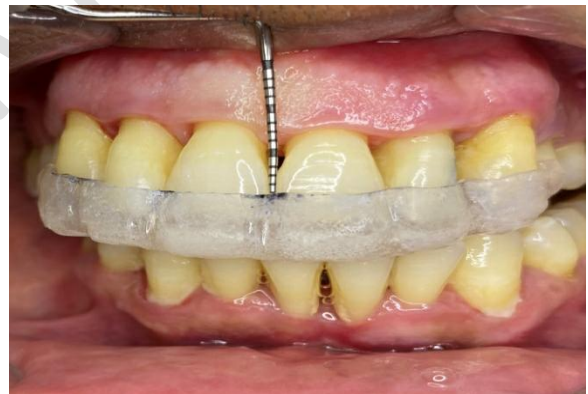### **CELL PROLIFERATION ASSAY**

Proliferation rates of HA treated HGF were determined using a 5-bromo-20 deoxyuridine (BrDU) incorporation assay (Roche, Basel, Switzerland). After 24 hours starvation cells were plated in a triplicate of  $2 \times 10^3$  cells/ well on 96 well plates coated with HA cells were allowed to proliferate for 0, 24, 48, and 72 hours before labeling with BrDU for 2 hours. BrDU incorporated into newly synthesized DNA was determined according to manufacturer's instructions. The gingival fibroblast cell culture lines were then evaluated for cellular proliferation and migration.

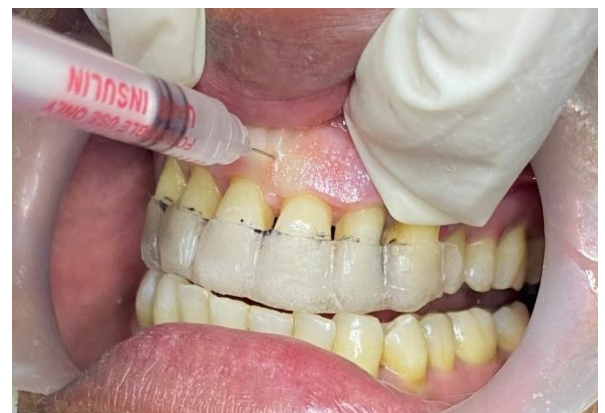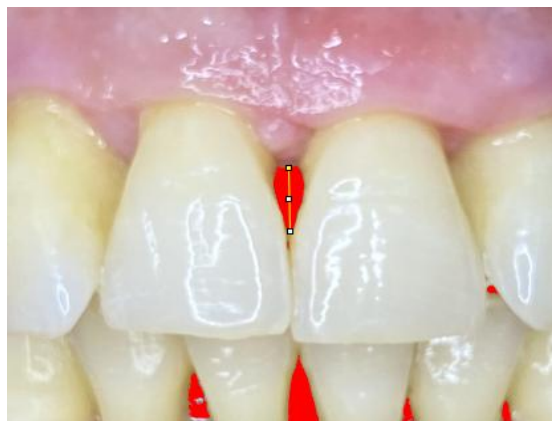**(FIGURE 8)**



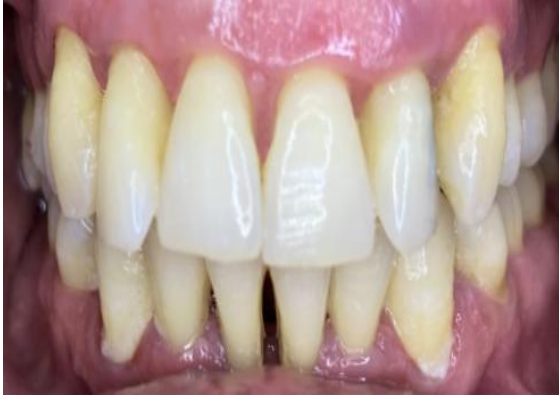**FIGURE 2** interdental papilla deficiency



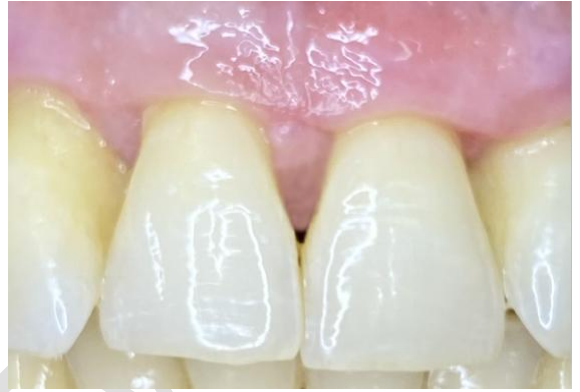**FIGURE 3** measurement using stent



**FIGURE 4** Image J analysis



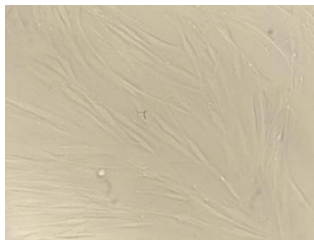**FIGURE 5** Injection using insulin syringe



**FIGURE 6** complete reconstruction **FIGURE 7** partial interdental papilla reconstruction



24 hours



48 hours



72 hours

## FIGURE 8 gingival fibroblast cell proliferation

**RESULTS** The software used for the statistical analysis was SPSS (statistical package for social sciences) version 25.0 and MedCalc software. The statistical tests used were:

- One-way ANOVA (Analysis of Variance) test for comparison of difference between mean values of more than 2 groups when the data followed normal distribution.
- Post-hoc tests were run to confirm where the differences occurred between groups, or they were used for the inter-group comparisons. Post hoc tests attempted to control the experiment wise error rate (usually  $\alpha = 0.05$ ) in the same manner that the one-way ANOVA was used instead of multiple t-tests.
- Unpaired or Independent t-test was used for comparison of mean values between 2 groups when the data followed normal distribution.
- Chi-square test was used to investigate whether distributions of categorical variables differed from one another.

A total number of 60 sites in 15 subjects having interdental papilla deficiency were treated in this study. Descriptive and Inferential statistics has been applied. 15 subjects were divided into two groups. Test group had received 2% HA as treatment for interdental papilla deficiency and control group had received placebo gel as treatment for interdental papilla deficiency. The mean age of test group was 37.13. The mean age of control group was 33.4. There were no statistically significant differences found with respect to age (Table 1).

	GROUP	N	Mean	Std. Deviation	Std. Error Mean	t	Sig. (2-tailed)
AGE	Test	30	37.13	8.22	1.50	3.56	0.056

(YEARS)	Control	30	33.4	7.89	1.60		
---------	---------	----	------	------	------	--	--

**p value-<0.05\*- statistically significant.**

**p value-<0.001\*\*- Highly significant.**

**Table 01: Mean comparison of demographic (age) between groups using students unpaired t test.**

In the present study on intragroup comparison for black triangle area (BTA), black triangle width (BTW), black triangle height (BTH) was done using J image analysis software and it was observed that mean BTA showed a gradual decline over the period of 6 months. Mean BTA for test group at V1 was 1.58 followed by 1.20 at V2, 0.98 at V3 and 0.42 at V4 (**Table 2**).

Test Group	Time interval	Mean	S.D.	Type III Sum of Squares	Mean Square	F value	p value
<b>BTA</b>	<b>V1</b>	1.58	0.46	21.27	9.53	101.02	0.001**
	<b>V2</b>	1.20	0.37				
	<b>V3</b>	0.98	0.15				
	<b>V4</b>	0.42	0.26				
<b>BTW</b>	<b>V1</b>	2.81	1.14	88.44	58.79	71.97	0.001**
	<b>V2</b>	2.10	1.06				
	<b>V3</b>	1.21	0.64				
	<b>V4</b>	0.55	0.46				
<b>BTH</b>	<b>V1</b>	3.86	2.01	194.31	129.81	57.35	0.001**
	<b>V2</b>	2.80	1.59				
	<b>V3</b>	1.32	0.76				
	<b>V4</b>	0.58	0.40				

**p value-<0.05\*- statistically significant.**

**p value-<0.001\*\*.- Highly significant.**

**Table 2: Mean comparison within test group using repeated measures ANOVA.**

In the present study, on intragroup comparison in control group for BTA, BTW, and BTH using J image analysis software, the results were different from that obtained in test group. When mean BTA was compared at V1 and V2, there was a numeric increase in BTA and it was significant ( $p<0.05$ ). (Table 3)

Control Group	Time interval	Mean	S.D.	Type III Sum of Squares	Mean Square	F	p value
<b>BTA</b>	<b>V1</b>	1.54	0.54	2.68	1.79	7.31	0.004*
	<b>V2</b>	1.86	0.62				
	<b>V3</b>	1.93	0.55				
	<b>V4</b>	1.85	0.52				
<b>BTW</b>	<b>V1</b>	2.96	1.00	1.13	0.65	3.63	0.039*
	<b>V2</b>	3.17	0.97				
	<b>V3</b>	2.96	0.99				
	<b>V4</b>	2.93	0.97				
<b>BTH</b>	<b>V1</b>	5.02	1.84	2.57	1.12	2.78	0.062
	<b>V2</b>	5.31	1.44				
	<b>V3</b>	4.97	1.45				
	<b>V4</b>	4.95	1.34				

p value-<0.05\*- statistically significant.

p value-<0.001\*\*- Highly significant.

**Table 3: Mean comparison within controlgroup using repeated measures ANOVA.**

In the present table of post hoc comparison of BTA in test and control group (**Table 4**), the test group showed gradual reduction in black triangle area from the baseline to 6 months. When black triangle area was compared at 3 months and 6 months in control group, there was a numeric reduction in the black triangle area but was not statistically significant ( $p>0.05$ ). So the control group did not show any improvement in interdental papillary deficiency area over the period of study.

GROUP	Time intervals		Mean Difference	p value
Test	Baseline	3 weeks	.379*	0.001
	Baseline	3 months	.605*	0.001
	Baseline	6 months	1.162*	0.001
	3 weeks	3 months	.226*	0.001
	3 weeks	6 months	.783*	0.001
	3 months	6 months	.557*	0.001
Control	Baseline	3 weeks	-.319*	0.001
	Baseline	3 months	-.387*	0.001
	Baseline	6 months	-.308*	0.002
	3 weeks	3 months	-0.068	0.561
	3 weeks	6 months	0.011	0.922
	3 months	6 months	.080*	0.012

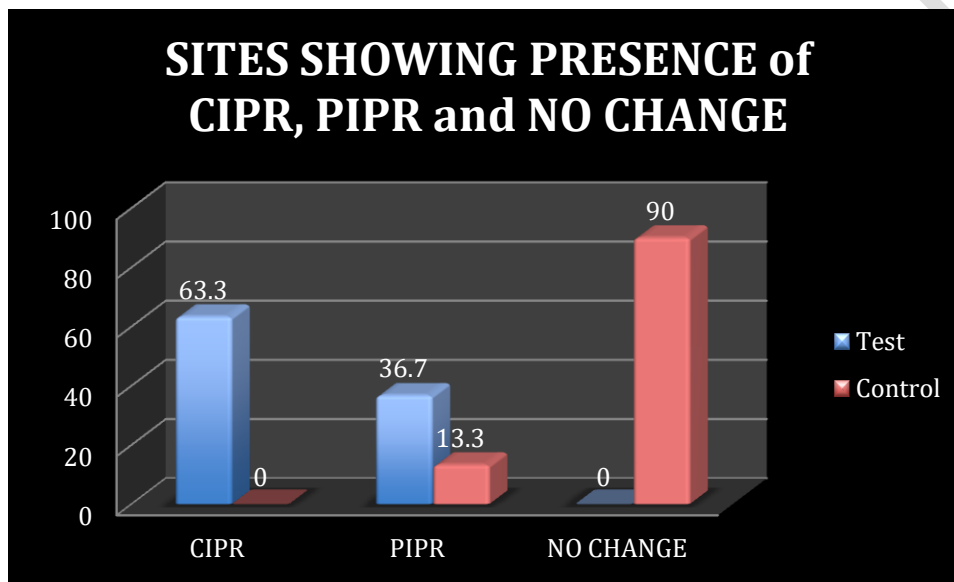
**Table 4: Post hoc comparison within groups on BTA with bornferroni correction.**

**Table 5** shows the mean of the stent measurement in test and control group at V1, V2, V3 and V4. It was observed that there was no significant differences in the interdental papillary deficiency in test and control group ( $p= 0.671$ ). In test group there was gradual fill in interdental papilla region. With the increase in time intervals of the study, the significance also increases. These clinical findings were exactly similar to the results obtained by J image software.

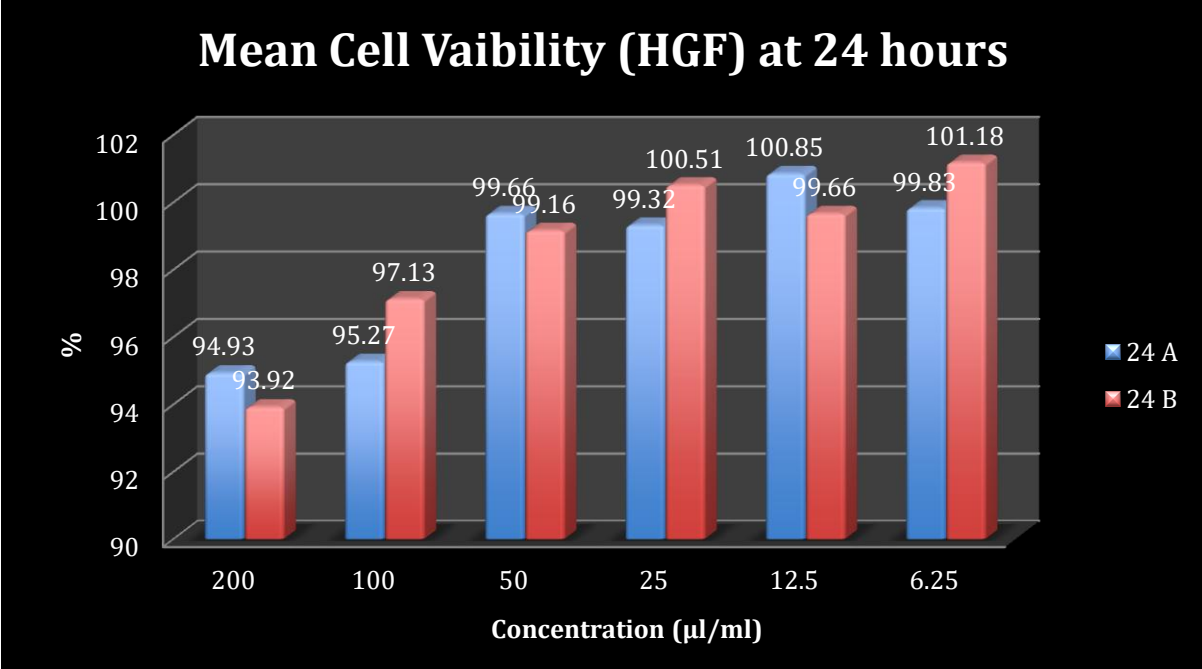
Groups	MEAN OF STENT MEASUREMENT			
	BASELINE	15 DAYS	3 MONTHS	6 MONTHS

<b>TEST</b>	3.92±1.63	3.11±1.33	2.6±0.9	2.4±0.85
<b>CONTROL</b>	3.88±1.34	3.90±1.15	3.86±0.9	4.1±1.2
<b>t value</b>	2.311	5.342	6.421	6.35
<b>p VALUE</b>	0.671	0.003*	0.026*	0.001**

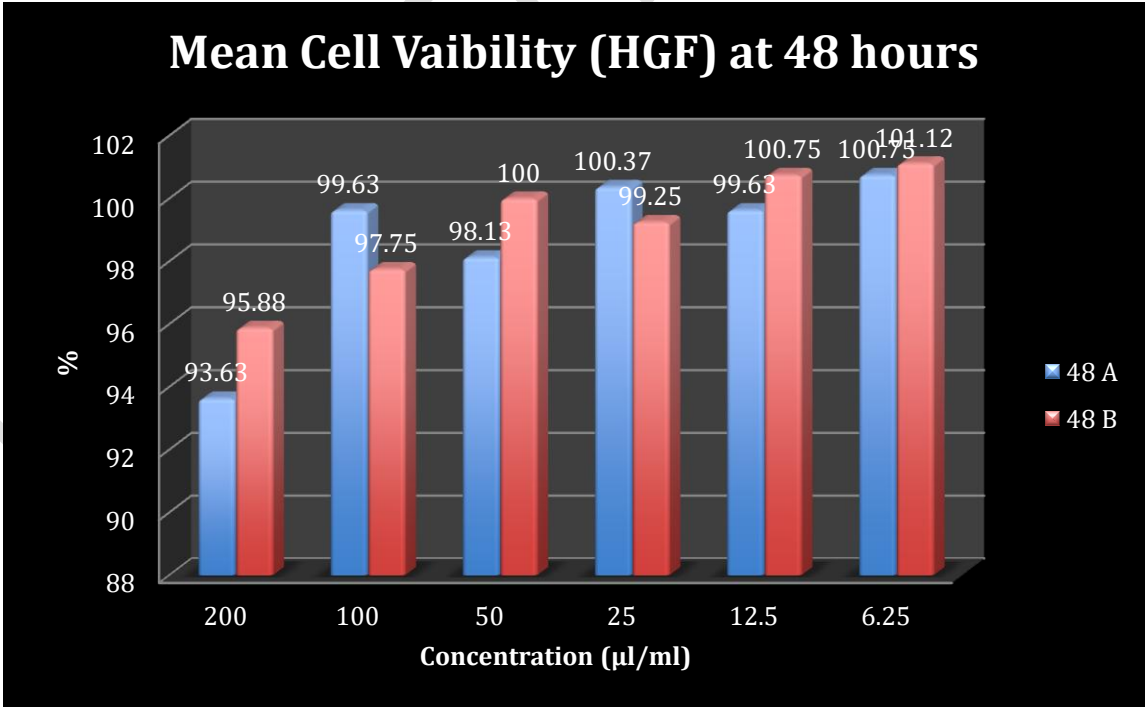
**Table 5: Mean of stent measurement in test and control group**



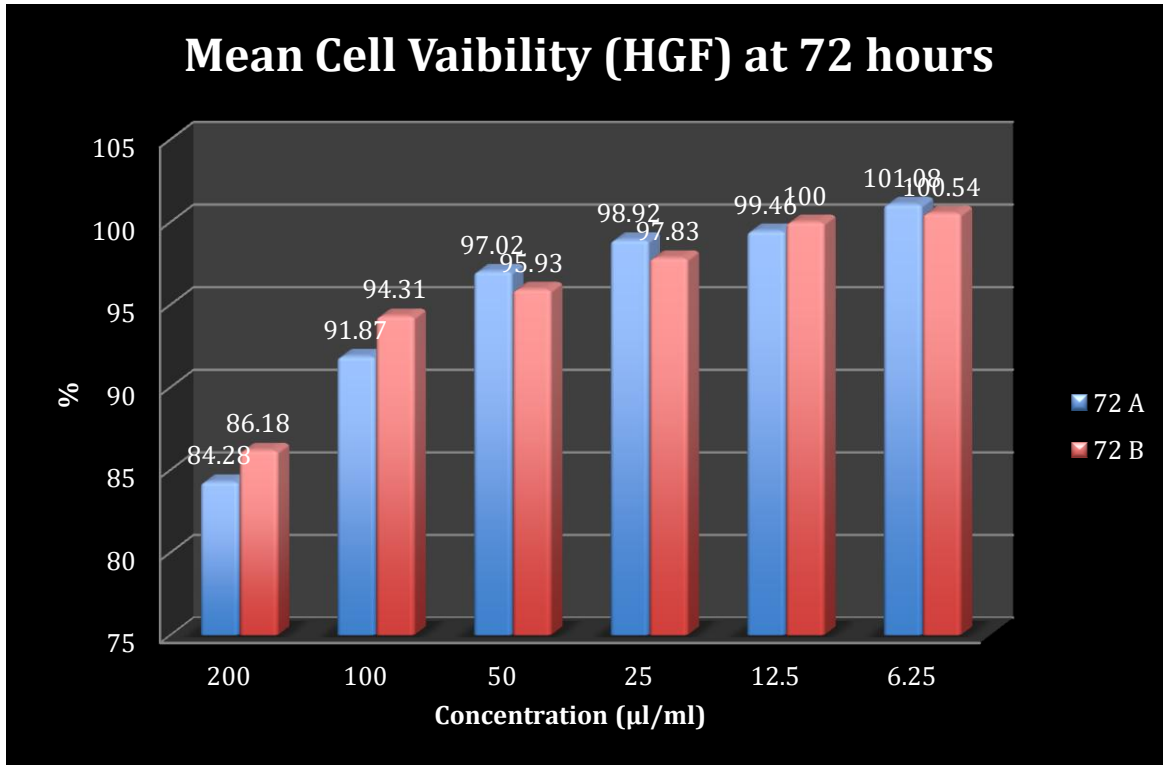
**Graph 1: Sites showing presence of CIPR, PIPR and no change**



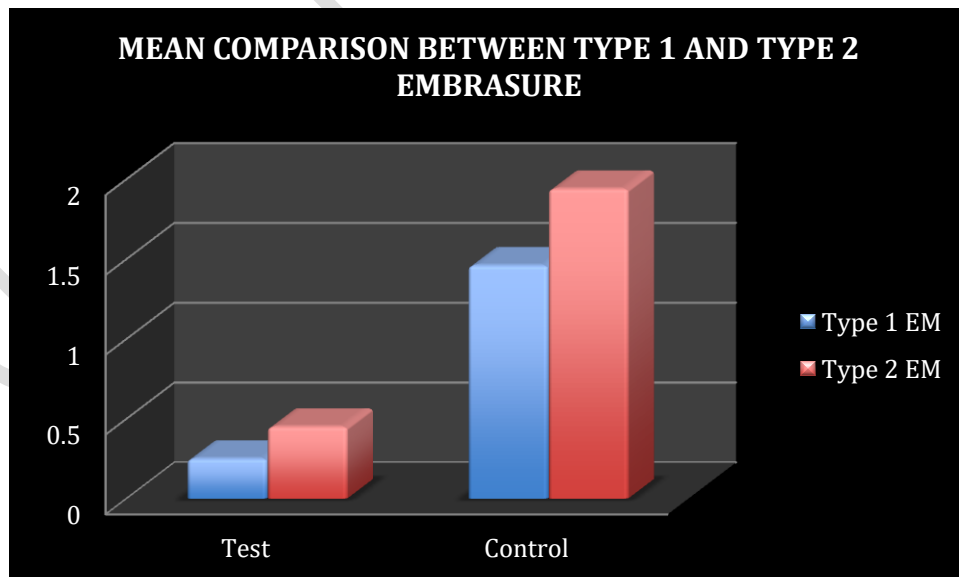
**GRAPH 02a: MEAN CELL VAIBILITY (HGF) AT 24 HOURS AT 24HOURS AT DIFFERENT CONCENTRATIONS**



**GRAPH 02b: MEAN CELL VAIBILITY (HGF) AT 24 HOURS AT 48 HOURS AT DIFFERENT CONCENTRATIONS**



**GRAPH 02c: MEAN CELL VAIBILITY (HGF) AT 24 HOURS AT 72 HOURS AT DIFFERENT CONCENTRATIONS**



**GRAPH 03: MEAN COMPARISON BETWEEN TYPE 1 AND TYPE 2 EMBRASURES**

## **DISCUSSION**

Interdental papilla deficiency is considered to be one of the most challenging dilemmas in esthetic dentistry. It has various challenges associated with it which include esthetic dissatisfaction and functional problems like food impaction and phonetic issues<sup>5</sup>. Various treatment modalities were introduced to improve the esthetics in the interdental region like grafting hard and soft tissues but the management technique to correct gingival black triangles were not a great success because of the limited blood supply to this confined area because of which the tissue in the region is fragile and sensitive to the recession, leading to unpredictable outcomes.<sup>1</sup> The invasive techniques for regeneration of gingival black triangles are categorized as non-surgical or surgical. Recently a non-invasive volumizing technique has been proposed for IDP enhancement.

The observational study for the treatment of interdental papilla deficiency presently comprised of total of 82 papillary deficient defects in 15 systematically and periodontally healthy subjects of both the sexes with in the age group range of 25-40 years. 60 sites were followed up out of 82 sites rest did not report during the follow up visits. The patient selected had at least one maxillary IDP deficiency following under the category of class I or class II in Nordland and Tarnow classification<sup>6</sup>. Similar classification system was used in the study done by Kapoor et al<sup>7</sup>, Awartani et al<sup>8</sup> while a study on IDP deficiency conducted by Singh et al<sup>9</sup> used Cardaropoli papilla index<sup>10</sup>. Follow up at 3 weeks, 3 months and 6 months for all the patients were done. The time interval in the study was similar to that used by Mansouri et al and Kapoor et al.

The clinical photographs of the sites were obtained with digital camera with 12 MP resolution having a fixed focal length of 26 mm. The clinical photographs of the interdental papilla deficiency were used for Image J analysis software. The percentage reduction in the black triangle area(in pixels) was also calculated<sup>8</sup>. Various image analysis software programs have been used previously in image analysis studies. In a study to investigate the root coverage assessment, Rosetti et al used ImageJ. With the corresponding potential error for 0.003%, they showed that this software may be considered for digital measurements<sup>11</sup>.

In the present study, the commercially available 2% HA gel was used in the test group and saline as placebo gel was used in the control group. This commercially available HA has an additional

benefit of crosslinking which prevents the early degradation of HA. No adverse reactions were noticed in the present study. Study done by Singh et al in 2019 also did not observe any adverse reactions. While Bertk K observed severe pain, swelling, tenderness and granuloma formation.<sup>12</sup> These adverse reactions could be attributed to self-prepared HA which may cause itching, redness and granuloma formation.

In the present study age and gender was matched i.e. in both test and control group there was no significant differences in the age and gender of the patients. The reason for matching age is that there should be no differences in relation to healing with respect to age. In the present study, only the maxillary anterior region was selected as the prevalence of interdental papilla deficiency is more common in maxilla. Studies done by Becker et al, Lee WP also used only the maxillary sites. While study done by Vandana et al<sup>9</sup> selected both maxillary and mandible sites. Till date this is the only study to evaluate 60 sites as study done by Vandana et al<sup>9</sup> has evaluated 35 sites, Awartani et al<sup>8</sup> evaluated 17 sites, and by Becker et al<sup>13</sup> evaluated 14 sites.

All the patients underwent Phase I periodontal therapy for the removal of plaque and calculus. The aim is to reduce the bacterial loads and thereby endotoxins. In the current study, there was a constant and continuous reduction in the BTA, BTW and BTH from the baseline to months in the test group while that of the control group did not show any significant improvement. The reduction in the various variables of BTA is indicative of interdental papilla enhancement in the test group. when BTA, BTH and BTW were compared in the control group from baseline to 6 months, then no significant changes were observed on photographic analysis, instead, there was an increase in BTA from V1 to V2. At the end of 6 months, there was no significant difference obtained in BTA, BTW and BTH when compared to baseline. The results obtained were in contrast with the study done by Bertl et al where he did not find any differences between the test and control group.<sup>12</sup> But, the results were in accordance with the study done by Mastafa, Adelaouf.<sup>14</sup> While, minute relapse has occurred in a few cases. But in the control group, there was no significant result obtained as only saline was injected as a placebo gel. The initial improvement found in test group both clinically and on photographic analysis may be due to volumizing effect of HA that provided support to the ID tissue. The gel leads to high cohesivity and tissue integration of the extracellular matrix.<sup>15</sup> The extended effect of HA in test

group at 3 months could be explained as HA causes receptor mediated cell division and increase the tubulin concentration which is responsible for proliferation of fibroblast and indirectly increases collagen synthesis.<sup>16</sup> As HA has been proven to be biocompatible on fibroblast cell lines, it is a key protein responsible for promoting cellular proliferation, migration and organisation of extracellular matrix.

The present study also evaluated whether the sites had CIPR or PIPR or no change at all. While evaluating the test sites 63.3% of sites had CIPR. The results were not in accordance with the study done by Becker et al where 21% of sites show papilla regenerations. While the results are in close proximity with the study done by Unnati P<sup>16</sup> where 52% of sites showed CIPR. The results were also in accordance with the study done by Lee et al 63% of sites had CIPR at 6 months and while in another study by Lee et al 67% of sites have CIPR.

In the present study when type of embrasure was compared with respect to interdental papilla enhancement it was found out that Type I embrasure showed better and fast enhancement when compared to Type II embrasure. The results were in accordance with the study done by Kapoor et al as in Type II the tip of interdental papilla is located beneath the interpapillary contact point. Study done by Tarnow et al<sup>17</sup> clearly explained that with the increase in the distance of 5mm between contact point and crest of bone, the interdental black space increases. The more the papilla moves apically, the more the distance increases. Thus Type II showing less papillary enhancement when compared to Type I.

In the current study, the effect of commercially available HA gel was evaluated on the human gingival fibroblast cell proliferation and its cytotoxic effect on the fibroblast cell line was investigated. The results depicted that Ha is a biocompatible material and it increases the proliferative abilities of gingival fibroblast. Ha gel at a higher concentration of 200 ml/ml for longer durations may cause cytotoxic effects on gingival fibroblasts. Results of the study done by Bogvieet al<sup>18</sup> and Akizuki et al<sup>19</sup> also favour the current study as it showed the beneficial effect of HA on gingival fibroblast cell viability. From the results of present study it can be stated that 2% HA gel is a good alternative for interdental papilla deficiency areas and it is advisable to prefer HA injections. Regular HA injections given on a specified time intervals can treat the interdental papilla deficiency completely.

## LIMITATIONS AND FUTURE PROSPECTS

Study with larger sample size with longer duration of one year can be done to evaluate long term effects of HA on IDP enhancement. Various concentration of Ha gel can be used to check for most efficacious one. Histological evaluation of HA treated sites can give better insight of the mechanism involved in IDP enhancement. Phenotypic Analysis of Gingival Fibroblast and identifying the receptors responsible for proliferative behavior holds a promising future research.

**CONCLUSION :** HA is a noninvasive volumizing alternative treatment modality for interdental papilla deficiency. It is biocompatible as it does not cause an adverse reaction. HA gel has a strong effect on the migratory and proliferative abilities of gingival fibroblasts.

There are no conflict of interest .

### COMPETING INTERESTS DISCLAIMER:

Authors have declared that no competing interests exist. The products used for this research are commonly and predominantly use products in our area of research and country. There is absolutely no conflict of interest between the authors and producers of the products because we do not intend to use these products as an avenue for any litigation but for the advancement of knowledge. Also, the research was not funded by the producing company rather it was funded by personal efforts of the authors.

## REFERENCES

- 1.Prato GP , Rotundo R, Corteliini P, Tinti C , Azzi R . Interdental papilla management: A review and classification of the therapeutic approaches . Int J Periodontics Restorative Dent 2004;24:246-55.
- 2.Brown M.B., Jones S.A. (2005): Hyaluronic acid: a unique topical vehicle for the localized delivery of drugs to the skin. Journal of European Academy of Dermatology and Venereology, 19, 308–18

3. Mesa FL, Aneiros J, Cabrera A, Bravo M, Caballero T, Revelles F, Del Moral RG, O Valle F. Antiproliferative effect of topic hyaluronic acid gel. Study in gingival biopsies of patients with periodontal disease. *Histology and histopathology*. 2002;17:747-54.
4. Sinha A, Hurakadli M, Yadav P. Botox and derma fillers: The twin face of cosmetic dentistry. *Int J Contemp Dent Med Rev*. 2015;2015:1-4.
5. Singh VP, Uppoor AS, Nayak DG, Shah D. Black Triangles dilemma and its management in esthetic edentistry. *Dent Res J (Isfahan)*,2013;10:296-301
6. Nordland WP, Tarnow DPA. Classification system for loss of papillary height. *J Periodontol*. 1998;69: 1124-1126.
7. Kapoor S, Dudeja A. Derma fillers: Ray of light in black triangles—A pilot study. *Contemporary Clinical Dentistry*. 2020 Jan;11(1):55.
8. Awartani FA, Tatakis DN. Interdental papilla loss: treatment by hyaluronic acid gel injection: a case series. *Clin Oral Investig*. 2016;20:1775–1780.
9. Singh S, Vandana KL. Use of different concentrations of hyaluronic acid in interdental papillary deficiency treatment: A clinical study. *J Indian SocPeriodontol*. 2019 Jan-Feb;23(1):35-41.
10. Cardaropoli D, Re S, Corrente G. The Papilla Presence Index (PPI): a new system to assess interproximal papillary levels. *International Journal of Periodontics & Restorative Dentistry*. 2004 Oct 1;24(5).
11. Kerner S, Etienne D, Malet J, Mora F, Monnet-Corti V, Bouchard P. Root coverage assessment: validity and reproducibility of an image analysis system. *J ClinPeriodontol*. 2007 Nov; 34(11):969-76.
12. Bertl K, Gotfredsen K, Jensen SS, Bruckmann C, Stavropoulos A. Can hyaluronan injections augment deficient papillae at implant-supported crowns in the anterior maxilla? A randomized controlled clinical trial with 6 months follow-up. *Clinical oral implants research*. 2017 Sep;28(9):1054-61.

13. Becker W, Gabitov I, Stepanov M, Kois J, Smidt A, Becker BE. Minimally invasive treatment for papillae deficiencies in the esthetic zone: a pilot study. *Clinical implant dentistry and related research*. 2010 Mar;12(1):1-8.
14. Abràmoff MD, Magalhães PJ, Ram SJ. Image processing with ImageJ. *Biophotonics international*. 2004; 11(7):36-42.
15. Kerscher M, Agsten K, Kravtsov M, Prager W. Effectiveness evaluation of two volumizing hyaluronic acid dermal fillers in a controlled, randomized, double-blind, split-face clinical study. *ClinCosmetInvestigDermatol*. 2017;10:239-247.
16. Pitale U, Pal PC, Thakare G, Verma M, Dhakad S, Pandey R. Minimally invasive therapy for reconstruction of lost interdental papilla by using injectable hyaluronic acid filler. *J Indian SocPeriodontol*. 2021 Jan-Feb;25(1):22-28.
17. Bogović A, Nižetić J, Galić N, Zelježić D, Micek V, Mladinić M. The effects of hyaluronic acid, calcium hydroxide, and dentin adhesive on rat odontoblasts and fibroblasts. *ArhHigRadaToksikol*. 2011 Jun;62(2):155-61.
18. Akizuki T, Oda S, Komaki M, Tsuchioka H, Kawakatsu N, Kikuchi A, Yamato M, Okano T, Ishikawa I. Application of periodontal ligament cell sheet for periodontal regeneration: a pilot study in beagle dogs. *J Periodontal Res*. 2005 Jun;40(3):245-51.