

Study Protocol

FUNCTIONAL AND RADIOLOGICAL OUTCOME ANALYSIS OF BIPOLAR PROSTHESIS USED IN FEMUR NECK FRACTURE THROUGH INTER-PROSTHETIC JOINT MOVEMENT : A STUDY PROTOCOL

Abstract:

Background: Fracture neck of femur is the commonest fracture in old aged individuals because of osteoporosis and advancing age causing more brittleness of bone. Blood to neck and head of femur is rich and complicated. A hip operation is successful only when it provide a stable hip which is pain free and has a good range of movement.

The Austin – Moore and Thompson prostheses have been used successfully for treating fracture NOF. Excruciating pain and erosion of acetabulum are very common complications after the use of the Austin- Moore prosthesis. The bipolar prosthesis was developed by James E Bateman in 1974, which had the great advantage of second joint, below the acetabulum. So hip motion is to occur at two surfaces thus reducing the articular erosion. Studies have shown that over an increasing period of time the bipolar prosthesis will become more of a unipolar prosthesis functionally due to stiffening up of the inter-prosthetic joint. By this study we will be able to assess whether bipolar prosthesis really functions as it's name suggests or vice versa .

Objectives:

1. Analysis of Inter – prosthetic joint movement in Bipolar prosthesis by radiological means.
2. Co-relating the inter-prosthetic joint motion with functional outcome of Bipolar prosthesis using Oxford hip score

Methodology: By appropriate and easy sampling method, the patients undergoing Bipolar hemiarthroplasty for NOF fracture will be assessed radiologically for amount of inter-prosthetic joint motion during post-operative period.

Results: Results would be assessed on basis of clinical evaluation, functional evaluation and radiological evaluation and statistical analysis would be done to conclude the findings.

Conclusion: That over an increasing period of time the bipolar prosthesis will become more of a unipolar prosthesis functionally due to stiffening up of the inter-prosthetic joint.

Keywords: radiograph, X-ray, Bipolar, Hip hemiarthroplasty, fracture Neck of Femur, Inter-prosthetic joint movements.

INTRODUCTION

Fracture neck of femur is a common orthopaedic problem in old age and they have a tremendous impact on both the health care system and society in general[1]. The NOF fracture remains an unsolved fracture in terms of treatment inspite of better implant design, surgical technique and patient care[2]. NOF fractures are on the rise, which is not surprising given that overall life expectancy has increased significantly over the last few decades. These fractures may double in the next 20 years, and the fracture rate has increased to twice for each decade of life after the fifth[3]. Because of osteoporosis and advancing age, which causes bone brittleness, this is the most common fracture in the elderly. As a result, prolonged immobilisation during such fractures in the elderly will jeopardise the patients' lives. The blood flow to the neck and head of the femur is rich and complicated. A good blood supply is vital for better healing process[4]. The main consequences of this fracture include non-union, avascular necrosis of the femoral head, and secondary degenerative arthritis. Non-union may be under the surgeon's control, while avascular necrosis and arthritis may be beyond his control. This complicates the management of these fractures because the healing process is never certain. It's also common knowledge that the hip is a weight-bearing joint that is responsible for a variety of performance-related functions. A good hip joint procedure should result in a pain-free, stable hip with a wide range of motion.

Since the early 1950s, prosthetic replacement has been used to solve problems such as femoral neck fracture necks and vitallium intramedullary prosthesis, which has helped to prevent non-union and avascular necrosis. This prosthesis was proven to be extremely useful, with promising results. The Austin – Moore and Thompson prostheses have been used successfully for treating fracture NOF. Excruciating pain and erosion of acetabulum are very common complications after the use of the Austin- Moore prosthesis[5][6]. The bipolar prosthesis was developed by James E Bateman in 1974, which had the great advantage of second joint, below the acetabulum. So hip motion is to occur at two surfaces thus reducing the articular erosion[7]. However, studies that attempted to demonstrate the relative movements at the interfaces produced contradictory results. It is well known that friction generates particulate debris from the polyethylene liner, which was thought to be the cause of foreign body reaction, resulting in stiffening of the interprosthetic joint as well as osteolysis and aseptic loosening of the implant. [8] According to studies, the stiffening of the inter-prosthetic joint causes the bipolar prosthesis to function more like a unipolar prosthesis over time[9]. This research presents the assessment of the IPJ movement in bipolar prosthesis done for fracture NOF at 6months and mid-term follow-up by radiological means[10]. By this study we will be able to assess whether bipolar prosthesis really functions as it's name suggests or vice versa as the literature suggests.

AIM AND OBJECTIVES

AIM

Analysis of the inter-prosthetic joint movement in bipolar hemi-arthroplasty done for NOF fracture patient through X-rays.

OBJECTIVES

1. Analysis of Inter – prosthetic joint movement in Bipolar prosthesis by radiological means.
2. Co-relating the inter-prosthetic joint motion with functional outcome of Bipolar prosthesis using Oxford hip score

MATERIALS AND METHODS

Study Design:

1. Prospective study
2. Retrospective study

Source of data:

Consist of 2 parts.

Part I is a (prospective study) in which Patient's who would undergo Bipolar hemiarthroplasty for NOF fracture at AVBRH will be included in the study after obtaining their consent during the period of May 2019 to April 2021. Study will be done on a total of 50 patients.

Part II will be a retrospective study where we take a data of patients who were operated earlier in our institute and had completed at least 2 years of follow-up.

Methodology :

By appropriate and easy sampling method, the patients undergoing Bipolar hemiarthroplasty for NOF fracture will be assessed radiologically for amount of inter-prosthetic joint motion during post-operative period.

Inclusion Criteria:

Patients who underwent bipolar hemiarthroplasty for NOF fracture would be included from 2016 onwards.

Exclusion Criteria:

- Bedridden patients
- Patients who have had post-operative infection,

- Patients who have developed myositis following bipolar hemiarthroplasty and
- Patients who have had Peri-prosthetic fractures

Implant used:

For all patients Life ortho care Bipolar prosthesis will be used (ISO – 13485 certified company). The implant is constructed of stainless steel 316. The femoral stem measures 150 mm in length and 8 mm in diameter. The diameter of the outer head ranges from 37 to 53 mm, with 2 mm increments. The inner diameter of the prosthetic femoral head was 26 mm, and the lining between the outer and inner heads was constructed of UHMWPE (Ultra High molecular Weight Polyethylene). The angle of the neck shaft is 130 degrees. There are two forms of prosthesis (Fixed solely with collar, Modular with or without collar, and Extra – extended stem).

Part 1 - (Prospective study) :

Pre-operative management : All patients who are undergoing bipolar hemiarthroplasty for fracture neck of femur will be considered for the study after getting a written consent from them.

All Patients will be adequately worked up before surgery. A detailed history about the mode of injury and type of fracture will be noted.

Surgical Procedure: Surgeries would be elective and done with all the aseptic precautions , Surgery will be performed under spinal anaesthesia or GA. Patient would be positioned laterally lying on the unaffected side. For all the patients Modified posterolateral approach will be used in our series.

Post-operative protocol: Abduction and external rotation of the limb would be avoided as much as possible throughout the post-operative period. During the immediate post-operative phase, all patients will receive Quads strengthening exercises as well as mechanical DVT prophylaxis. All patients will begin full weight bearing ambulation as soon as they are able. Specific X-rays would be taken after the initial pain subsided to assess the inter-prosthetic joint (IPJ) and outer bearing movement during the immediate post-op period (24 to 48 hours), at 6 weeks, and after 6 months with the operated hip in neutral and maximum abducted positions.

X-ray Technique:

Two A.P X-rays of pelvis will be taken.

1. Limbs in neutral position and neutral rotation X-ray with affected limb in Maximum abduction will be taken.

Radiological Assessment:

We follow the method of plain radiographs, as described by Bochner.

On the X-ray in the neutral position, 3 lines are drawn as follows:

Line 1: a tangent is drawn through the inferior aspects of both the ischial tuberosities which is used as a reference line.

Line 2; a tangent drawn along the Inferior aspect of acetabular part of the prosthesis

Line 3 : Line along the centre of femoral stem's long axis.

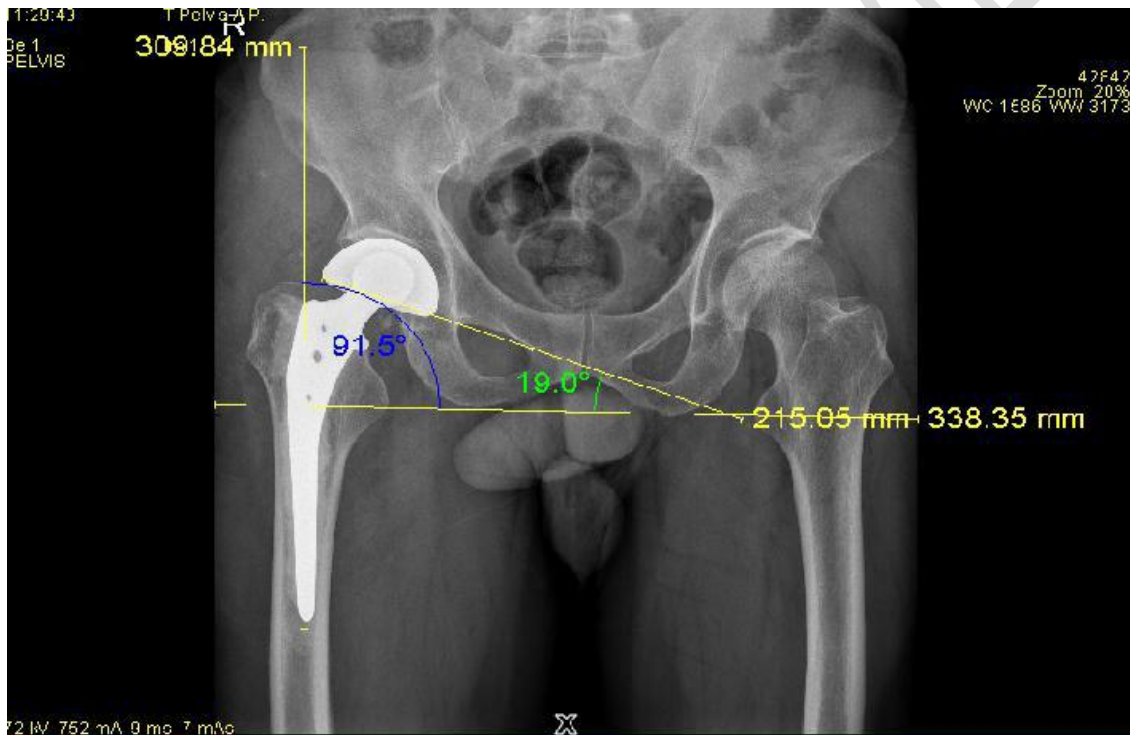


Fig 1. X-Ray image

Angle A is defined as the intersection of the line 1 and line 2

Angle B is formed by the intersection of the line 2 and line 3

The same process will be repeated on the maximum abduction AP X-ray also and angles are marked as A1 and B1.

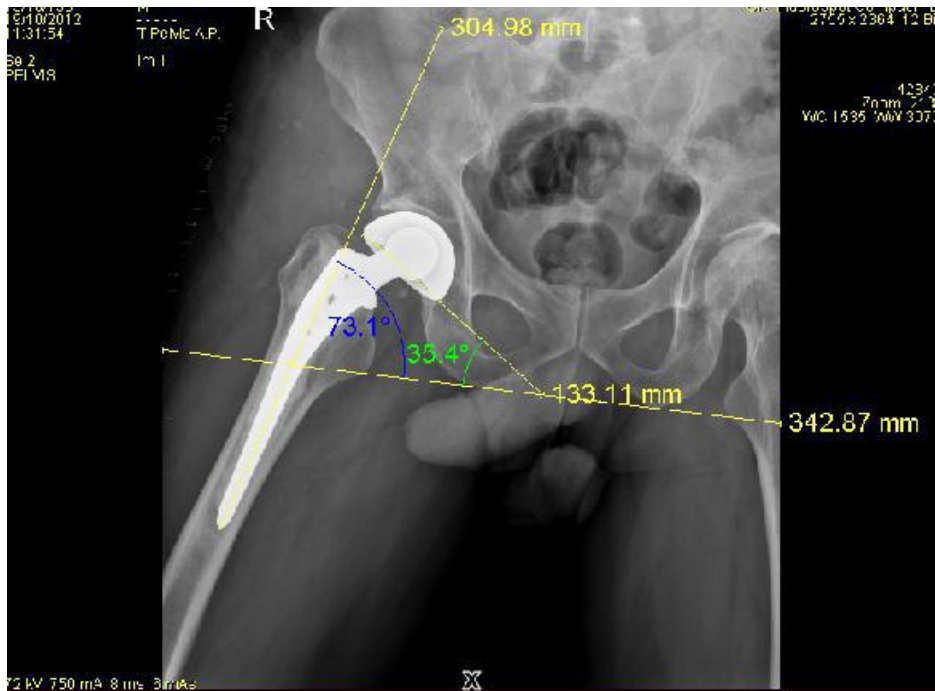

Fig 2. Xray of pelvis

Now, B2 is the difference b/w angle B and B1 which represents total amount of abduction of the hip in the operated limb.

A2 is the difference b/w angle A and A1 which represents the extent of motion taking place between the acetabular part and the acetabulum (Outer bearing interface).

As we have 2 variables ie. (B2 – total amount of abduction, A2 – motion at the outer bearing interface), the difference between B2 and A2 represents the extent of abduction happening at the Inter- Prosthetic joint.

Thus the sum of abduction, movement at outer bearing interface and Movement at inter-prosthetic joint will be calculated and tabulated for each patient at each follow-up.

Example:

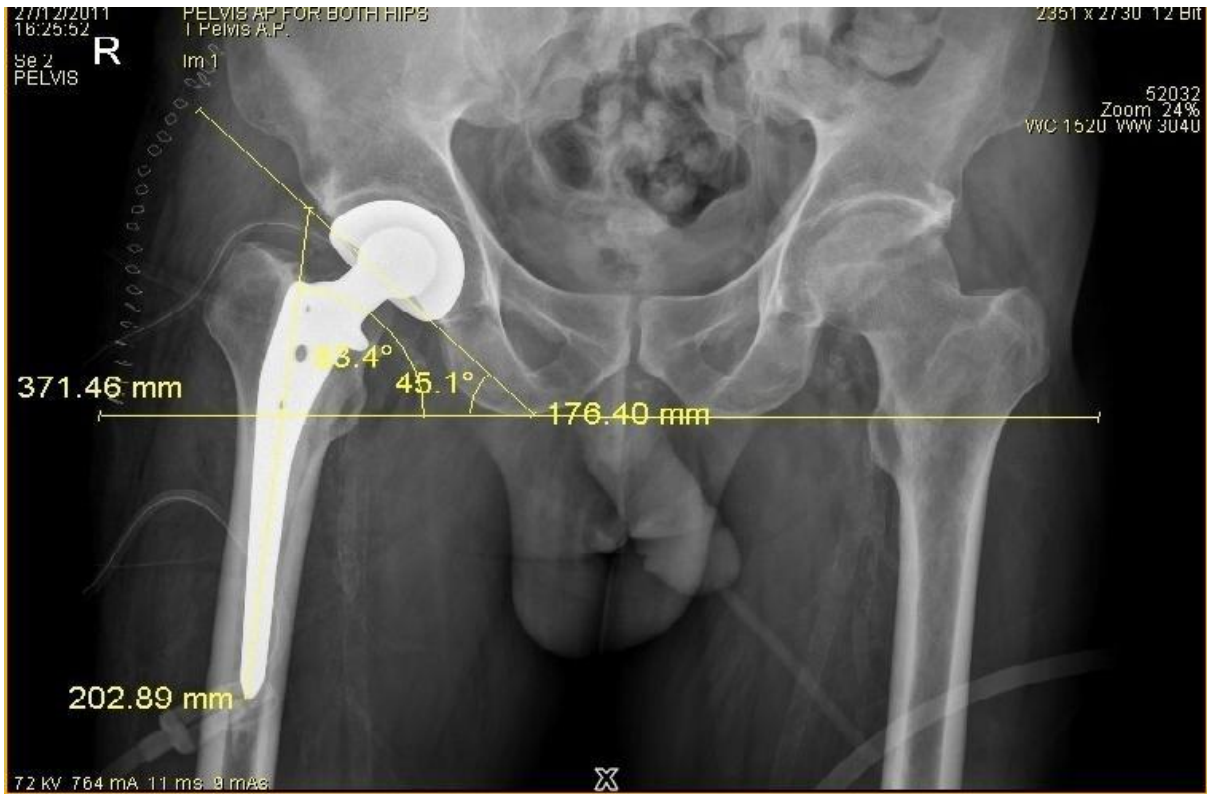

Fig 3. X-ray of pelvis with both hips (neutral position) with Bipolar prosthesis on right side showing

Angle A – 45.1 and Angle B – 86.4 degrees.

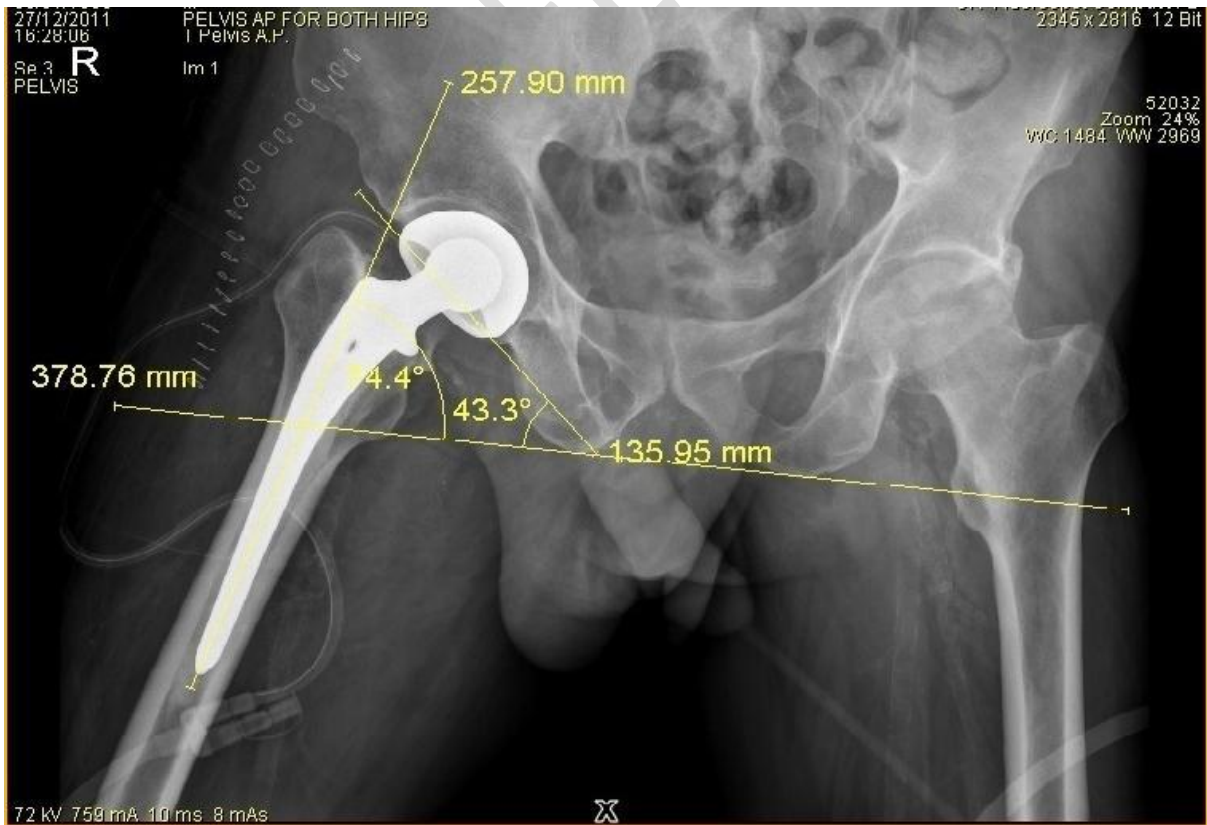

Fig 4. X-ray of pelvis with both hips (Abduction of operated hip) with Bipolar prosthesis on right side

showing Angle A1 – 43.3 and Angle B1 – 74.4 degrees.

A = 45.1, B = 83.4, A1 = 43.3, B1 = 74.4 (DEGREES)

B2= 9 DEGREES (TOTAL ABDUCTION)

A2 = 1.8DEGREES (MOTION @ OUTER CUP)

B2-A2 = 7.2 DEGREES (INTER-PROSTHETIC JOINT MOTION)

A2 = 20 % (MOTION @ OUTER CUP)

B2 - A2 = 80 % (INTER-PROSTHETIC JOINT MOTION) .

After the half yearly follow-up, in addition to Radiological assessment Functional outcome will also be assessed with Oxford hip score..

Part – 2 (Retrospective study):

Patients in this group who have already undergone Bipolar H.A and completed 2 years follow-up will be received. The x-rays will be taken in the similar fashion as described above.

Functional outcome assessment will be done using Oxford hip score. The retrospective study helps us to assess Inter prosthetic joint movement at 6 months follow-up.

Oxford Hip Score (OHS):

- It's useful to Analyse the results post surgical procedures by measuring patient's perceptions in relation to surgery. OHS assesses pain (6 items) and function (6 items) of the hip in relation to daily activities such as walking, dressing, sleeping etc.12 items with 5 categories of responses. Scores range from 0 to 4 (worst to best).

Grading :

0 to19 Worst, indicates extreme hip arthritis, requires some form of surgical intervention.

20 to 29 Fair, indicates moderate to severe hip arthritis. Assessment by X-ray

30 to 39 Good,indicates mild to moderate hip arthritis.

40 to 48 Excellent, indicates satisfactory joint function. requires no formal treatment.

STATISTICAL ANALYSIS - Appropriate statistical test would be applied to analyze data.

Follow-up:

Follow-up of all patients at 2 weeks, 6 weeks , 3 months and 6 months

Results:-

Results would be assessed on basis of clinical evaluation, functional evaluation and radiological evaluation and statistical analysis would be done to conclude the findings.

Discussion and conclusion

The primary benefit of the Bipolar prosthesis over a conventional unipolar prosthesis is mobility at the two interfaces, namely between the prosthetic inner femoral head and the polyethylene liner and between the acetabulum and the outer head. This study hypothesised that by minimising wear caused by sliding motion in the acetabular socket, issues such as acetabular erosions could be delayed or averted. The prosthesis has been scanned in various non-weight-bearing and static weight-bearing positions to quantify the fraction of movement that occurs at the inter-prosthetic joint in a bipolar prosthesis in several radiography examinations. According to Drinker and Murray, while some inner motion occurred in most implants, it was less than predicted. Philips TW (1987) had done a study on Fluoroscopic movement in 100 patients who had undergone Bateman Bipolar arthroplasty. Out of these 100 patients Group I had 76 patients with arthritis of hip and Group II had 24 patients with neck of femur fractures. In 80% of group I patients, the prosthesis retained Bipolar function at the end of 4 years follow-up study as compared to only 25% of group II patients retained the bipolar functioning of the prosthesis.

Verbene G.H.M (1983), did a radiological study of movements of two components in Variokopf prosthesis in 20 patients with fracture neck of femur during Immediate, 1 month and 3 months post-operative period. He observed that the IPJ lost mobility and at 3 months it became almost completely stiff with inter-prosthetic joint motion of only 16.9% being retained.

Presence of systemic disorders like hypertension¹¹⁻¹⁷, diabetes¹⁸⁻²³ also play a key role in fracture healing and treatment of these underlying entities needs to be addressed properly. Few of the other related studies on bone and joint disorders are available²⁴⁻³⁸.

Ethical Approval:

As per international standard or university standard written ethical approval will be collected and preserved by the author(s).

Consent

As per international standard or university standard, patients' written consent will be collected and preserved by the author(s).

REFERENCES

1. Arvind Kumar SM, Kumar NV, Udayamoorthy S. Radiological assessment of inter-prosthetic joint movement in bipolar hip hemiarthroplasty for fracture neck of femur. *International Journal of Orthopaedics*. 2017;3(2):583-9.
2. Arvind Kumar SM, Kumar NV, Udayamoorthy S. Radiological assessment of inter-prosthetic joint movement in bipolar hip hemiarthroplasty for fracture neck of femur. *International Journal of Orthopaedics*. 2017;3(2):583-9.
3. Wirth MA, Rockwood CA. Acute and chronic traumatic injuries of the sternoclavicular joint. *JAAOS-Journal of the American Academy of Orthopaedic Surgeons*. 1996 Sep 1;4(5):268-78.
4. CHANDLER SB, KREUSCHER PH. A study of the blood supply of the ligamentum teres and its relation to the circulation of the head of the femur. *JBJS*. 1932 Oct 1;14(4):834-46.
5. Johnston CE, Ripley LP, Bray CB, Shaffer LW, Strong TE, Henning GD, Pruner RA. Primary endoprosthesis replacement for acute femoral neck fractures: a review of 150 cases. *Clinical Orthopaedics and Related Research*[®]. 1982 Jul 1;167:123-30.
6. Moore AT. Discussion on femoral head prosthesis. *JBJS*1965 A. 1965;47.
7. Bateman JE. Single assembly total hip arthroplasty, preliminary report. *Orthop Digest*. 1974;15:35-43.
8. Cordasso P. Evolution of treatment of femoral neck fractures. *Arch Surg*. 1972;37:871.
9. Carnesale PG, Anderson LD. Primary prosthetic replacement for femoral neck fractures. *Archives of Surgery*. 1975 Jan 1;110(1):27-9.
10. Badgley C. Treatment of displaced subcapital fractures of the femoral neck in aged with immediate replacement arthroplasty (Discussion). *JBJS*. 1961;43:606.
11. Papalkar, P., S. Kumar, S. Agrawal, N. Raisinghani, G. Marfani, and A. Mishra. "Heterotaxy Syndrome Presenting as Severe Pulmonary Artery Hypertension in a Young Old Female: Case Report." *Journal of Gerontology and Geriatrics* 66, no. 2 (2018): 59–61.
12. Charan, N., M. Choudhari, M. Sonkusale, and R. Deshpande. "Anesthetic Management of Chronic Thromboembolic Pulmonary Hypertension for Pulmonary Endarterectomy." *Journal of Datta Meghe Institute of Medical Sciences University* 12, no. 4 (2017): 289–91. https://doi.org/10.4103/jdmimsu.jdmimsu_40_17.
13. Gaikwad, K.B., N.G. Joshi, and S.P. Selkar. "Study of Nitrosative Stress in 'Pregnancy Induced Hypertension.'" *Journal of Clinical and Diagnostic Research* 11, no. 3 (2017): BC06–8. <https://doi.org/10.7860/JCDR/2017/23960.9396>.
14. Yadav, S., M. Agrawal, C. Hariharan, D. Dewani, K. Vadera, and N. Krishna. "A Comparative Study of Serum Lipid Profile of Women with Preeclampsia and Normotensive Pregnancy." *Journal of Datta Meghe Institute of Medical Sciences University* 13, no. 2 (2018): 83–86. https://doi.org/10.4103/jdmimsu.jdmimsu_70_17
15. Kumar, S., P. Bhayani, D. Hathi, and J. Bhagwati. "Hyponatremia Initial Presenting Feature of Normal Pressure Hydrocephalus in Elderly Patient: A Rare Case Report." *Journal of Gerontology and Geriatrics* 66, no. 3 (2018): 156–57.
16. Bhinder, H.H.P.S., and T.K. Kamble. "The Study of Carotid Intima-Media Thickness in Prediabetes and Its Correlation with Cardiovascular Risk Factors." *Journal of Datta Meghe Institute of Medical Sciences University* 13, no. 2 (2018): 79–82. https://doi.org/10.4103/jdmimsu.jdmimsu_58_18.

17. Khatib, M.N., R. Kirubakaran, S. Gaidhane, A.H. Shankar, and Z. Quazi Syed. "Yoga for Improving Functional Capacity, Quality of Life and Cardiovascular Outcomes in People with Heart Failure." *Cochrane Database of Systematic Reviews* 2017, no. 7 (2017). <https://doi.org/10.1002/14651858.CD012015.pub2>.
18. Cladius, S., U. Jadhav, B. Ghewade, S. Ali, and T. Dhamgaye. "Study of Diabetes Mellitus in Association with Tuberculosis." *Journal of Datta Meghe Institute of Medical Sciences University* 12, no. 2 (2017): 143–47. https://doi.org/10.4103/jdmimsu.jdmimsu_62_17.
19. Bhinder, H.H.P.S., and T.K. Kamble. "The Study of Carotid Intima-Media Thickness in Prediabetes and Its Correlation with Cardiovascular Risk Factors." *Journal of Datta Meghe Institute of Medical Sciences University* 13, no. 2 (2018): 79–82. https://doi.org/10.4103/jdmimsu.jdmimsu_58_18.
20. Rathi, N., B. Taksande, and S. Kumar. "Nerve Conduction Studies of Peripheral Motor and Sensory Nerves in the Subjects with Prediabetes." *Journal of Endocrinology and Metabolism* 9, no. 5 (2019): 147–50. <https://doi.org/10.14740/jem602>.
21. Walinjkar, R.S., S. Khadse, S. Kumar, S. Bawankule, and S. Acharya. "Platelet Indices as a Predictor of Microvascular Complications in Type 2 Diabetes." *Indian Journal of Endocrinology and Metabolism* 23, no. 2 (2019): 206–10. <https://doi.org/10.4103/ijem.IJEM-13-19>.
22. Phadnis, P., M.A. Kamble, S. Daigavane, P. Tidke, and S. Gautam. "Prevalence and Risk Factors – Hemoglobin A1c, Serum Magnesium, Lipids, and Microalbuminuria for Diabetic Retinopathy: A Rural Hospital-Based Study." *Journal of Datta Meghe Institute of Medical Sciences University* 12, no. 2 (2017): 121–32. https://doi.org/10.4103/jdmimsu.jdmimsu_59_17.
23. Dande, R., A.R. Gadbail, S. Sarode, M.P.M. Gadbail, S.M. Gondivkar, M. Gawande, S.C. Sarode, G.S. Sarode, and S. Patil. "Oral Manifestations in Diabetic and Nondiabetic Chronic Renal Failure Patients Receiving Hemodialysis." *Journal of Contemporary Dental Practice* 19, no. 4 (2018): 398–403. <https://doi.org/10.5005/jp-journals-10024-2273>.
24. Mundada, G., S. Khan, S. Singhanian, V. Gupta, P. Singh, and S. Khan. "Type-I Monteggia with Ipsilateral Fracture of Distal Radius Epiphyseal Injury: A Rare Case Report." *Annals of African Medicine* 16, no. 1 (2017): 30–32. https://doi.org/10.4103/aam.aam_55_16.
25. Belekar, V. "A Comparative Study to Evaluate the Efficacy of Butorphanol as an Adjuvant to Epidural Analgesia for Rib Fractures." *Journal of Datta Meghe Institute of Medical Sciences University* 12, no. 3 (2017): 166–69. https://doi.org/10.4103/jdmimsu.jdmimsu_105_17.
26. James SL, Castle CD, Dingels ZV, Fox JT, Hamilton EB, Liu Z, Roberts NL, Sylte DO, Bertolacci GJ, Cunningham M, Henry NJ. Estimating global injuries morbidity and mortality: methods and data used in the Global Burden of Disease 2017 study. *Injury Prevention*. 2020 Oct 1;26(Suppl 2):i125-53.
27. Pradhan S, Madke B, Kabra P, Singh AL. Anti-inflammatory and immunomodulatory effects of antibiotics and their use in dermatology. *Indian journal of dermatology*.

2016 Sep;61(5):469.

28. Acharya S, Shukla S, Mahajan SN, Diwan SK. Acute dengue myositis with rhabdomyolysis and acute renal failure. *Annals of Indian Academy of Neurology*. 2010 Jul;13(3):221.
29. Gadbail AR, Chaudhary M, Patil S, Gawande M. Actual Proliferating Index and p53 protein expression as prognostic marker in odontogenic cysts. *Oral Diseases*. 2009 Oct;15(7):490-8.
30. Prasad N, Bhatt M, Agarwal SK, Kohli HS, Gopalakrishnan N, Fernando E, Sahay M, Rajapurkar M, Chowdhary AR, Rathi M, Jeloka T. The adverse effect of COVID pandemic on the care of patients with kidney diseases in India. *Kidney international reports*. 2020 Sep 1;5(9):1545-50.
31. Walia IS, Borle RM, Mehendiratta D, Yadav AO. Microbiology and antibiotic sensitivity of head and neck space infections of odontogenic origin. *Journal of maxillofacial and oral surgery*. 2014 Mar 1;13(1):16-21.
32. Lohe VK, Degwekar SS, Bhowate RR, Kadu RP, Dangore SB. Evaluation of correlation of serum lipid profile in patients with oral cancer and precancer and its association with tobacco abuse. *Journal of oral pathology & medicine*. 2010 Feb;39(2):141-8.
33. Korde S, Sridharan G, Gadbail A, Poornima V. Nitric oxide and oral cancer: A review. *Oral oncology*. 2012 Jun 1;48(6):475-83.
34. Gondivkar SM, Gadbail AR. Gorham-Stout syndrome: a rare clinical entity and review of literature. *Oral Surgery, Oral Medicine, Oral Pathology, Oral Radiology, and Endodontology*. 2010 Feb 1;109(2):e41-8.
35. Gadbail AR, Chaudhary M, Gawande M, Hande A, Sarode S, Tekade SA, Korde S, Zade P, Bhowate R, Borle R, Patil S. Oral squamous cell carcinoma in the background of oral submucous fibrosis is a distinct clinicopathological entity with better prognosis. *Journal of Oral Pathology & Medicine*. 2017 Jul;46(6):448-53.
36. Gadre PK, Ramanojam S, Patankar A, Gadre KS. Nonvascularized bone grafting for mandibular reconstruction: myth or reality?. *Journal of Craniofacial Surgery*. 2011 Sep 1;22(5):1727-35.
37. Sorte K, Sune P, Bhake A, Shivkumar VB, Gangane N, Basak A. Quantitative assessment of DNA damage directly in lens epithelial cells from senile cataract patients. *Molecular vision*. 2011;17:1.
38. Basak S, Rajurkar MN, Mallick SK. Detection of Blastocystis hominis: a controversial human pathogen. *Parasitology research*. 2014 Jan;113(1):261-5.

- Arthroplasties for hip fracture in adults.

Lewis SR, Macey R, Parker MJ, Cook JA, Griffin XL. *Cochrane Database Syst Rev*. 2022 Feb 14;2(2):CD013410. doi: 10.1002/14651858.CD013410.pub2.PMID: 35156194 Review.

- Surgical interventions for treating intracapsular hip fractures in older adults: a network meta-analysis.

Lewis SR, Macey R, Stokes J, Cook JA, Eardley WG, Griffin XL. Cochrane Database Syst Rev. 2022 Feb 14;2(2):CD013404. doi: 10.1002/14651858.CD013404.pub2. PMID: 35156192 Review.

- Comparison of surgical complications following hip hemiarthroplasty between the posterolateral and lateral approaches.

Mansouri-Tehrani MM, Yavari P, Pakdaman M, Eslami S, Nourian SMA. Int J Burns Trauma. 2021 Oct 15;11(5):406-411. eCollection 2021. PMID: 34858721 **Free PMC article.**

- Is bipolar hemiarthroplasty a reliable option for Ficat stage III osteonecrosis of the femoral head? 15- to 24-year follow-up study.

Hwang KT, Kim YH, Kim YS, Choi IY. Arch Orthop Trauma Surg. 2012 Dec;132(12):1789-96. doi: 10.1007/s00402-012-1613-5. Epub 2012 Sep 15. PMID: 22983096

- [Mid-term effectiveness of total hip arthroplasty with collum femoris preserving prosthesis].

Li M, Hu Y, Li K, Liao Q, Wen T, Zhong D. Zhongguo Xiu Fu Chong Jian Wai Ke Za Zhi. 2012 Aug;26(8):897-901. PMID: 23012917 Chinese.

- Bateman bipolar hip arthroplasty. A review of 44 cases.

Mannarino F, Maples D, Colwill JC, Swanson AB. Orthopedics. 1986 Mar;9(3):357-60. doi: 10.3928/0147-7447-19860301-07. PMID: 3960773