

## Cardiac manifestation of COVID-19 patients and their outcome

### Abstract:

COVID-19, the novel corona virus disease of 2019 pandemic caused by the SARS-CoV-2 virus has imminently threatened all of us having significant morbidity and mortality all around the world. Upper respiratory tract infection, pneumonia, severe acute respiratory distress syndrome, multiorgan failure or even death can be the manifestation of COVID-19. However, 'n' number of cardiac complications including acute myocardial injury, myocarditis, arrhythmia, pericarditis, decompensated heart failure and cardiogenic shock has been described so far. We report the first systematic and comprehensive echocardiographic evaluation of patients requiring hospitalization for COVID-19 infection. It was found that 32% of patients with COVID-19 have normal echocardiography. Out of all unavoidable cardiac complications in covid-19, due to pulmonary parenchymal and vascular disease, Right Ventricular (RV) dilation with or without dysfunction is the most frequent abnormality in patients who earlier had normal heart function. So, one of predictor of mortality in COVID-19 patients might be a RV function evaluation. The right ventricle dysfunction is at high risk in COVID-19 patients just because of its pathophysiological relevance. RV dysfunction is potentially resulting due to cytokines with its negative inotropic effects, directly angiotensin converting enzyme 2-mediated cardiac injury, acute respiratory distress syndrome and pulmonary embolism. They all are increasing preload and provoking RV failure. So, decrease in mortality and improvement in patient outcomes in COVID-19 patients can be achieved by early detection and management of right ventricle dysfunction. There is lack of data from the central India, so the study is being conducted.

KEYWORDS: COVID-19, RV Dysfunction, 2D ECHO, acute respiratory distress syndrome, pulmonary embolism

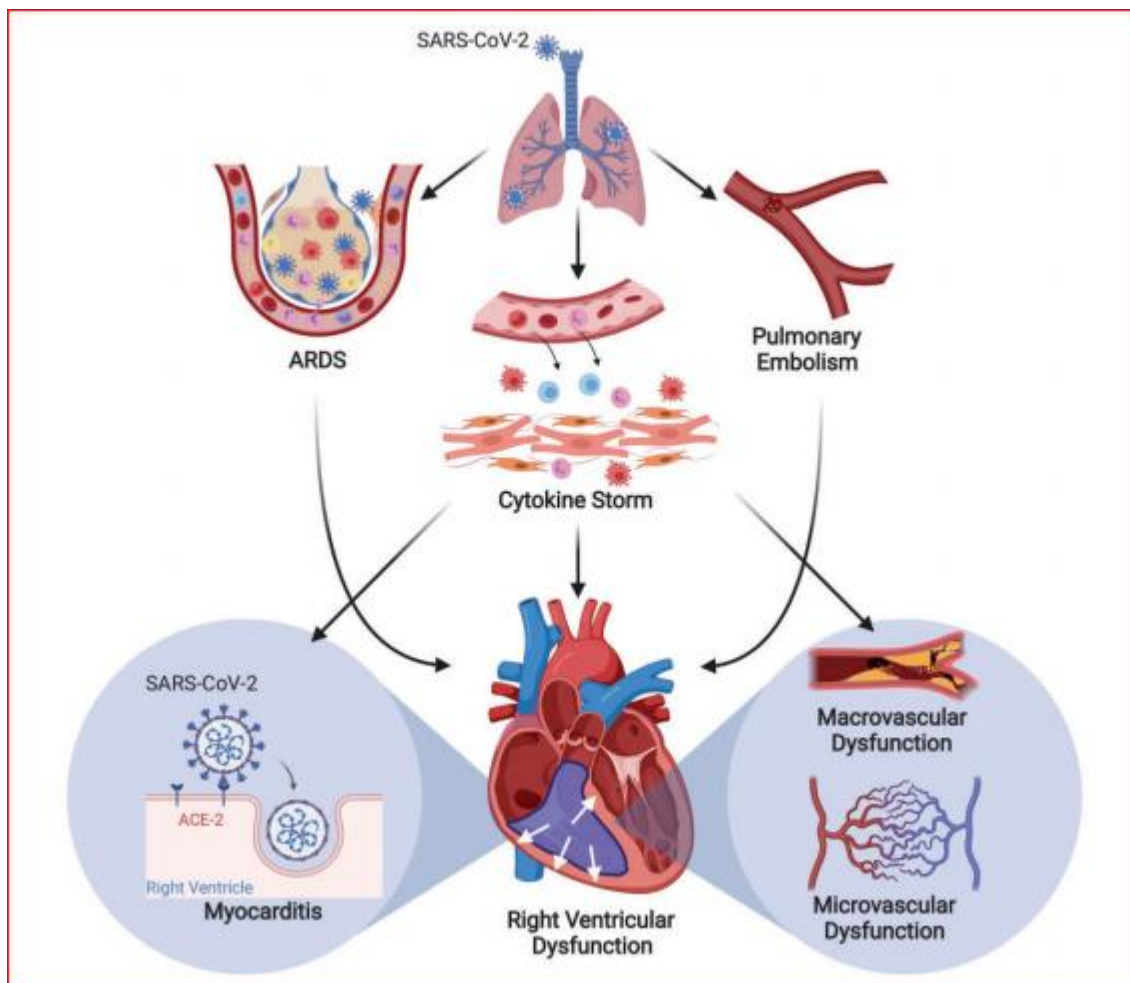
### Introduction

(COVID-19), The novel corona virus disease 2019, has threatened us from self-limiting mild upper respiratory tract infection to severe lower respiratory tract infection [pneumonia, acute respiratory distress syndrome (ARDS)], multiorgan dysfunction may leading to death [1,2] causing mortality and residual morbidity all over the world. Unavoidable cardiac complications and acute respiratory distress syndrome are fatal enough to cause high death rate. According to recent reports [1,3] cardiac complications has increased mortality and has high prevalence in COVID-19 [3].

However, laboratory parameters (troponin I) and only clinical assessment were utilised to calculate mortality and morbidity without any cardiac image based studies. In fact, patients with myocardial injury have markedly high mortality than normal individuals (59.6% vs. 8.9) in COVID 19. Cardiac arrhythmias, ischemia, decompensated heart failure and cardiogenic shock are the various cardiac disease presentation of infection in COVID-19 [4,5].

Heart failure and its multiple causes being best diagnosed with the help of transthoracic 2D echocardiography (2D ECHO) which supports patient, hospitalized in intensive care units for risk assessment ,hemodynamic evaluation and it’s management .We will be conducting a transthoracic 2D ECHO examination of Patients with HRCT thorax (CT index 9 and more) highly suggestive of covid-19 infection.

Frequency of cardiac abnormalities will be assessed. Whether a provoked viral infection directly or indirectly by stress or cytokine induced myocardial dysfunction causing all cardiac complications or not, still unknown. Interestingly, in a recent study COVID-19 patients had Right Ventricular (RV) dilation with diminished function associated with elevated pulmonary arterial systolic pressure who earlier had normal heart function. So, one of the significant indicator of mortality in COVID-19 patients might be a RV function evaluation [6]



**Pic 1. Mechanisms of RV dysfunction in COVID-19**

**Picture:** Mechanisms of RV dysfunction in COVID-19. Schematic presentation associated with acute respiratory distress syndrome (ARDS), pulmonary embolism, cytokine storm, micro- and macro vascular dysfunction. Also a direct angiotensin-converting enzyme 2 (ACE2)-mediated effects of SARS-CoV-2 virus on the right ventricle.

The right ventricle dysfunction is at high risk in COVID-19 patients just because of its pathophysiological relevance. Patho-physiological relationship of RV with pulmonary vasculature leading to RV dysfunction and failure plays an important role in the sudden onset

hemodynamic deterioration or arrhythmias or even a sudden cardiac death in patients with COVID-19. RV dysfunction is potentially resulting due to cytokines with its negative inotropic effects, directly angiotensin converting enzyme 2-mediated cardiac injury, ARDS and pulmonary embolism. They all increasing preload and provoke RV failure. So, to decrease in mortality and improvement in patient outcomes in COVID-19 patients can be achieved by early detection and management of right ventricle dysfunction. There is lack of data from the central India, so the study is being conducted.

## **AIM AND OBJECTIVES**

### **Aim**

- To study cardiac manifestations of COVID-19 patients and its outcome.

### **Objectives**

- To perform a transthoracic 2D echocardiographic (2D-ECHO) evaluation of moderate to severe patients COVID-19 infection (**HRCT Score of 9 and more**) requiring hospitalization.
- To assess the frequency of cardiac abnormalities.
- To examine the echocardiographic parameters and clinical condition (NEWS 2).
- To correlate clinical outcome during their hospitalization with echocardiographic assessment.

### **Research Question-**

- Are Cardiac Manifestations very common in COVID-19 patients?

### **Null hypothesis**

- Cardiac functions are normal in COVID-19 patients.

### **Alternate hypothesis**

- Cardiac Manifestations are common in COVID-19 patients.

## **“PICOT” DEPICTION OF THE STUDY**

**P-** Patients having HRCT thorax (CT index 9 and more) highly suggestive of covid-19 infection.

**I-** Assessment of cardiac function by 2D echocardiography

**C-** Nil

**O-** Outcome cardiac abnormalities, Duration of Hospital stay discharge or death.

**T-** Duration of study will be 6 months or till the sample size is achieved.

## **MATERIAL AND METHOD**

### **Material**

- The study will be done in Acharya Vinoba Bhave Rural Hospital (AVBRH), Sawangi (Meghe), a 1525 inpatient capacity, fully equipped teaching hospital attached to Jawaharlal Nehru Medical College, Wardha, Maharashtra.

### **Duration**

- Study duration will be 6 months or till the sample size is achieved.

### **Study Design**

- Prospective observational study

### **Inclusion Criteria**

- Patients with HRCT thorax (CT index 9 and more) highly suggestive of covid-19 infection, with or without positive RTPCR/RAT

### **Exclusion Criteria**

- Patients presenting with heart failure or history of heart failure
- Patients with low CT Index (< 9)

### **Sample Size:**

As prevalence of cardiac manifestations were present in 65% (reference), taking 95% confidence interval, 10 power of the study, and 5% margin of error, the sample size came to be around 78.

### **Data Collection:**

Prospectively, we will be studying 78 hospitalised adult patients ( $\geq 18$  years of age) with HRCT thorax highly suggestive of COVID-19 (CT index 9 and more) with or without RTPCR or RAT positive.

We will record their socio-demographic data, comorbid conditions. Their physical examination will be done on admission. HRCT thorax and laboratory investigations (including D-dimer, CRP, and Serum Ferritin) will be recorded. Risk-stratification will be done according to their COVID-19-NEWS2 score. [7, 8] All patients will be undergoing comprehensive detailed transthoracic 2D echocardiography on admission or within 24 hours as per our protocol.

Clinical cardiac manifestations like pulse, blood pressure, signs of heart failure, ECG for arrhythmias will be noted daily during their hospital stay. Clinical outcome i.e. deterioration and/ or improvement will be evaluated using COVID-19 WHO Ordinal scale.

In case of discharge or death, day of discharge and day of death will be noted respectively and duration of hospital stay will be calculated. Evaluated subtle echocardiographic abnormalities of COVID-19 patients will be compared with the reference values published previously [9,10,11]

### **Echocardiography**

Experienced cardiologist in echocardiographic recording and interpretation will be doing 2D ECHO with the equipment - Philips HD11XE, 2-4 MHZ. Linear probe will be used for ECHO

### **Left Ventricular Assessment**

4 chamber view of heart is obtained; Left ventricle is visualized. 2 screen view of heart is selected. Left ventricle in diastole is noted and image selected. Now, in the second screen left

ventricle in systole is selected and image is captured. Now by selecting Simpson's formula, LV EDV and LV ESV are calculated by tracing the LV inner borders in diastole and systole.

Left ventricle Ejection Fraction is calculated by formula:

$$EF = \frac{(LV\ EDV - LV\ ESV)}{(LV\ EDV)} \times 100$$

Left ventricular (LV) mass, volumes, diameters and left ventricular ejection fraction will be determined. [10] The velocities of peak, early filling (E wave) and late diastolic filling (A wave), E/A ratio and early filling velocity deceleration period will be included in Mitral inflow measurements. Mitral septal and lateral annular velocities (e') of early diastole will be calculated, in the apical 4-chamber view [10]. Volume of left atrium will be measured with the biplane area to length method when the systole ends. From the LV outflow tract, stroke volume will be determined, will be helpful in measurement of cardiac index and output.

### Right Ventricular Assessment

In 4-chamber apical views, the whole right ventricle (RV) is being seen, so at the end of systole and diastole RV areas and length of tricuspid annulus will be measured. RV function will be assessed by tricuspid annular plane systolic excursion, systolic tricuspid lateral annular velocity (RV S') will be measured in the 4-chamber apical view. Also fractional area change and myocardial output index (Tei index) is calculated in addition for qualitative grading. For the right-sided hemodynamic evaluation, the velocity of acceleration time of pulmonary flow (PAT) is calculated for determining pulmonary vascular resistance.

### HRCT Thorax

High Resolution Computed Tomography (HRCT) will be done by SOMATOM SCOPE POWER, G-XL-81609 equipment. It can detect ground glass opacities (GGO) more easily in the early stage [12]. The chest CT is very easy to do. Reports will be available faster than RTPCR reports. It enables early and quick diagnosis of initial pneumonia in COVID-19 [13]. The sensitivity of RTPCR was inferior to that of CT thorax (71% vs. 98%, respectively), reported in some studies. Low viral load, inappropriate sample collection, different kits with variation in diagnosis rate and minimally developed technology for the nucleic acid detection are most commonly associated with the low effectiveness of measurement of viral nucleic acid through RTPCR. [14]

### CT severity Index : [15]

Chart 1.A CT score from 0 to 5 will be awarded to each lobe depending on the involved lobe (in %):

SCORE	INVOLVEMENT
0	0% involved

1	< 5% involved
2	5% to 25% involved
3	26% to 49% involved
4	50% to 75% involved
5	> 75% involved

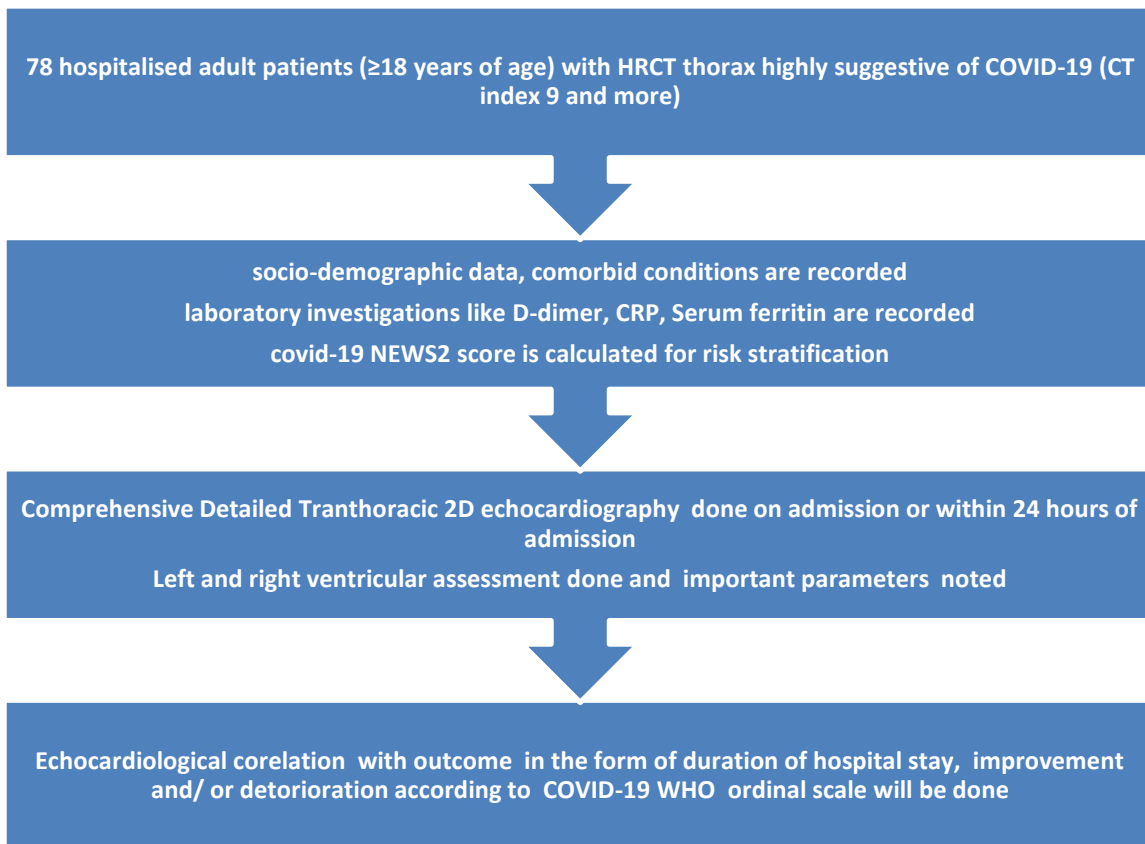
Addition of the points from each lobe will be our total CT index and it's between 0 to 25 points. The sensitivity is 80.0% and specificity is 82.8%, if we consider the CT cut-off value of 7 to identify severe cases of COVID-19.

**COVID-19 NEWS2 Score :**

It determines the illness severity of a patient and prompts need of intervention of critical care for the patients. It is a simple scoring system which includes physiological measurements. Physiological parameters include level of consciousness, temperature, pulse rate, respiration rate, oxygen saturation and systolic blood pressure.

**Chart 2. COVID-19 WHO Ordinal Scale :**

1	Patients moving with normal activities	<u>Mild Disease</u>
2	Patients moving with limited activities ,home O2 requirement, or both	
3	Hospitalized, no O2 therapy #not requiring medical care	
4	Hospitalized, no O2 therapy requiring medical care ongoing	
5	Patients in hospital with any supplemental O2	<u>Severe Disease</u>
6	Patients in hospital either on NIV (Mechanical ventilation with mask) or HFNC (High Flow Nasal Cannula)	
7	Hospitalized, IMV (Mechanical ventilation with endotracheal tube) or ECMO (Extra Corporeal Membrane Oxygenation)	
8	Patient succumbed	



Pic 2. Study morphology

### **Statistical Analysis:**

Null hypothesis for our research is that there are no significant cardiac manifestations of COVID 19. Research shows that cardiovascular complications and manifestations are prevalent in COVID 19X (Alternate hypothesis)[3,4,5,6 ] STATA Version 14 will be used for analysis. The characteristics of study participants like age, gender, NEWS 2 score and WHO score will be described using frequencies, means, and standard deviations (SD). The Student T Test will be used to compare the means of normally distributed data. Cox-regression methods will be used to evaluate independent risk factors for its outcome like mortality and duration of hospital stay. Categorical variables will be used for Two-tailed Fisher's exact test or chi-squared tests. P-value of <0.05 for the primary endpoint will be considered statistically significant.

### **Results And Discussion**

Many studies reflect on effects of Covid -19 on various systems [16-20]. With our best knowledge, our study will be the systematic as well as first Echocardiographic study of patients of COVID-19 infection in India. We will be discussing the most commonly found abnormality in Echocardiography study in patients of COVID-19. We expect nearly 33% of patients may be having normal 2D ECHO. In accordance with the previous publications, the most common expected echocardiographic abnormality may be RV dilatation with or

without dysfunction. We will be discussing risk factors associated with Right ventricular dysfunction. Conditions like pulmonary embolism, pulmonary vasoconstriction leading to hypoxia, loss of lung volume, pneumonia, excess of positive end-expiratory pressure, carbon dioxide retention or a combination of any are the factors increasing pulmonary vascular resistance patients who were hospitalised and may be acutely precipitating RV dysfunction. Patients who are older with comorbidities along with worse lung disease (CT Index >9), hypoxia, high filling pressure of left ventricular and raised biomarkers like CRP, D-dimer and troponin-I may cause increase vascular resistance in pulmonary circulation of patients with infection of COVID-19. Hence, we propose multiple factor causes like raised pulmonary vascular resistance, high left atrial pressure and parenchymal lung disease may manifest as a cardiac injury.<sup>22-24</sup>

### **Study Limitations**

As the small number of patients has been studied, outcome analysis interpretation should be considered cautiously. Patients having symptoms of heart failure or history of heart failure has been excluded from study. Patients with low CT Index (< 9) also been excluded.

### **Conclusions and Clinical Implications:**

Our study will give the evidence that heart may be involved in COVID- 19 even if no structural heart disease is there. We will be studying the cardiac abnormality in the COVID-19 patients. An echocardiogram can be useful in identifying aetiology of cardiac injury and possibly targeted treatment. Follow up for long term is required among post-COVID patients to study the delayed cardiac dysfunction or complications of COVID-19.

### **Ethical Approval:**

As per international standard or university standard written ethical approval will be collected and preserved by the author(s).

### **Consent**

As per international standard or university standard, patients' written consent will be collected and preserved by the author(s).

### **References:**

1. Zhou F, Yu T, Du R, Fan G, Liu Y, Liu Z, et al. Clinical course and risk factors for mortality of adult inpatients with COVID-19 in Wuhan, China: a retrospective cohort study. *Lancet*. 2020 Mar 28;395(10229):1054–62.
2. Bhatraju PK, Ghassemieh BJ, Nichols M, Kim R, Jerome KR, Nalla AK, et al. Covid-19 in Critically Ill Patients in the Seattle Region - Case Series. *N Engl J Med*. 2020 May 21;382(21):2012–22.
3. Guo T, Fan Y, Chen M, Wu X, Zhang L, He T, et al. Cardiovascular Implications of Fatal Outcomes of Patients With Coronavirus Disease 2019 (COVID-19). *JAMA Cardiol*. 2020 Jul 1;5(7):811.

4. Fried JA, Ramasubbu K, Bhatt R, Topkara VK, Clerkin KJ, Horn E, et al. The Variety of Cardiovascular Presentations of COVID-19. *Circulation*. 2020 Jun 9;141(23):1930–6.
5. Clerkin KJ, Fried JA, Raikhelkar J, Sayer G, Griffin JM, Masoumi A, et al. COVID-19 and Cardiovascular Disease. *Circulation*. 2020 May 19;141(20):1648–55.
6. Li Y, Li H, Zhu S, et al. Prognostic value of right ventricular longitudinal strain in patients with COVID-19. *JACC Cardiovasc Imaging*, Epub ahead of print 2020. <https://doi.org/10.1016/j.jcmg.2020.04.014>
7. Lambden S, Laterre PF, Levy MM, Francois B. The SOFA score: development, utility and challenges of accurate assessment in clinical trials. *Crit Care*. 2019;23:374. doi: 10.1186/s13054-019-2663-7
8. Liao X, Wang B, Kang Y. Novel coronavirus infection during the 20192020 epidemic: preparing intensive care units—the experience in Sichuan Province, China. *Intensive Care Med*. 2020;46:357–360. doi: 10.1007/s00134-020-05954-2
9. Lang RM, Badano LP, Mor-Avi V, Afilalo J, Armstrong A, Ernande L, Flachskampf FA, Foster E, Goldstein SA, Kuznetsova T, et al. Recommendations for cardiac chamber quantification by echocardiography in adults: an update from the American Society of Echocardiography and the European Association of Cardiovascular Imaging. *J Am Soc Echocardiogr*. 2015;28:1–39.e14. doi: 10.1016/j.echo.2014.10.003
10. Nagueh SF, Smiseth OA, Appleton CP, Byrd BF 3rd, Dokainish H, Edvardsen T, Flachskampf FA, Gillebert TC, Klein AL, Lancellotti P, et al. Recommendations for the evaluation of left ventricular diastolic function by echocardiography: an update from the American Society of Echocardiography and the European Association of Cardiovascular Imaging. *J Am Soc Echocardiogr*. 2016;29:277–314. doi: 10.1016/j.echo.2016.01.011
11. Kitabatake A, Inoue M, Asao M, Masuyama T, Tanouchi J, Morita T, Mishima M, Uematsu M, Shimazu T, Hori M, et al. Noninvasive evaluation of pulmonary hypertension by a pulsed Doppler technique. *Circulation*. 1983;68:302–309. doi: 10.1161/01.cir.68.2.302
12. J. Wei, H. Xu, J. Xiong, Q. Shen, B. Fan, C. Ye, et al., Novel Coronavirus (COVID-19) pneumonia: serial computed tomography findings, *Korean J. Radiol.* 21 (4) (2019) 501–550, <https://doi.org/10.3348/kjr.2020.0112> 2020.
13. Z.Y. Zu, M.D. Jiang, P.P. Xu, W. Chen, Q.Q. Ni, G.M. Lu, et al., Coronavirus disease 2019 (COVID-19): a perspective from China, *Radiology*(2020) 200490, <https://doi.org/10.1148/radiol.2020200490> ([Epub ahead of print]).
14. Y. Fang, H. Zhang, J. Xie, M. Lin, L. Ying, P. Pang, et al., Sensitivity of Chest CT for COVID-19: Comparison to RT-PCR, *Radiology* (2020) 200432, <https://doi.org/10.1148/radiol.2020200432> ([Epub ahead of print])
15. Piotr G. Wasilewski, A, E, F Bartosz Mruk, E, F Samuel Mazur, E Gabriela Półtorak-Szymczak, F Katarzyna Sklinda, E, F and Jerzy Walecki A, E COVID-19 severity scoring systems in radiological imaging – a review.
16. Jagtap G, Talwar D, Kumar S, Acharya S, Ansari I, Rajput M. Type 2 myocardial infarction in COVID19: World’s first case series. *MEDICAL SCIENCE*. 2021 Jul;25(113):1583–8.

17. Pawar T, Talwar D, Kumar S, Banode P, Takey P, Khanna S, et al. Stroke in young: An unusual presentation of COVID-19. *MEDICAL SCIENCE*. 2021 Jun;25(112):1417–21.
18. Bhatia A. Role of Drugs in COVID 19 Patient: A Review. *JOURNAL OF PHARMACEUTICAL RESEARCH INTERNATIONAL*. 2021;33(36A):99–105.
19. Halani D, Jaiswal A, Kumar S, Talwar D, Madaan S. Post natal covid-19 induced severe acute respiratory distress syndrome managed with monoclonal antibody and prone ventilation. *MEDICAL SCIENCE*. 2021 Jun;25(112):1427–31.
20. Godhiwala P, Acharya S, Jagtap G, Bhake A, Shukla S. Leukemoid Reaction in a COVID-19 Patient. *JOURNAL OF EVOLUTION OF MEDICAL AND DENTAL SCIENCES-JEMDS*. 2021 Feb 8;10(6):399–400.
21. James SL, Castle CD, Dingels ZV, Fox JT, Hamilton EB, Liu Z, Roberts NL, Sylte DO, Henry NJ, LeGrand KE, Abdelalim A. Global injury morbidity and mortality from 1990 to 2017: results from the Global Burden of Disease Study 2017. *Injury Prevention*. 2020 Oct 1;26(Supp 1):i96-114.
22. Kumar A, Chery L, Biswas C, Dubhashi N, Dutta P, Dua VK, Kacchap M, Kakati S, Khandeparkar A, Kour D, Mahajan SN. Malaria in South Asia: prevalence and control. *Acta tropica*. 2012 Mar 1;121(3):246-55.
23. Chole RH, Patil RN, Basak A, Palandurkar K, Bhowate R. Estimation of serum malondialdehyde in oral cancer and precancer and its association with healthy individuals, gender, alcohol, and tobacco abuse. *Journal of cancer research and therapeutics*. 2010 Oct 1;6(4):487.
24. Pradhan S, Madke B, Kabra P, Singh AL. Anti-inflammatory and immunomodulatory effects of antibiotics and their use in dermatology. *Indian journal of dermatology*. 2016 Sep;61(5):469.
25. Acharya S, Shukla S, Mahajan SN, Diwan SK. Acute dengue myositis with rhabdomyolysis and acute renal failure. *Annals of Indian Academy of Neurology*. 2010 Jul;13(3):221.
26. Gadbail AR, Chaudhary M, Patil S, Gawande M. Actual Proliferating Index and p53 protein expression as prognostic marker in odontogenic cysts. *Oral Diseases*. 2009 Oct;15(7):490-8.