

Quantitative Analysis Of Gross Morphology Of Placenta In Normal And Hypertensive Patients

Abstract:

Background: Placenta is an important organ and the growth and development of fetus is dependent on it. The different pregnancy complications as antepartum haemorrhage, postpartum haemorrhage, coagulopathy etc. in mothers and IUGR (intrauterine growth retardation), prematurity etc. in foetus are reflected in the placenta & are associated with pregnancy induced hypertension(PIH) . They form the major causes of maternal and fetal mortality & morbidity.

Objectives:

1. Quantitative analysis of the changes in gross morphology of placenta in normal and hypertensive pregnancies.
2. To study the resultant effect on the foetal outcome.

Material & Methods: We had taken 100 placentas of normal & hypertensive group patients each for study .We collected them from the labour room & operation theatre of Dept. of Obstetrics & Gynaecology of our medical college. Gross morphological features of placentas like size, weight, no. of cotyledons , areas of infarction, retroplacental clot, calcification and insertion of umbilical cord etc. were noted and simultaneously the histological study was also done.

Observations & Results: The gross morphological parameters like diameter , size, surface area, number of cotyledons and weight were reduced in hypertensive placentas than normal placentas while areas of infarction, retroplacental clot, calcification were more in hypertensive placentas than normal placentas. ($p < 0.005$) The observed differences were statistically significant.

Keywords: PIH(Pregnancy Induced Hypertension) , infarction, retroplacental clot, calcification,, intrauterine growth retardation, preterm delivery.

Introduction:

Each and every organism exhibits reproduction as a feature. We all know that ‘mother and foetus’ are the two important ends of this process . The existence of foetus in the intrauterine life is dependent on the important organ i.e. ‘Placenta’.

The hypertensive disorder in pregnancy also known as preeclampsia is a multisystem disorder having symptom complex of raised blood pressure, oedema and / or proteinuria¹ and affects 5-7% of all pregnancies worldwide.

Generally we study the hypertensive disorders in pregnancy as five types :

- 1.Gestational hypertension
- 2.Preeclampsia
- 3.Eclampsia
- 4.Preeclampsia superimposed on chronic hypertension
- 5.Chronic hypertension

The development of placenta as well as the development of foetus is affected by the PIH .The size and weight of placenta decreases as pregnancy induced hypertension severity increases² .There is also a significant rise in the incidence of intrauterine growth retardation and still birth when the placental weight is on lower side. With low placental weight, low birth weight is observed³ . Preeclampsia begins to abate with the delivery of the placenta because the root cause of preeclampsia is the placenta i.e. presence of trophoblast tissue⁴ .

It is generally believed that in preeclampsia there is impairment of trophoblast invasion . So “preeclampsia” is associated with abnormally shallow placentation ⁵ . That means the **hypoinvasive** placental phenotype is the characteristic of **preeclampsia** ⁶ .

This reduced invasion of the trophoblasts is supposed to be the main important factor in the development of intrauterine growth retardation of the foetus and preeclampsia in mother .

This ultimately results into unfavorable outcome of the pregnancy increasing the maternal and perinatal morbidity and mortality. In this study , we observed gross changes in hypertensive placentas so as to compare them with the placentas of normal pregnancies both quantitatively and qualitatively and also study their effect on foetal outcome .

Materials and methods :

The placentas were collected from the labour room and operation theatre of Department of Obstetrics and Gynaecology of our medical college. The gross features of the placentas such as weight, size, infarction, calcification or any retro placental clot were noted. Foetal gross observation done and findings noted like APGAR score, weight ,reflexes, maturity etc. APGAR score is calibrated by colour, cry, activity, heart rate and muscle tone of the baby. Low APGAR generally denotes birth asphyxia of the baby.

Also, for the histological study, biopsies of 5mm. size were taken from the centre as well as from the peripheral part of each placenta.

The following steps were followed 1] Fixation 2] Dehydration 3] Clearing 4] Wax Impregnation

After this the tissues underwent Section Cutting:(5-7 micron thick sections were cut.)

& Staining: Following stains were used for the present study:

i Haematoxylin and Eosin(H&E Stain) & ii. Masson’s Trichrome Stain

Observations and Results:

The present study entitled was carried out in the department of Anatomy .The placentas were collected from the labour room and operation theatre immediately after parturition and stored in 10% formal saline and subjected to gross morphological study and subsequently tissues were collected for histological study. Two sets having 100 placentas each were taken for the study.

The Placentas were studied in the following Groups.

Group I - Normal Pregnancy

Group II - Pregnancy with history of PIH (Pregnancy Induced Hypertension).

Table 1] **Distribution of study participants according to Gestational Age**

Gestational age (weeks)	Mean(weeks)	SD	P value
Normal Patients	38.22	1.750	0.000
Hypertensive Patients	36.79	2.281	

t value = 4.97 , P value = 0.000

Distribution of study participants according to Gestational Age

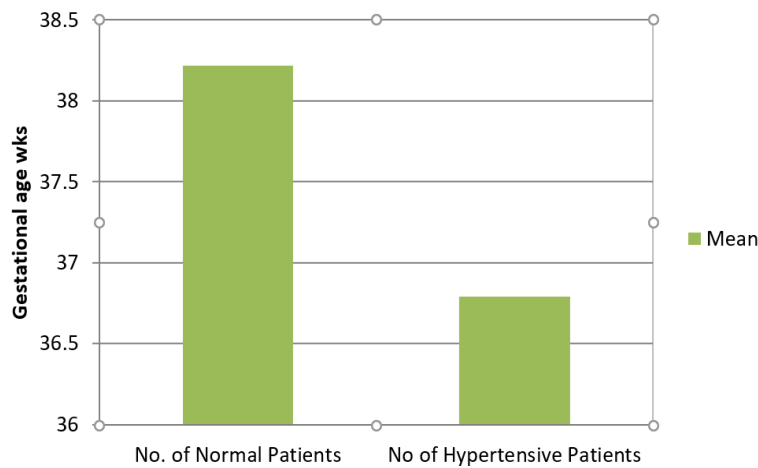


Fig 1: Observed difference was statistically significant.

In our study, in **hypertensive** pregnancy 62 % of patients were below 36(32-36) weeks of gestation i.e. **preterm** and In **normal group** , 63 % were between 37-41 wks i.e. **full term**. This shows that the proportion of preterm gestation and prematurity is more in patients of hypertension in pregnancy.

Table 2] **Distribution of Study participants according to size of placenta**

Size of Placenta(cm)	Mean(cm)	SD	P value
Normal	18.13	1.81	0.000
Hypertensive	16.32	2.14	

We found the mean diameter of the placenta in hypertensive patients is smaller i.e. 16 cm (2.14 sd) and that in normal placenta was bigger i.e.18 cm (1.81 sd)

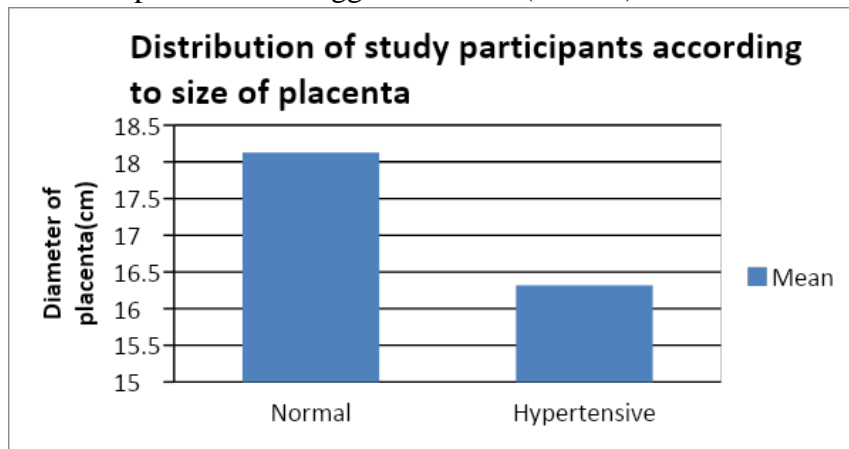


Fig 2:Observed difference was statistically significant

Table 3] Distribution of Study Participants According To Weight of Placenta

Weight of Placenta(gm)	Mean weight (gm)	SD	P value
Normal	469.60	59.35	0.000
Hypertensive	388.60	93.70	

We found the mean weight of the placenta in hypertensive patients is smaller i.e. 388 gm (93.70 sd) and that in normal placenta was bigger i.e.469gm (59.35 sd)

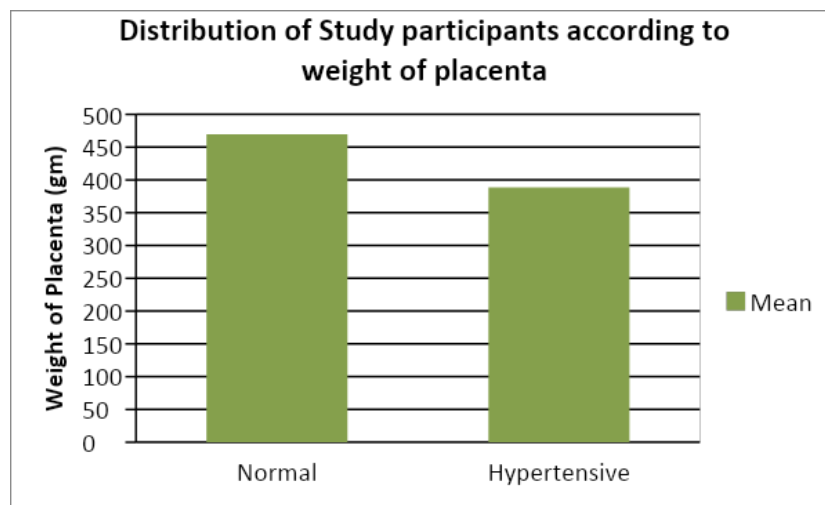


Fig 3 Observed difference was statistically significant

So, when we studied the morphology of placenta, we recorded the weight (gm) and the size i.e. diameter (cm) of placenta and observed that in both the parameters, the values were **lower in the hypertensive group as compared with the normal.**

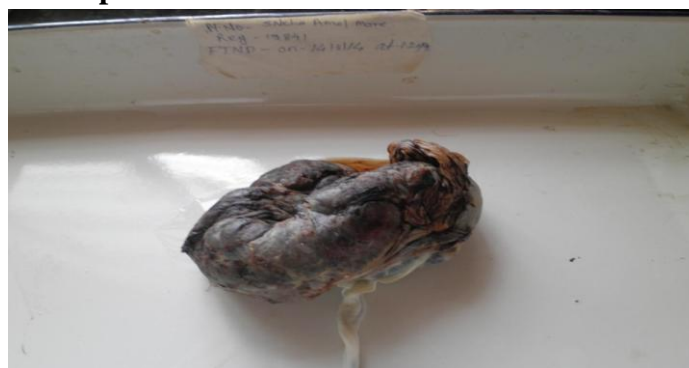

Fig 4 Small atrophic placenta

Table 4| Distribution showing mean Number of cotyledons in normal & hypertensive patients

No. of Cotyledons	Mean	SD	P value
Normal	21.45	2.45	0.000
Hypertensive	18.28	2.62	

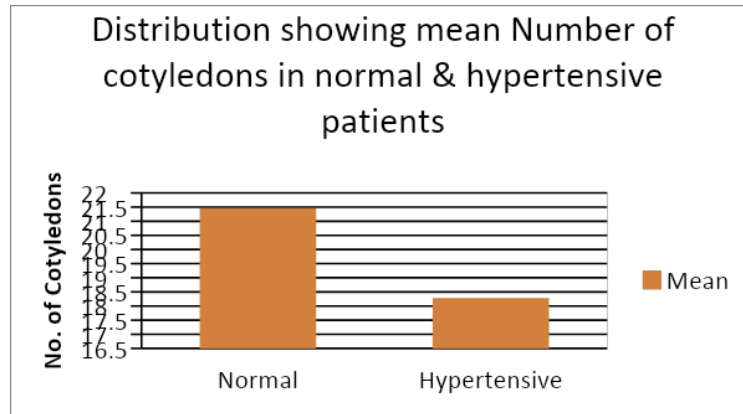


Fig 5: Observed difference was statistically significant.

In normal group 63% placentas had above 20 cotyledons and 37% had below 20 of cotyledons . According to our study ,we observed that in hypertensive group there were less no of cotyledons i.e. only16% placentas had above 20 cotyledons while 84% of the placentas had below 20 cotyledons. (some even had **less than 15** cotyledons.) So ,the mean no. of cotyledons in normal group was 21. 45 and in hypertensive group was 18. 28 .

Table 5] Distribution showing insertion of umbilical cord in normal & hypertensive .

Insertion of umbilical cord	Normal(%)	Hypertensive(%)
Central	91	80
Eccentric	8	2
Marginal	1	18

Chi square test=19.2 df =2, p value =0.00005

In **normal** patients 91% patients had central insertion of cord and 8% patients had eccentric insertion of cord and **1% only with marginal insertion** .While in **hypertensive** patients there were 80% placenta with central insertion of cord, 2% with eccentric and **18% with marginal insertion**.

We noted that **marginal insertion was a characteristic feature of hypertensive** placentas .

Table 6] Distribution showing Retroplacental clot in normal & hypertensive patients

Retroplacental clot	Normal(%)	Hypertensive(%)
Present	1	14
Absent	99	86

Chi square test = 10.38 P value =0.0006

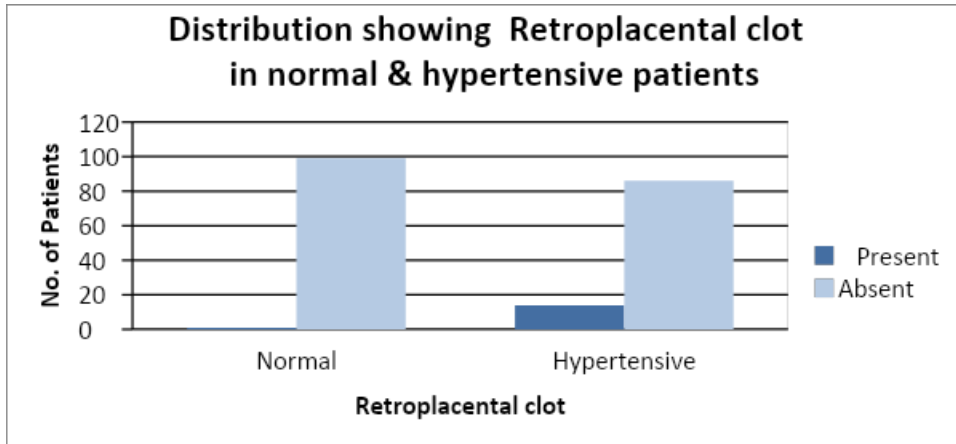


Fig 6 Observed difference is statistically highly significant



Fig 7: A large retroplacental clot on maternal surface

When we inspected the maternal surface of the placentas we found , there was only **one%** patient with retroplacental clot in the **normal** group and there were **14 %** patients with retroplacental clot in **hypertensive** group .

Table 7] Distribution showing Infarction in normal & hypertensive patients

<u>Infarction</u>	Normal(%))	Hypertensive(%))
Present	4	44
Absent	96	56

Chi square test =41. 69 P value= 0.00001

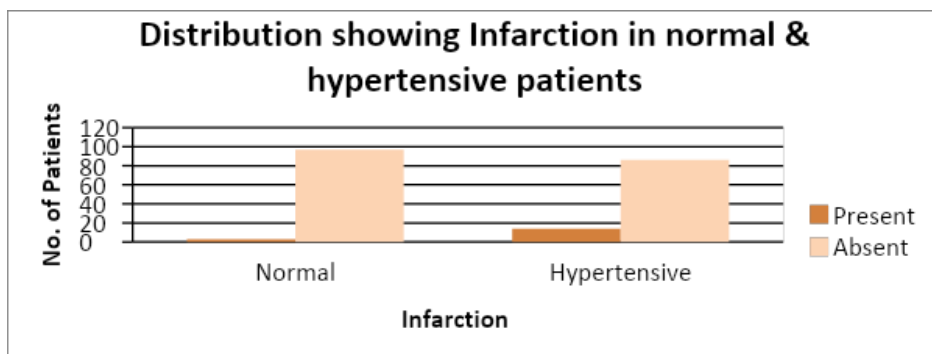


Fig 8 Observed difference is highly statistically significant.

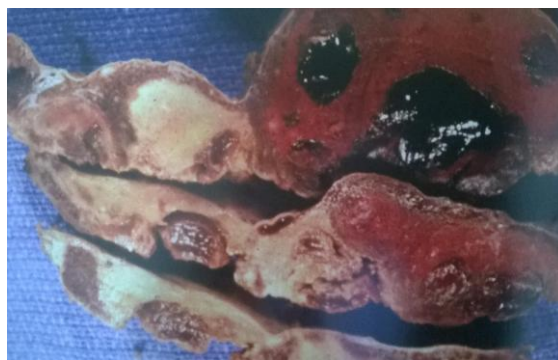

Fig 9: We see here the white areas of infarction and the areas of hemorrhage near it.

Table 8] Distribution showing Calcification in normal & hypertensive patients

<u>Calcification</u>	Normal(%)	Hypertensive(%)
Present	33	47
Absent	67	53

Chi square test=3.5 P value =0.03

In our study, **33** out of 100 patients were having calcification in **normal** group, while in **hypertensive** group, there were **47** patients with calcification of the placenta.

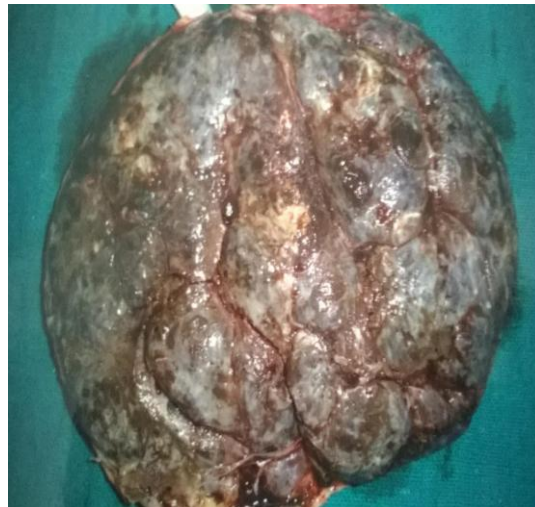


Fig 10 Calcified placenta showing multiple white spots

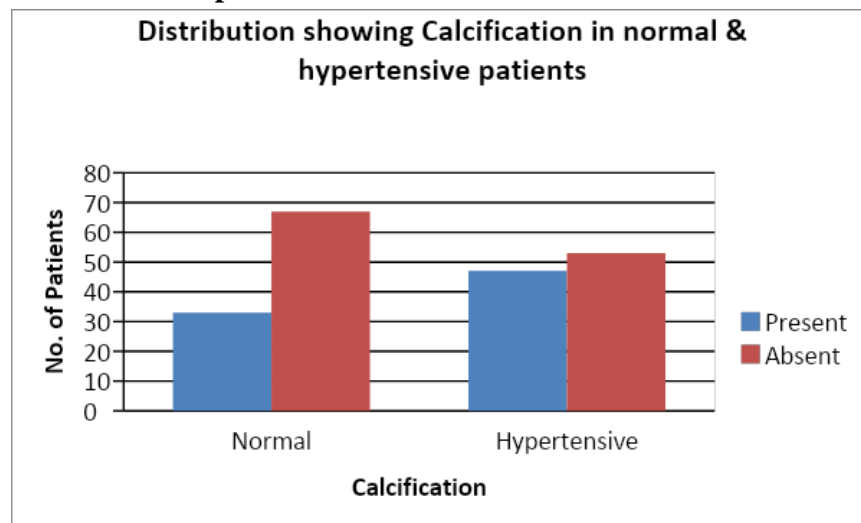


Fig 11 Observed difference was statistically significant .

Table 9] Distribution showing mean birthweight of newborn in normal and hypertensive patients

Birth weight(gm)	Mean (gm)	Std Dev	P Value
Normal	2830	46	0.000
Hypertensive	2350	56	

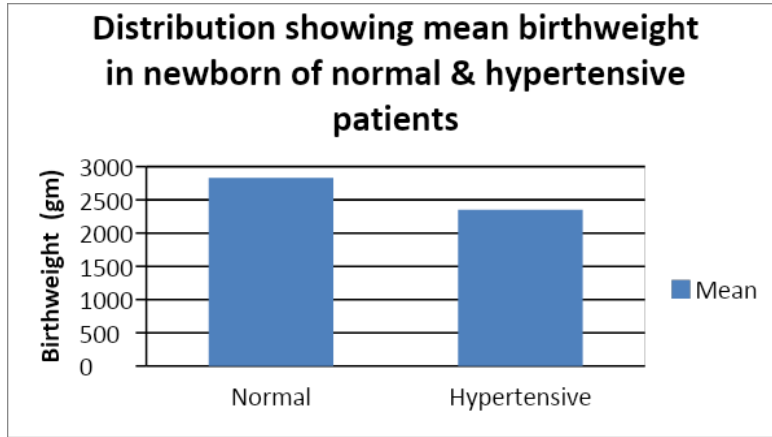


Fig 12 Observed difference was statistically significant.

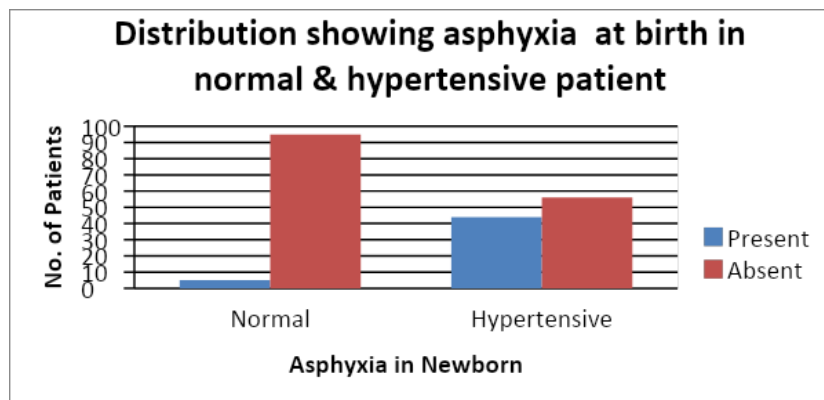
The mean birth weight in newborns of normal group was 2830 gm and in hypertensive gp was 2350 gm.

Table 10] Distribution showing asphyxia at birth in normal & hypertensive
Asphyxia Normal(%) Hypertensive(%)

	Normal(%)	Hypertensive(%)
Present	5	44
Absent	95	56
Total	100	100

Chi square test =39.03 P value = 0.0001

Fig 13



In above table, we observed that no. of babies with asphyxia in normal patients was only 5% and in hypertensive patients was 44%. So the proportion of **asphyxia in newborn in hypertensive patients was more as compared with normal patients.**

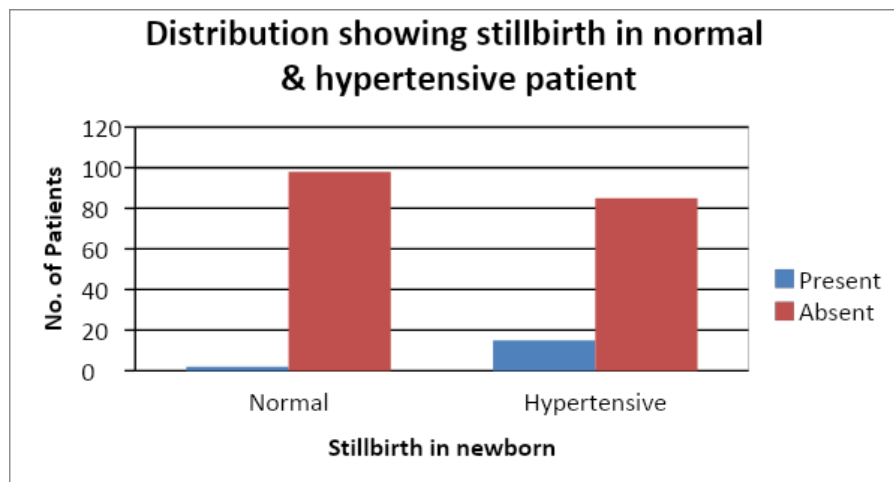
Table 11] Distribution showing stillbirth in normal & hypertensive patients

Stillbirth	Normal(%)	Hypertensive(%)
Present	2	15
Absent	98	85
Total	100	100

Chi square test =9.25 P value = 0.001

In our study ,there were only 2% stillbirth babies in normal patients & in hypertensive patients no. of stillbirth babies were 15% .So the **proportion of stillbirths was higher in hypertensive patients as compared with normal.**

Fig 14



Discussion :

Various authors have studied the gross morphological features of placentas . In our study, the gestational age at the time of delivery ranged from 32 -41 weeks in both groups . It was observed that 62 % of PIH cases had preterm delivery (below 36 wks) . This suggests that,

maximum patients of the hypertensive group were of preterm gestational age. Our findings were similar to Maham Aklaq⁷ and Vassiliki Krivelessi⁸.

Figen Barut And Aikut Barut⁹ in their study mentioned that average placental weight in normal patients was 508 gm and in hypertensive patients was 404 gm. S. kotgiwar and N.Ambiye¹⁰ and K. Devishankaran¹¹ found that in hypertensive patients the average placental weight was 291gm and in normal patients it was 573 gm .The placental weight was 427 gm in mild PIH and 374 gm in severe PIH as was found by Vissiellekki kressie.⁸

According to Thomson et al¹² in 1969 ,birth weight of foetus and weight of placenta both were below average in preeclampsia but their ratios were slightly increased . Uдания Jain in 2001¹³ and Pradeep Londhe¹⁴ in 2011, in their study found similar finding of reduced placental weight in hypertensive group than normal group.

In our study, average placental weight was 388 gm for hypertensive patients and 469 gm for normal patients.

Davies et al¹⁵ and Murthy et al¹⁶ both were of the opinion that the placental sizes assessed by area , weight or volume were significantly correlated with the weight of the neonates in case of normal delivery. The growth of the foetus is dependent upon its nutrition coming from maternal blood . The size and the surface area of the placenta available for diffusion of nutrients from mother to foetus also has effect on the foetal weight .

There were 3.5 % mean areas of infarction in placentas in normal patients while 17.4 % were the mean areas of infarction in hypertensive patients as studied by Dr. Pradeep Londhe¹⁴ .

There were 3.77 % & 16.5% areas of infarction in normal patients and hypertensive patients respectively according to the study done by Mujumdar S. and H. Dasgupta¹⁷ .

In our study, the areas of infarction were 4% in normal patients and 44% in hypertensive patients

The deposits of calcification were found as white or pale fine granules or clumps on the placenta .Our findings were nearly similar to Fox¹⁸ in 1964 who found 24.6% calcification in normal group. Pushpa Goswami et al¹⁹ in 2012, found that mean number of calcified areas of placentas in PIH were more than those found in normal patients. Majumdar S .and Dasgupta H.¹⁷ found that mean calcified areas in placenta 4.13 ± 1.15 in normal as compared to $33.3 + 3.15$ number in hypertensive patients which were significant. Our findings were nearly similar with the above findings with 33 out of 100 patients were having calcification in normal group, while **in hypertensive group, there were 47 patients with calcification** of the placenta and we had significant ‘‘p value’’.

S. Kotgirwar, M. Ambiye¹⁰ in 2011, found out of 30 cases, incidence of eccentric insertion of cord was 18 in hypertensive group & in normal group, it was 14. However, *Deeplaxmi Salmani²⁰ in 2012 ,found that the eccentric insertion was more i.e. 82% in hypertensive patients while central insertion was less i.e. 18%. Pradeep Londhe¹⁴ in 2011 found that, 11.3% of marginal insertion of cord was in hypertensive and 2.7% was in normal patients. In our study , in **hypertensive** group maximum no. of patients had central insertion while next common type

was **marginal 18%** and in control group, maximum no. was central insertion followed by next common type eccentric 2%.

Our findings were similar to Fox²¹ in 1978, who reported a higher incidence of retroplacental haematoma in PIH. Gunnapriya Raghunath, et al²² observed, 3 cases of abruption with retroplacental clots in PIH among 101 cases. Aparna Narsimha Rao²³ studied the correlation between retroplacental clots with severity of hypertension and found retroplacental clots in 22.22% cases in placentas of eclampsia & 18.5% cases in severe preeclampsia and none in placentas of normal patients. Das, et al²⁴ in 1996 found an incidence of 10% cases of retroplacental haematoma in the PIH group.

In our study, retroplacental clots in PIH was 14% compared to only 1% in normal group which was statistically significant ($p < 0.005$). Abbasi RM, et al²⁵ found 3-4 fold increase in perinatal mortality in PIH which was a leading cause of stillbirths in 45% of the patients as reported by Patil Yet al²⁶ & perinatal mortality was 52.0% in PIH (hypertensive patients) as compared to 29.8% in normotensive. Few evidences can be recollected from a number of studies²⁷⁻³⁶.

Our study also shows hypertensive disorders in pregnancy affect the perinatal outcome in the form of IUGR, increased no. of asphyxiated and stillborn infants. So, the perinatal mortality and morbidity was increased in hypertensive pregnancies in our study also.

Conclusion :

Our study was aimed to correlate the morphological changes of the PIH(hypertensive) placentas with the outcome of pregnancy and also comparison with those of the normal group. The birth weight of foetuses in hypertensive group were on lower side than the foetuses in the normal group and the APGAR score was also lower than normal. Low APGAR generally denotes birth asphyxia of the baby.

These all studies were statistically significant. The gross changes in placentas with history of PIH were retroplacental haematoma, areas of infarction and calcification, scanty no of cotyledons, reduced size, weight and surface area of the placenta and these all changes were noted in more no. in hypertensive group than in normal group. Definitely all the above observations lead to the conclusion that there was unfavorable outcome of pregnancy in hypertensive patients. The **intranatal and perinatal asphyxia was increased in hypertensive pregnancies**. We know that the placenta is the mirror image of antenatal period and provides information about it. So, it is very important that we should perform the examination of placenta adequately after every delivery as a routine procedure.

References:

1. Duley L. Pre-eclampsia and the hypertensive disorders of pregnancy. British Medical Bulletin. 2003; 67: 161–176. DOI: 10.1093/bmb/ldg005.
2. Kartha S, Poothode U, Jayalakshmy P S. Placental Pathology In Pregnancy Induced Hypertension. Journal of Evolution of Medical and Dental Sciences. 2014 August; 3(35):9272-9278. DOI:10.14260/jemds/2014/3197.

3. Ansari H , Singh A , Zaidi MT ,Chandra N.Vasculosyncytial Membrane In Placental Villi Of Normotensive And Hypertensive Pregnancies. *J Anat Soc India* .2011;60(2):168-170.
4. Roberts JM and Escudero C . The placenta in preeclampsia. *Pregnancy Hypertens*. 2012 April 1; 2(2): 72–83.doi:10.1016/j.preghy. 2012.01.001.
5. Zhou Y, Genbacev O, Damsky CH, Fisher SJ. Oxygen regulates human cytotrophoblast differentiation and invasion: implications for endovascular invasion in normal pregnancy and in pre-eclampsia. *J Reprod Immunol* 1998; 39:197–213.
6. Caniggia I, Grisaru-Gravnosky S, Kuliszewsky M, Post M, Lye SJ. Inhibition of TGF-beta (3) restores the invasive capability of extravillous trophoblasts in preeclamptic pregnancies. *J Clin Invest* 1999;103:1641–1650.
7. Akhlaq M , Nagi A H , Yousaf A W. Placental morphology in pre-eclampsia and eclampsia and the likely role of NK cells. *Indian J Pathol Microbiol*. 2012;55:17-21.
8. Krielessi, V , Papantoniou N , Papageorgiou I , Chatzipapas I , Efstathios M, Zakopoulos N ,et al. Placental Pathology and Blood Pressure's Level in Women with Hypertensive Disorders in Pregnancy *Obstetric and Gynecology International Volume*. 2012;ArticleID684083:1-6. doi:10.1155/2012/684083.
9. Barut F, Barut A, Gun B D, Kandemir NO, Harma M I, Harma M, et al. Intrauterine growth restriction and placental angiogenesis. *Diagnostic Pathology*. 2010; 5:24-30.
10. Kotgiwar S, AMBIYE M, Athawale S, Gupta V, Trivedi S. Study Of Gross And Histological Features Of Placenta In Intrauterine Growth Retardation .*J. Anat. Soc India*. 2011; 60(1): 37-40
11. Devi Sankar K , Bhanu P S , Kiran S , Ramakrishna B A and Shanthi V. Vasculosyncytial membrane in relation to syncytial knots complicates the placenta in preeclampsia: a histomorphometrical study. *Anat Cell Biol*. 2012 Jun; 45(2): 86–91.
12. Thomson A M, Billewicz W Z and Hytten F E. The weight of the placenta in relation to birth weight .*The Journal of Obstetrics and Gynecology of the British Common Wealth*.1969; 76(10) : 865- 871.
13. Udainia A , Jain ML . Morphological Study of Placenta in Pregnancy Induced Hypertension With its Clinical Relevance. *J Anat Soc India* . 2001; 50(1): 24-27.
14. Londhe PS, Mane AB. Morphometric Study Of Placenta And Its Correlation In Normal And Hypertensive Pregnancies . *International Journal of Pharma and Bio Sciences*. 2011 Oct-Dec; 2(4): 429-437.
15. Davies et al Pryse D J and Beazley J M . A Study of placental size and chorio-ammionitis in a consecutive series of hospital deliveries. *The Journal of Obstetrics and Gynaecology of the British common Wealth* . 1993; 80:246-251.
16. Murthy L S , Agarwal K N and Khanna S . Placental morphometric and morphologic alterations in maternal undernutrition. *Am. J. Obstet. Gynaecol*. 1976; 124 (6) : 641-645.
17. Majumdar S, Dasguptha H, Bhattacharya K, Bhattacharya A. A study of placenta in normal and hypertensive pregnancies. *J Anat Soc India* 2005;54:34-8.
18. Fox H. Calcification Of The placenta. *Journal of Obstetrics and Gynaecology*.1964;(1-6):759-765 j
19. Goswami P , Lata H , Memon S , Khaskhelli L B .Excessive Placental Calcification Observed in PIH Patients and its Relation To Fetal Outcome. *JLUMHS* September-December 2012;Vol11 No.03:143-148.

20. Salmani D, Purushothaman S, Somashekara SC, Gnanagurudasan E, Sumangaladevi K, Harikishan R, et al. Study of structural changes in placenta in pregnancy-induced hypertension. *J Nat Sc Biol Med.* 2014;5:352-5.
21. Fox H. Macroscopic Abnormalities Of the Placenta . In *Pathology of the placenta.* (Philadelphia. W.B. Saunders) 1978 ; pp 95-197.
22. Raghunath G , Vijayalaksmi , Shenoy V. A study on the Morphology and the Morphometry of the Human Placenta and its Clinical Relevance in a population in Tamilnadu. *Journal of Clinical and Diagnostic Research.* 2011 Apr; 5(2):282-286.
23. Narasimha A , Vasudeva D S . Spectrum of changes in placenta in toxemia of pregnancy. *Indian Journal of Pathology and Microbiology.* 2011 January-March; 54(1):15-20.
24. Das B, Dutta D, Chakraborty S, Nath P. Placental Morphology In Hypertensive Disorders Of Pregnancy and Its Correlation With Foetal Outcome. *J.Obstet.Gynaecol,India.* 1996;46:40-46.
25. Abbasi RM, Rizwan N, Mumtaz F, Farooq S. FetoMaternal Outcome among Abruptio Placentae Cases at a University Hospital of Sindh. *JLUMHS* 2008; 2:106-109.
26. Patil Y, D'costa GF. Causes of mortality in stillbirth-An Autopsy study. *Bombay hospital journal* 2007: 49 (2).
27. Jaiswal A, Halani D. Evaluation of Predictor like Maternal Serum Lipid Profile in 2nd Trimester in Pregnancy Related Hypertensive Disorders. *JOURNAL OF PHARMACEUTICAL RESEARCH INTERNATIONAL.* 2021;33(38A):195–201.
28. Dawood FS, Kittikraisak W, Patel A, Hunt DR, Suntarattiwong P, Wesley MG, et al. Incidence of influenza during pregnancy and association with pregnancy and perinatal outcomes in three middle-income countries: a multisite prospective longitudinal cohort study. *LANCET INFECTIOUS DISEASES.* 2021 Jan;21(1):97–106.
29. Inamdar, Saunitra A., Himanshi Agarwal, Sourya Acharya, and Anil Inamdar. “Coexistence of Hypertriglyceredemia and Hypercholesterolemia with Gestational Diabetes Mellitus in Pregnancy: A Case Report.” *MEDICAL SCIENCE* 24, no. 102 (April 2020): 594–98.
30. Bhatia, Avni, Aditya Bhagwat, Sourya Acharya, Amol Bhawane, and Neema Acharya. “Postpartum Haemolytic Uremic Syndrome (PHUS) with Posterior Reversible Encephalopathy Syndrome (PRES) Complicating Pregnancy: A Rare Case Report.” *JOURNAL OF CLINICAL AND DIAGNOSTIC RESEARCH* 13, no. 4 (April 2019): OD1–3. <https://doi.org/10.7860/JCDR/2019/40900.12748>.
31. Singh, Harshika, Manjusha Agrawal, Arvind Bhake, and Nihar Gupta. “COLOUR DOPPLER EVALUATION IN HIGH-RISK PREGNANCY AND PERINATAL OUTCOME.” *JOURNAL OF EVOLUTION OF MEDICAL AND DENTAL SCIENCES-JEMDS* 7, no. 43 (October 22, 2018): 4603–8. <https://doi.org/10.14260/jemds/2018/1027>.
32. Agarwal H, Acharya N, Shrivastava D, Mohammad S. Pregnancy with Uterine Prolapse - Rare Cases with Distinct Labour Outcomes. *JOURNAL OF EVOLUTION OF MEDICAL AND DENTAL SCIENCES-JEMDS.* 2021 Feb 1;10(5):329–32.
33. Dhar R, Singh S, Talwar D, Mohan M, Tripathi SK, Swarnakar R, Trivedi S, Rajagopala S, D'Souza G, Padmanabhan A, Baburao A. Bronchiectasis in India: results from the

European multicentre bronchiectasis audit and research collaboration (EMBARC) and respiratory research network of India registry. *The Lancet Global Health*. 2019 Sep 1;7(9):e1269-79.

34. Gondivkar SM, Indurkar A, Degwekar S, Bhowate R. Evaluation of gustatory function in patients with diabetes mellitus type 2. *Oral Surgery, Oral Medicine, Oral Pathology, Oral Radiology, and Endodontology*. 2009 Dec 1;108(6):876-80.
35. Khatib N, Gaidhane S, Gaidhane AM, Khatib M, Simkhada P, Gode D, Zahiruddin QS. Ghrelin: ghrelin as a regulatory Peptide in growth hormone secretion. *Journal of clinical and diagnostic research: JCDR*. 2014 Aug;8(8):MC13.
36. Nagrale AV, Herd CR, Ganvir S, Ramteke G. Cyriax physiotherapy versus phonophoresis with supervised exercise in subjects with lateral epicondylalgia: a randomized clinical trial. *Journal of Manual & Manipulative Therapy*. 2009 Jul 1;17(3):171-8.