

Case Report on Hirschsprung's Disease

Abstract

Introduction: - Hirschsprung's disease (HIRSH-SPROONGZ) is a disorder that affects the large intestine (colon) and makes passing faces difficult. As a result of missing nerve cells in the baby's colon muscles, the disease is present at birth (congenital). Hirschsprung's popularized it in 1886 after "Ruysch" recognized it in 1961. Hirschsprung's disease is an intrinsic developmental condition. The enteric nervous system has an inherent component.

Clinical Findings: - Difficulty in passing stool, Abdominal pain, Fever, (Temperature 100-degree f) Vomiting, Failure of thrive, constipation, tiredness.

Diagnostic Evaluation: - CBC Investigation, blood test, Hb-12.9%, Total RBC count-4.84million/cumm, RDW-13.2%, HCT-36.7%, Total WBC Count-26200 cu mm, Monocytes- 01%, Granulocytes- 30%, Lymphocytes- 65%, Total platelet count-3.5 Lacs/cu mm, ALT(SGPT)-17 U/L, AST (SGOT)-44 U/L.

Peripheral Smear: - RBCs-Normocytic Normochromic Platelets-Adequate on smear, No Hemiparasite seen, WBCs-Neutrophilic leukocytosis.

Therapeutic Intervention: - blood Transfusion, Inj.Aminoven 200 mg BD, Inj. Cefotaxime 400mg BD IV, Inj. Pantaprazole 12mg OD, Syp. Augmentin 3ml BD, Syp. Azee 5ml OD, Inj. Emset 1.8 mg SOS.

Outcome: - After treatment the child shows improvement his passing stool frequently and relive vomiting, fever, abdominal pain, and facial expression are good.

Conclusion: - My patient was admitted in pediatric ward no 22 at AVBRH with a known case of Hirschsprung's disease, and he had complaint of difficulty in passing stool at birth, after getting appropriate treatment and surgery his condition was improve.

Keywords: - Hirschsprung's Disease, Congenital Megacolon, Intestinal Aganglionis, Enteric nervous system, Congenital Aganglionis, Megacolon.

Introduction

Hirschsprung's Disease is a rare disease that affect the nerve cell in the intestine, causing bowel obstruction. A section of the bowel is missing nerve cell in Hirschsprung's disease (HD), these cells usually control the bowel muscles, which push the content along. The contents of the bowel continue to move until they reach the section of the bowel where the cell is missing. As a result, the poo passage become blocked or slowed¹.

Hirschsprung's Disease is caused by ganglion cell failure to migrate cephalocaudally via the neural crest from week four to twelve of pregnancy, resulting in the lack of ganglionic cells in all or part of the colon². Distal colons of varying lengths are unable to relax, resulting in functional colonic

blockage over time. Typically, the Aganglionis segment originates at the anus and extends proximally.³

The most frequent kind of short segment illness affects the rectosigmoid area of the colon. The whole colon is affected by long segment disease. The small and big intestines are both affected. The majority of patients appear in infancy, thus it's critical to get a diagnosis as soon as possible to avoid complications. Most people live regular adult lives with adequate care.⁴

Hirschsprung's Disease is an uncommon gastrointestinal illness that affects mostly the large intestine (colon) Normally, the bowel muscles contract in a regular pattern to push feces (poo) through to the rectum. The nerve ganglionic cell that controls these muscles is absent from the portion of the intestine in Hirschsprung's Disease. This means that the feces can't flow through normally. Congenital bowel is the most frequent kind of congenital bowel.

Affected newborns generally show with distal intestinal blockage in the first few days of life due to bowel motility dysfunction. Aganglionis bowel response and a "pull-through" operation to move the usually innervated intestine down to the anal border are the current treatments.⁴

The current therapies include resection of the aganglionic intestine and a "pull-through" surgery to bring the normally innervated bowel down to the anal margin². Despite advancements in surgery, long-segment HSCR, in which a longer section of bowel or the whole colon is aganglionic, can have poor results. Enterocolitis is more common in children, and up to 75% of them suffer incontinence or bladder issues. The colon as a whole is aganglionic. Children are particularly susceptible to enterocolitis, and up to 75% of them have incontinence or constipation. Some youngsters will require a colostomy for the rest of their lives.⁵

The goal of this study is to give a basic overview of Hirschsprung's disease, covering the origin and management of HSCR in children. 2 Hirschsprung's disease (HD) is a complicated enteric nerve system condition that results in functional intestinal blockage. In children aged 1 to 5.4, HD is the most prevalent cause of distal intestinal obstruction.

After almost half a century, Dr Swenson et colleagues were credited with the first description of clinical characteristics of illness in their seminal work (Hirschsprung's disease)², and he incorrectly inferred that the pathology was in the proximal dilated intestine. Various surgical methods have been reported since then, all of which are based on the removal of a ganglionic segment and anastomosis of the ganglionated Surgery is considered curative for most HD patients because it connects the intestine to the rectum.⁵

It's worth mentioning that congenital megacolon was recognized about 4000 years before Harlod Hirschsprung in prehistoric India; amazingly, they ascribed the disease's aetiology to nerve abnormalities and advised sigmoid colostomy as a therapy. ⁴ The global prevalence of HD is 1:5000, with a 4:1 male-to-female ratio. The M:F ratio is affected by the length of the sick bowel until it becomes. In complete colonic aganglionosis, the length of the aganglionic segment, which always begins distally at the internal sphincter and extends proximally to various distances, is virtually the same 1.5:1.

Aganglionosis of the short segment (rectosigmoid), which affects 80% of HD patients, total colonic aganglionosis, which affects at least the ileocecal valve but not more than 50 cm of small bowel, long segment aganglionosis, which falls between the previous two categories, and finally Zuebler syndrome (very long segment) The extremely brief portion The internal anal sphincter

achalasia, which is more accurate for pathologic entity⁵ and spans >50cm of small intestine, has taken its position.⁶

Hirschsprungs disease (HSCR) is a functional intestinal blockage caused by a congenital abnormality in the distal section of the large intestine's normal myenteric plexus parasympathetic ganglion cells. In 16916, Frederick Ruysch published the first description of congenital megacolon. It went virtually ignored in the medical community until Harald Hirschsprungs brought it up in 18871, sparking a debate. This unique illness has piqued scientists' curiosity. Despite this, it took 50 years for the important role of the distal aganglionic bowel to be revealed. A good outcome was achieved after surgical removal of the aganglionic section and anastomosis with ganglionated tissue.⁷

Treves (1898) described two types of megacolons, one resulting from chronic constipation and the other arriving suddenly. Hirschsprung's Disease (HSCR) is the most prevalent congenital gut motility disease, marked by the lack of ganglion cells (aganglionosis) in the intestine.

The distal intestine's myenteric and submucosal plexuses It is considered to be caused by a failure of enteric nervous system (ENS) precursor colonization of the distal intestine during embryonic development.⁸

Hirschsprungs disease is a condition that affects the rectum and a portion of the colon above it that can vary in length. Although it is usually just a few millimeters long, it can occasionally affect the whole intestine. While HD can run in families, no cause has been identified. Hirschsprung's disease (HSCR) is marked by a paucity of enteric nervous system ganglion cells (aganglionosis) in the distal intestine.⁶

Patient Identification: - A male child of 2 years 6 month from Burtipura Dist. Gondia admitted in pediatric ward no 22 in AVBRH on 29 Jun 2021 with a know case of Hirschsprungs disease, his weight is 10kg and his height is 90cm.

Present Medical History: - A male child of 2 years & 6-month-old was admitted to AVBRH on 29 Jun 2021 by his parents with a complaint of child was not passing stool since from birth, and fever, vomiting, abdominal pain, failure of thrive, constipation, nervousness, and he was admitted to pediatric ward no 22 he his a know case of Hirschsprungs disease, and child is weak and inactive on admission time.

Past medical history: - In My patient was diagnose to have Hirschsprungs disease, at the age of 1 year when he was admitted to hospital due to abdominal pain and vomiting that time child rectal biopsy and Abdominal X-ray is done.

Present Surgical History: - My patient was diagnosed to have Hirschsprungs disease, now the endorectal pull through surgery and colostomy closure procedure is done. and other investigation also done.

Family History: - In my patient There are three members in the family. my patient was diagnosed to have Hirschsprungs disease, and his parents are healthy and he his belongs to nuclear family. all other member of the family is healthy were not having any other complaints in their health except my patients who was being admitted in the hospital at AVBRH.

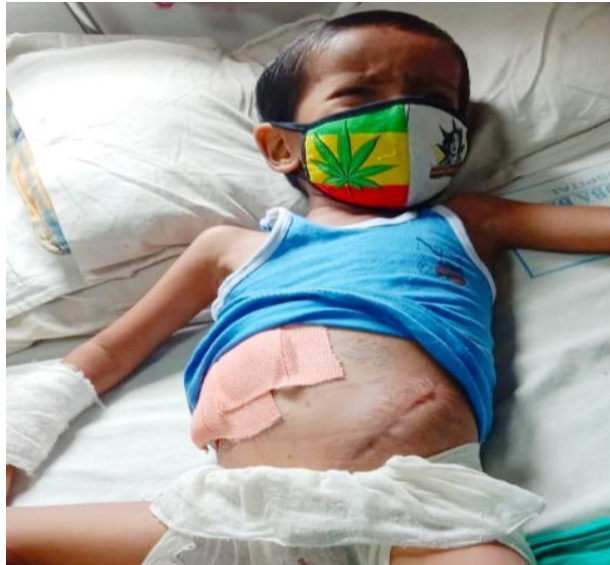

Fig 1. Patient with symptoms

Past Intervention and Outcome: - The patient was diagnosed with a Hirschsprungs disease, when he was 1 year old. from that time onwards he was admitted to the hospital in abdominal pain and vomiting and difficulty in passing stool that time rectal biopsy and Abdominal X-ray is done. then he is diagnosed as Hirschsprung's Disease. Then time to time for further treatment of the disease it was found effective as the patient does not develop complication till them.

Clinical Finding: - Difficulty in passing stool, abdominal pain, fever (temperature 100-degree f), vomiting, Failure of thrive, constipation, tiredness and nervousness.

Etiology: - The aetiology of Hirschprung's Disease is unknown. It can run in families and be linked to a genetic mutation in some situations. Hirschprung's Disease develops when nerve cells in the colon do not regenerate fully. The muscular contractions that transport food through the intestines are controlled by a nerve in the colon. The gastric ulus are controlled by the enteric neural system, which is composed of a network of nerves. the physiology of the gastrointestinal system in a mostly autonomous way.

Physical Examination: - There is not much abnormality found in head-to-toe examination except abdomen in abdomen it's found in abdominal distention the child is then and having dull look he is weak and not so cooperative and his irritable and so tired.

Diagnosis Assessment: - CBC Investigation, Blood test, Hb -12gm%, Total RBC Count - 4.84million /cu mm, RDW-13.2%, HCT-36.7%, Total WBC Cont-26200 /cu mm, Monocytes-01%, Granulocytes-30%, Lymphocytes-65 %, AST (SGOT)-44U/L, ALT (SGPT)-17, Alkaline phosphate-239 U/L, Total protein-6.7 g/dl, Albumin-3.7 g/dl, Globulin-3.0gm/dl, Total bilirubin-

0.3 mg / dl, Bilirubin Conjugated-0.1 mg / dl, Bilirubin Unconjugated-0.2 mg /dl, Platelet Count 3.5 micro litter, MCV -75.8%, MCH -26.7 %, MCHC -35.1%.

Eosinophil -01%, Basophil 0%, KFT-Urea 18%, Creatinine – 03 %, Sodium – 142%, Potassium-4.8%,

Peripheral smear: - RBCs-Normocytic Normochromic Platelets-Adequate on smear, No Hemiparasite seen, WBCs-Neutrophilic leukocytosis.

Radiological Investigation: - There is a functional blockage with reduced peristaltic activity into the aganglionic segment and aberrant or absent relaxation of the aganglionic segment on radiological examination because HSCR decreases bowel segment motility. On radiographs, these features can be observed often, although their frequency fluctuates, making them insufficient to rule out HSCR (eg. histology of rectal biopsies)

Abdominal X-ray: - In my patient Abdominal X-ray is done there is not much abnormality found in abdomen. Some abnormalities are seen in air fluid level can be seen in erect abdominal views indicating intestine. A diagnostic examination should begin with an abdomen X-ray. Essentially, low intestinal blockage and distended bowel loops of various abdominal radiographs must be searched for it.

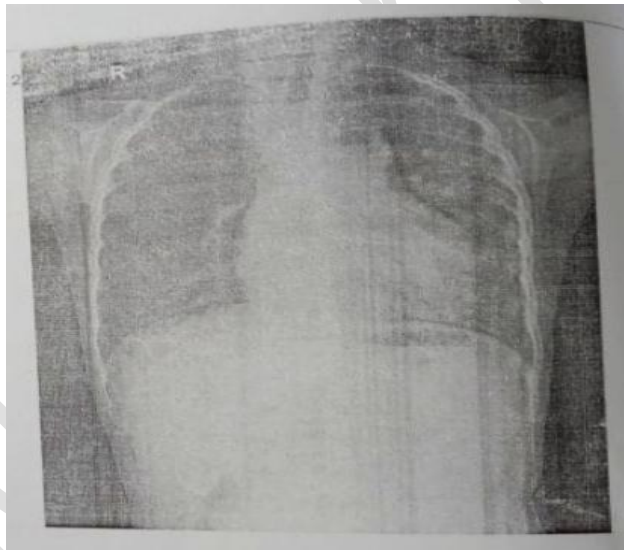


Fig 2. Diagram shows: CXR Abdomen AP x-ray

Rectal biopsy: - In my patient rectal biopsy procedure is done. In rectal biopsy some abnormalities are seen. it is used to determine the cause of blood or pus in the stool. rectal biopsy is a procedure to remove a small piece of tissue from the rectum for examination. Rectal biopsy can be used to determine the cause of blood, mucus, or pus, in the stool. It can also confirm findings of another test or x-rays, or take a biopsy of a growth found in the colon.

Barium Enema: - Barium enema is frequently used in my patients. The megacolon is depicted with a typical constricted section in the distal colon or rectum.

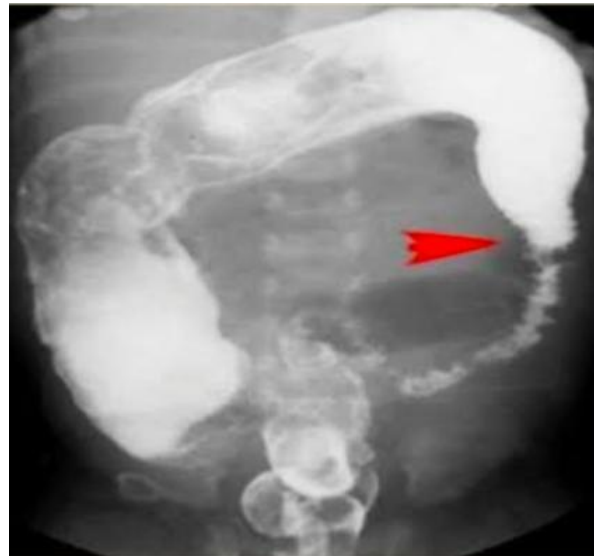


Fig 3. Diagram showing Barium Enema

Pull Through Surgery: - In my patient the Pull Through Surgery is done. To treat hirschsprungs illness, which creates a blockage in the intestine. The goal of pull-through surgery is to remove the damaged part of your child's intestine and then draw the healthy portion of the intestine down to the anus. Using minimally invasive methods, this surgery may usually be done in a single operation.

Colostomy Closure: - Colostomy closure surgery has been performed on my patient. The procedure's goal is to close the stome in the stomach using sutures. The top part of the colon is reattached to the colon's remaining section.

Therapeutic Intervention: - blood Transfusion, Inj. Aminoven 200 mg BD, Inj. Cefotaxime 400mg BD IV, Inj . Pantaprazole 12mg OD, Syp. Augmentin 3ml BD, Syp. Azee 5ml OD, Inj. Emset 1.8 mg SOS, Inj. Metronidazole 120mg TDS, Inj. Amikacin 180 mg OD, Inj. Neomol 180 mg TDS. Syp. Orofor xt 2.5 ml BD.

Discussion :

A male child of 2 years 6 Month old form Burtipura Dist. Gondia was admitted to pediatric ward no 22 on AVBRH on 29 Jun 2021 with a complaint of difficulty in passing stool, abdominal pain, fever, vomiting, failure of thrive, Constipation, tiredness and Nervousness, he is a known case of Hirschsprung's disease which was diagnose when he was 1 year old as soon as he was admitted to hospital investigation were done and appropriate treatment were started and surgery is done after getting treatment he is show great improvement and the treatment was still going on till my last date of care.

Hirschsprung's disease is most commonly seen in children, however Kottmeier and Clatworthy (1965) showed that bowel dysfunction caused by a functional megacolon can also appear in children. Another reason why all patients should get a low rectal biopsy before undergoing any type of resection is because of this. If so-called 'skip regions' exist, they must be exceedingly rare (For shall, 1964; Kottmeier & Clevenger, 1995).

The single death, in retrospect, might have been averted. A decisive procedure should have been done at the initial admission. Other writers that propose a one-stage Duhamel resection (Ehrenpreis et al., 1966; Kostia, 1962) concur with our findings. Other related studies were reviewed⁹⁻¹⁴.

For individuals who have had Hirschsprung's disease for a long time and have a big, hypertrophied colon, a colostomy is an appropriate initial step. Two children had such a colostomy, which took almost nine months to remove. The bowel had restored to its original size. By the conclusion of this era, the problem will have been reduced to manageable proportions. Hirschsprung's disease is a condition that can be detected as early as childhood. It's probable that gastroenteritis, a major cause of newborn mortality, contributed to some of the deaths in Jamaica.¹⁵⁻¹⁷

Conclusion:

Hirschsprung's Disease should be considered when dealing with persistent constipation. An abdominal X-ray and a rectal sample can be used to confirm the diagnosis. Surgical surgery is recommended due to the progressive nature of the condition and the possibility of fetal complications. Hirschsprung's Disease is one of the most frequent pediatric illnesses. It is critical to make a diagnosis.

in the early stages of the condition, so that the kid does not succumb to the disease's complications. Surgery for Hirschsprung's illness necessitates a pre- and post-surgical assessment to obtain reliable histopathological experience and pull through operational method, as well as a colostomy closure process. Despite these challenges, managing the long-term consequence of enterocolitis Constipation and incontinence continue to be a problem.

COMPETING INTERESTS DISCLAIMER:

Authors have declared that no competing interests exist. The products used for this research are commonly and predominantly use products in our area of research and country. There is absolutely no conflict of interest between the authors and producers of the products because we do not intend to use these products as an avenue for any litigation but for the advancement of knowledge. Also, the research was not funded by the producing company rather it was funded by personal efforts of the authors.

References:

1. DC. Datta pediatric nursing second edition new Delhi Jaypee Brother Medical Publishers: page no 301-305.
2. Amiel J, Lyonnet S. Hirschsprung's Disease, associates Syndrome, and genetics: a review. J Med Genet 2001;38:729-39.
3. Parisi MA, Kapur RP. Genetics Of Hirschsprung's Disease. Curr opin pediatr 2000;12:610-7.

4. Feldman M, Friedman LS, Sleisenger MH. Hirschsprung's Disease: Congenital unders, 2002:2131-5. Megaolon. In:Sleisenger & Fordtran's Gastrointestinal and liver disease: pathophysiology, diagnosis, management.7th edition Philadelphia, pa: saunders ,2002:2131-5.
5. Stewart DR, von Allmen D. The genetics of Hirschsprung's Disease. *Gastroenterol clin North Am* 2003;32:819-37.
6. Parisi MA, Kapur RP. Genetics of Hirschsprung disease. *Curr Opin Pediatr* 2000; 12:610-7. Saunders, 2002:2131-5
7. Holschneider AM, Puri P. Hirschsprung's Disease and Allied Disorders. 2nd ed. Amsterdam: Harwood Academic Publishers, 2000.
8. Sahu, Preeti Rajendra, Kishor Madhukar Hiwale, Sunita Jayant Vagha, and Samarth Shukla. "Spectrum of Lesions on Upper Gastrointestinal Endoscopy and Its Correlation with Histopathological Evaluation." *JOURNAL OF EVOLUTION OF MEDICAL AND DENTAL SCIENCES-JEMDS* 9, no. 32 (August 10, 2020): 2301–6. <https://doi.org/10.14260/jemds/2020/498>.
9. Sahu PR, Hiwale KM, Vagha SJ. Study of Various Gastrointestinal Tract Lesions by Endoscopic Biopsies in a Tertiary Care Centre of Rural District of Maharashtra. *JOURNAL OF EVOLUTION OF MEDICAL AND DENTAL SCIENCES-JEMDS*. 2021 Apr 19;10(16):1135–9.
10. Selvam, Sinduja, Amar Taksande, Amol Lohakare, and Rewat Meshram. "An Infant with Congenital Cytomegalovirus Infection Presenting with Hypomelanosis of Ito." *JOURNAL OF EVOLUTION OF MEDICAL AND DENTAL SCIENCES-JEMDS* 9, no. 48 (November 30, 2020): 3697–99. <https://doi.org/10.14260/jemds/2020/811>.
11. Goyal C, Naqvi W. Developmental delay in congenital hypothyroidism. *PAN AFRICAN MEDICAL JOURNAL*. 2021 Feb 12;38.
12. Lozano, Rafael, Nancy Fullman, John Everett Mumford, Megan Knight, Celine M. Barthelemy, Cristiana Abbafati, Hedayat Abbastabar, et al. "Measuring Universal Health Coverage Based on an Index of Effective Coverage of Health Services in 204 Countries and Territories, 1990-2019: A Systematic Analysis for the Global Burden of Disease Study 2019." *LANCET* 396, no. 10258 (October 17, 2020): 1250–84. [https://doi.org/10.1016/S0140-6736\(20\)30750-9](https://doi.org/10.1016/S0140-6736(20)30750-9).
13. Khatib N, Gaidhane S, Gaidhane AM, Khatib M, Simkhada P, Gode D, Zahiruddin QS. Ghrelin: ghrelin as a regulatory Peptide in growth hormone secretion. *Journal of clinical and diagnostic research: JCDR*. 2014 Aug;8(8):MC13.
14. Agrawal A, Timothy J, Cincu R, Agarwal T, Waghmare LB. Bradycardia in neurosurgery. *Clinical neurology and neurosurgery*. 2008 Apr 1;110(4):321-7.
15. Bourne R, Steinmetz JD, Flaxman S, Briant PS, Taylor HR, Resnikoff S, Casson RJ, Abdoli A, Abu-Gharbieh E, Afshin A, Ahmadi H. Trends in prevalence of blindness and distance and near vision impairment over 30 years: an analysis for the Global Burden of Disease Study. *The Lancet Global Health*. 2021 Feb 1;9(2):e130-43.
16. Borle RM, Nimonkar PV, Rajan R. Extended nasolabial flaps in the management of oral submucous fibrosis. *British Journal of Oral and Maxillofacial Surgery*. 2009 Jul 1;47(5):382-5.
17. Franklin RC, Peden AE, Hamilton EB, Bisignano C, Castle CD, Dingels ZV, Hay SI, Liu Z, Mokdad AH, Roberts NL, Sylte DO. The burden of unintentional drowning: global, regional

and national estimates of mortality from the Global Burden of Disease 2017 Study. *Injury prevention.* 2020 Oct 1;26(Supp 1):i83-95.

Under peer review