

TESTICULAR MASS WITH LIVER METASTASIS: A CASE REPORT

ABSTRACT:

Background: A malignancy of testicles is known as testicular cancer. The testicles are positioned directly below the penis in the scrotum. The testicles' purpose is to create sperm for reproduction. A lump in the testicles and pain or swelling in the scrotum are the possible symptoms. Infertility may occur as a result of treatment. An undescended testis, a family history of the disease, and a previous history of testicular cancer are all risk factors. Germ cell tumors, which are split into seminomas and non-seminomas, are the most prevalent form. Sex-cord stromal tumors and lymphomas are two more forms. Liver metastasis is a cancerous tumor that has spread to the liver from another organ that has been impacted by malignancy. In liver metastases, the malignant cells that develop are not liver cells. They are cancer cells from the region of cancer's genesis in the body. Cancer has progressed to the liver from another portion of the body, doctors may refer to the metastatic liver disease as stage four or modern cancer. The incidence of primary liver cancer is lower than that of liver metastases: cirrhosis or hepatitis are common risk factors in persons with primary liver cancer.

Case presentation: We present a case of a 24-year-old male with complaints of mass in left testis for the past one and half years. The mass was slow-growing, non-painful. The patient complained of heavy feeling in the lower abdomen with a recent history of loss of appetite, weight loss, and backache. The diagnosis was done with the help of ultrasound, blood tests, computed tomography (CT), magnetic resonance imaging (MRI) scan imaging & treated with excision.

Conclusion: Testicle's malignancy is regarded as an oncologic achievement because more people will be treated with an amalgamation of chemotherapy and surgery. The radiologists are crucial in finding cancers throughout the patient presentation, correctly grading illness, and detecting recurrence malignancy during scanning monitoring. A case of Testicle's malignancy and liver metastasis in a twenty-four-year-old man that had managed with a multicentric approach. Genetic counseling and psychological assistance should be provided to the family of a person presenting with the testicular mass as a part of the genetic condition.

KEYWORDS: -Testicular mass, liver metastasis, iliac lymphadenopathy.

INTRODUCTION:

Testicular cancer is linked to cryptorchidism, familiar history and infertility. Seminoma is the most significant type of cell in testicular cancer, affecting young males aged 18-35 years. Ultrasonography (USG) is to identify testicular cancers, and computed tomography (CT), magnetic resonance imaging (MRI) scan is used to stage them.[1] Testicular cancer is a very uncommon illness, accounting for less than 1% of all malignancies of the internal organs. The age histology of tumors affects the demographics of those who are impacted. Primary germ cell tumors account for more than 90% of all testicular tumors, making young adults the most often affected age group [2]. Testicular tumors in the United States generally present as a solid mass in the testis. Infracts and infections are on the differential diagnosis, matching the patient's symptoms and history. The largest nodal diameter is utilized to differentiate retroperitoneal

lymph nodes from regional lymph nodes when grading CT or MR scanning between N1 and N3 disease [1]. The cancer cells that develop in the right testicle are more likely to spread to the inter-aortocaval lymph nodes, whereas tumors that start in the left testicle are more likely to move to the para-aortic lymph nodes. Specific emphasis should be placed on the inter-aortocaval lymph nodes when a right-sided primary testicular tumor is present. Evidence shows that radiologists ignore more right-sided positive lymph nodes than left-sided positive lymph nodes. [3]. Presentation at the clinic usually includes an enlarged testis/scrotum and a lump. These were the most prevalent symptoms linked with the diagnosis of testicular cancer [2].

CASE REPORT: -

We present a case of a 24-year-old male patient who presented to the surgery outpatient department with complaints of mass in the left testis for the past one and half years. The mass was slow-growing and non-painful. The patient complained of heavy feeling in the lower abdomen with a recent history of loss of appetite, weight loss, and backache. He had no history of fever, trauma, any urinary or bowel complaints. His clinical details were insignificant of any chronic disease. There was no previous medical or surgical history that was relevant. There was no one in the family with a history of cancer. The weight was 61kg, the height was 157cm. There was an enlargement of the left testis on the examination with a smooth palpable, non-tender mass in the left testis measuring approximately 4×2cm. There was no sign of inflammation and no mass detectable in the right testis. The skin was normal except for the puffiness.

The rest of the general and physical examination was unremarkable. The investigation of the USG of inguinoscrotal region exam revealed: "Heterogeneously hypoechoic enlarged left testis with raised vascularity having multiple calcific foci within it. There was also evidence of free fluid in left scrotal sac s/o left-sided hydrocele". USG of abdomen pelvis revealed multiple-well enlarged lymph node, s/o of peritoneal lymphadenopathy. The investigation of contrast-enhanced computed tomography (CECT) of the abdomen and pelvis scan revealed "Enlarged left testis with multiple retroperitoneal and iliac lymphadenopathy with liver parenchymal lesion and multiple lung parenchymal nodular lesion. It showed fig: 1. On the investigation of blood test exam, AFP test (ALPHA FETOPROTEIN) and βHCG test results the value, i.e., AFP: - 127ng/ml and βHCG: -2785.3IU/ml. Based on clinical examination and investigations, a clinical diagnosis of testicular mass was diagnosed. The tumor was surgically removed and sent for pathological analysis. His blood count is within normal limits with mild elevation of ESR and CRP. Liver function tests revealed deranged AST and ALT. The rest of the liver enzymes were in the normal range. Kidney function tests and routine urine examination revealed no abnormalities.

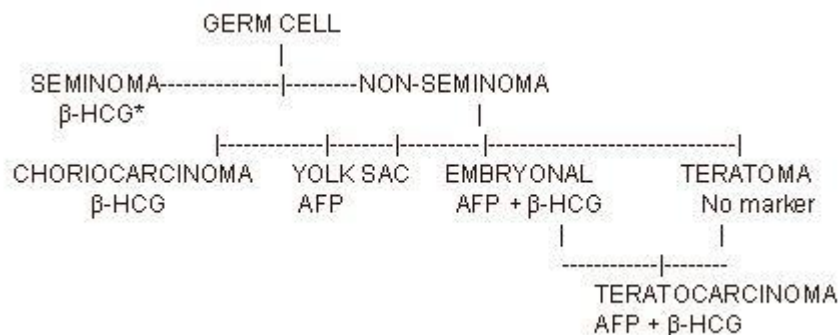


Fig: 1 -Use of Tumor Markers for Specific Cell Types of Testicular Cancer.

The patient was admitted to the male surgery department of the AVBRH hospital with chief complaints, as mentioned previously; routine investigation, like assessment (complete blood count), LFT, KFT, blood group analysis, and serum tumor markers test for the detection of testicular cancer; AFP, beta HCG, LDH with virology investigation was performed. The diagnostic evaluation was done with USG of inguinoscrotal regions of Abdo-pelvis, pre-operatively orchiectomy CECT abdo-pelvis was performed, and post-surgical orchiectomy CT pelvis was performed. An orchiectomy procedure was planned and performed for the removal of testicular mass. (Fig: 2) After the operative procedure, Inj ceftriaxone 19 mg IV BD, inj pan 40 mg IV OD, inj emset 4 mg IV SOS, inj neomol 19 mg IV TDS, inj pause 500 mg IV SOS.

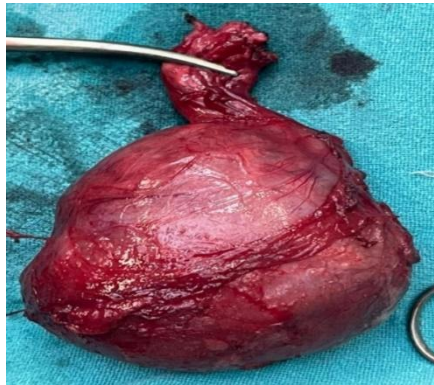


Fig. 2: -The removal of testicular Mass

A CT pelvis (p+c) scan was performed postoperatively, with the clinical history of the post-operative case of testicular mass is revealed. The left testis is not visualized in the scrotal sac. There is mildly enhancing soft tissue with subcutaneous edema noted over the left scrotal sac and left the inguinal region with few air density foci seen suggestive of post-operative changes. The right testis appears normal. There is multiple pathologically enlarged round enhancing lymph nodes noted in the bilateral inguinal region, iliac region, para-aortic region, aortocaval region. Few of LNs show central necrosis in contrast study. It showed **fig: 3**. Few Lymph Nodes are compression and abutting infrarenal IVC and iliac veins. The infrarenal IVC, left common iliac vein, external iliac vein, common femoral vein, shows non-opacification on venous phase with mildly distended caliber suggestive acute to subacute deep venous thrombosis.

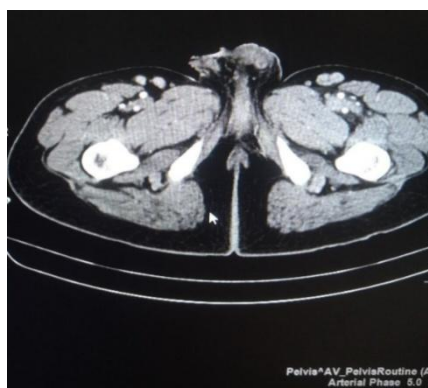


Fig: 3 CT Scan Pelvis axial cross section of testis

In the **Fig: 3 (CT Scan Pelvis axial cross section of testis)** showing the left testis is not visualized in scrotal sac. There is mildly enhancing soft tissue with subcutaneous edema noted over left scrotal sac and left inguinal region with few air density foci seen suggestive of post operative changes.

CLINICAL FINDINGS: -

USG OF INGUINO-SCROTAL REGION: -

There is heterogeneously hypoechoic echotexture of the left testis with mild enlargement of the left testis. It shows irregular border and moderately increased vascularity on color doppler. The lesion shows multiple calculi foci within it—left testis (M)-51×35.4×31.0mm in size. There is mild fluid collection noted in the left scrotal sac. The right testis appears normal in size, shape, echotexture, and vascularity. (M)-35×24×18mm in size. There is a typical appearance of the epididymis. Right epididymis is 10×6mm. Left epididymis is 12×8mm. Both spermatic cords show normal appearance with no evidence of varicocele. No inguinal lymphadenopathy was seen. In **fig: 4** showing “**Heterogeneously hypoechoic enlarged left testis with raised vascularity having multiple calcific foci within it. There was also evidence of free fluid in left scrotal sac s/o left sided hydrocele**”.

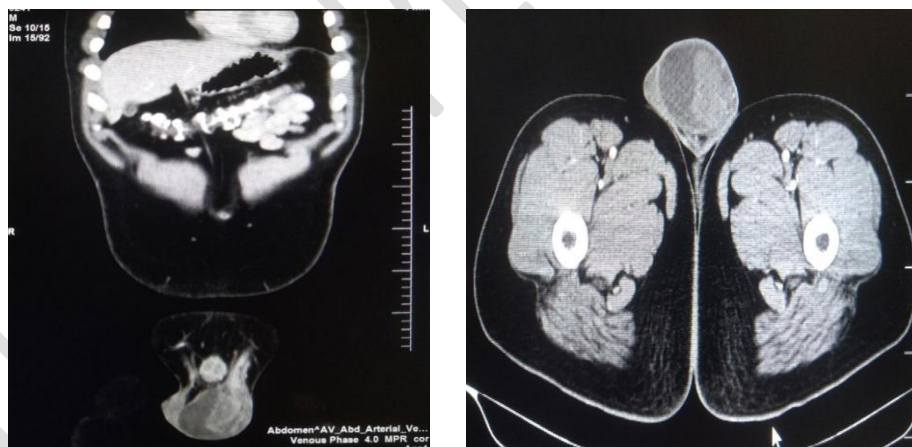


Fig 4: Axial and coronal CECT showing enlarged left testis which appears mild lobulated with heterogenous predominantly peripheral enhancement. Evidence of free fluid collection noted in the left scrotal sac.

USG OF ABDO-PELVIS: - The liver is normal in size and shape, and echotexture measures 14.5cm. Gallbladder is collapsed, and portal vein is usual. The pancreas is normal in size, shape, and echotexture. The spleen is normal in size, shape, and echotexture measures 11.2cm. The right kidney measures 10.9×4.0cm. The left kidney measures 11.0×5.0 cm. Both the renals are regular in shape, size, and echotexture with maintained CMD (corticomedullary differentiation).

Prostate volume is 17cc. The urinary bladder (pre void) is a distended urinary bladder (post-void). There are multiple (4.5) enlarged hypoechoic, well-defined, oval, and round-shaped lymph nodes noted in the pre-and para-aortic region. It shows the central area of necrosis within—most considerable measure 3.0×2.5cm in size associated with peripheral vascularity. No enlarged inguinal lymph nodes noted.

CONTRAST ENHANCED COMPUTED TOMOGRAPHY (CECT) OF ABDO-PELVIS: -

Left testis: Measures approximately 5.2 x 4 x 2.2 cm (CC X TRANS X AP, volume – 23CC) – enlarged, appears mild lobulated with heterogenous Predominantly peripheral enhancement (USG / MRI are better in Characterization). Evidence of free fluid collection noted in the left scrotal sac.

Right testis: Measures 3.2 x 2.6 x 2.8 cm (APX TRANS X CC, VOLUME – 11CC), regular in size contour, and enhancement on post-contrast. Evidence of multiple heterogeneously enhancing closely placed lobulated mass Lesions with central poor enhancing areas in the pre-aortic, para-aortic region, Perceval and retro caval regions and common iliac region, in total Para-aortic-paracaval lesion measuring approximately 8 x 4.8 x 4.8cm (CC X Trans X AP) and extending from T12 to L5 vertebral body. The lesions are seen Completely enhancing and displacing the aorta and its branches, enhancing the left renal artery. They are causing a mass effect in the form of mild anterior displacement of jejunal loops. Lesions are abutting the left psoas muscle posteriorly. The left mid ureter is partially compressed by the lesion—however no evidence of hydronephrosis. Enlarged nodes are also seen in the right iliac region. LIVER – measures 15 cm. Normal in size, shape, and enhancement pattern. Evidence Non-enhancing ill-defined hypodense lesion noted in measuring approximately 2.8x2.2 cm in segment VIII. No evidence of EHBD & IHBD is noted. The portal vein is normal in size. The intrahepatic part of IVC & hepatic veins is normal. GALL BLADDER – Appears normal. Wall thickness is normal. No evidence of any calculus. The pancreas appears normal. The stomach is well defined, with no evidence of wall thickening. Spleen measures 10 cm, normal in size, shape, axis, and enhancement pattern. The right kidney measures 9 x 5.6 cm, normal in shape, size, and pattern. No evidence of any calcification. No evidence of any pelvicalyceal dilatation. The cortical Phase, nephrographic Phase, and parenchymal Phase all are normal. Left kidney – measures 11.5 x 5.9 cm. There is no e/o dilatation of the pelvicalyceal system. E/o fat stranding and fluid collection were noted in the anterior, lateral, and posterior left renal fascia. The cortical Phase, nephrographic Phase, and parenchymal Phase all are normal. Visualized bowel loops appear normal in caliber. The urinary bladder appears normal in shape and contour. Wall thickness is normal. Prostate appears normal in size. Visualized section of the lower chest shows few nodular opacities in bilateral lower Lung fields (Right > Left).

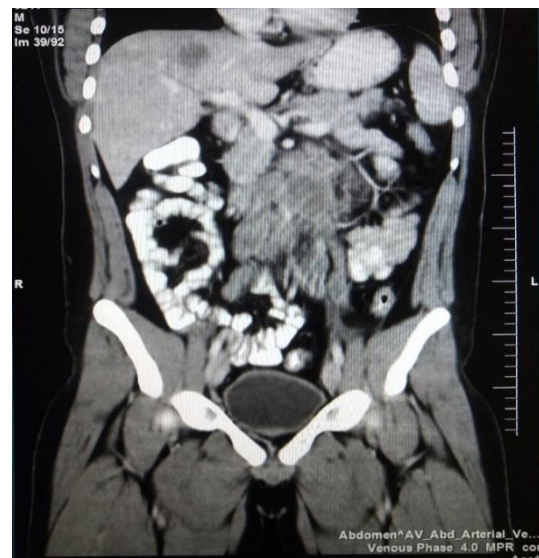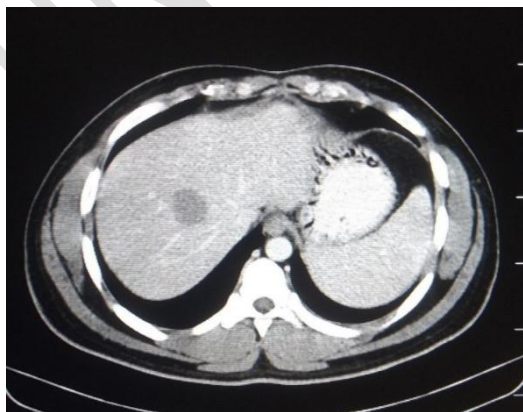


Fig: 5 Transverse Image of CT scan abdomen

Fig: 6 Coronal Image of CT scan abdomen

In the **Fig: 5 & 6 (CT Scan Pelvis axial and Coronal section of abdomen)**, Axial and coronal CECT showing Evidence non enhancing ill-defined hypodense lesion noted in measuring approximately 2.8x2.2 cm in segment VIII of liver – Metastasis.

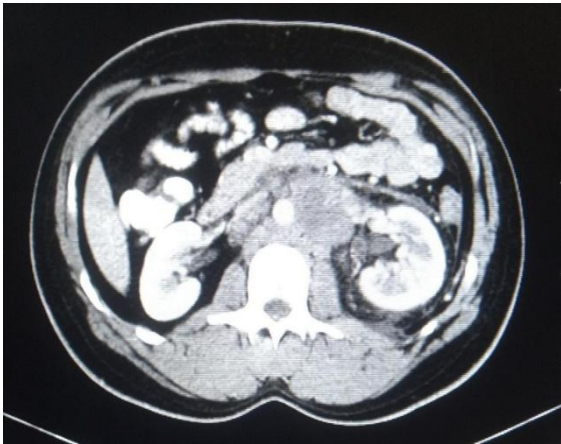


Fig: 7 Transverse Image of CT scan abdomen

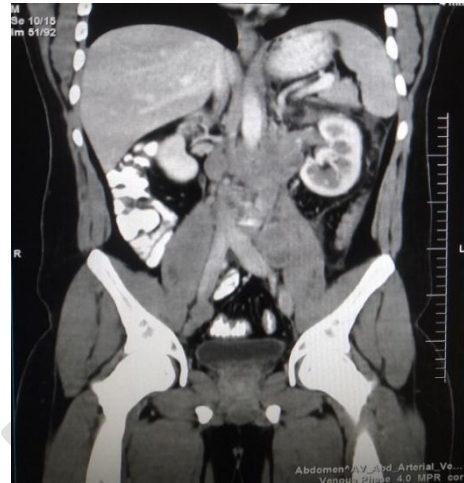

Fig: 8 Coronal Image of CT scan abdomen

In the **Fig: 7 & 8 (CT Scan Pelvis axial and Coronal section of abdomen)**, Axial and coronal CECT of abdomen showing multiple heterogeneously enhancing closely placed lobulated mass lesions with central poor enhancing areas in pre-aortic, para-aortic region, pre caval and retro caval regions and common iliac region encasing and displacing the aorta. – Retroperitoneal lymphadenopathy.

DISCUSSION: -

Patients with testicular cancer have a good prognosis, with a more than 95% five-year survival rate. Although a clinical examination is used to make the initial diagnosis, imaging plays an essential role in the diagnosis and treatment of testicular cancer, which is based on tumor load and grading [3]

Testicular Cancer Types: Germ cell tumors account for 95% of testicular cancers in young men, whereas sex cord-stromal tumors account for 5%. Seminomas account for around half of germ cell tumors, whereas non-seminomatous germ cell tumors (NSGCTs) account for the other half. Mixed germ cell tumors make up 33% of NSGCTs, pure embryonal carcinomas make up 10%, teratomas make up 4%, yolk sac tumors make up 1%, and choriocarcinomas make up 0.3 percent. Leydig cell tumors, Sertoli cell tumors, granulosa cell tumors, and thecomas are all sex cord-stromal cancers. [4-6]. Lymphoma is the most prevalent testicular cancer in males over the age of 60. Non-Hodgkin lymphoma is the most prevalent type of testicular lymphoma, and it has a dismal prognosis. Sarcoma, fibroma, vascular tumors, Leukemia, leiomyoma, and neurofibroma are other uncommon testicular cancers. Testicular metastases are rare [1] Most recognized risk factors, including cryptorchidism, carcinoma in situ, and estrogen exposure in utero, are linked to early life experiences. Testicular cancer has been linked to various occupational, lifestyle, socioeconomic, and other risk factors. Although few risk factors for testicular cancer have been identified, several appear to be linked to hormonal balance at various periods of life. Later-life lifestyle and occupational exposures may affect disease promotion, but they are unlikely to be implicated in cancer start. Cryptorchidism (male descendent testicle) is the most well-known risk factor for testicular cancer [7]. A blood test is performed. Some

testicular cancers produce these protein hormones. Some malignancies have tumor markers such as AFP, HCG, and LDH, however many testicular cancers do not appear before orchiectomy. Serum levels of AFP, HCG, and LDH should be measured and repeated weekly until marker levels return to normal [8]. Few of the related studies were reviewed [9-13]. HCG levels can be raised by pure seminomas, but not AFP levels. Non-Seminomas frequently cause an increase in AFP and HCG levels. Appropriate disease evaluation is required during a patient's therapy: assessing Treatment response, restaging, and post-treatment surveillance for disease recurrence are all needed for successful treatment. For painless testicular masses, ultrasound is generally the first screening modality, with computed tomography (CT) most often utilized for staging and restaging. In low tumor load phases, testicular cancer is considered almost curable. Multimodality imaging assessment, in addition to tumor marker, is critical in-patient treatment. At the same time, US and CT are the most common imaging modalities used for the initial staging of cancer cells. PET-CT and MRI can also be utilized for restaging in some cases. Tumor response to therapy, restaging, and monitoring all need imaging. The clinical team must have a complete understanding of the imaging modalities that should utilize at each stage of the disease, and radiologists should advise physicians on which studies to order based on the patient's circumstances.[4-15]

CONCLUSION:

Testicle's malignancy is regarded as an oncologic achievement because more people will be treated with an amalgamation of chemotherapy and surgery. The radiologists are crucial in finding cancers throughout the patient presentation, correctly grading illness, and detecting recurrence malignancy during scanning monitoring. A case of Testicle's malignancy and liver metastasis in a twenty-four-year-old man that had managed with a multicentric approach. Genetic counseling and psychological assistance should be provided to the family of a person presenting with the testicular mass as a part of the genetic condition.

ETHICAL APPROVAL:

Not applicable.

REFERENCES:

1. Coursey Moreno C, Small WC, Camacho JC, Master V, Kokabi N, Lewis M, Hartman M, Mittal PK. Testicular tumors: what radiologists need to know—differential diagnosis, staging, and management. *Radiographics*. 2015 Mar;35(2):400-15.
2. Raghavan D. Germ cell tumors. *PMPH-USA*; 2003.
3. Hale GR, Teplitsky S, Truong H, Gold SA, Bloom JB, Agarwal PK. Lymph node imaging in testicular cancer. *Translational andrology and urology*. 2018 Oct;7(5):864.
4. Cassell A, Jalloh M, Ndoye M, Yunusa B, Mbodji M, Diallo A, Gaye O, Labou I, Niang L, Gueye S. Review of testicular tumor: diagnostic approach and management outcome in Africa. *Research and reports in urology*. 2020; 12:35.
5. Marko J, Wolfman DJ, Aubin AL, Sesterhenn IA. Testicular seminoma and its mimics: from the radiologic pathology archives. *Radiographics*. 2017 Jul;37(4):1085-98.
6. Garner MJ, Turner MC, Ghadirian P, Krewski D. Epidemiology of testicular cancer: an overview. *International journal of cancer*. 2005 Sep 1;116(3):331-9.

7. Jain, Soumya, Suresh Phatak V, Amruta Varma, and Gaurav Mishra. "Testicular Torsion - USG and Color Doppler Correlation: A Case Report." *MEDICAL SCIENCE* 24, no. 103 (June 2020): 1553–57.
8. Sawale, Shantanu, Meenakshi Yeola, Samarth Shukla, and Sourya Acharya. "Self-Examination of Scrotum- Need of the Hour to Create Awareness Regarding Testicular Pathologies- A Cross Sectional Study." *JOURNAL OF EVOLUTION OF MEDICAL AND DENTAL SCIENCES-JEMDS* 9, no. 19 (May 11, 2020): 1528–32. <https://doi.org/10.14260/jemds/2020/334>.
9. Bhansali PJ, Phatak SV, Bishnoi L, Raj N. Intratesticular Simple Cyst - Ultrasound and Elastography Appearance. *JOURNAL OF EVOLUTION OF MEDICAL AND DENTAL SCIENCES-JEMDS*. 2021 May 17;10(20):1561–2.
10. Mounika, Pottala, Deepit Sandeep Shrivastava, and Deepika Diwani. "Umbilical Metastasis Secondary to Ovarian Carcinoma - A Rare Case of Sister Mary Joseph Nodule." *JOURNAL OF EVOLUTION OF MEDICAL AND DENTAL SCIENCES-JEMDS* 9, no. 44 (November 2, 2020): 3343–44. <https://doi.org/10.14260/jemds/2020/734>.
11. Garg, Reetika Parmod, Anil Agrawal, Arvind Sridhar Bhake, and Sunita Vagha. "Correlation Study of Coagulation Profile in Spectrum of Liver Diseases." *JOURNAL OF EVOLUTION OF MEDICAL AND DENTAL SCIENCES-JEMDS* 9, no. 8 (February 24, 2020): 549–54. <https://doi.org/10.14260/jemds/2020/123>.
12. Gondivkar SM, Indurkar A, Degwekar S, Bhowate R. Evaluation of gustatory function in patients with diabetes mellitus type 2. *Oral Surgery, Oral Medicine, Oral Pathology, Oral Radiology, and Endodontology*. 2009 Dec 1;108(6):876-80.
13. Khatib N, Gaidhane S, Gaidhane AM, Khatib M, Simkhada P, Gode D, Zahiruddin QS. Ghrelin: ghrelin as a regulatory Peptide in growth hormone secretion. *Journal of clinical and diagnostic research: JCDR*. 2014 Aug;8(8):MC13.
14. Agrawal A, Timothy J, Cincu R, Agarwal T, Waghmare LB. Bradycardia in neurosurgery. *Clinical neurology and neurosurgery*. 2008 Apr 1;110(4):321-7.
15. Nagrale AV, Herd CR, Ganvir S, Ramteke G. Cyriax physiotherapy versus phonophoresis with supervised exercise in subjects with lateral epicondylalgia: a randomized clinical trial. *Journal of Manual & Manipulative Therapy*. 2009 Jul 1;17(3):171-8.