

The comparison of Trichoscopic findings in female pattern hair loss (FPHL) and chronic telogen effluvium (CTE) in female patients

ABSTRACT:

BACKGROUND: Chronic hair loss is a major complaint in middle-aged females. It is sometime difficult to differentiate between female pattern hair loss (FPHL) and chronic telogen effluvium (CTE) in female patients. Trichoscopy is a non-invasive technique that can help to distinguish between FPHL and CTE.

Aims: To compare the trichoscopic findings in female pattern hair loss (FPHL) and chronic telogen effluvium (CTE) in female patients.

Material and Methods: It is a cross sectional prospective comparative study carried out in the department of dermatology, Acharya Vinoba Bhave Rural Hospital affiliated to Jawaharlal Nehru Medical College, Wardha, Maharashtra. Adult female patients with ages ranging from 30 to 60 years old complaining of diffuse hair loss were included in the study. Patients with scarring alopecia were excluded from the study. Patients were divided into two groups consisting of 20 patients in each group. Group A and B included patients with FPHL and CTE respectively. Trichoscan (SIF hair analysis system) was performed on frontal region of the scalp.

Results: Hair diameter variability was significantly seen in FPHL. Hair diameter was reduced in FPHL (0.045) as compared to chronic telogen effluvium (0.063) with statistical difference between them. Hair density was significantly reduced in FPHL (32 ± 12.24) as compared to CTE (60.66 ± 18.12). Vellus hair density was significantly more in FPHL (22.4 ± 14.3) as compared to chronic telogen effluvium (7.73 ± 6.71). Single hair unit was more in FPHL (65 ± 17.08) as compared to chronic telogen effluvium. Density of yellow dots is more significantly observed in female pattern hair loss as compared to chronic telogen effluvium.

Conclusion: Trichoscopic features based on hair shaft diameter, hair follicular density, vellus hairs, yellow dots and variability in hair shaft diameter can easily help to distinguish female pattern hair loss from chronic telogen effluvium. This differentiation can help dermatologists to plan better and specific management of hair loss in female patients.

INTRODUCTION:

Hair loss can be damaging for the self-image and well-being. Diffuse non scarring hair loss is a common problem in women and a major reason for consultation for hair related disorders. Adult women can have a varying degree of hair fall which can be subdivided into acute or chronic onset diffuse hair loss. This is considered to be a multifactorial problem ranging from CTE to

FPHL. Acute telogen effluvium (ATE) is the most common cause of diffuse hair loss followed by chronic telogen effluvium(CTE) and female pattern hair loss (FPHL) ⁽¹⁾.

In early stage, female pattern hair loss and chronic telogen effluvium can present in similar ways. Chronic telogen effluvium has to be differentiated from female pattern hair loss as the management approach is different between both conditions. Trichoscopy is a reliable, non-invasive technique that allows visualization of hair density, hair diameter, and epidermal portion of hair follicle, vellus hairs, and yellow dots and to study the surface of the scalp. It can be helpful in the diagnosis of female pattern hair loss and chronic telogen effluvium without requiring a biopsy⁽²⁾.

Material and Method: It was a prospective cross-sectional comparative study carried out in the department of Dermatology, Acharya Vinoba Bhave Rural Hospital, affiliated to Jawaharlal Nehru Medical College, Wardha, Maharashtra. Institutional ethical committee clearance was approved before the start of the study. Informed written consent was taken from each patient before enrolling in the study. Study was carried out in female patients ranging between 25 to 60 years old. Female patients with acute telogen effluvium, alopecia areata, cicatricial alopecia, trichotillomania and traction alopecia were excluded from the study. Patients were randomly selected and enrolled in the study. Patients were distributed in A and B groups. In group A, clinically diagnosed cases of female pattern hair loss were enrolled while in group B, clinically diagnosed cases of chronic telogen effluvium were enrolled. Female patients with thinning of the interparietal part of the scalp (Christmas tree pattern) with bitemporal recession were clinically diagnosed as female pattern hair loss and included into the Group A. Diffuse hair loss for more than 6 months without any obvious cause with no interparietal thinning or bitemporal recession was clinically considered as chronic telogen effluvium. Detailed history regarding onset, duration, and severity was taken. Detailed history was taken to rule out other causes of hair loss in women.

Trichoscan used in the present study was SIF hair analysis system that allows visualization of hair shaft thickness, hair density, percentage of vellus hairs, follicular units per unit area, yellow dots. Frontal region of the scalp was examined in each patient. Magnification ranging from 50x to 300x was used to visualize details of hair shaft and scalp epidermis. The result was analyzed using unpaired T-test with significant level of p-value < 0.05.

Result:

Table 1. Trichoscopic features in FPHL and CTE

	FPHL	CTE	p value
Anisotrichosis >20% (% of patients)	90	22	< 0.0001
Hair diameter	0.045 ± 0.006	0.0590 ± 0.008	< 0.002
Density(per unit area)	32 ± 12.24	60.66 ± 18.12	< 0.001

Vellus Hair (%)	22.4 ± 14.3	7.73 ± 6.71	< 0.001
Single hair unit (%)	65 ± 17.08	39 ± 11.08	< 0.003
Yellow dot	4.66 ± 1.72	1.33 ± 0.58	< 0.002

Variability in hair diameter of more than 20% was seen in 90% of patients with female pattern hair loss (FPHL) which was statistically significant as compared to chronic telogen effluvium which more than 20% variability of hair diameter was only seen in 22% of the CTE patients [Table 1] [Figure 1] Mean diameter of the hair shaft in FPHL was 0.045 ± 0.006 while in chronic telogen effluvium mean it was 0.059 ± 0.008 with statistically significant difference of 0.001. [Table 1] Density of hair follicular units per unit area were significantly reduced in FPHL (32.54 ± 12.24) as compared to chronic telogen effluvium (60.66 ± 18.12). [Figure 2] Percentage of vellus hairs were 22.4 ± 14.3 in FPHL as compared to 12.73 ± 6.71 in CTE with a statistically significant difference of 0.001. The percentage of single hair follicular units was higher in FPHL (65.03 ± 17.08) as compared to chronic telogen effluvium (39.35 ± 11.08) with a statistical significance of 0.003. [Table 1][Figure 3] Yellow dots per field of vision were significantly more in FPHL (4.66 ± 1.72) as compared to chronic telogen effluvium (1.33 ± 0.58). [Table 1] [Figure 4]

Discussion:

Acute Telogen effluvium is characterized by diffuse sudden onset, rapid shedding of club hairs mostly preceded by any triggering events such as febrile illness, accidental trauma, major surgery, emotional trauma, drug intake, postpartum and poor diet⁽³⁾. It is a self-limiting condition and lasts only for 3 to 6 months which also can be improved with treatment of the underlying condition. As described by David Whittings, chronic telogen effluvium is an idiopathic, chronic diffuse hair loss without central loss of density in middle-aged women lasting for more than 6 months duration with normal histology. ⁽⁴⁾ It becomes clinically evident when more than 25% volume of hairs is reduced. ⁽⁵⁾ Pathogenesis of chronic telogen effluvium is unknown and the diagnosis is made only after exclusion of other causes of hair loss including thyroid disorder, other systemic disorders, anemia, chronic illness, emotional trigger, and by clinical and laboratory examinations⁽⁶⁾.

Female pattern hair loss is diffuse, slowly progressive, with a gradual onset and predominantly affecting the frontoparietal region of the scalp leading to leading to a loss of interparietal hair density. FPHL is characterized by miniaturization of hair follicles with normal anagen to telogen hair ratio with marked variation in hair diameter affecting frontal, central, and parietal regions of the scalp. ⁽⁷⁾⁽⁸⁾

Female pattern hair loss is considered to be a major hair problem faced by mainly middle-aged women and it is also challenging for the dermatologist to treat this condition. The prevalence of female pattern hair loss is not known in India. Various studies done in China and Korea have

mentioned the prevalence of about 5-6 % in middle-aged women.⁽⁹⁾⁽¹⁰⁾ The prevalence of female pattern hair loss increases with age with higher prevalence in post-menopausal women of more than 60 years age and it shows an inconsistent response to treatment⁽¹¹⁾.

The main differential diagnosis of female pattern hair loss is chronic telogen effluvium in an early stage of the disease. They are difficult to differentiate as both disorders present with similar complaints of diffuse and episodic hair loss.⁽¹²⁾ Distinction between these two conditions is important as natural history, pathogenesis, prognosis and management differs. ⁽¹³⁾ ⁽¹⁴⁾ Chronic telogen effluvium is a self-limited condition with an overall good prognosis, while FPHL is a progressive disease, causing significant decrease in hair density which may lead to cosmetically unacceptable baldness. Biopsy can help differentiate between them as CTE shows classical histopathological findings and FPHL showed miniaturization of terminal hair with lower terminal to vellus hair ratio. Biopsy is an invasive procedure that should not be practiced as a routine examination for this kind of patient. Trichoscopy can be used to differentiate between these two conditions as it is non-invasive, easily available, and allows us to visualize and assess scalp and hair characteristic. ⁽¹⁵⁾ It can give valuable clue to diagnosis, predict the course of the disease and avoid unnecessary biopsies.⁽¹⁶⁾⁽¹⁷⁾

Variability in hair diameter (anisotrichosis) is a definitive sign of FPHL. In our study, about 90% of female pattern hair loss patients showed anisotrichosis, while it was present only in 22% of the patients in the chronic telogen effluvium group. The findings of our study are in concordance with findings reported by Bhamla et al. ⁽¹⁸⁾ Although thin hairs can be seen in CTE, they are more characteristically seen in FPHL according to our results.

Hair density in FPHL was significantly lower as compared to CTE patients. Similar findings were noted by Hatice et al. ⁽¹⁹⁾ The percentage of vellus hairs was significantly higher in FPHL as compared to CTE. 22% of the hairs per unit area of trichoscopy were vellus hairs in FPHL patients, while only 7.73 % were vellus hairs in the CTE group. The number of single hair units was higher (statistically significant) in FPHL as compared to CTE. Though yellow dots are not a specific trichoscopic finding in FPHL, the percentage of yellow dots per area unit was significantly higher as compared to the CTE group. Similar findings on trichoscopy were found in Rakowska et al study⁽²⁰⁾.

Rakowska et al devised trichoscopic criteria for the diagnosis of female pattern hair loss (FPHL). Lower mean hair thickness, more than 10% thin hairs in frontal area and more than 4 yellow dots per unit area are considered major criteria to diagnose FPHL. Trichoscopic findings are more pronounced in frontal area as compared to occipital area. This criterion is said to have a specificity of 98% for the diagnosis of FPHL. No specific trichoscopic findings are observed in CTE other than short hairs with the sharp end⁽²⁰⁾.

Miniaturization of terminal hairs into vellus-like hairs is the main pathogenic mechanism in FPHL with lower terminal to vellus hair ratio. These vellus-like follicles have shortened anagen cycle leading to production of fine, nonpigmented short hair shaft.⁽²¹⁾ Pathophysiologic mechanisms of FPHL are considered to be multifactorial, including genetics, androgens, and microinflammation⁽²¹⁾.

Trichoscopy can establish the diagnosis of FPHL based on various features without the help of an invasive biopsy technique. Early diagnosis of FPHL is possible with the help of trichoscopy. It also can help in monitoring treatment response in patients of female pattern hair loss⁽²⁾.

Conclusion:

Trichoscopy allows us to evaluate characteristics like hair density, variability in hair shaft diameters, percentage of vellus hair, percentage of single hair units, and yellow dots per unit area. This can help us diagnose FPHL and distinguish it from chronic telogen effluvium which pose diagnostic dilemma in clinical practice.

FIGURE 1: Variability in hair diameter on trichoscopy

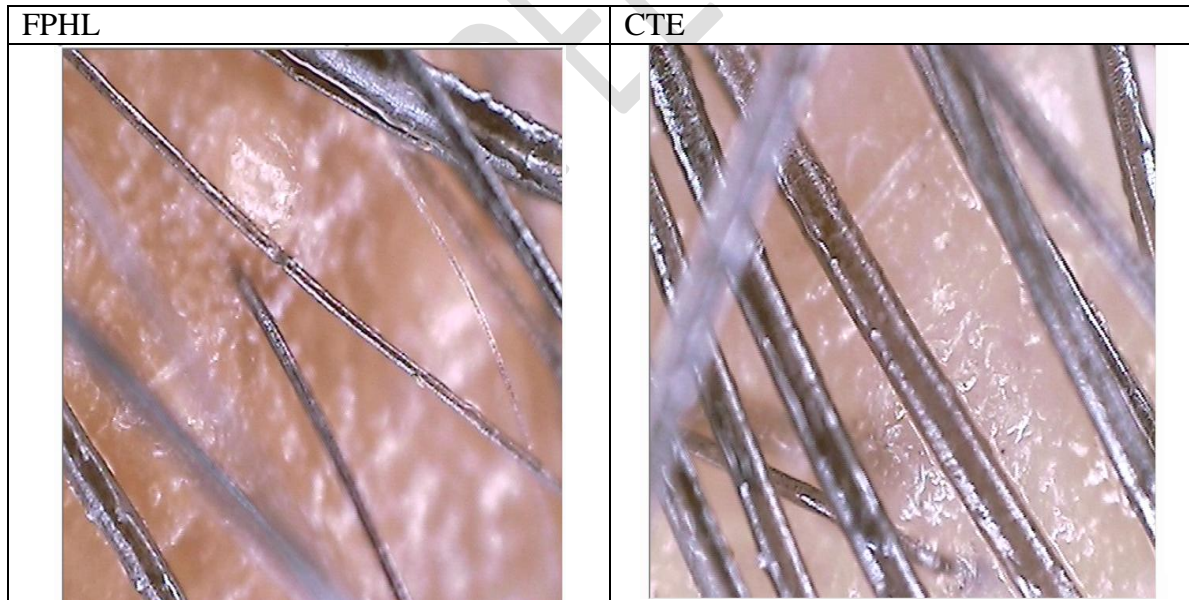
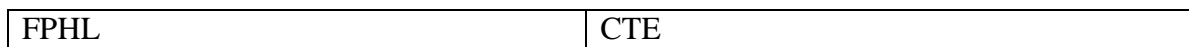


Figure 2: Hair density in FPHL and CTE



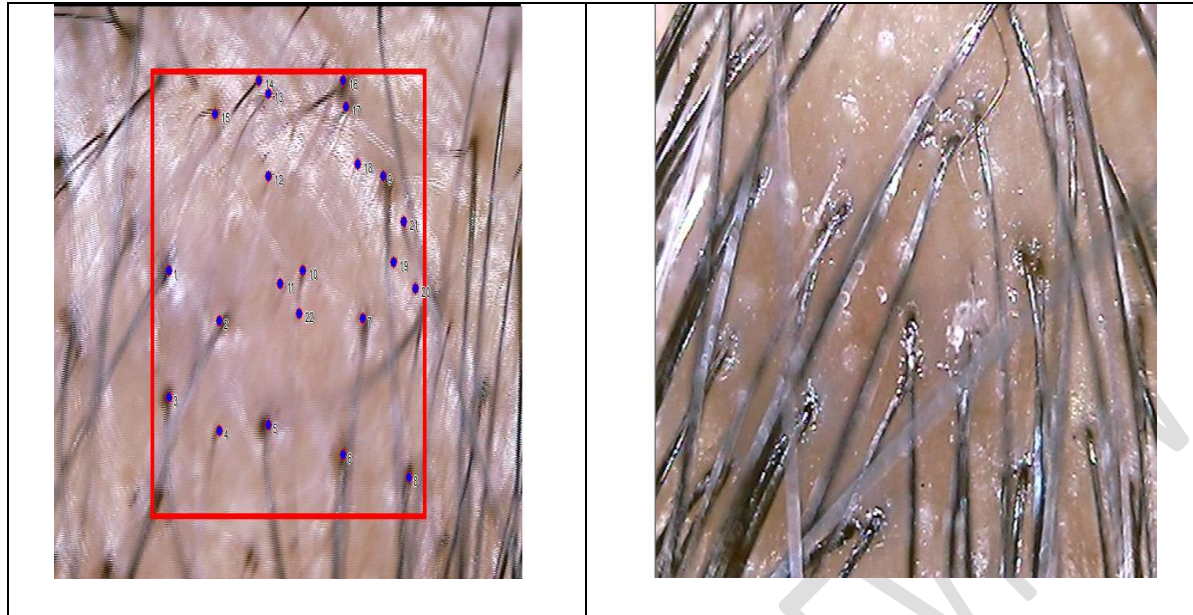


Figure 3: Follicular hair units on trichoscopy:

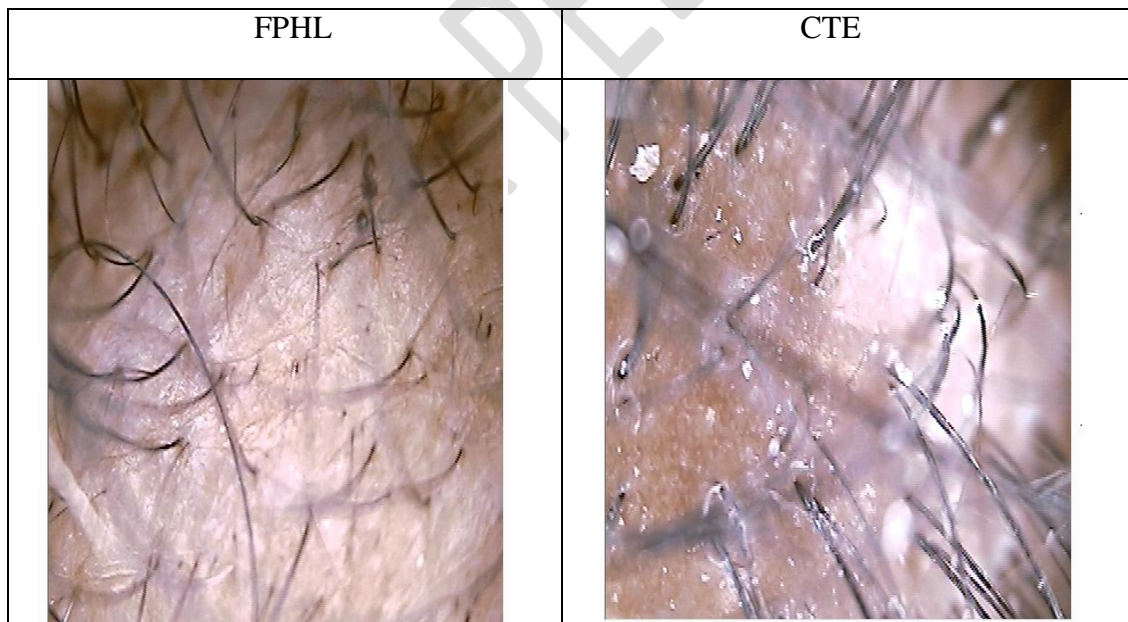
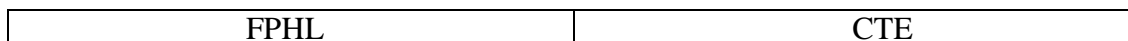
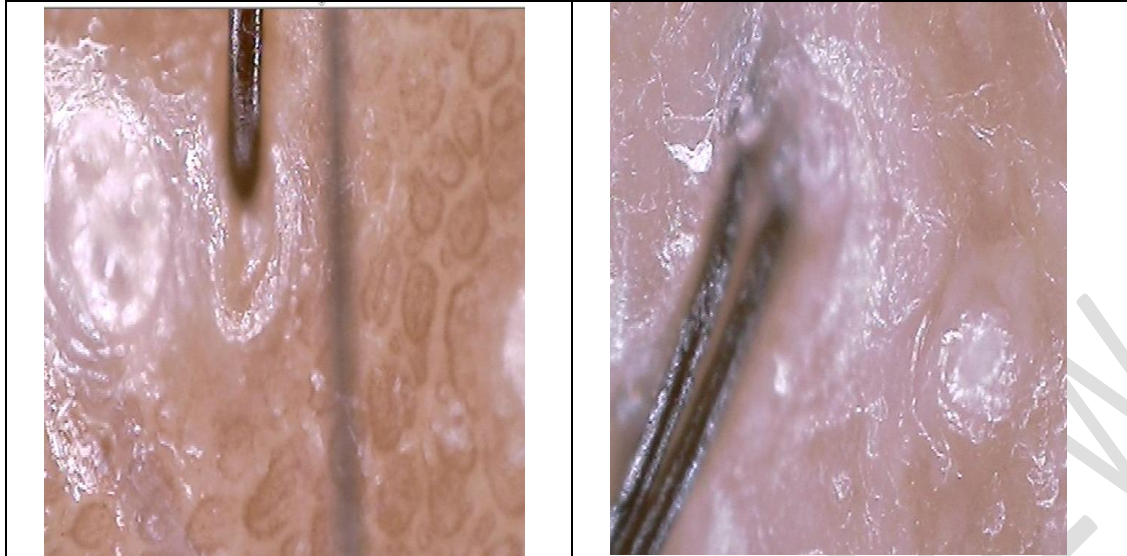


Figure 4: Yellow Dots:





References:

1. Shrivastava S. Diffuse hair loss in an adult female: Approach to diagnosis and management. *Indian J Dermatol Venereol Leprol.* 2009;75(1):20.
2. Dhurat RS. Utility of trichoscopy. *Indian J Dermatopathol Diagn Dermatol* 2018;5:89-96.
3. Kligman AM. Pathologic dynamics of hair loss.1. Telogen effluvium. *Arch Dermatol* 1961;83:175-98.
4. Whiting DA. Diagnostic and predictive value of horizontal sections of scalp biopsy specimens in male patterned androgenetic alopecia. *J Am Acad Dermatol* 1993; 28:755-63.
32. Whiting DA. Chronic telogen effluvium: increased scalp hair shedding in middle-aged women. *J Am Acad Dermatol* 1996;35:899-906.
5. Asghar F, Shamim N, Farooque U, Sheikh H, Aqeel R. Telogen Effluvium: A Review of the Literature. 2020;7.
6. Gilmore S, Sinclair R. Chronic telogen effluvium is due to a reduction in the variance of anagen duration. *Australas J Dermatol* 2010; 51: 163–167.
7. Singal A, Sonthalia S, Verma P. Female pattern hair loss. *Indian J Dermatol Venereol Leprol* 2013;79:626-40.
8. Ramos PM, Miot HA. Female Pattern Hair Loss: a clinical and pathophysiological review. *An Bras Dermatol.* 2015 Aug;90(4):529–43.

9. Wang TL, Zhou C, Shen YW, Wang XY, Ding XL, Tian S, et al. Prevalence of androgenetic alopecia in China: A community-based study in six cities. *Br J Dermatol* 2010;162:843-7.
10. Paik JH, Yoon JB, Sim WY, Kim BS, Kim NI. The prevalence and types of androgenetic alopecia in Korean men and women. *Br J Dermatol* 2001;145:95-9.
11. Shapiro J. Clinical practice. Hair loss in women. *N Engl J Med*. 2007;357:1620-30.
12. Sinclair RD, Dawber RP. Androgenetic alopecia in men and women. *Clin Dermatol* 2001; 19: 167–178.
13. Reborna A. Telogen effluvium. *Dermatology* 1997; 195: 209–212.
14. Rand S. Chronic telogen effluvium: potential complication for clinical trials in female androgenetic alopecia? *J Am Acad Dermatol* 1997; 37: 1021.
15. Study Of Trichoscopy And Histopathology In Patients With Patchy Alopecia Attending The Hair Clinic DR. RIMMALAPUDI SHRAVYA, DR.A.L. SINGH.JCR. 2019; 6(6): 628-632.
16. Dogra S, Sarangal R. What's new in cicatricial alopecia?. *Indian J Dermatol Venereol Leprol* 2013;79:576- 90.
17. Alopecia Areata Treated with Oral Azathioprine: A Case Series.Saoji V, Kulkarni S, Madke B. *Int J Trichology*. 2019;11(5):219-222.
18. Bhamla S, Dhurat R, Saraogi P. Is Trichoscopy a reliable tool to diagnose early female pattern hair loss? *Int J Trichology*. 2013;5(3):121.
19. Hatice UCE ÖZKOL, Ömer ÇALKAK, Necmettin AKDENİZ. Is TrichoScan a new diagnostic method for diffuse hair loss? *Turk J Med Sci* (2014) 44: 432-438.
20. Rakowska A, Slowinska M, Kowalska-Oledzka E, Olszewska M, Rudnicka L. Dermoscopy in female androgenic alopecia: Method standardization and diagnostic criteria. *Int J Trichology*. 2009;1(2):123.
21. Fabbrocini G, Cantelli M, Masarà A, Annunziata MC, Marasca C, Cacciapuoti S. Female pattern hair loss: A clinical, pathophysiologic, and therapeutic review. *Int J Womens Dermatol*. 2018 Dec;4(4):203–11.