

Anaesthetic management of Pre eclamptic patient with solitary kidney and uterine didelphys posted for emergency Caesarean section: A case report

ABSTRACT

Uterine didelphys results from impaired fusion of the paired Müllerian ducts. The incidence of uterine anomalies is believed to be 0.5–2.0% of reproductive-age women, with didelphic uterus renal agenesis accounting for approximately 10%. Uterine didelphys is associated with in approximately 25% of cases¹. Pre eclampsia is defined as SBP more than 160 mmhg, DBP more than 90 mmhg, associated with proteinuria and urine protein excretion >300mg in a 24 hour period or a protein creatinine ratio of atleast 0.3². Neuraxial blockade stands an effective mode of anaesthesia for these patients. Management of pre eclamptic patient with solitary kidney can be a challenge to anaesthesiologist due to various metabolic derangements including hyperkalemia, hypocalcemia, hyperphosphatemia and metabolic acidosis. Multidisciplinary approach is required to have good pregnancy outcome in these patients.

Keywords: preeclampsia, uterine didelphys, solitary kidney

Introduction

Congenital solitary kidney is a disorder caused by an abnormal development of one of the two kidneys. This abnormality can be either anatomical (unilateral renal agenesis) or functional (extreme forms of dysplasia). Uterine didelphys is a type of Mullerian duct anomaly where there is complete duplication of uterine horns as well as cervix with no communications in between. Pre eclampsia is defined as SBP more than 160mmhg, DBP more than 90 mmhg, associated with proteinuria and urine protein excretion >300mg in a 24 hour period or a protein creatinine ratio of atleast 0.3. We report a case of 21 years old pre eclamptic patient with uterine didelphys and solitary kidney to undergo Caesarean section.

Case report

A 20 years old G2A1@30 weeks +3 days of gestational age with uterine didelphys with solitary kidney (diagnosed in previous abortion with ultrasound) and gestational hypertension on treatment with Tab.labetalol 100 mg, Tabdepine 10 mg, and Inj.Dexamethasone 6 mg admitted for safe confinement of pregnancy 2 days back. Basic investigations done and found within normal limits. Her NST was reactive and showed fetal tachycardia, she had bilateral pitting pedal edema so she was administered with Pritchard regimen and she was posted for Emergency Caesarean section.

Under aseptic precautions ,patient in sitting position ,using 26 gauge quincke needle ,spinal anaesthesia was administered. Patient made supine immediately and oxygen given via facemask at 6l/minute.During the procedure ,the patient’s heart rate maintained around 80 bpm and MAP maintained above 60 and lasted for one and half hour ,postop uneventful.

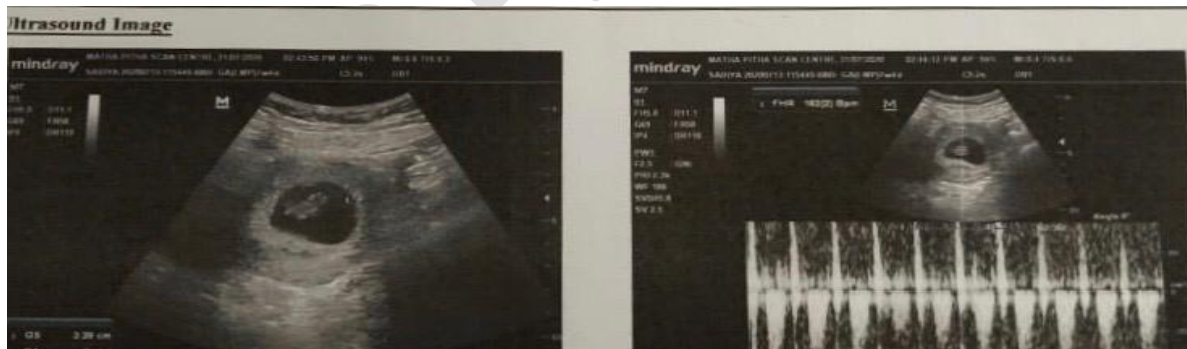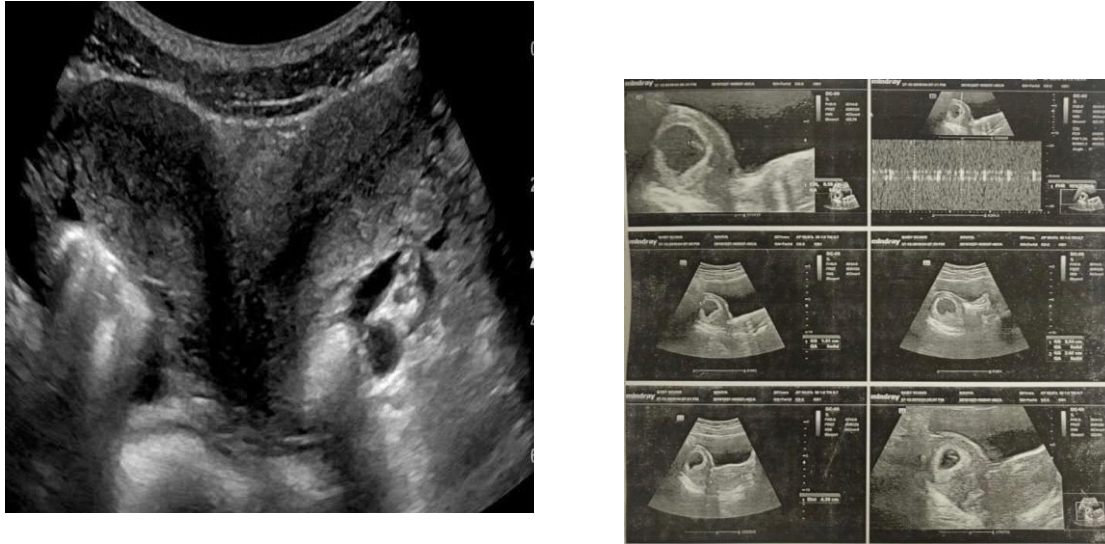


Fig. 1-4. Ultrasound images

Discussion

Patient with solitary kidney can develop various metabolic derangements including hyperkalemia, hypocalcemia, hyperphosphatemia and metabolic acidosis .Judicious fluid management ,maintenance of normovolemia and avoidance of hypotension are priorities for the successful prevention of intra op renal injury for patient with solitary kidney .In patient who had hypertension and proteinuria held a high risk for progression to renal insufficiency

.General anaesthesia for Caesarean delivery in pre eclamptic women has increased risk of developing intra cranial hemorrhage and stroke. Thus neuraxial blockade does avoid the possibility of difficult intubation secondary to airway edema. Nonetheless there are situations in which general anaesthesia is the best anaesthetic option like severe ongoing maternal hemorrhage ,sustained fetal bradycardia with a reassuring maternal airway examination and severe thrombocytopenia or other coagulopathy or a combination of these indications. But Spinal anaesthesia in contrary has cardiovascular effects by sympathetic blockade that extends beyond the level of sensory blockade by 2 to 6 segments. Bradycardia and hypotension may occur .In this condition Ephedrine hydrochloride can be used which increases the heart rate and blood pressure at the same time. Increased production of circulating factors with potent press or effect and the increased sensitivity to vasopressor drugs in pre eclampsia along with the use of hyperbaric bupivacaine with opioids could decrease spinal induced hypotension in preeclamptic parturients. Cardiac output monitoring after spinal anaesthesia has shown that neither spinal anaesthesia nor the use of phenyl ephedrine to treat hypotension decrease cardiac output during Caesarean section delivery further supporting its safety in pre eclamptic parturients.

Conclusion

Patients with solitary kidney due to congenital causes or nephrectomy need to be counsel regarding risks of developing pyelonephritis, preeclampsia and its associated complications during pregnancy. These patients require close monitoring throughout their antenatal and postpartum period to avoid any deterioration of renal function. Multidisciplinary approach is required to have good pregnancy outcome in these patients.

References

1. Madureira AJ, Mariz CM, Bernardes JC, Ramos IM. Case 94: Uterus didelphys with obstructing hemivaginal septum and ipsilateral renal agenesis. *Radiology* 2006. May;239(2):602-606 10.1148/radiol.2392031187 [PubMed] [CrossRef] [Google Scholar]
2. Kim TE, Lee GH, Choi YM, Jee BC, Ku SY, Suh CS, et al. Hysteroscopic resection of the vaginal septum in uterus didelphys with obstructed hemivagina: a case report. *J Korean Med Sci* 2007. Aug;22(4):766-769 10.3346/jkms.2007.22.4.766 [PMC free article] [PubMed] [CrossRef] [Google Scholar]
3. Nahum GG. Uterine anomalies. How common are they, and what is their distribution among subtypes? *J Reprod Med* 1998. Oct;43(10):877-887 [PubMed] [Google Scholar]
4. Golan A, Langer R, Bukovsky I, Caspi E. Congenital anomalies of the müllerian system. *Fertil Steril* 1989. May;51(5):747-755 [PubMed] [Google Scholar]
5. Smith NA, Laufer MR. Obstructed hemivagina and ipsilateral renal anomaly (OHVIRA)

syndrome: management and follow-up. *FertilSteril* 2007. Apr;87(4):918-922
10.1016/j.fertnstert.2006.11.015 [PubMed] [CrossRef] [Google Scholar]

6. Shavell VI, Montgomery SE, Johnson SC, Diamond MP, Berman JM. Complete septate uterus, obstructed hemivagina, and ipsilateral renal anomaly: pregnancy course complicated by a rare urogenital anomaly. *Arch GynecolObstet* 2009. Sep;280(3):449-452
10.1007/s00404-008-0919-6 [PubMed] [CrossRef] [Google Scholar]

7. Burgis J. Obstructive Müllerian anomalies: case report, diagnosis, and management. *Am J ObstetGynecol* 2001. Aug;185(2):338-344 10.1067/mob.2001.116738 [PubMed] [CrossRef] [Google Scholar]

8. García González P, MeanaMorís AR, GraciaChapullé A, Matesanz Pérez JL. The role of MRI in congenital cystic lesions in the pelvis: a case of uterus didelphys with double vagina, hematocolpos, and ipsilateral renal agenesis... *Radiologia* 2009. Mar-Apr;51(2):194-197
10.1016/j.rx.2009.01.001 [PubMed] [CrossRef] [Google Scholar]

9. Shulman LP. Müllerian anomalies. *ClinObstetGynecol* 2008. Jun;51(2):214-222
10.1097/GRF.0b013e31816feba0 [PubMed] [CrossRef] [Google Scholar]

10. Jindal G, Kachhawa S, Meena GL, Dhakar G. Uterus didelphys with unilateral obstructed hemivagina with hematometrocolpos and hematosalpinx with ipsilateral renal agenesis. *J Hum ReprodSci* 2009. Jul;2(2):87-89 10.4103/0974-1208.57230 [PMC free article] [PubMed] [CrossRef] [Google Scholar]

11. Olpin JD, Heilbrun M. Imaging of Müllerian duct anomalies. *ClinObstetGynecol* 2009. Mar;52(1):40-56 10.1097/GRF.0b013e3181958439 [PubMed] [CrossRef] [Google Scholar]

12. Rock JA, Breech LL. Surgery for anomalies of the Mullerian ducts. In: Rock JA. And Thompson JD, editor, *Te Linde Operative Gynecology*, 9th ed, Philadelphia: Lippincott Wilkins, 2003:746-8. [Google Scholar]

13. Rehman A, Hasan Z, Amanat S, Shaukat T, Saeed A, Jamil K, et al. Combined persistent Mullerian Duct Syndrome, Transverse Testicular Ectopia and Mosaic Klinefelter's Syndrome. *J Coll Physicians Surg Pak* 2008. Jun;18(6):375-377 [PubMed] [Google Scholar]

14. Kaufman Y, Lam A. The pelvic uterus-like mass—a primary or secondary Müllerian system anomaly? *J Minim Invasive Gynecol* 2008. Jul- Aug;15(4):494-497
10.1016/j.jmig.2008.03.002 [PubMed] [CrossRef] [Google Scholar]

UNDER PEER REVIEW