

Impact Of Superior And Inferior Approach In Identification And Preservation Of Spinal Accessory Nerve During Modified Radical Neck Dissection In Patients With Oral Squamous Cell Carcinoma.

Abstract:

Background: During neck dissection, injuries to spinal accessory nerve (SAN) are most common cause of post-operative shoulder morbidity. Which is known as 'Shoulder Syndrome'. Despite the evolution in neck dissection procedures from radical to super-selective neck dissection, post-operative shoulder dysfunction remains a point of exasperation for head and neck surgeons. It significantly impacts the standard of living for patients with head and neck cancer. According to the anatomic course and branching of SAN, there are various dissection technique for identification and preservation. Our comparison of superior dissection approach with inferior dissection approach for identification, preservation, and complete skeletonization of SAN in posterior neck dissection has not been studied based on its anatomical course.

Objective: To compare Superior Vs. Inferior approach group in regards to safety and superiority of the approach for SAN preservation with minimal or no intraoperative and or post-operative functional complications.

Method: The patients will be randomly divided into two groups according to the approach used to identify and preserve SAN (superior Vs. inferior approach group). The intraoperative clinical and post-operative data will be collected and evaluated with appropriate statistical analysis.

Results: Collected data from 24 patients will undergo statistical analysis to obtain the results.

Conclusion: This study expects to find a superior modality amongst the Superior dissection approach and inferior dissection approach in terms of identification, preservation, and post-operative functional deficit for spinal accessory nerve.

Keywords: Functional neck dissection, sloping shoulder syndrome, spinal-accessory nerve, trapezius muscle, iatrogenic spinal accessory nerve injury.

Introduction:

In this era, head and neck cancer is a common cause of morbidity and mortality. However, approximately >10 million newly diagnosed and >6 million deaths each year occur owing to cancer. Oral cancer is considered the sixth most common cancer in the world, with India contributing to almost one-third of the total burden. ^(1, 2)

'Squamous cell carcinoma' (SCC) remains the most common form of oral cancer. According to the primary site involved, such epithelial malignancies spread too quickly via the lympho vascular route and metastasize and invade surrounding tissues and lymph nodes in a somewhat predictive pattern. ⁽³⁾

Thus neck dissection (ND) is a foremost procedure for diagnosis (staging) and treatment in head and neck cancer patients with cervical lymph node metastasis. Controlling the local lymph node metastasis tumor extemporization and neck dissection remains a prime oncological requirement. Neck dissection is a surgical procedure done with curative intent in which lymph nodes and surrounding lymphatic tissue of the neck.

Evolution has taken place in neck dissection procedure from Radical Neck Dissection to Functional neck dissection super-selective neck dissection with the same described oncological results and given priority the try for preserve cancer-free vital structures and SAN.⁽⁴⁾ Modified neck dissection with preservation of the SAN has widely acknowledged an oncologically safe procedure. This will further prevent functional disabilities for patients and also unnecessary medico-legal implications for the doctors.

Spinal accessory nerve is an eleventh paired cranial nerve with cranial and spinal root having somatic motor function. Cranial portion of SAN is considered as a part of vagus complex. After exiting from jugular foramen an external branch comprises spinal accessory fibers derives from LMNs of C1-C4 segments of cervical spinal cord. SAN innervates sternocleidomastoid muscle and upper two thirds of trapezius muscle. After supplying sternocleidomastoid muscle, the SAN run downwards obliquely in posterior triangle of neck flanked by the superficial and deep layers of the deep cervical fascia. In this area SAN is embedded in loose connective tissue and with the cervical lymph node chain. SAN gives off numerous branches to the upper part of the trapezius afore passing under the anterior edge of muscle. The SAN continues to descend obliquely in the trapezius muscle to innervate the lower part of the muscle.^(5, 6) Any accidental injury during neck dissection to SAN causes “sloping shoulder syndrome”.

Increase frequency of injury to SAN occurs during its separation from SCM muscle in Inferior triangle of neck. Therefore knowledge of posterior neck anatomy is important to prevent any accidental injury during functional neck dissection in almost any extensive surgery of the posterior neck. The comparison of Superior dissection approach with inferior dissection approach for identification and preservation of SAN in posterior neck dissection has not been studied based on its anatomical course.⁽⁷⁾

Our intent for the study is, 1) To compare Superior Vs. Inferior approach group in regards to safety and superiority for structural continuity and functional integrity of SAN with minimal or no intraoperative and or post-operative functional complications.

Aim: To evaluate and compare the efficacy of Superior and Inferior dissection approach for identification and preservation of spinal accessory nerve (SAN) during modified radical neck dissection in oral squamous cell carcinoma (OSCC).

Objectives:

To Evaluate the time taken in identification and preservation of spinal accessory nerve, feasibility of complete skeletonization and postoperative functional deficit with respect to spinal accessory nerve in Superior dissection approach.

To evaluate the time taken in identification and preservation of spinal accessory nerve, feasibility of complete skeletonization and postoperative functional deficit with respect to spinal accessory nerve in Inferior dissection approach.

To compare the aforementioned parameter when associated respectively with superior dissection approach and inferior dissection approach during neck dissection procedure in patients with OSCC.

Methodology:

The present prospective, single blinded, interventional, randomized controlled parallel arm study is scheduled to be conducted in the department of Oral and Maxillofacial Surgery, Sharad Pawar Dental College and Hospital, Acharya Vinoba Bhave Rural Hospital, Sawangi (Meghe), Wardha for a duration of 6 months. The description includes normal dissection during routine surgery after proper consent and with no other deviation to the routine methods.

Sample size calculation: By using purposive sampling, total 24 patients will be included - 12 patients in each group will be selected during the period of December 2020- May 2021.

Formula Used:

$$n = \left(\frac{(Z_{\alpha/2})(\sigma)}{E} \right)^2$$

n= 24 Where, E=5 σ = 15 $Z_{\alpha/2}$ = 1.96 for 95% confidence interval.

Power of the test: 80% and Confidence Interval: 95% have been verified by statistician & found to be optimum.

Patient selection:

Patients fulfilling the following criteria will be recruited for the trial.

Criteria for Inclusion:

- Proven case of OSCC in whom a surgical procedure i.e. excision with neck dissection and reconstruction are performed with the curative intent.

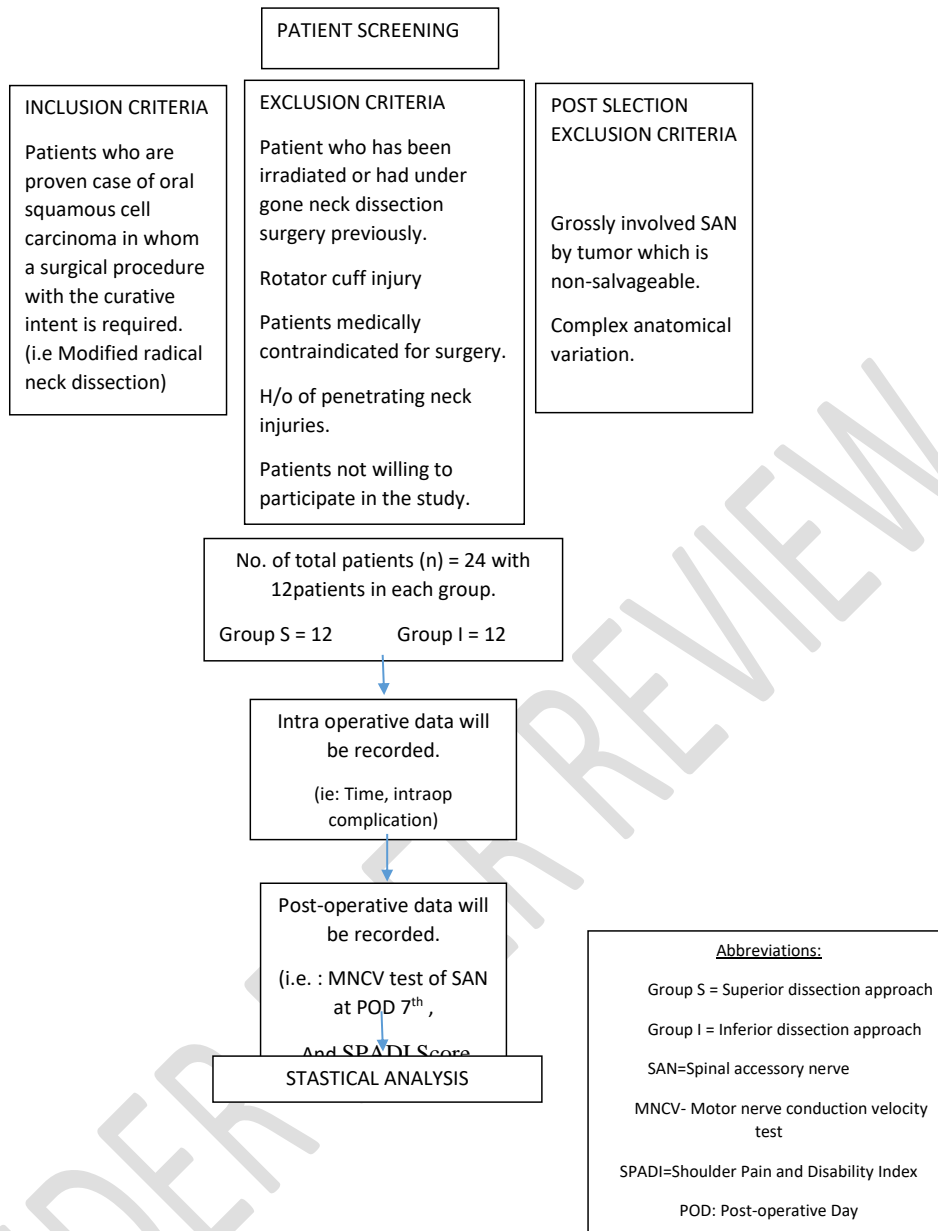
Criteria for Exclusion:

- Patient who has been irradiated or had undergone neck dissection surgery previously.
- Rotator cuff injury
- Patients medically contraindicated for surgery.
- H/o of penetrating neck injuries.
- Patients not willing to participate in the study.

Criteria for Post-Selection Exclusion:

- Grossly involved SAN by tumor which is non-salvageable.
- Complex anatomical variation

Fig 1. SUMMARY OF RESEARCH METHODOLOGY



The study population (n =24) will be divided equally into two groups in a randomized manner. The subjects will be blinded to the allocation group.

Group S- Patients in which intraoperative identification of SAN will be done with Superior approach at posterior triangle of neck.

Group I- Patients in which intraoperative identification of SAN will be done with Inferior approach at posterior triangle of neck.

SURGICAL PROTOCOL:

- All the cases will be operated by a single senior surgeon having considerable experience in Oral Oncology with familiarity to both the approaches.

- After obtaining a pre-anaesthetics fitness, patient will undergo surgical procedure which is a primary tumor resection along with functional neck dissection.
- Intra operative time for identification for SAN will be noted and measured from raising posterior flap to identification, till skeletonization of SAN throughout its course in posterior triangle of neck. This will be done for both the groups (Group S and Group I) by an independent individual by a digital stop watch.
- Postoperative physiologic functional integrity of SAN will be evaluated by using Motor nerve conduction velocity (MNCV) at 7th POD. Objective analysis will be done by SPADI Scale (Shoulder pain and disability index) at POD 30th.

Here we attempted to elaborate and compare two possible approaches for SAN identification and preservation as below,

Approaches to SAN in Posterior triangle:

1) Superior Approach:

This approach involves identification of antero-superior part of SAN which is done higher up in the posterior triangle at the anterior border of the sternocleidomastoid (STM) muscle. The fascia is raised up anteriorly. Point for identification are Erb's point and a constant vein running along with SAN (Chauker's vein¹¹). For preservation and complete skeletonization all the bulk of SCM is dissected using blunt dissection with a fine artery forceps, the nerve is then traced proximally following the whole of its course, without dividing the attachments of SCM. In this approach the division of the major part of the SCM which remains anterior to the SAN. Using this method, the nerve is traced and exposed between the sternocleidomastoid and the trapezius muscle. All distal branches of the nerve are bared out and preserved. Initial dissection allows assessment of nodal metastases along the SAN and if the tumor involvement is found, the procedure is aborted and the nerve will be transected. Moreover, the course of SAN in the SCM is not straight, and the attachment of cervical branches is not consistent, so this approach may have chances of injury to the cervical contributions. Though SAN is dissected circumambiently but the posterior neck contents deep to the SAN remain undivided. The SAN is judiciously elevated with a nerve hook with minimal traction and safely transported to the upper neck away from the further field of dissection. The further remainder neck dissection is continued and completed.

2) Inferior Approach:

In this approach cervical vessels and anterior border of trapezius are used as identification points. The dissection has to be started at the anterior border of the trapezius muscle, overhead to the fascia of the splenius-capitis and the levator-scapulae muscles in the posterior triangle of neck. A small slip of SCM posterior to the nerve, which has to be dissected, thus easy to separate the nerve, and the reflections of the branches are more prominent and easier to identify. Then the nerve is traced superiorly into the posterior border of the sternocleidomastoid muscle. The fibers of the sternocleidomastoid- muscle above SAN are divided precisely, exposing the nerve. This retrograde technique, the nerve is followed to anterior border of

trapezius to sternocleidomastoid muscle then to the posterior belly of the digastric muscle superiorly. Moreover, further posterior triangle dissection is not required for this type of approach.

EVALUATION:

- Time taken by both the approaches will be evaluated and compared.
- Functional integrity for SAN will be evaluated by MNCV device within one week postoperatively. MNCV values of both the approaches will be compared i.e. Amplitude and latency.
- Shoulder pain and disability index questionnaire (SPADI) will also be evaluated to compare postoperative shoulder function at operated side on POD 30th.

Table for collecting Basic Clinical Data:

1. Time taken from reflection of posterior flap to exposure and skeletonization of SAN:

Group	Time Measured (in minutes)
Superior Approach	
Inferior Approach	

2. MNCV evaluation onPostoperative Day.

MNCV TEST	Group –S Interpretation		Group-I Interpretation	
	Amplitude (mV)	Latency (mS)	Amplitude (mV)	Latency (mS)
On Operated side				
Non-operated side (control group)				

3.Shoulder Pain and Disability Index (SPADI):

(Source: Roach KE, Budiman-Mak E, Songsiridej N, Lertratanakul Y. Development of a shoulder pain and disability index. Arthritis Care Res. 1991 Dec;4(4):143-9.)

A) Pain scale: How severe is your pain? Circle the number that best describes your pain where: 0 = no pain and 10 = the worst pain imaginable.

At its worst?	0	1	2	3	4	5	6	7	8	9	10
When lying on the involved side?	0	1	2	3	4	5	6	7	8	9	10

Reaching for something on a high shelf?	0	1	2	3	4	5	6	7	8	9	10
Touching the back of your neck?	0	1	2	3	4	5	6	7	8	9	10
Pushing with the involved arm?	0	1	2	3	4	5	6	7	8	9	10

B) Disability scale:

How much difficulty do you have? Circle the number that best describes your experience where: 0 = no difficulty and 10 = so difficult it requires help.

Washing your hair?	0	1	2	3	4	5	6	7	8	9	10
Washing your back?	0	1	2	3	4	5	6	7	8	9	10
Putting on a shirt that buttons down the front?	0	1	2	3	4	5	6	7	8	9	10
Putting on your pants?	0	1	2	3	4	5	6	7	8	9	10
Placing an object on a high shelf?	0	1	2	3	4	5	6	7	8	9	10
Carrying a heavy object of 10 pounds (4.5 kilograms)	0	1	2	3	4	5	6	7	8	9	10
Removing something from your back pocket?	0	1	2	3	4	5	6	7	8	9	10

Interpretation of scores:

Total pain score: _____ / 50 x 100 = ___ %

(Note: If a person does not answer all questions divide by the total possible score, eg. if 1 question missed divide by 40)

Total disability score: _____ / 80 x 100 = %

(Note: If a person does not answer all questions divide by the total possible score, eg. if 1 question missed divide by 70)

Total Spadi score : _____ / 130 x 100 = %

(Note: If a person does not answer all questions divide by the total possible score, eg. if 1 question missed divide by 120) The means of the two subscales are averaged to produce a total score ranging from 0 (best) to 100 (worst).

Minimum Detectable Change (90% confidence) = 13 points (Change less than this may be attributable to measurement error)

After collection of all the data the clinical outcome will be evaluated in terms of the following parameters:

Intraoperatively: Intraoperative operating time and surgical complications (intraoperative) related to SAN.

Postoperatively: MNCV test within a week where latency and amplitude of bilateral SAN will be evaluated and compared.

After a month subjective shoulder function evaluation will be done with the help of multi-dimensional SPADI questionnaire. Thus the obtained data will be tabulated and will be analysed using statistical methods.

RESULTS:

Results would be aimed at determining a superior modality amongst Superior dissection approach and inferior dissection approach in terms of identification, preservation and post-operative functional deficit for spinal accessory nerve.

DISCUSSION:

In this era, preservation of SAN during neck dissection is preferred approach in major of the high volume cancer centres. So when it is possible, preservation of SAN has to be a rule rather than an exception. Despite of that shoulder morbidity on the operated side is still a significant, common early post-operative complication. The understanding various surgical approaches for identification and preservation according to nuances of SAN is of deemed importance to prevent shoulder dysfunction.

Bocca and Pignataro (1967), showed by their pioneer work that SAN is located in an aponeurotic compartment separated from the cervical nodes; preservation of the nerve is possible and prevents shoulder dysfunction syndrome with same oncological outcome. So now modified neck dissection with preservation of internal jugular vein along with SAN is more putative treatment for nodal metastasis in OSCC.⁽⁹⁾

Cheng et al. (2000), in their prospective study they investigated the effects of neck dissection on the shoulder function and subjectively evaluated the pain level. Study suggested that patients who underwent selective neck dissection had the least damage to SAN function and the least shoulder morbidity after neck dissection. While almost 80% patients who underwent radical neck dissection developed sloping shoulder morbidity and prolonged functional recovery.⁽¹⁰⁾

Chaukar, DA, Pai, Anil D'Cruz, AK. A (2006), published a novel precise method for identification of SAN with maximum postoperative functional output.⁽¹¹⁾ They have taken a small but constant vein as a stable marker which runs anterior to the SAN.

Luciana Pereira de Lima, Ali Amar, Carlos Neutzling Lehn (2011), they evaluated SAN dysfunction after neck dissection procedure. Evaluation of nerve injury in this study was done by electromyogram. They mentioned the usefulness of trapezius muscle EMG correlating with intraoperative SAN injury. They also concluded that surface EMG for post of evaluation for SAN dysfunction is more sensitive and painless method.⁽¹²⁾

Michael James Eastwood et al (2018) , in their cadaveric anatomical study they concluded that 1) SCM branch of the occipital artery (SBOA), 2) Superior SCM tendon (SST) are considered reliable and accurate landmarks for intraoperative identification of SAN.⁽¹³⁾

Akhilak Hussain et al (2019), they have described possible safer dissection ways to approach SAN during its dissection from SCM at posterior triangle intraoperatively. Their study depicts inferior approach is time saving and easier than other dissection approaches.⁽⁸⁾

Eisele et al 1991, in their study of 200 neck dissection with inferior (retrograde) approach for preservation of SAN, only in one case they found iatrogenic injury to the nerve. But they

haven't performed any post-operative objective shoulder function assessment. They concluded that retrograde approach (inferior) is more feasible, helps to eliminate the unnecessary anatomical complication and thus reduces the surgical time.⁽¹⁴⁾ Related studies on neck dissection and oral squamous cell carcinoma were reviewed⁽¹⁵⁻¹⁹⁾.

Intraoperative identification and skeletisation of the SAN is key in reducing nerve injury thus preserving the motor function.

Scope: The study intended to evaluate the superiority of approach based on anatomical course, preserving and maintaining functional outcome of SAN.

Conclusion:

Decreased post-operative shoulder function after intraoperative CN XI damage to some extent – due to surgical approach used during dissection, but logic dictates that a method of preservation of the nerve should accurately avoid excessive dissection and with adequate anatomical awareness, minimal retraction- manipulation damage can be prevented, thereby conserving the maximum post-operative function.

References:

1. Moore SR, Johnson NW, Pierce AM, Wilson DF. The epidemiology of mouth cancer: a review of global incidence *Oral Dis* 2000. Mar; 6 (2): 65 - 74. <https://doi.org/10.1111/j.1601-0825.2000.tb00104.x>
2. GLOBOCAN: Estimated Cancer Incidence, Mortality and Prevalence Worldwide in 2012. International Agency for Research on Cancer [online] 2012; [cited 2016 July 16] Available from: http://globocan.iarc.fr/Pages/fact_sheets_population.aspx.
3. Martin TA, Ye L, Sanders AJ, et al. Cancer Invasion and Metastasis: Molecular and Cellular Perspective. In: Madame Curie Bioscience Database [Internet]. Austin (TX): Landes Bioscience; 2000-2013. Available from: <https://www.ncbi.nlm.nih.gov/books/NBK164700/>.
4. Gogna S, Kashyap S, Gupta N. Neck Cancer Resection and Dissection. [Updated 2020 Aug 16]. In: StatPearls [Internet]. Treasure Island (FL): StatPearls Publishing; 2021 Jan-. Available from: <https://www.ncbi.nlm.nih.gov/books/NBK536998/>
5. Walker HK. Cranial Nerve XI: The Spinal Accessory Nerve. In: Walker HK, Hall WD, Hurst JW, editors. *Clinical Methods: The History, Physical, and Laboratory Examinations*. 3rd edition. Boston: Butterworths; 1990. Chapter 64. Available from: <https://www.ncbi.nlm.nih.gov/books/NBK387/>
6. Krause HR, Bremerich A, Herrmann M (1991). The innervation of the trapezius muscle in connection with radical neck-dissection: an anatomical study. *Journal of Cranio Maxillo-Facial Surgery*, 19: 87±89.
7. Popovski, V et al. "Spinal accessory nerve preservation in modified neck dissections: surgical and functional outcomes." "Preservazione del nervo accessorio spinale nelle dissezioni del collo: outcomes chirurgici e funzionali." *Acta otorhinolaryngologica Italica : organo ufficiale della Societa italiana di otorinolaringologia e chirurgia cervico-facciale* vol. 37,5 (2017): 368-374. doi:10.14639/0392-100X-844.
8. Hussain A, Singhal A, Siddiquee N, Thakur B. Safer dissection of spinal accessory nerve from sternocleidomastoid muscle during neck dissection. *Ann Indian Acad Otorhinolaryngol Head Neck Surg* 2019;3:55-7
9. Bocca E, Pignataro O. LXXXI A Conservation Technique in Radical Neck Dissection. *Annals of Otology, Rhinology & Laryngology*. 1967;76(5):975-987. doi:10.1177/000348946707600508)

10. Cheng PT, Hao SP, Lin YH, Yeh AR. Objective comparison of shoulder dysfunction after three neck dissection techniques. *Ann Otol Rhinol Laryngol*. 2000 Aug;109(8 Pt 1):761-6. doi: 10.1177/000348940010900811. PMID: 10961810.
11. Chaukar DA, Pai A, D'Cruz AK. A technique to identify and preserve the spinal accessory nerve during neck dissection. *J Laryngol Otol*. 2006 Jun;120(6):494-6. doi: 10.1017/S0022215106000879. PMID: 16772057.
12. Lima, Luciana Pereira de, Amar, Ali and Lehn, Carlos Neutzling Spinal accessory nerve neuropathy following neck dissection. *Brazilian Journal of Otorhinolaryngology* [online]. 2011, v. 77, n. 2 [Accessed 12 July 2021] , pp. 259-262. Available from: <<https://doi.org/10.1590/S1808-86942011000200017>>. Epub 25 Apr 2011. ISSN 1808-8686. <https://doi.org/10.1590/S1808-86942011000200017>.
13. Eastwood MJ, George AP. A Novel Approach to Identifying the Spinal Accessory Nerve in Surgical Neck Dissection. *Otolaryngology–Head and Neck Surgery*. 2018;159(2):300-302. doi:10.1177/0194599818766057.
14. Eisele DW, Weymuller EA Jr, Price JC. Spinal accessory nerve preservation during neck dissection. *Laryngoscope*. 1991 Apr;101(4 Pt 1):433-5. doi: 10.1002/lary.1991.101.4.433. PMID: 1810288.
15. Mathur, Akash, Naincy Rastogi, Dinesh Gurjar, Ramkrishna Sai, Arvind Lakesar, and Hemant Malhotra. “Safety and Efficacy of Weekly versus Three-Weekly Paclitaxel plus Platinum Neoadjuvant Chemotherapy in Patients with Locally Advanced Squamous Cell Head and Neck Carcinoma: A Pilot Study.” *SOUTH ASIAN JOURNAL OF CANCER* 7, no. 4 (December 2018): 254–57. https://doi.org/10.4103/sajc.sajc_18_17.
16. Goyal, R., Singh, C.V., Jain, S., Parveen, S., Gupta, P., Gupta, D., 2020. Our Experience with Nasolabial Flaps in Soft Tissue Reconstruction of Oral Malignancy; Feasible Option in Rural Set Up. *Indian Journal of Otolaryngology and Head and Neck Surgery*. <https://doi.org/10.1007/s12070-020-02257-2>
17. Agarwal, A., Bholra, N., Kambala, R., Borle, R.M., 2019. Touch Imprint Cytology: Can It Serve as an Alternative to Frozen Section in Intraoperative Assessment of Cervical Metastasis in Oral Squamous Cell Carcinoma? *Journal of Oral and Maxillofacial Surgery* 77, 994–999. <https://doi.org/10.1016/j.joms.2019.01.011>
18. Panchbhai, A., Bhowate, R., 2020. MRI evaluation of involvement of parotid and submandibular glands by tongue squamous cell carcinoma. *Oral Oncology* 102. <https://doi.org/10.1016/j.oraloncology.2019.104557>
19. Niveditha S, Chandak SR, Lamture Y. Diagnostic Efficacy of Fine Needle Aspiration Cytology in Neck Swelling - A Systematic Review. *JOURNAL OF EVOLUTION OF MEDICAL AND DENTAL SCIENCES-JEMDS*. 2021 Mar 15;10(11):829–34.