

## **Evaluation of Clinical Outcome of Cranioplasty Using Different Prosthetic Materials In Traumatic Brain Injury Patient: An Observational Study**

### **Abstract:**

**Background:** Injuries of head, cerebral tumours, infections and ischemia are the most common causes of intracranial disorders and decompressive craniotomy may require to treat those patient followed by reconstruction later on. After loss of skull bone, cranial reconstruction or Cranioplasty is a choice of treatment worldwide for the restoration of the skull integrity. There are different types of materials which can be used for Cranioplasty but all have their own advantages and pitfalls.

**Objective:** Evaluation of clinical outcome of Cranioplasty using different prosthetic materials i.e Polymethyl methacrylate (PMMA), Titanium (Ti), Polymethyl methacrylate Bone Cement(PMMA Bone cement) in traumatic brain injury patient.

**Method:** The patients will be divided into 4 groups according to the material used for Cranioplasty. (PMMA, Ti, Autologous bone graft, PMMA Bone cement). The intra operative clinical data and post-operative data will be collected from the previously collected records. (operative time, blood loss, including any complication or graft rejection). Statistical analysis will be done.

**Results:** Collected data form 40 patients will be statistically analysed to obtain the result. Expected outcome is PMMA Bone cement, is an equally effective prosthetic material as compared to PMMA and Ti in terms of intra operative and post-operative clinical outcome for Cranioplasty in traumatic brain injury patients.

**Conclusion:** This study would help in knowing the feasibility of using PMMA bone cement as a Cranioplasty material and will evaluate the clinical outcome of PMMA, Ti and PMMA bone cement in Cranioplasty.

**Keywords:** Cranioplasty, Traumatic brain injury, PMMA Bone Cement, titanium, PMMA

### **Introduction:**

Trauma, pathologies, congenital defects and adjunct surgical corrections often leads to Cranial defects which may put the brain in jeopardy and indicates for a secondary reconstructions which is a interdisciplinary action involving maxillofacial Prosthodontist and neurosurgeon. Such defects can be treated with Cranioplasty, for shielding the underlying brain. Along with providing protection to the brain it relieves pain, restores appropriate cosmetic appearance, improving neurological function, psychosocial rehabilitation and overall improves the quality of life.<sup>1-3</sup> There are many options which have been proposed for the reconstruction of these defects . Autologous bone is generally used for Cranioplasty in a wide manner. It is comparatively inexpensive, easily obtainable, shows good fit and contour, there is no risk of disease transmission and is viable.<sup>4</sup> The most commonly reported complications are bone resorption and infection, with a wide range in timing, and occurrence<sup>5-6</sup>. There are various alternative options have been proposed in the literature for cranioplasty throughout the years. Among them PMMA and Ti are most widely used. At present, PMMA can be used in a customized 3- dimensional (3D) mould too for achieving

better cosmetic outcome. The ideal material for cranioplasty should have some favourable characteristics, among them viability (i.e, the ability of growth and resistant to infection) and ready availability is of utmost importance. It should be biocompatible, biologically inert, having the capability of osteoconduction and osteoinduction , be able to withstand mechanical forces, easy to manipulate and allows customised designing and fabrication, so that the prosthesis fits the cranial defect exactly and obtains proper closure. It should gradually be replaced by bone, should be nonconductive of heat and of course the cost should be reasonable.<sup>7,8</sup> PMMA Bone cement has the properties of an graft material for Cranioplasty. But there is no study in the literature using this material as a Cranioplasty graft material in spite of having ideal properties and being cost effective, which is an important factor to be taken into consideration in the rural parts of a developing country like India<sup>9,10</sup>.

This study is to examine the clinical outcome of PMMA Bone cement and to suggest whether it is an equally effective material or not in clinical outcome as compared to PMMA and Ti for Cranioplasty in traumatic brain injury patients.

**Aim:** To evaluate clinical outcome of Cranioplasty using different prosthetic materials (PMMA, Ti, PMMA Bone Cement) in traumatic brain injury patient.

**Objectives:**

1. To evaluate the clinical outcome of Cranioplasty using **autologous bone graft**.
2. To evaluate the clinical outcome of cranioplasty using different prosthetic materials i.e **Polymethylmethacrylate (PMMA), Ti and Polymethyl bone cement (PMMA Bone cement)**
3. To comparatively evaluate the clinical outcome of Cranioplasty using different prosthetic material.

**Methodology:**

This study will be performed In the Department of Prosthodontics and Crown & Bridge, Sharad Pawar Dental college, Sawangi (Meghe), Wardha.

**Sample size calculation:** Sample size determination is 35 in number and considering the drop outs, sample size has been estimated 40. The total minimum sample size with 90% of confidence interval is 10 for each group. The study is divided into four groups which will include 10 participants in each group.

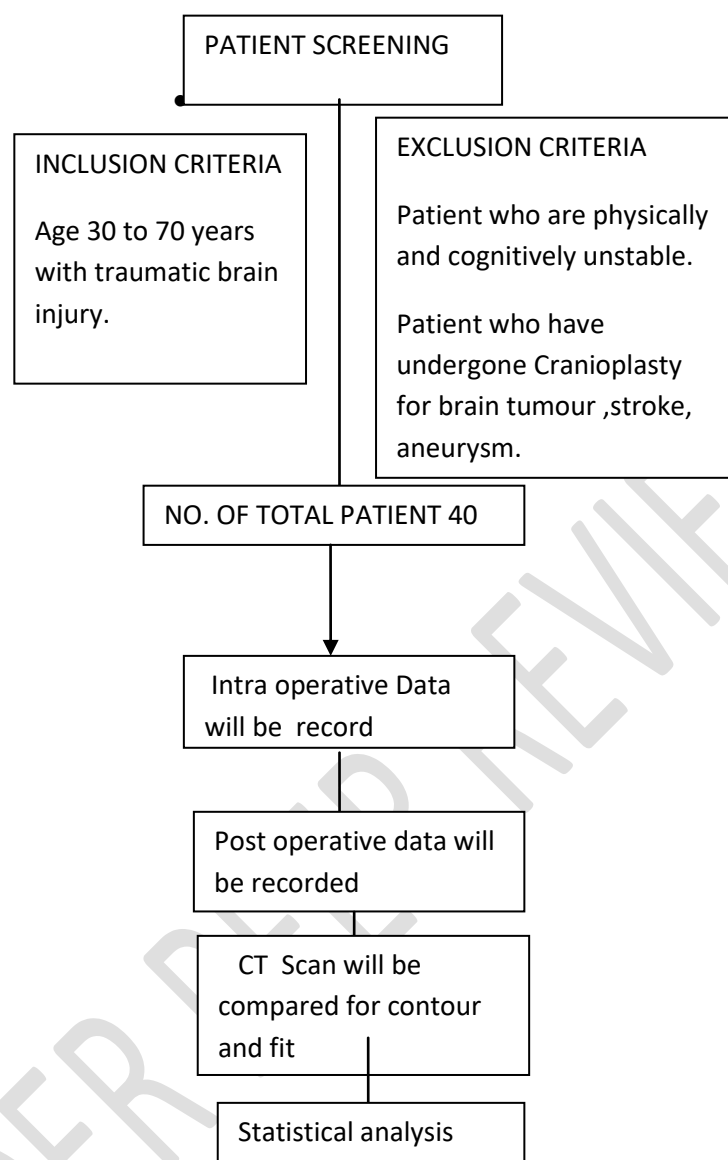
**Study type and design:** Retrospective observational.

**Patient selection:** 40 patients will be selected who had post traumatic brain injury and subsequently underwent cranioplasty from 2015 to 2020 in the Dept. of Neurosurgery of Acharya Vinoba Bhave Rural Hospital, ABVRH(Sawangi, Meghe), Wardha.

**Inclusion criteria:** Age 30 to 70 years with traumatic brain injury and without any other underlying disease or systemic disease.

**Exclusion criteria:**

Patient who have undergone Cranioplasty for brain tumor, stroke, aneurysm.  
Patient who are physically and cognitively unstable.



**Fig.1: Summary of research methodology**

The patients will be divided into 4 groups according to the material used for Cranioplasty. Group 1 patients receiving fresh frozen autograft Cranioplasty. Group 2 patients receiving a custom-made prefabricated PMMA prosthesis. Group 3 receiving titanium plates for Cranioplasty and group 4 patients rehabilitating with bone cement (PMMA Bone cement), Cranioplasty. Firstly all the demographic data will be collected then in order to comparatively evaluate the intra operative clinical outcome of Cranioplasty using different prosthetic materials all the basic clinical data i.e (operative time, blood loss and post operative complications) will be collected from the Dept. of Neurosurgery of Acharya Vinoba Bhave Rural Hospital, ABVRH (Sawangi, Meghe), Wardha by using their digitalized database patient record. The fit and contour of the Cranioplasty will be compared with the help of 6 months post operative CT scan. In 6 months post cranioplasty CT scan the preoperative contour will be marked with the dotted line and the distance between the dotted line and the outer border of the given graft will be measured with digital caliper. The measurement will be done from the highest point of the dotted line contour. Measurements will be taken three times and the mean of these three values will be considered.

**Table 1. Collecting Basic Clinical Data:**

Age (years) Mean + SD	Group 1 Autograft (control)	Group 2 PMMA	Group 3 Ti	Group 4 PMMA Bone cement
Age (years)/ sex				
Operation time (min)				
Operative blood loss (ml)				

After collection of all the data the clinical outcome will be evaluated in terms of the following parameters:

**Intraoperatively:** Intraoperative blood loss, operating time and surgical complications (intraoperative).

**Postoperatively:** Infection or any complications, fit and contour of the prosthesis.

Thus the obtained data will be tabulated for further statistical analysis. Data will be analyzed using statistical methods.

**Statistical analysis:** Descriptive statistics and frequency distribution test will be done to record the demographic details.

One way ANOVA test is performed for intergroup comparison, and paired t test for intra group comparison at different time intervals.

Chi square test for determining the association between different variables post operatively.

## RESULTS:

Results would be aimed at determining that whether PMMA Bone cement is an equally effective prosthetic material as compared to PMMA and Ti in terms of intra operative and post-operative clinical outcome for Cranioplasty in traumatic brain injury patients as an alternative to autogenous bone graft.

## DISCUSSION:

Intracranial disorders may occur due to several reasons among them head injuries, cerebral tumours infections and ischemia are the common causes. Treatment of intracranial disorders may include decompressive craniotomy followed by reconstruction. Once the cranial bone flap is removed, it should be reconstructed for restoring the integration of the skull, providing adequate biological and mechanical protection of the brain tissues lying underneath skull, and to maintain normal intracranial pressure, hence consequently re-establishing cerebrospinal fluid dynamics and cerebral blood flow. It carries a noticeable importance for preventing the consequences of psychological issues and deformed aesthetic appearance.<sup>7</sup> Polymethylmethacrylate is a mouldable acrylic resin and it is as strong as natural bone tissue, so it can provide adequate protection. Hence this material is very much useful in Cranioplasty and that has been established from long back. This material is stable, not affected by the temperature of body, tissue compatible, nonconductive of heat and allows easy placement and modification along with being cost effective. Biocompatibility of PMMA is also very good. G.H Vince et. al. in 2018<sup>11</sup> found in their study that no marked difference in the overall rate of complication among the groups of patients who underwent the procedure with autologous bone graft versus free-hand modelled substitution of acrylic.

Lee.S. et. al.<sup>10</sup> concluded in their studies that when an autologous bone graft is not available, the CAD/ CAM PMMA prosthesis can be an excellent choice of treatment. Titanium on the other hand is relatively radiolucent, nonferromagnetic, and non-paramagnetic. On a comparative note, titanium possesses a low density, minimum rate of corrosion, and modulus of elasticity equal to that of bone.<sup>11,12</sup> Bone cements is available in two-component system namely powder consisting of Pre-polymerized forms and liquid which comprises monomer, inhibitors, and stabilizers. When mixed in proportions the viscosity changes from a luting or liquid to a rubbery dough and can be moulded and applied onto the prosthesis intra-operatively onto the plastic /prosthesis- bone junction. The material hardens after the setting time and has to be manipulated quickly. The exothermic reaction takes place and heat dissipates therefore to minimize the effect the bone cement layer should not be exceeding more than 5mm. these synthetic compounds tends to undergo reabsorption and replaced by natural bone later on.<sup>13,14</sup> Related studies on brain injury investigations<sup>15,16</sup> and prosthetic rehabilitation of orofacial structures<sup>17,18</sup> were reviewed.

## **CONCLUSION:**

This study would help in knowing the feasibility of using PMMA bone cement as a Cranioplasty material and will evaluate the clinical outcome of PMMA, Ti and PMMA bone The current study will help in identifying whether PMMA bone cement will be as effective as the other widely used material ( PMMA, TI) for Cranioplasty. Further prospective studies with larger sample size and longer follow up period is required to evaluate the affectivity of the material.

## **Ethical Approval:**

As per international standard or university standard ethical approval has been collected and preserved by the authors.

## **REFERENCES:**

1. Piazza Matthew, Grady M. Sean, Cranioplasty, Neurosurg Clin N Am 28 (2017) 257–265
2. Sophie E.C.M. Van De Vijfeijken Et Al. Autologous Bone Is Inferior to Alloplastic Cranioplasties: Safety of Autograft and Allograft Materials for Cranioplasties, a Systematic Review , World Neurosurgery 117: 2018, 443-452
3. Kharade Pankaj, Dholam Kanchan, Gorakh Ahire, A technique for fabrication of cranial prostheses using high-temperature vulcanizing silicone material, J Prosthet Dent
4. Iwama T, Yamada J, Imai S, Shinoda J, Funakoshi T, Sakai N. The use of frozen autogenous bone flaps in delayed cranioplasty revisited. Neurosurgery. 2003;52:591-596 [discussion: 595e 596].
5. Corliss B, Gooldy T, Vaziri S, Kubilis P, Murad G, Fargen K. Complications after in vivo and ex vivo autologous bone flap storage for cranioplasty: a comparative analysis of the literature. World Neurosurg, 2016;96:510-515.
6. Malcolm JG, Rindler RS, Chu JK, Grossberg JA, Pradilla G, Ahmad FU. Complications following cranioplasty and relationship to timing: a systematic review and meta-analysis. J Clin Neurosci. 2016;33:39-51.

7. Zanutti Bruno, Zingaretti Nicola, Verlicchi y Angela, Robiony Massimo Z, Alfieri Alex, Parodi Pier Camillo, Cranioplasty: Review of Materials (J Craniofac Surg 2016;27: 2061–2072)
8. Vaishya Raju , Chauhan Mayank, Vaish Abhishek; Bone Cement, Journal of clinical orthopedics and trauma, 2013(4):157-163
9. Lee C Sai, Chieh-Tsai Wu, Lee Shih-Tseng, Chen Po-Jen; Cranioplasty using polymethyl methacrylate prostheses, Journal of Clinical Neuroscience 16 (2009) 56–63
10. Vince H.C, Comparison between autologous bone grafts and acrylic (PMMA) implants – A retrospective analysis of 286 cranioplasty procedures, J Clin Neurosci (2018)
11. Prolo DJ, Oklund SA. The use of bone grafts and alloplastic materials in cranioplasty. Clin Orthopedics and Related Research. 1991;(268):270–278.
12. Joffe J M, Aghabigi B, Davies E. H., Harris M., A retrospective study of 66 titanium cranioplasties; British Journal of Oral and Maxillofacial Surgery: 1993(31) 144-148
13. Havelin LI, Espehaug B, Vollset SE, EngesAeter LB. The effect of the type of cement on early revision of Charnley total hip prostheses. A review of eight thousand five hundred and seventy-nine primary arthroplasties from the Norwegian Arthroplasty Register. The Journal of bone and joint surgery. American volume. 1995 Oct;77(10):1543-50.
14. Pisulkar S et al. Encasing the Encephalon: Enhancing Psychosocial Rehabilitation ;Int J Cur Res Rev 2020;12:14
15. Sandhu, G.S., and H.R. Nagrale. “Computed Tomography Evaluation of Brain in Chronic Alcoholics.” Journal of Neurosciences in Rural Practice 11, no. 1 (2020): 63–71. <https://doi.org/10.1055/s-0039-1700610>.
16. Gupta, P.P., A.M. Dhok, S.T. Shaikh, A.S. Patil, D. Gupta, and N.N. Jagdhane. “Computed Tomography Evaluation of Craniovertebral Junction in Asymptomatic Central Rural Indian Population.” Journal of Neurosciences in Rural Practice 11, no. 3 (2020): 442–47. <https://doi.org/10.1055/s-0040-1712719>.
17. Nimonkar, S., V.M. Belkhode, S. Sathe, and A. Borle. “Prosthetic Rehabilitation for Hemimaxillectomy.” Journal of Datta Meghe Institute of Medical Sciences University 14, no. 2 (2019): 99–102. [https://doi.org/10.4103/jdmimsu.jdmimsu\\_40\\_19](https://doi.org/10.4103/jdmimsu.jdmimsu_40_19).
18. Pisulkar, S., C. Dahihandekar, H. Rajpurohit, and R. Mistry. “Prosthetic Rehabilitation of Orbital Defect Owing to Surgical Management of Rhabdomyosarcoma.” Journal of Datta Meghe Institute of Medical Sciences University 15, no. 2 (2020): 312–16. [https://doi.org/10.4103/jdmimsu.jdmimsu\\_118\\_20](https://doi.org/10.4103/jdmimsu.jdmimsu_118_20).