

Comparative Assessment of Post-operative Sequelae Following Surgical Removal of Mandibular Third Molar With And Without Extra-Oral Application of Kinesiologic Tape.

Abstract:

Background -The transalveolar extraction of impacted mandibular third molars creates a huge level of injury to the delicate tissues of the oral cavity, which can initiate significant inflammatory reaction. Amongst some postoperative sequelae of third molar surgeries- pain, trismus and facial oedema are the most common. Treating with taping therapy has shown acceptable outcomes in reducing pain and in managing post-operative muscle spasm.

Objectives - The motive behind this research is to compare post-operative pain, swelling and trismus following third molar surgery in both test and control groups.

Methodology - The research will be a prospective randomized control split-mouth non-blinded clinical study model to assess the impact of the Kinesiology Tape (KT) on post-operative sequelae following removal of mandibular third molar surgically. With the cumulative 15 patients to be allocated for operating bilaterally involved impacted mandibular third molar. The study will be done under two groups, Group A – Test group (KT) one side of patient's face, subjected to beige tape application. Group B – Control group (No KT) other side of patient's face, will be the controlled group without application of KT. Each patient will undergo 2 operative surgeries at 2 week-interval conducted by the same surgeon. Immediately after extraction extra-oral application of KT will be done for test group.

Expected Results - The use of kinesiologic tape will be effective in improvement of post-operative discomfort of the patient in the conditions of reduction of swelling, pain and trismus.

Conclusion- As kinesiologic taping originates from sports medicine, currently there are very limited evidence-based scientific studies for KT application for treatment of post-operative edema in head and neck surgeries. This study will help to evaluate the use of KT enabling patients to have a restful time after operation leading them to get a better quality of life.

Keywords - Kinesiologic Tape, Third Molar, Taping

Introduction:

Third molar surgical procedures are the most well-known procedures carried out in oral surgery that have varying complications and sequelae in preoperative, perioperative and post-operative phases.

The transalveolar extraction of impacted mandibular third molars create a huge level of injury to the delicate tissues of the oral cavity, which can initiate significant inflammatory reaction.^[1] As a consequence of this, patient may experience several problems counting pain, facial oedema, haemorrhage, alveolar osteitis, neural paraesthesia, and muscle spasm causing restricted mouth opening in the post-operative period. These sequelae are more pronounced in some patients producing varying degrees of discomfort to them.

Amongst these postoperative sequelae of third molar surgeries- pain, trismus and facial oedema are the most common. Not only are they inevitable but, also a matter of concern for both, the patient and the surgeon. Hence extensive research has been done in terms of post-operative management of third molar surgeries, especially pertaining to trismus, swelling and pain. Pharmacologic manipulation has also worked to alter the inflammatory response.^[1] The optimum level of pain reaches within 3-5 h after the resolution of anaesthetic effect, and is present for 2-3 days, and then slowly fades by 7th day. On the other hand, swelling reach to its upper limit within 12-48 hours and fades by 5-7 days. Conversely, trismus continues until the pain and the inflammation diminishes.^[2] Facial oedema has such degree variation that it affects patient's capability to cooperate with others, as well as to restart basic and instrumental activities of everyday living, primarily in first 3 post-operative days.^[3]

Taping treatment has shown acceptable outcomes in managing post-operative muscle spasm and in reducing pain. In 1970, Dr. Kase invented Kinesio taping (KT) which is an 'elastic-therapeutic tape' particularly used in variety of sport and health condition including post-operative rehabilitation in oral and maxillofacial surgery. The taping begins started to be used in sports and musculoskeletal conditions with the focus to assist the injured delicate tissues (muscles and joints) assisting with diminishing pain. Some researches has concluded that the KT also controls the circulation of the blood and lymphatic system and also to assist in cleansing the congestions of haemorrhagic or lymphatic fluid by impacting the skin and fluids to move according to topical application of the tape, towards the vicinity of inferior pressure from areas of superior pressure.^[4,5]

Recently though, KT has gained some attention in this context. Some of the recent research have advocated the usage of KT is very useful and impactful management of postoperative complications of maxillofacial surgery. Even the hypothesis for effectiveness of KT seems weaker in some researches, recent ones have provided the evidence but it opens larger area to check the effectiveness of KT in post-operative oral surgery rehabilitation.

Our motive behind this research is to find whether theoretically based findings about KT can be implemented clinically as well.^[6]

STUDY DESIGN:

The research will be a prospective randomized control split-mouth non-blinded clinical study model to assess the impact of the KT on post-operative sequelae after surgical removal of mandibular third molar. With the cumulative 15 patients to be allocated for removal of bilateral involved mandibular third molar in near similar difficulty index 4-5 according to Pederson scale, justifying the extraction under local anaesthesia. The study will be done under two groups, Group A – Test group (KT) one side of patient's face, subjected to beige tape application. Group B – Control group (No KT) other side of patient's face, will be the controlled group without application of KT.

SAMPLE SETTING

“It will be a hospital based experimental study in which the patient will be allocated from the Out-Patient Department (OPD) of the “Department of oral and maxillofacial surgery, Sharad Pawar Dental College, Sawangi”, Wardha’.

STUDY DURATION: November 2020- November 2022

SAMPLE SIZE: 15 required in each groups

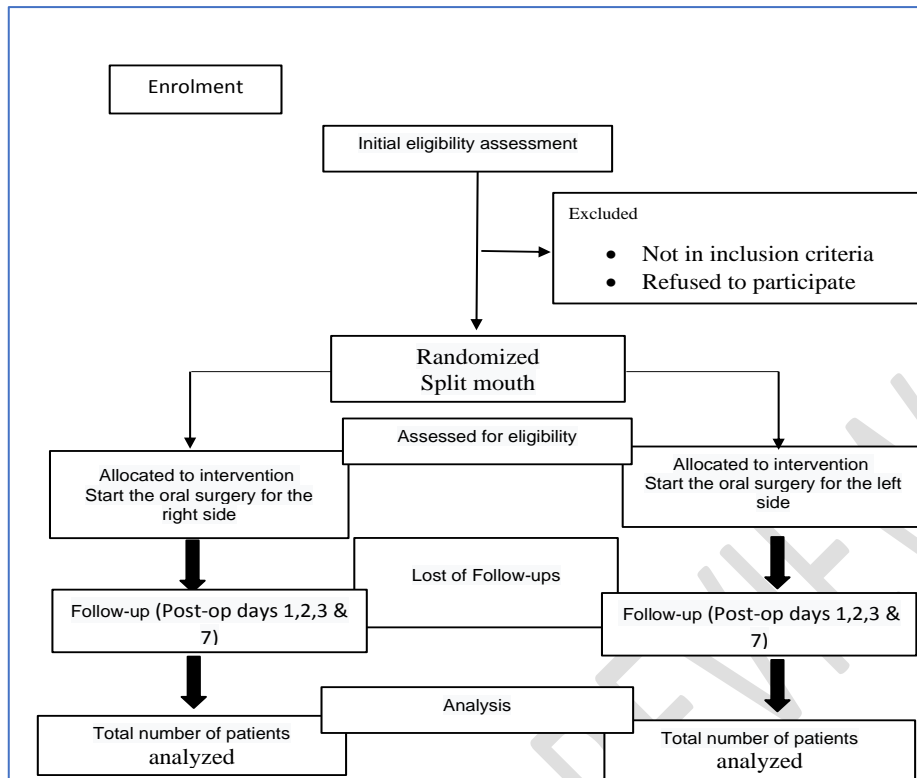


Fig. 1. Study protocol

CRITERIA FOR INCLUSION:

1. Age 18 years and above.
2. Impacted mandibular third molar indicated for extraction.
3. A medical history free of any systemic or pathological condition.
4. A medical history free of any pharmacological therapy able to introduce variables into the experiment.

CRITERIA FOR EXCLUSION:

1. Patients not willing to be a part of the study.
2. Patients with uncontrolled systemic diseases.
3. Patients with incidence of skin lesions.
4. Patients reluctant to shave facial hair (for men).

METHODOLOGY:

- Informed consent will be obtained from all patients before inclusion in the study. (Annexure- I)

- **Patient selection and preparation:**

The present study will be performed on patients with the age 18 years and above with impacted lower third molars who will be undergoing transalveolar extraction with respect to lower third molars in the department.

All the patients will be informed about the study and their written consent to participate in the study will be obtained. Routine analysis of blood will be done to rule out any systemic disease. Case history of the patient will be recorded.

- **Surgical procedure:**

Each patient will undergo 2 operative surgeries by the same oral surgeon at 2 week-interval. Under standard surgical protocol, surgery will be performed in aseptic conditions. Local anaesthesia will be given on the route of inferior alveolar nerve, lingual & long buccal nerve block injection using 2% lignocaine with 1:200000 epinephrine.

The incision will be given using surgical scalpel (No.15 blade) and a mucoperiosteal flap will be raised. Osteotomy will be performed using round & fissured burs with sterile saline irrigation. Crown or root sectioning will be done as per requirement. The tooth will be extracted using an elevator or dental forceps. The socket will be curetted and irregular bone borders of alveolus will be smoothed. Repositioning of flap will be done & sutured using 3-0 silk.

➤ **Application of Kinesio Tape:**

Immediately after extraction application of KT application will be done for test group. The skin should be cleaned, shaved if needed, and any remaining dampness and oil will be taken out. The KT with the size of 5 cm × 5 m will be used for the study. Tape length will be modified for every patient, differentiated by the distance (in the extended neck position) between the clavicle and the tragus-commissure line. The KT will be applied into 5 equal strips with approx^[6]. 1cm of width, with the base of these strips placed just above the supraclavicular nodes (the target area for drainage). To activate the acrylic adhesive, the tape is gently rubbed^[7]. After tape application, skin folds will be visible as the head is placed in normal position. The tape will be kept for 7 days in each patient.

The patients will be evaluated on the following parameters -

• **PAIN:**

Pain to be measured postoperatively and consequently from first to third day and on the 7th day as T1, T2, T3 and T7 respectively using gold standard Visual Analogue Scale (VAS) scale.^[8] Patients will be asked to rate their pain these 4 days at the same time each day and submit it on the 7th day.

• **SWELLING:**

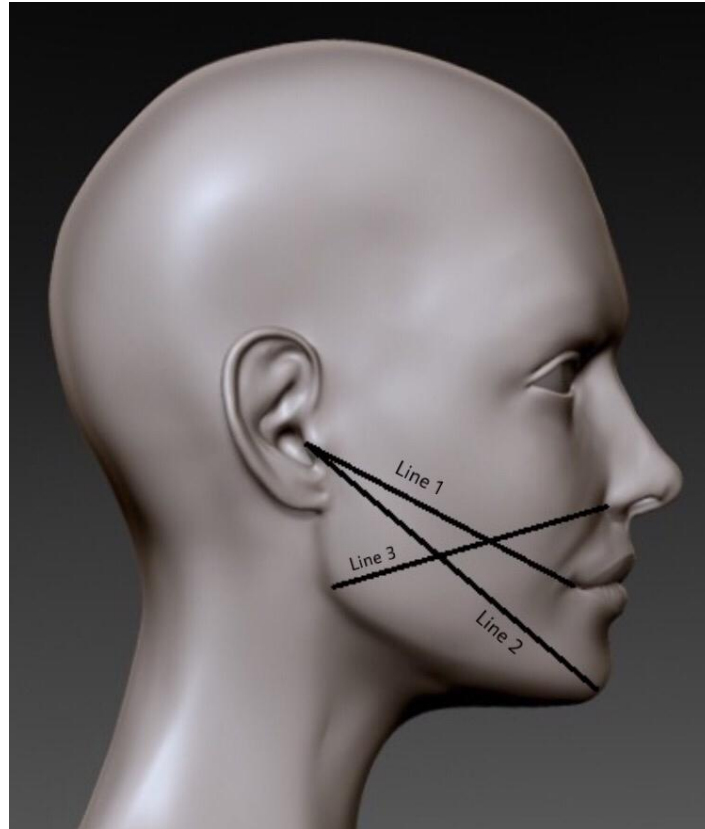
Swelling of the face to be measured by measuring tape on post-operative days, first, second, third and seventh day. The measurements will be taken in following three lines^[9] mentioned in the diagram below:

Line 1- the most posterior point of the tragus to the most lateral point of the lip commissure,

Line 2- the most posterior point of the tragus to the soft tissue pogonion point.

Line 3- the ala of the nose to the angle of the mandible,

Figure 2. Measurement of swelling of face



- **TRISMUS :**

Maximal mouth opening (maximum interincisal distance (IID)) will be measured post-operatively on first, second, third and seventh days by using Vernier callipers.

Methods: Assignment of interventions (for controlled trials):

- **Allocation:** Study population would be randomized equally (n=15) into two different groups (Test group & control group) using computer generated table of random numbers.
- **Implementation:** Independent observer
- **Blinding (masking):** non blinding study.

Data collection, management, and analysis methods:

Data collection methods: Patients reporting to OPD of “Oral and Maxillofacial Surgery department, Sharad Pawar Dental College”.

Ethics and dissemination:

The study is approved from institutional ethical committee “Sharad Pawar Dental College” “[Ref. No- DMIMS(DU)/IEC/2020-21/9418].”

Declaration: The research will be conducted under the Helsinki declaration 2013 and after approval by the guidelines prescribed by IEC of DMIMS DU.

Expected Results:

The use of kinesiologic tape will be effective in improvement of post-operative discomfort of the patient in the conditions of reduction of swelling, pain and trismus.

Discussion:

In a study by **Ana Carolina Heras et al. (2019)**, patients (5 males and 8 females) underwent extractions of the two lower third molars simultaneously. Kinesio tape was applied on one side of patients's face (test group - KT), immediately after surgery. The other side of the face was used as control (No KT) instead of KT application. The assessment of edema and pain was done using the visual analog scale (VAS) and on the Todorović-Marković method, respectively, one before surgery and other immediately after surgery, and on 2nd and 7th postoperative days. Scheirer-Ray-Hare test was used for statistical analysis of the results. The study showed edema (on 2nd and 5th day after extraction) and intensity of pain (on 1st, 2nd and 5th day after extraction) was low on the KT side ($p < 0.05$). In addition, swelling and pain diminished on the KT side by 5th day of extraction ($p < 0.05$). Introduction of KT therapy treatment in this study was successful to reduce the swelling and postoperative pain of the patients undergoing oral surgery. According to Ristow et al. (2013, 2014, 2014) and Tozzy et al. (2016), patients subjected to taping therapy reduced the edema by 60%, after the second postoperative day.^[8,9]

In a case report by **Sarah Handerson et al.**, a female patient (26 yrs old) underwent elective surgical extraction of her lower third molar. Kinesio tape application was done to the patient's lower mandible and masseter region for a post-surgical lymphatic drainage, results showed a major decrease in pain, swelling and trismus. The healing time was also reduced to 5 days from 10 days. It suggests that taping is potentially as an efficient treatment following surgical removal of a wisdom teeth.^[10] Related studies on third molars evaluation^[11-13] and complications related to surgical removal^[14-15] were reviewed.

Conclusion:

As kinesiologic taping originates from sports medicine, currently there are very limited evidence-based scientific studies for exploring KT application for treatment of post-operative edema in head and neck surgeries. This study will help to examine and assess the use of KT enabling patients to have a comfortable time after operation and helps them getting better quality of life.^[9] It may also reduce postoperative need for NSAID and analgesics, thus reducing the side effects associated with these drugs.

References:

1. Kafa N, Citaker S, Omeroglu S, Peker T, Coskun N, Diker S. Effects of kinesiologic taping on epidermal-dermal distance, pain, edema and inflammation after experimentally induced soft tissue trauma. *Physiother Theory Pract.* 2015;31(8):556–61.
2. Gupta A., Rajanikanth K., Bhola N. Comparison of effect of bromelain and aceclofenac on post-operative sequelae following surgical removal of impacted mandibular third molar – A clinical trial *European Journal of Molecular & Clinical Medicine*, 2020, Volume 7, Issue 2, Pages 2060-2069

3. Patil C., Jadhav A., K R., Bhola N., Borle R.M., Mishra A. Piezosurgery vs bur in impacted mandibular third molar surgery: Evaluation of postoperative sequelae. *J Oral Biol Craniofac Res.* 2019 Jul-Sep; 9(3): 259–262.
4. Kase K, Wallis J, Kase T. *Clinical therapeutic application of the kinesiio taping method.* Tokyo, Japan: Ken Ikai Co Ltd; 2003.
5. Mohammed IA., Delemi ZH. Kinesiology tape in comparison with oral Diclofenac sodium in reducing swelling after surgical removal of lower wisdom teeth. *Al-Rafidain Dent J.* 2019;19(1):90-97.
6. Aysenur Genc, Sirmahan Cakarer1 & Basak Keskin Yalcin1 & Beril Berivan Kilic2 & Sabri Cemil Isler1 & Cengizhan Keskin1(2018) A comparative study of surgical drain placement and the use of kinesiologic tape to reduce postoperative morbidity after third molar surgery <https://doi.org/10.1007/s00784-018-2442-x>
7. Özgür G, Murat U, Hilal ÖG, Nergiz Y, COMPARISON OF DIFFERENT KINESIO TAPING TECHNIQUES FOLLOWING THIRD MOLAR SURGERY, *Journal of Oral and Maxillofacial Surgery* (2020) doi:<https://doi.org/10.1016/j.joms.2019.12.026>
8. Shim JY, Lee HR, Lee DC. The use of elastic adhesive tape to promote lymphatic flow in the rabbit hind leg. *Yonsei Med J.* 2003;44:1045–52
9. Tristão da Rocha Heras AC, Streling de Oliveira DM, Guskuma MH, Carolina de Araújo M, Fernandes KBP, Alexandre da Silva Junior R, Andraus RAC, Maia LP, Freire Fernandes TM, Kinesio Taping use to reduce pain and edema after third molar extraction surgery: a randomized controlled split-mouth study, *Journal of Cranio-Maxillofacial Surgery*, <https://doi.org/10.1016/j.jcms.2019.12.003>.
10. Henderson S, Alexanders J, Shaw T (2016) The Clinical Effectiveness of Using Kinesio Tape Following Wisdom Teeth Extraction. *Physiother Rehabil* 1: 103. doi:10.4172/2573-0312.1000103.
11. Ristow O, Hohlweg-MajertB, Kehl V, Koerdt S, HahnefeldL, Pautke C. Does elastic therapeutic tape reduce postoperative swelling, pain, and trismus after open reduction and internal fixation of mandibular fractures? *J Oral Maxillofac Surg.* 2013;71(8):1387-96.
12. Reddy, K.V., A. Jadhav, N. Bhola, A. Mishra, and P. Dakshinkar. “Is 0.75% Ropivacaine More Efficacious than 2% Lignocaine with 1:80,000 Epinephrine for IANB in Surgical Extraction of Impacted Lower Third Molar?” *Oral and Maxillofacial Surgery* 23, no. 2 (2019): 225–31. <https://doi.org/10.1007/s10006-019-00779-w>.
13. Khan, Imran, Rajshekhar Halli, Pushkar Gadre, and Kiran S. Gadre. “Correlation of Panoramic Radiographs and Spiral CT Scan in the Preoperative Assessment of Intimacy of the Inferior Alveolar Canal to Impacted Mandibular Third Molars.” *JOURNAL OF CRANIOFACIAL SURGERY* 22, no. 2 (March 2011): 566–70. <https://doi.org/10.1097/SCS.0b013e3182077ac4>.
14. Kasatwar, Akash, Nitin Bhola, Rajiv Borle, and K. Rajanikanth. “Displacement of Lower Third Molar into the Lateral Pharyngeal Space in a Case of Mandibular Angle Fracture: An Unusual Complication.” *CONTEMPORARY CLINICAL DENTISTRY* 7, no. 2 (June 2016): 229–31. <https://doi.org/10.4103/0976-237X.183046>.
15. Durge, Khushboo Jeevan, Pavan Bajaj, and Diksha Agrawal. “Distal Molar Surgery.” *JOURNAL OF EVOLUTION OF MEDICAL AND DENTAL SCIENCES-JEMDS* 9, no. 44 (November 2, 2020): 3335–38. <https://doi.org/10.14260/jemds/2020/732>.