

Study Protocol

Comparative Efficacy of knotless (polyglyconate) over conventional (poliglecaprone 25) suture as a wound closure material in mandibular impacted third molar surgery (MI3M).

Abstract:

Background- The third molar surgery is the most commonly practised minor oral surgery in dental clinic. Post-operatively the patient suffers from pain, swelling and trismus due to tissue injury during surgical procedure. After extraction of third molar, conventional sutures are used for primary closure of the wound. During the procedure the clinician get difficulties intra-orally related to knot placement, limitation of instrument accessibility and knot slippage. Barbed sutures are the knotless suture which help in adhering the tissue while suturing.

Objectives- The primary focus of the study is to evaluate the efficacy of knotless suture as a wound closure agent in terms of post-operative pain, swelling, trismus, degree of wound healing and quality of life over the conventional one.

Methodology- Two groups (study & control) with 20 individuals as subjects are considered for the study model. Systemically healthy individual with presence of at least one mesioangular or horizontal or vertically oriented mandibular impacted third molar(MI3M) with similar difficulty index, depth of, and relationship with ramus will be included in the study sample. Wound closure would be achieved by using 3-0 knotless suture using continuous sub-cuticular suturing technique for the study group and 3-0 conventional suture using simple interrupted suturing technique for control group respectively. Post-operatively measurement of pain, swelling, trismus, degree of wound healing and quality of life will be done.

Expected Results- Knotless suture for closure of wound after MI3M surgery will be effective in reducing post-operative pain, edema and trismus and also helpful in better wound healing and improve quality of life.

Conclusion- Use of knotless barbed suture after surgical removal of lower impacted third molar to simplify intra-oral suturing technique and to reduce post-operative pain, swelling, trismus and knot related complications would be a familiar and effective way which could be executed by a dental practitioner himself.

Keywords- Knotless suture, Third Molar, Barbed suture

Introduction:

The surgical removal of the impacted third molar is the most frequent minor oral surgical procedure done in a dental clinics^[1] and it is frequently attended by post-operative distressing complications such as pain, edema and trismus. These arise secondarily to tissue

injury during surgical manipulation, tissue re-approximation and suturing. The cascade of release of inflammatory mediators and tissue reaction follow leading to certain hemodynamic changes, producing exudates that result in post-operative pain, limitation of activities for few days such as ability to chew food, ability to speak, swelling and trismus^[2]. These combinedly affect the post-operative quality of life(QOL)^[3,4].

Literature is replete in modalities or techniques to limit these inflammatory responses. These include different techniques such as use of least traumatic surgical techniques, use of drugs like local anesthesia^[5] with or without additives, anti-inflammatory and analgesics, use of physical therapeutic methods and the technique employed for closure of the wound. Conventionally, the closure of wounds are achieved by placing the sutures across the edges of the wound, however, with recent developments in materials and devices used for closure, a paradigm shift in wound closure techniques has been observed^[6].

Primary closure of the surgical wound can be performed with conventional sutures or using suture less technique such as tissue glues^[7]. Conventional suturing can be done by placing either a single suture or “multiple sutures”. Using minimal sutures with smaller diameter is usually preferred to avoid multiple tissue puncture, tissue manipulation leading to significant inflammatory response^[8]. Conventional suturing demands securing the suturing material with knots and is posed with difficulties such as limited access, challenge in instrumentation and securing the knot. Intra-oral clinical challenges related to knot placement such as, complexity in securing the first tie and accomplishing the desirable approximation of the tissues in areas with limited accessibility and difficult instrumentation, tendency for knot slippage compromise wound closure. Furthermore, suture knot serves as a foci for entrapment of food debris and bacterial colonisation leading to tissue irritation. Knotless suture is an advanced suture device which may be an superior option to eradicate the aforementioned drawbacks of conventional suturing. It is categorically designed with barbs angled in direction away from the needle over a monofilament suture. Knotless sutures have barbs placed over the full length of the suture to aid in engaging the tissues while suturing. The margins of the wound thus opposed, obviate the need of knots to secure the sutures. Unidirectional Barbed sutures incorporates barbs in single direction, whilst, bidirectional barbed sutures exhibit needles at opposite ends with a change in direction of the barbs at the mid-length of the suture material.

US patent was granted for barbed sutures by Dr John Alcamo, a general surgeon, in 1964 and later on received FDA clearance for the use of barbed suture to other allied surgery specialities. “Knotless suture device have been into practice with consistent superior results in the domains of bariatric surgery (Ferrer-Márquez M., et al 2016), abdominoplasty (Warner JP, Gutowski KA., 2009), facial rejuvenation procedures (Rachel JD., et al 2010), arthrotomy (Nett M., 2011), laparoscopic myomectomy (Iavazzo C., et al 2015), partial nephrectomy (Metcalf M., et al 2015), and in other minimally invasive procedures. The maiden report of successful use of knotless suture in oral cavity was reported by Ganesh SK., et al 2015^[9]”. The potential merits of this suture device have been reported as reducing the time of wound closure, additional strength to the wound due to barbs with maintenance of uniform tension throughout the approximated tissues and better eversion of tissues during re-approximation of flaps.

In maxillofacial trauma knotless suture are being used for intra oral wound closure^[9]. Recently, Ramkumar Ceyar.K.A, et al carried out a study comparing the efficacy of knotless suture and conventional suture in closure of IM3M surgical wound in a split mouth randomized controlled trial. The results showed that Knotless suture was found to be effective for mucosal wound closure as it cuts down the suturing time, promotes effectual

closure of wound and lowers the complications related to knot. Knotless suture simplifies the suturing technique, reduces the intra-operative time and provides good tissue approximation fostering wound healing^[10].

The utility of the suture device in third molar surgical wound or any other oral wound, evidence is limited and is a matter of investigation. Therefore, this study is deliberated to assess the practical efficacy of the knotless suture for wound closure in MI3M surgery with the hypothesis that the using a barbed suture would help reduce post-operative pain, edema and trismus.

Materials and Methods:

Study Design: Prospective, Randomized control, double blind, and parallel arm study model

Eligibility criteria:

Inclusion Criteria:

1. Subjects with ASA Group I status
2. Systemically healthy subjects between 18 to 35 years.
3. Presence of unilaterally impacted mesioangular/vertical/horizontal mandibular third molar having class II position B according to Pell and Gregory classification.
4. Individuals with fair oral hygiene with plaque index score less than 2(Silness and Loe 1964 Plaque Index)
5. Subjects with adequate mouth opening (≥ 30 mm).

Exclusion criteria:

1. The subject having systemic diseases such as HTN, DM, blood dyscrasias, immune-compromised status.
2. Pregnant and breast feeding mothers
3. Use of antibiotics, anti-inflammatory agents 48 hours prior to the scheduled inclusion in the study
4. Presence of any local infection like pericoronitis
5. Presence of any chronic facial pain on the side of intervention.
6. Radiological involvement to impacted third molar tooth with IAN
7. Subjects who are chronic smokers
8. Female subjects on oral contraceptives
9. Subjects with poor oral hygiene
10. Subjects with trismus.

Post-recruitment Exclusion Criteria-

1. Procedure lasting more than 60 minutes
2. Subjects not complying with study protocol
3. Subjects lost to follow up
4. Subjects with post-operative inferior alveolar nerve injury.

Statistical Analysis :

“Statistical analysis will be done by using descriptive and inferential statistics using chi-square test, Student’s paired and unpaired t test, software used in the analysis will be

SPSS 24.0 version and Graph Pad Prism 7.0 version and $p < 0.05$ will be considered as level of significance”.

Methodology:

The study design would be a prospective randomized, controlled, double-blind, parallel arm study model complying with the CONSORT^[11] flow diagram (Annexure I) for randomized control trials, evaluating 46 systemically healthy subjects with the presence of at least one mesioangular or horizontal or vertically oriented MI3M with similar difficulty index, depth of, and relationship with ramus will be included in the study sample. A detailed clinical evaluation using a proforma tailor made to suit the needs of the study will be performed. All the subjects recruited in the study will be explained in detail about the study protocol, the material used, the possible adverse effects of the interventions and a written informed consent will be obtained.

The preoperative measurements such as measurement of facial swelling using pre-determined points^[12] and maximum inter-incisal mouth opening would be done using calibrated ruler by an independent observer and compared to the values measured on POD 2nd and 7th. Study population would be randomized equally (n=20) into two different groups (group S & group C) using computer generated table of random numbers.

The neural blockade of the inferior alveolar nerve, lingual nerve and the buccal nerve will be performed with 2.5 ml solution of 2% Lignocaine mixed with 1:80,000 Adrenaline using the classical technique. Following subjective and objective confirmation of successful neural blockade, the surgical removal of impacted lower third molars will be done by reflecting the buccal mucoperiosteal flap and osteotomy with odontotomy using bur and handpiece. Following tooth removal, curettage of the socket and irrigation will be done and after achieving the haemostasis, wound closure would be achieved by using 3-0 knotless suture (polyglyconate) using continuous sub-cuticular suturing technique for the study group and 3-0 conventional suture (monocryl) using simple interrupted suturing technique for control group respectively.

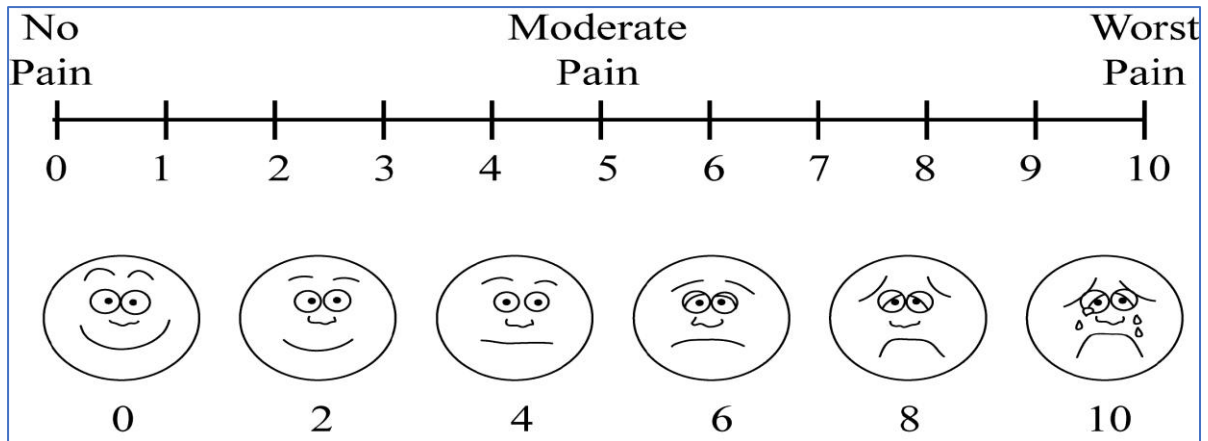
Two or more interrupted sutures will be secured across the incision line, with one suture just distal to the second molar and the other placed equi-distantly to close the incision line in the conventional suture group secured by using surgeon's knot. For the study group, the suture will be activated by holding the ends of suture material and pulling them away from each other. By doing this the barbs gets engaged deeper into tissue and will approximate the wound margin in precise manner. The suture should be cut in a closer proximity to the tissue with no exposure of the suture material intra-orally. Postoperatively, all the subjects would be prescribed cap amoxicillin 500 mg 8 hourly and tab. paracetamol 650 mg 8 hourly for next five days.

Outcomes:

Measurement of post-operative intensity of pain

VAS (A 10 point visual analog scale) will be used to subjectively assess the pain strength (quality of pain) where point 1 on the VAS designated slight discomfort and point 10 indicate intolerable pain which will be recorded on the second and seventh post-operative day. See Fig. 1

Fig.1: Pain Scale



The quantitative evaluation of pain would be done by recording the number of analgesics(paracetamol 650 mg) by the subjects post-operatively for 5 consecutive days. Subjects requiring more than three analgesic dose per day would suggest severe level of unbearable pain post-operatively.

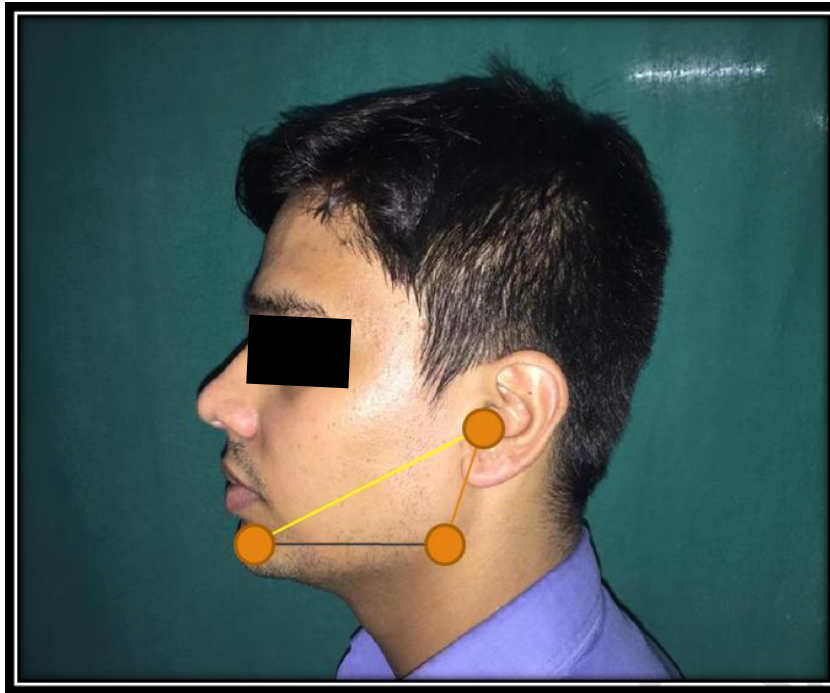
Measurement of post-operative severity of trismus-

For assessment of mouth opening, the maximum inter-incisal opening will be recorded using a vernier caliper. All these measurements would be recorded by an independent observer who will be blinded to the study protocol.

Measurement of post-operative extent of facial swelling-

Facial swelling and mouth opening will be assessed preoperatively before the procedure and compared with the measurements recorded on the second and seventh days postoperatively by an independent observer. Three clinical landmarks will be taken to assess facial swelling: Tragus to menton, menton to angle of mandible and angle of mandible to tragus^[12]. See Fig. 2.

Fig.2: Landmarks for Assessing Facial Swelling



“Measurement of wound healing (Landry’s index)”

On post-operative day 2nd and 7th, wound healing was measured based upon the “Landry’s Wound Healing Index”. The wound healing would be assessed based on tissue colour, response to palpation, presence of granulation tissue, incision margin and suppuration. The scores range from 1 to 5 in a progressive manner such as “(1)very poor, (2)poor, (3)good, (4)very good and (5)excellent wound healing”. See Fig. 3.

Fig.3: Clinical Evaluation Proforma

Very poor	Tissue color: $\geq 50\%$ of gingiva red Response to palpation: Bleeding Granulation tissue: Present Incision margin: Not epithelialized, with loss of epithelium beyond incision margin Suppuration: Present
Poor	Tissue color: $\geq 50\%$ of gingiva red Response to palpation: Bleeding Granulation tissue: Present Incision margin: Not epithelialized, with connective tissue exposed
Good	Tissue colour: $\geq 25\%$ and $< 50\%$ of gingiva red Response to palpation: No bleeding Granulation tissue: None Incision margin: No connective tissue exposed
Very good	Tissue colour: $< 25\%$ of gingiva red Response to palpation: No bleeding Granulation tissue: None Incision margin: No connective tissue exposed
Excellent	Tissue color: All tissues pink Response to palpation: No bleeding Granulation tissue: None Incision margin: No connective tissue exposed

Measurement of suturing time:

Suturing time would be recorded from the beginning of suturing till the time the final surgical knot will be secured or till the activation of knotless suture by an independent observer using digital clock in seconds.

Measurement of pain and physical quality of life using PoSSe Scale:

Post-operative pain, discomfort and the quality of life affected of the subject will be assessed subjectively with the help of PoSSe (Post-operative symptom severity evaluation) scale^[11]. The questionnaire will be explained to the subjects in detail requiring them to select one option which closely describes their status. The PoSSe (Post-operative symptom severity evaluation) scale will be adapted and translated to vernacular language (Marathi and Hindi) for the better understanding, assessment and evaluation by the subjects. At the 7th post-operative day the forms will be given to the subjects and the scores tabulated will be statistically evaluated to calculate the score. These scores represent percentages so that the patient selecting the most severe response would score 100% and the least severe response would score 0%. The scores of the responses to each question will be summed up^[11].

Discussion:

“Sutures are an essential part of the surgical procedure, employed for closure of wound in any anatomical site. They provide the required haemostasis and anatomic tissue approximation in an esthetic manner. Classic suturing techniques and their strength rely completely on the knots placed to secure the suture. However knots present specific clinical problems; knots attract debris. Knot slippage at time of approximation of tissues leads to inadequate wound closure, wound dehiscence etc. The above mentioned reasons make knotless sutures an effective option for intra-oral wound closure”. Ramkumar Ceyar. K. An et al^[11] compared the efficacy of 3-0 knotless barbed suture (polydioxanone) versus 4-0 polyglactin 910 (vicryl) in achieving wound closure following lower third molar surgery. Time to gain the wound healing, hemostasis, post-operative mouth opening, pain and edema were all measured as clinical outcome parameters. Bilateral lower third molar impaction with 25 patients of almost the same difficulty index was registered in the split-mouth study. For the study group wound closing was done with 3-0 knotless suture and for the control group 4-0, vicryl was used following extraction. There was a decrease in pain, edema, and improved mouth opening post-operatively in the study group. In one study given by A.K. Sharma, G.P.T. Doss, E. Panneerselvam, S.K. Ganesh, K.R. VB et al^[10], the potency of knotless wound closure device in intra-mucosal closure of wound for maxillofacial trauma in comparison with the conventional one (vicryl suture) was evaluated. The study constituted 40 patients with isolated mandibular fractures requiring an intra-oral approach for open reduction and internal fixation. In the study group, the closure of the wound was performed using bidirectional knotless suture and in the control group, vicryl was used. The clinical outcome factors witnessed were time taken for wound closure and wound healing using ‘Landry's index’. The study showed that barbed sutures decrease intra-operative time and shorten wound closure in areas of constrained access and it also facilitates superior wound healing preventing complications related to knots. Also Corinne L. Durand^[13] compared knotless sutures with a conventional absorbable suture material for wound closure in intra-oral mucosa. The factors included were time taken for closure of wound and difference in healing at 2nd and 4th weeks postoperatively. All teeth were extracted following which the incisions were approximated with knotless suture using continuous suturing technique on one side and with a conventional one using interrupted suturing technique on the other side. Time taken for suturing for each were recorded which varied for the material used to close the first side. Healing, dehiscence, and other complications were evaluated at 2nd and 4th postoperative week. Dehiscence and

swelling were described as typical postoperative complications, but the differences between the groups were not significant. The study concluded that knotless sutures resulted closure time was faster than conventional sutures with similar healing and complication rates. However further studies in a large scale will be required to compare overall costs of care and to assess uncommon complication that might arise, although none were observed in his small series.

Conclusion:

Use of knotless barbed suture following lower impacted third molar surgery to simplify intra-oral suturing technique and to reduce post-operative pain, swelling, trimus and knot related complications would be a familiar and effective way which could be executed by a dental practitioner himself.

COMPETING INTERESTS DISCLAIMER:

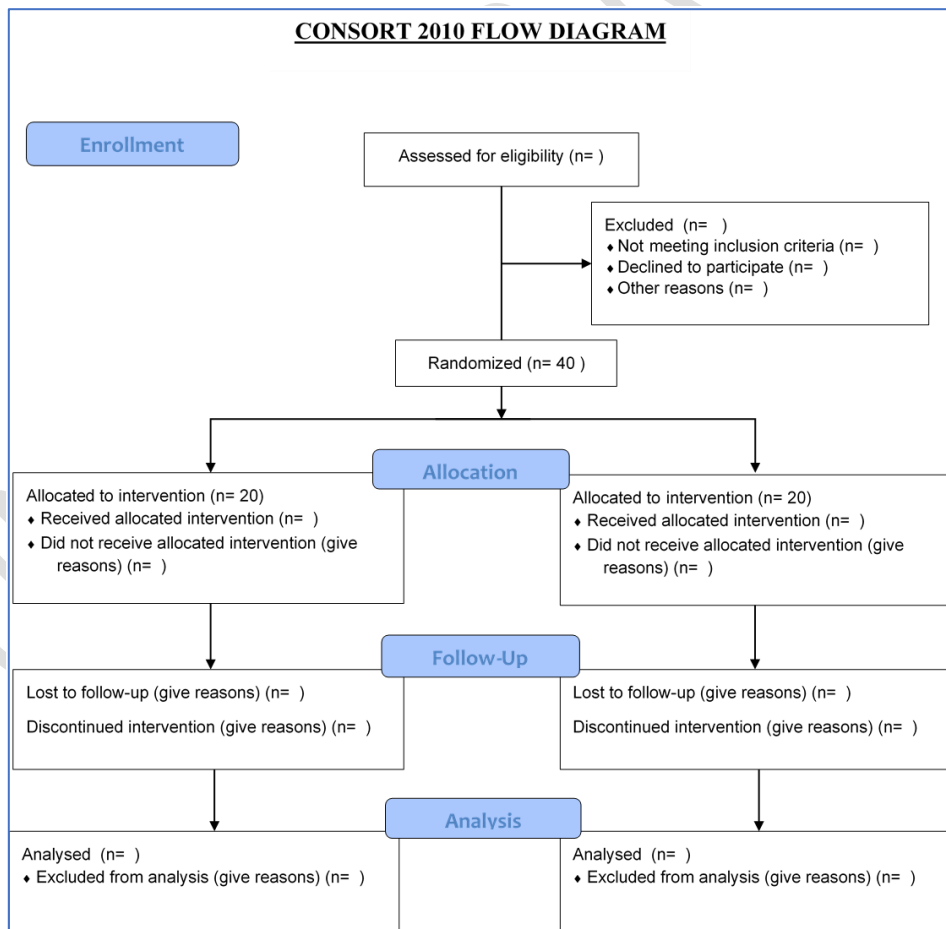
Authors have declared that no competing interests exist. The products used for this research are commonly and predominantly use products in our area of research and country. There is absolutely no conflict of interest between the authors and producers of the products because we do not intend to use these products as an avenue for any litigation but for the advancement of knowledge. Also, the research was not funded by the producing company rather it was funded by personal efforts of the authors.

REFERENCES:

1. Ceyar.K.A R. et al, Effectiveness Of Knotless Suture As A Wound Closure Agent For Impacted Third Molar – A Split Mouth Randomized Controlled Clinical Trial, *Journal of CranioMaxillofacial Surgery*, 2020.
2. John W. Harrison et al, Healing of Surgical Wounds in Oral Mucoperiosteal Tissues, *Journal of endodontics*, Vol. 17, No, 8 August 1991.
3. J.Savin, G.R. Ogden et al, Third Molar Surgery- a preliminary report on aspects affecting quality of life in early postoperative period, *British Journal of Oral and Maxillofacial Surgery*, Vol. 35, Issue 4, August 1997
4. Patil C, Jadhav A, K R, Bhola N, Borle RM, Mishra A. "Piezosurgery vs bur in impacted mandibular third molar surgery: Evaluation of postoperative sequelae". *J Oral Biol Craniofac*. 2019.
5. Reddy KV, Jadhav A, Bhola N, Mishra A, Dakshinkar P. Is 0.75% ropivacaine more efficacious than 2% lignocaine with 1:80,000 epinephrine for IANB in surgical extraction of impacted lower third molar? *Oral Maxillofac Surg*. 2019
6. Oswal S, Borle R, Bhola N, Jadhav A, Surana S, Oswal R. Surgical Staples: A Superior Alternative to Sutures for Skin Closure After Neck Dissection-A Single-Blinded Prospective Randomized Clinical Study. *J Oral Maxillofac Surg*. 2017.
7. Khande, K., Saluja, H. & Mahindra, U. et al, Primary and Secondary Closure of the Surgical Wound After Removal of Impacted Mandibular Third Molars, *Journal of Maxillofacial Oral Surgery*,2011.
8. Pedersen A. et al, Decadronphosphate in the relief of complaints after third molar surgery. A double-blind, controlled trial with bilateral oral surgery. *Internal Journal Oral Surgery*, 1985.
9. Sriraam Kasi Ganesh et al, Knotless suture for wound closure in intra oral surgery - A report of two cases, *Journal of Oral and Maxillofacial Surgery*, 2018.

10. A.K. Sharma, G.P.T. Doss, E. Panneerselvam, S.K. Ganesh, K.R. VB et al, The use of knotless barbed suture for closure of intra-oral incisions for maxillofacial trauma – A randomized controlled trial, British Journal of Oral & Maxillofacial Surgery, 10 August 2020.
11. D. A. Ruta, E. Bissias et al, Assessing health outcomes after extraction of third molars: the postoperative symptom severity (PoSSe) scale, British Journal of Oral and Maxillofacial Surgery (2000) 38, 480–487.
12. Bhargava D, Sreekumar K, Rastogi S, Deshpande A and Chakravorty N. A prospective randomized double-blind study to assess the latency and efficacy of twin-mix and 2% lignocaine with 1:200,000 epinephrine in surgical removal of impacted mandibular third molars: a pilot study. Oral Maxillofacial Surg. 2013 Dec;17(4):275–80
13. Durand CL. Comparison of Knotless Barbed Suture Versus Monofilament Suture in the Oral Cavity of Cats. J Vet Dent. 2017 Sep;34(3):148-154, 2017 Jun 21.

ANNEXURE - I:



UNDER PEER REVIEW