

Root Canal Morphology of Mandibular First Premolars Using Radiography: An invitro study

ABSTRACT

OBJECTIVE:

The goal of this study was to document the Root Canal morphology of the first mandibular premolars using radiography.

MATERIAL AND METHODS:

The trial took place at the LUMHS Operative Dentistry Department. Two hundred removed permanent mandibular first premolars that met all of the study's inclusion criteria were gathered from LUMHS Jamshoro/Hyderabad and nearby private dental clinics in Hyderabad. All debris, soft tissues, and calculus were removed from the teeth, which were then preserved in a 10% formalin solution. Each tooth's length was measured from the crown's tip to the root's apex. An removed tooth, on the other hand, was examined from all angles, including buccal, lingual, and proximal. Root concavities and grooves, as well as bifurcation and apical curvature, were found.

RESULTS:

Comparison between both views showed 189 teeth have 1 root in and 186 have 1 canal in buccolingual view, while 182 teeth have 1 root and 179 have 1 canal in mesiodistal view. 11 teeth on buccolingual and 18 teeth on mesiodistal view showed 2 roots and 14 teeth on buccolingual and 21 teeth on mesiodistal view showed 2 canals. 110 teeth showed type I canal pattern.

CONCLUSION:

It is concluded that mandibular first premolar teeth have a wide range of radicular traits, with the majority of them having one root and one canal.

KEYWORDS: Mandibular 1St Premolar, Root Canal, Radiograph, Root Development

INTRODUCTION

Over time, it has been shown that precise diagnosis and treatment planning, as well as understanding of root canal anatomy and its regular fluctuations, are necessary for effective endodontic therapy.^{1,2}

The wide spectrum of root canal anatomy investigations, from Hess and Zurcher [3] early work to more contemporary studies illustrating the anatomic intricacies of root canal systems, have all stressed the fact that a root with a tapering canal and a single foramen is an exception rather than a rule [1]. The anatomy of the root canal system is complicated. It differs not just between various teeth but even within a single tooth between individuals. In root canal anatomy, extra canals, anastomosis, and other irregularities are widespread; extra canals, anastomosis, and other irregularities are prevalent⁴

According to current research, the root canal system is a complicated system that divides and unites canals along the way to the apex, rather than a single canal that runs evenly from orifice to apex.^{5,6} An orifice in the pulp chamber leads to an apical foramen in the periodontium at the end of a root canal. During the course of a root canal, a variety of configurations can occur from tooth to tooth in different people as well as the same person.^{7,8}

The anatomy of mandibular premolars is among the most complicated. Treatment errors and post-treatment flare-ups have been documented in these teeth, suggesting that their morphology is too variable.⁹ The mandibular first premolars are known for the complex nature of their canal

configuration. Earlier studies have reported a high occurrence of Type I canal pattern.¹⁰ Because of the great variances in root canal architecture, these teeth are difficult to endodontically treat and have a high failure rate¹¹. Root canal morphology of the mandibular first premolars has been reported based on the study of various population groups, including the Chinese, Turkish, American, Mexican, and African American population.¹¹⁻¹⁴ Observations on the root canal morphology of teeth from an Indian population were uncommon, according to literature surveys. Radiography, cleaning method, direct inspection with a microscope, 3D reconstruction, and macroscopic sections are commonly used to study root canal anatomy.^{15,16}

The examination of mandibular first premolar teeth entails a variety of elements. A single canal is accessible in the majority of instances, although there may be variation in the number of roots and canals, which can lead to endodontic treatment errors.¹ By evaluating buccolingual and mesiodistal radiography, the physician should have a clear understanding of the organisation of the pulp space of the tooth that has to be treated. So, before beginning endodontic therapy, a thorough examination of the unique geometry of the roots and root canals, as well as the variants, is required.¹⁷

The purpose of this study was to see if radiographic root canal diversity evaluation in mandibular 1st premolars in vitro was accurate in the general population.

MATERIAL AND METHODS

This observational study was done by non probability consecutive sampling with was carried out in the Operative / Endodontic Department, LUMHS Jamshoro from March 2021 to October 2021. 200 teeth permanent mandibular first premolars were incorporated in the WHO open resource calculator version by KC LUN & PETER from the National University of Singapore.

Inclusion Criteria:

Permanent mandibular first premolars with intact pulp chamber extracted for:

- Orthodontic treatment.
- Periodontal diseases.
- Periapical diseases.
- Extreme mobility

Exclusion Criteria:

- Grossly decayed or carious teeth.
- Fractured teeth
- Teeth with incomplete formation of root
- Teeth consisting of full coverage restoration
- Root canal treated teeth.

DATA COLLECTION:

At the Liaquat University Hospital's maxillofacial department, 200 extracted permanent mandibular first premolars that met the inclusion criteria were collected. For all ages and genders, no information on the purpose of extraction was enrolled together. All fragments, attached soft tissues and calculus were removed from the teeth and were kept in a 10% formalin solution. Each tooth's length was measured from the crown's tip to the root's apex. Each tooth's buccal, lingual, and proximal surfaces were thoroughly examined. Root concavities and grooves, as well as bifurcation or apical curvature, were discovered. Then the following steps were taken:

- Access cavities was prepared with a diamond round bur 0.5mm in high-speed handpiece.
- Oval shape access cavity was prepared that was extended buccally to the tip of buccal cusp lingually upto lingual cusp inclination.
- 2.5 % of sodium hypochlorite solution was used to irrigate the pulp chamber
- The main canal was located with No. 10 K-file and the second canal was also be tried to locate/attempt with No. 8 or No. 10 file.
- The canals were prepared upto 25 No files and radiographs were taken from the buccolingual and proximal side after keeping files in each canal.
- Root canal morphology according to classification was noted in proforma.

RESULTS

Among 200 extracted teeth, 184 teeth shows 1 root and 1 canal , 5 teeth 1 root 2 canals, 9 teeth 2 roots 2 and canals, and 2 teeth showed 2 roots and 1 canal on buccolingual radiograph (**Table 1**). While on Mesial radiograph 176 teeth shows 1 root and 1 canal, 6 teeth showed 1 root and 2 canal, 15 teeth showed 2 roots and 2 canals and 3 teeth shows 2 root and 1 canal (**Table 2**). Comparison between both groups shows in buccolingual view 189 (94.5%) teeth have 1 root and 11 (5.5%) teeth have 2 roots, and on mesiodistal view 182 (91%) teeth have 1 root and 18(9%) have 2 roots. While 186 (93%) teeth shows 1 canal and 14(7%) have 2 canals on buccolingual view, mesiodistal view radiograph shows 179 (89.5%) teeth have 1 canal and 21 (10.5%) have 2 canals. See (**Table-3&4**). Type I canals was seen in 110 extracted teeth as shown in Figure 1.

TABLE-1

NUMBER OF ROOTS AND CANALS IN BUCCOLINGUAL VIEW

(n=200)

No. of Teeth	No. of Roots	No. of Canals
184 (92%)	1	1
5 (2.5%)	1	2
9(4.5%)	2	2
2(1%)	2	1

TABLE-2

NUMBER OF ROOTS AND CANALS IN MESIODISTAL VIEW

No. of Teeth	No. Of Roots	No. Of Canals
176(88%)	1	1
6(3%)	1	2
15(7.5%)	2	2
3(1.5%)	2	1

TABLE-3

COMPARIONS OF NUMBER OF ROOTS BETWEEN BOTH VIEWS

No. of Roots	(Buccolingual)	(Mesiodistal)
1 Root	189 (94.5%)	182 (91%)
2 Root	11 (5.5%)	18 (9%)

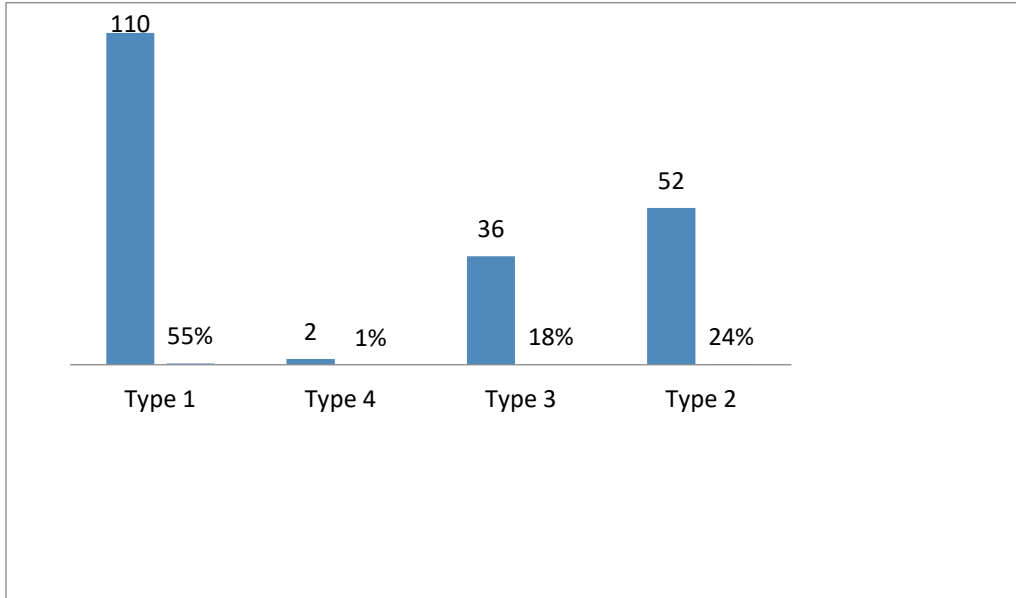
TABLE-4

COMPARISONS OF NUMBER OF ROOT CANALS BETWEEN BOTH VIEWS

No. of Root Canals	Buccolingual View	Mesiodistal View
1 Canal	186 (93%)	179 (89.5%)
2 Canal	14 (7%)	21 (10.5%)

FIGURE-1

WEINE'S CANAL MORPHOLOGY CLASSIFICATION



DISCUSSION

Understanding basic root and root canal morphology, as well as probable variations in root canal system architecture, is critical for nonsurgical root canal therapy success.

Numerous studies have reported the root and canal morphologies of the mandibular premolars because these teeth can present with complicated morphologies and anatomical variations and hence have possessed a high frequency of endodontic flare-ups and failures.^{18,19,20,21}

Although CBCT and micro CT can reliably evaluate root canal morphology, radiographs may be the sole noninvasive way to provide information on the morphology of the root canal system in a typical practise. This method has proven to be easy, quick, and requires minimal equipment.

Periapical (PA) taken both in Mesiodistal and Buccolingual views are compared and studied. Mesiodistal view enables to clearly demarcate the presence of second roots canal if present. Buccolingual view is also included in this study, as it is routinely taken preoperatively, as a protocol of treatment before starting any RCT and therefore serves for comparison and validation of the findings.

Radiographic method is noninvasive, it presents a two-dimensional image of a three-dimensional object and does not reveal the complexity present in the root canal system due to superimposition. So radiographs taken from different angles are necessary for accurate diagnosis.

England et al²² suggested that two X-rays with a 20⁰ difference in angle combined with zooming can assist in determining multicanal morphology of mandibular first premolars.

The results of present study revealed 94.5% of mandibular premolars with single root detected on buccolingual view and 91% of teeth exhibited single root on mesiodistal view and these findings are similar to those of many previous studies.^{13,15,23}

The results of this study revealed that 93% % of the mandibular first premolars exhibited single canals. This proportion is higher than those reported in many previous studies.^{1,23}

kacharaju, et al: reported 78% of mandibular first premolar exhibited single root canal in BL view and 68% in MD views.

Jain and Bahuguna¹ found that 67.39% of the 138 extracted mandibular first premolar teeth collected from a Gujarati population are type 1 single root canal system. While present study showed 55% of teeth with type 1 configuration and 24% of teeth with type IV configuration which is in agreement with study of Kacharaju et al.²⁴

Cross sectional investigations to determine the relevant images of the number and shapes of canals would possibly yield more precise results, and the number of teeth tested was limited, thus more studies with bigger sample sizes should be undertaken to validate more reliable results.

CONCLUSION

The results of this study demonstrate that mandibular first premolar teeth contain a variety of radicular characteristics, with the majority having one root and one canal. Two roots, two canals, and mesial invagination of the root were all present in a few cases, complicating endodontic therapy. Type I root canal morphology was more common in the mandibular first premolar teeth.

Consent & Ethical Approval:

As per international standard or university standard guideline Patient's consent and ethical approval has been collected and preserved by the authors.

REFERENCES

1. Jain A, Bahuguna R. Root Canal Morphology of Mandibular First Premolar in a Gujarati Population - an In Vitro Study. *Dent Res J* 2011; 8(3): 118-122.
2. Nattress BR, Martin DM. Predictability of radiographic diagnosis of variations in root canal anatomy in mandibular incisor and premolar teeth. *Int Endod J* 1991;24:58-62.
3. Hess W, Zurcher E. The anatomy of root canals of the teeth of the Permanent & Deciduous Dentition. New York: William Wood & Co. 1925.
4. M. Torabinejad and R. Walton E, *Endodontics Principles and Practice*, Louis Sanders, 4th edition, 2008.
5. Gu Y, Lu Q, Wang H, Ding Y, Wang P, Ni L. Root canal morphology of permanent three rooted mandibular first molars-part I:pulp floor and root canal system. *J Endod.* 2010;36:1341-6. 12.

6. Tahmasbi M, Jalali P, Nair K, Madhu KN, Sevin B, Nair UP. Prevalence of middle mesial canals and isthmi in the mesial root of mandibular molars: an in vivo
7. Poorni S, Karumaran CS, Indira R. Mandibular first premolar with two roots and three canals. *Aust Endod J.* 2010 Apr;36(1):32-4.
8. Cleghorn BM, Christie WH, Dong CC. The root and root canal morphology of the human mandibular first premolar: A literature review. *J Endod.* 2007 May;33(5):509-16.
9. K. M. Hargreaves and S. R. Cohen, *Cohen's Pathways of the Pulp Expert Consult*, St Louis. Mosby, 10th edition, 2011.
10. Cohen S, Hargreaves KM. *Pathways of the pulp*, 9th ed. St.Louis: Mosby-Elsevier; 2006. p. 216-7, 227.
11. Sert S, Bayirli GS. Evaluation of the root canal configurations of the mandibular and maxillary permanent teeth by gender in the Turkish population. *J Endod* 2004;30:391-8.
12. Trope M, Elfenbein L, Tronstad L. Mandibular premolars with more than one root canal in different race groups. *J Endod* 1986;12:343-5
13. Lu TY, Yang SF, Pai SF. Complicated root canal morphology of mandibular first premolar in a Chinese population using the cross section method. *J Endod* 2006;32:932-6.
14. Pineda F, Kuttler Y. Mesiodistal and buccolingual roentgenographic investigation of 7,275 root canals. *Oral Surg Oral Med Oral Pathol* 1972;33:101-10
15. Rwenyonyi CM, Kutesa AM, Muwazi LM, Buwembo W. Root and canal morphology of maxillary first and second permanent molar teeth in a Ugandan population. *Int Endod J* 2007;40:679-83.
16. Sempira HN, Hartwell GR. Frequency of second mesiobuccal canals in maxillary molars as determined by use of an operating microscope: A clinical study. *J Endod* 2000;26:673-4

17. Khedmat S, Assadian H, Saravani AA. Root canal morphology of the mandibular first premolars in an Iranian population using cross-sections and radiography. *J Endod*. 2010 Feb;36(2):214-7.
18. Bürklein S, Heck R, Schäfer E. Evaluation of the root canal anatomy of maxillary and mandibular premolars in a selected German population using cone-beam computed tomographic data. *J Endod* 2017;43:1448-52.
19. Chourasia HR, Boreak N, Tarrosh MY, Mashyakhly M. Root canal morphology of mandibular first premolars in Saudi Arabian Southern Region subpopulation. *Saudi Endod J* 2017;7:77.
20. Savitri D, Singh R, Sujatha I, Chandra S. Endodontic treatment of mandibular first premolar with two roots dividing at two different levels report of two cases. *Int J Appl Sci* 2015;19:141-4.
21. Azim AA, Azim KA, Abbott PV. Prevalence of inter-appointment endodontic flare-ups and host-related factors. *Clin Oral Investig* 2017;21:889-94.
22. England Jr MC, Hartwell GR, Lance JR. Detection and treatment of multiple canals in mandibular premolars. *J Endod* 1991;17:174-8.
23. Zaatar EI, al-Kandari AM, Alhomaidah S, al-Yasin IM. Frequency of endodontic treatment in Kuwait: radiographic evaluation of 846 endodontically treated teeth. *J Endod* 1997; 23: 453-456.
24. Kacharaju KR, Hari P, Yee A, Ngo J, Ismail MF. Analysis of Mandibular Premolars Root Canal Morphology Using Radiographic and Cross-Sectional Techniques in Malaysian Population. *Dent Hypotheses* 2019;10:14-9.