

BLUNT TRAUMA ASSOCIATED WITH SCLERAL AND RETINAL INJURY

Abstract:

Ruptures of the eye normally occur at the point of impact, called a direct rupture, with a strongly focused blow. Because the force is dispersed according to hydraulic law, if the force is more diffuse, the rupture will be indirect and occur in the tunic of sclera of weak location. The Physical examination commonly reveals the presence of a scleral hole of the globe following ocular trauma, however hidden perforations are common. The limbus, the area right below the ocular muscles, and the area around the optic nerve are all vulnerable locations in the sclera. A number of posterior segment abnormalities which are caused by blunt trauma, trauma to the orbit, and due to trauma related to other systemic causes. There can be several type of injuries to retina which include (commotio retinae), injury choroid, retinal pigment epithelial oedema, retinal pigment epithelial oedema (choroidal rupture), and optic nerve (evulsion of optic fibres) which can also occur due to blunt ocular trauma. After this kind of ocular trauma, retinal detachment, traumatic macular holes may be seen. Concussive forces also lead to damage to the orbital tissues near to the globe, which can also result in injury to various structures inside the eye like (chorioretinitis sclopetaria). other types of retinal injury include Diffuse retinopathy (Patcher's retinopathy) can be caused by systemic trauma. They tend to be circumferential rather than radial, although if the hit is powerful enough, they may spread radially. The ones near the limbus are difficult to tell apart from lacerations, while the ones further back are easy to spot.

KEYWORDS: Scleral hole, ocular trauma, optic nerve, retinal pigmentation, commotio retinae

INTRODUCTION

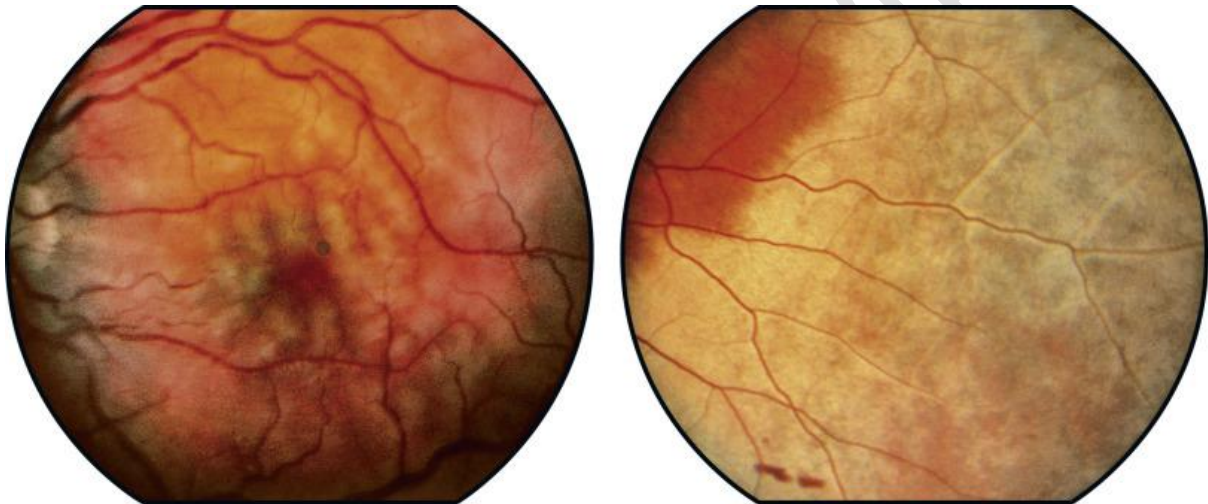Various intrinsic eye ailments can result from a blunt eye injury. The physician may meet two emergent entities: globe rupture and retrobulbar hematoma, which are the subjects of this section^[1]. Eye deformity, pain, and vision loss are common symptoms of globe rupture, yet the distortion may not be seen on the exam depending on the clinical suggestion. A retrobulbar hematoma can also cause eye pain and visual loss, although proptosis can aid to confirm the diagnosis.^[1] Both diagnoses are vision-threatening and necessitate immediate ophthalmologic evaluation for final treatment.

In this article the injuries to important structures of eye that is sclera and retina have been discussed which can occur due to above mentioned mechanism

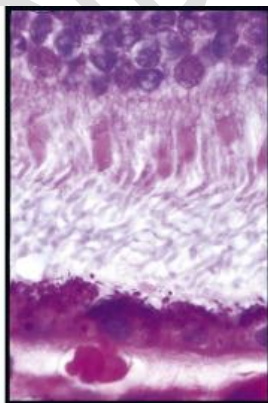
Several studies have revealed that presenting visual acuity is one of the criteria that strongly predicts visual prognosis after such injury ^[2]. Some of the most commonly occurring retinal and scleral injuries have been described below

Oedema in Berlin (Commotio Retinae)

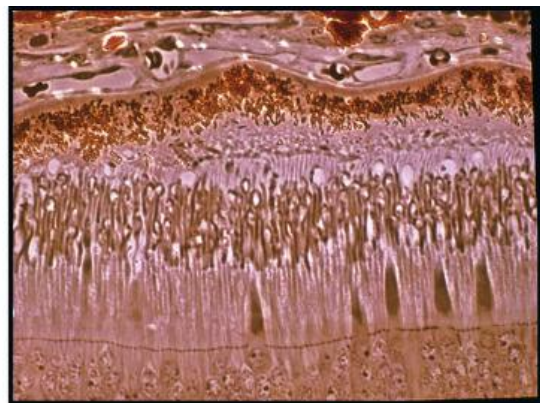
Berlin's edema, also known as commotio retinae, is a zonal whitening of the retina caused by outer photoreceptor rupture and retinal pigment epithelium damage caused by forceful trauma, resulting in oedema of all retinal layers.^[3] This type of damage causes no intraretinal cystic alterations or haemorrhage. External force transmitted through the vitreous to the chorioretinal region, which causes outer retinal ischemia, is thought to be the mechanism. These modifications fade away on their own, although they can induce late pigment atrophy.^[3]



Berlin's oedema (commotio retinae) causes the outer segments of photoreceptors to be disrupted microscopically. Fluid may collect in the retina's outer layers later. There may be retinal pigment epithelial degeneration and cystoid retinal degeneration when the oedema goes away. A big cyst or a macular hole might result from the coalescence of cystoid regions. Recovery of vision is difficult, especially if the macula is damaged.^[3]

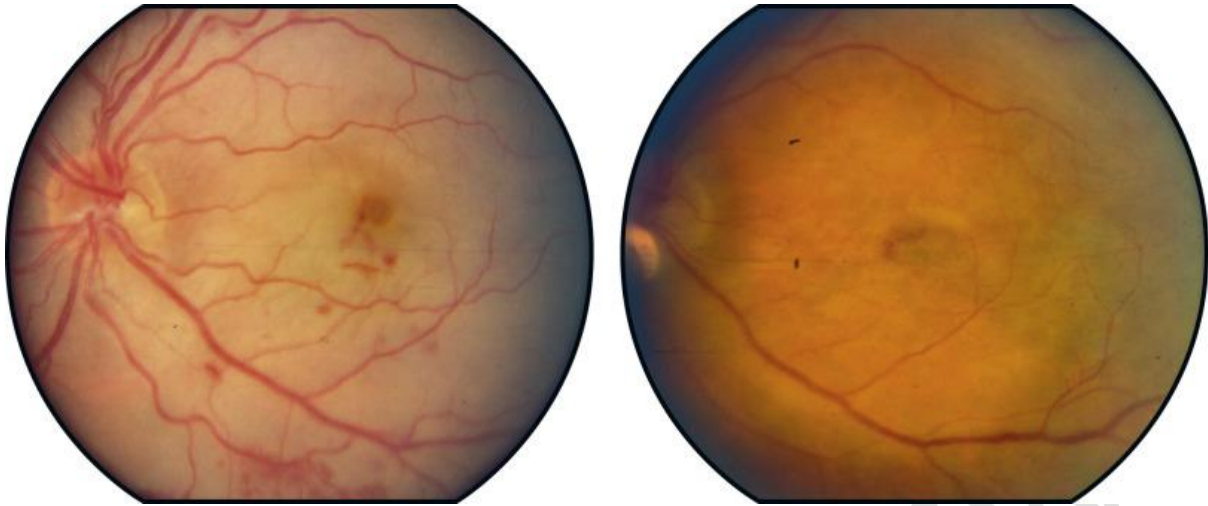


© 748

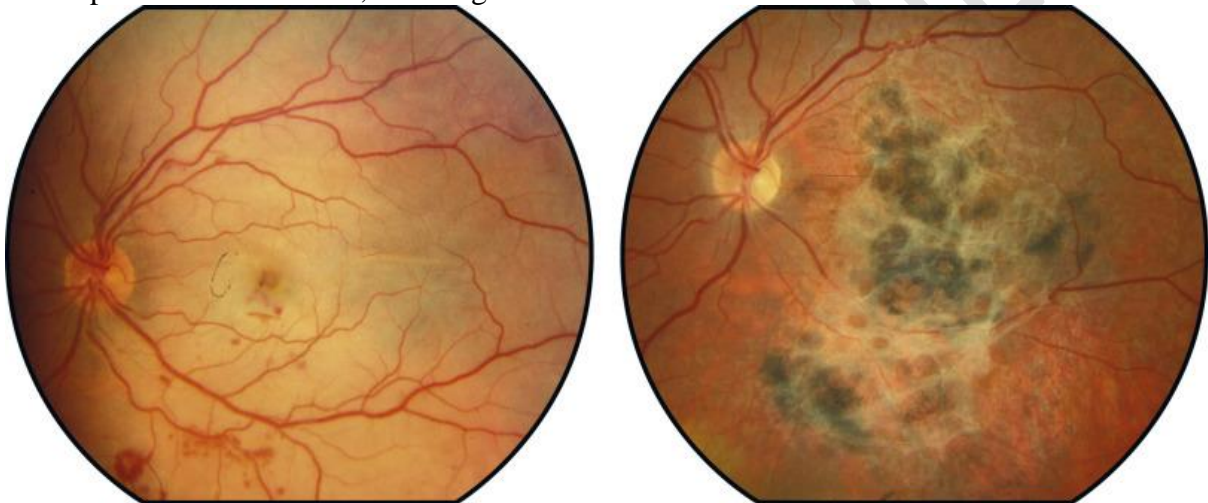


© 749

This patient was in a car accident that resulted in the deployment of the air bag. OS developed acute commotio retinae and moderate macular haemorrhage (left image). Over the next two months, macular pigment mottling (right image) developed gradually, although vision restored to 20/40 OS.^[3]



A hockey player's left eye was injured by a hockey stick, resulting in acute retinal whitening and scattered intraretinal haemorrhages. A severe reactive hyperplastic pigmentary change developed two months later, resulting in irreversible vision loss.^[3]

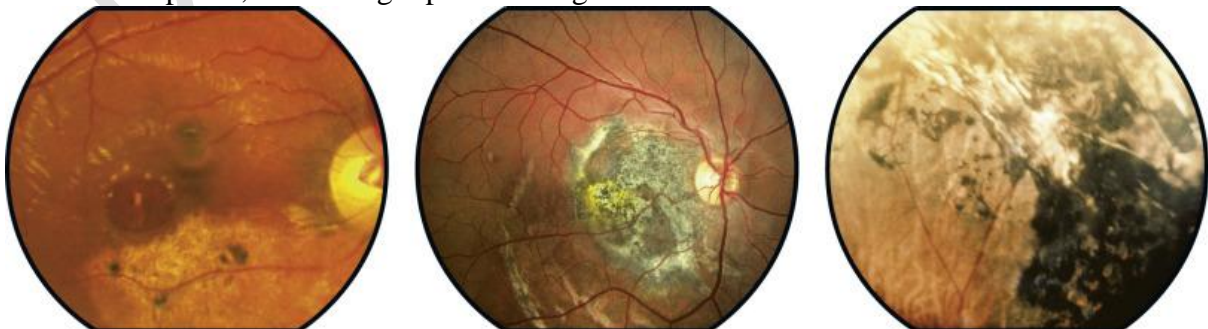

Traumatic Retinal Pigment Epitheliopathy (TRPE)

It is a type of retinal pigment epitheliopathy that occurs

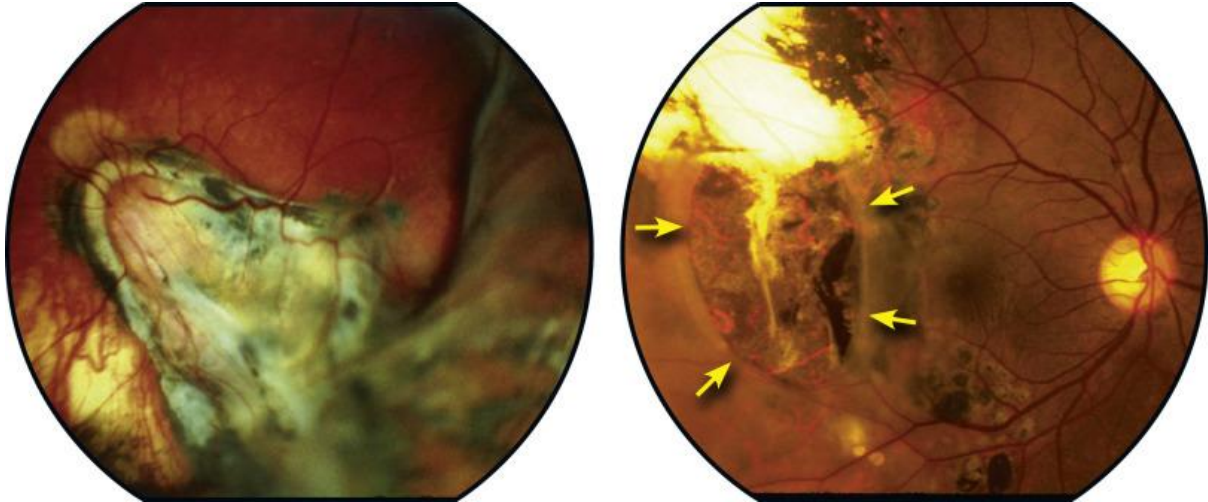
Traumatic retinal pigment epitheliopathy is characterised by atrophic, pigmentary, or fibrotic changes. Eyes with little pigmentation, such as blue eyes, are prone to atrophy, whereas those with high pigmentation in the pigment epithelium and choroid are prone to hyperpigmentation. Fibrous degeneration can affect any eye, depending on the severity of the trauma.^[3]

. The left patient is mostly atrophic, the middle one has pigment epithelial hyperplasia and fibrous metaplasia, and the right patient has generalised seborrhea.^[3]

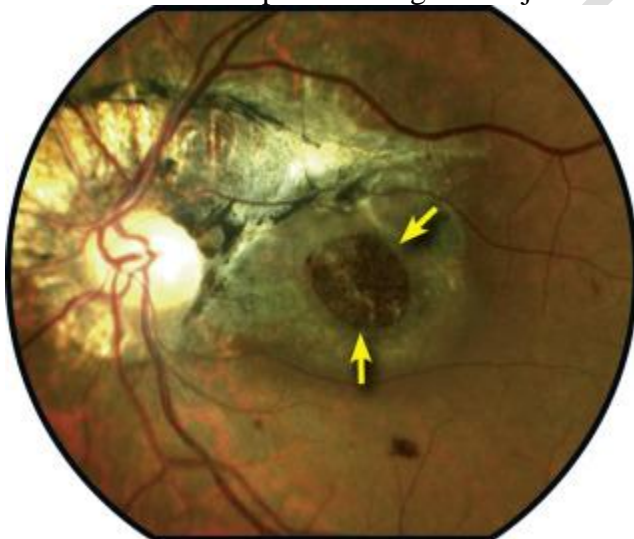

These photos show two professional boxers who were hit in the eye by the thumbs of their boxing gloves, causing ocular damage. Extensive fibrovascular and pigmentary scarring may

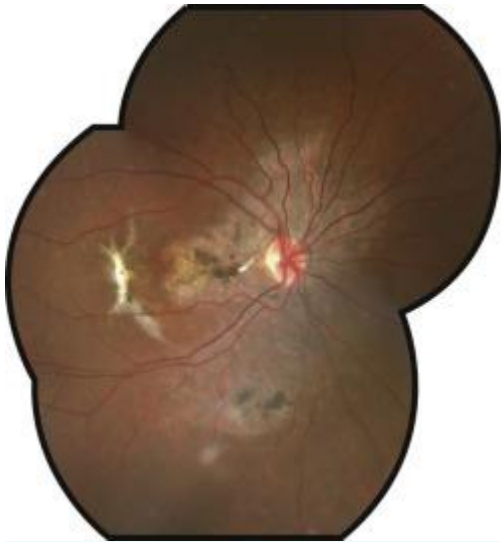
be seen in the left picture. There are areas of atrophy, hyperpigmentation, and fibrosis coincident with a massive retinal break in the temporal macula in the image on the right (arrows).^[3] Despite the existence of field loss, the boxer's macula was saved and his visual acuity was good, allowing him to pass a normal vision test before his next fight. While he was taking part in an ocular boxing complications study, the extent of his pathology was discovered. The match was called off, and the retina was removed.^[3]



A paintball injury occurred to this patient. Optic nerve atrophy, peripapillary atrophy, fibro-pigmentary degeneration, and a big macular hole are all present (arrows). Multiple indications of blunt posterior segment injuries are shown in this instance.^[3]



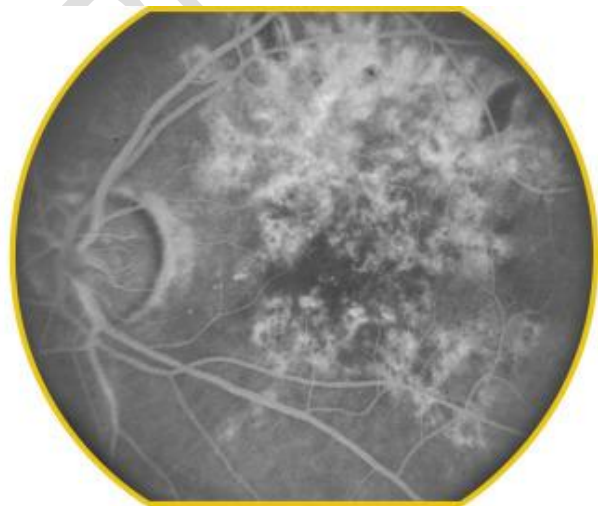
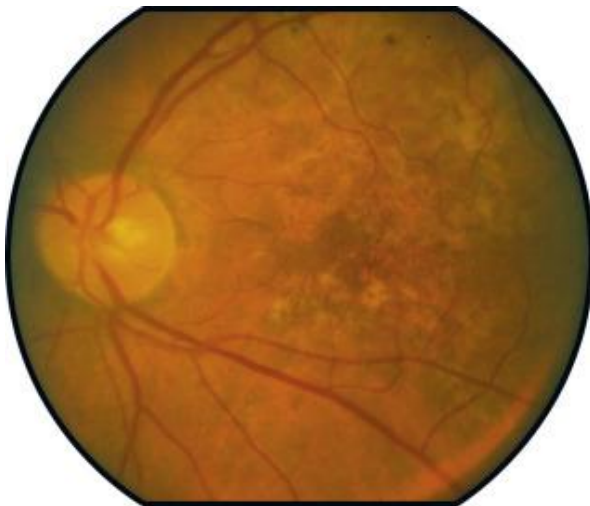
A bungee cord caused blunt injuries to this patient. He was using anticoagulants, which made the subretinal bleeding worse. The injury caused widespread retinal pigment epitheliopathy and a fibrotic choroidal rupture.



During an incident, this patient was struck in the eye with a wooden board.^[3]

The pigmentary changes were highlighted on a fluorescein angiography, which revealed extensive pigment mottling throughout the posterior pole (left) (right).

In this injured eye, the visual acuity was 20/200.^[4]

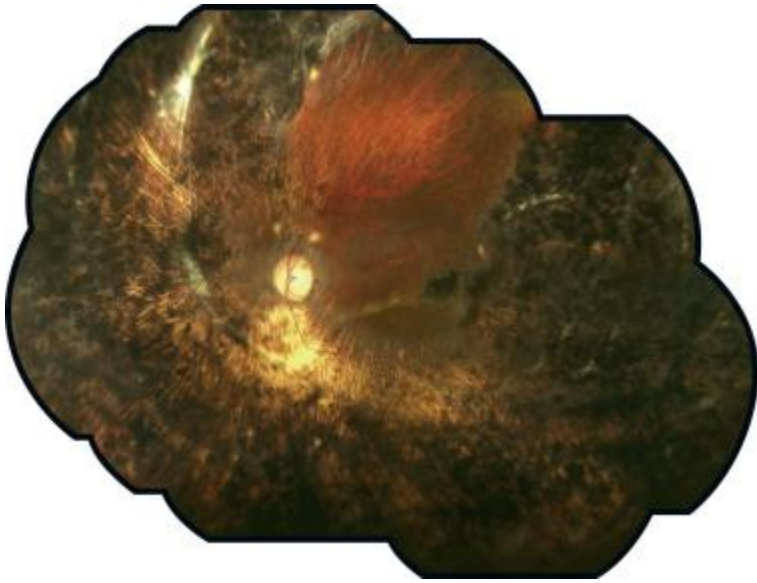


A beer bottle had injured this patient in the eye.

The result was a massive dislocation with extensive retinal pigmentary epithelial growth and atrophy.

There was additional ocular atrophy and a band of fibrotic scarring in the supranasal hemisphere.

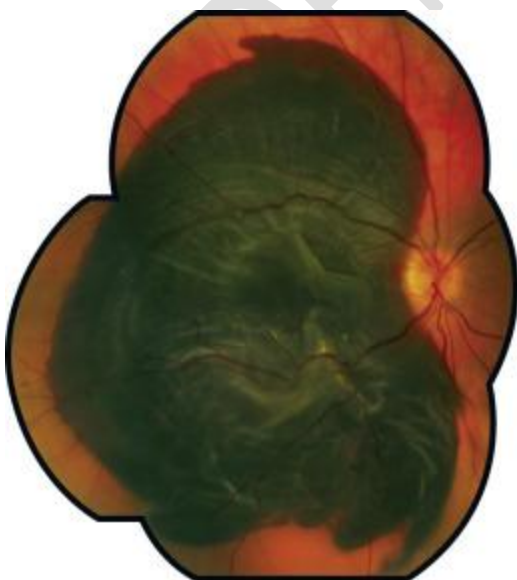
Only a little portion of the superior peripheral retina is unaffected.^[4]



This patient received only minor physical injuries in a car accident, but was on anticoagulant medication, which contributed to the large haemorrhage evident in the photo.

She had a large subretinal haemorrhage and a shallow but visible retinal detachment with folds when she arrived. Macular Hole Caused by Trauma^[4]

A macular hole is frequently the result of ocular trauma, particularly because the region's avascularity may predispose a hole to form after a number of traumas. Other chorioretinal injuries, such as commotio retinae, choroidal rupture, and traumatic retinal pigment epitheliopathy, are frequently present. It can happen anywhere from days to years after an accident. Macular holes have also been caused by trauma such as a laser or lightning strike. While traumatic macular holes may close on their own, most cases require vitrectomy surgery, intraocular gas tamponade, and post-operative face-down orientation. The rate of anatomic closure is comparable to that of idiopathic^[5]



HISTORY AND PHYSICAL

Any patient who reports direct eye damage, ongoing eye pain, or vision loss should have a high suspicion for globe injury. It's important to figure out what caused the injury and when it happened. It's also vital to find out if any anticoagulants are being used^[5]

Reduced vision or complete blindness, uneven globe contour, teardrop pupil, hyphaemia, or a shallow anterior chamber can all be symptoms of globe rupture on the slit-lamp test.. In globe rupture, the Seidel sign is positive, indicating that aqueous humour is flowing from the injury site into the fluorescein-stained eye. However, if the globe rupture is visible, the Seidel sign should be checked. Retrobulbar hematoma has a characteristic clinical appearance of proptosis and acute eye discomfort. Vision loss is possible, just as it is in the case of a globe rupture.^[5]

Depending on the cause of the damage, there may be periorbital edema, ecchymosis, or subconjunctival bleeding in either of these categories.

Evaluation

If feasible, visual acuity should be evaluated individually in each eye, taking care not to manipulate any potential intrinsic globe injury. Pupillary abnormalities should be observed as well^[5] Any associated intracranial and facial bone injuries should be thoroughly evaluated. Fractures, particularly of the orbital floor, are linked to a significant proportion of globe ruptures and retrobulbar hematomas. Extra-ocular motility testing in the afflicted eye may be limited due to entrapment, intrinsic globe distortion, or retrobulbar haemorrhage.

In the case of trauma or anticoagulant usage, laboratory investigation should be pursued as the clinical circumstances warrants. While establishing the diagnosis, Additional maxillofacial injuries can be ruled out with computed tomography (CT) imaging. CT imaging can identify foreign objects, scleral disruption, and possibly vitreous bleeding in addition to globe distortion and retrobulbar hematoma..^[5]

ETIOLOGY

The following are some of the most common causes of blunt eye trauma:^[6]

- Sporting events (especially ice hockey, soccer, softball, and baseball)
- Accident in a car
- An injury sustained on the job (especially drilling, hammering, or working with cars)
- Interpersonal violence or fighting
- Falling
- BB guns and firecrackers are examples of children's games.

Young guys are more prone than older men to suffer from blunt eye damage. Men under the age of 30 account for 95 percent of ocular trauma injuries, which are frequently caused by interpersonal violence.

The house is the most common site of blunt eye injuries, followed by the workplace. Falls are the most common cause of blunt eye damage in the elderly.

CLINICAL FEATURES:

The intensity of the injury determines the symptoms of blunt eye trauma^[6]

Mild signs and symptoms include:

- Minor discomfort
- Bruising
- Swelling
- A blemish on the face
- traces of blood on the white area of the eye (sclera)
- Fluid build-up in the eye is known as edema.

The following are severe signs of blunt eye injuries that suggest a significant injury:

- Any blood on the coloured area of the eye (iris) causes vision alterations.
- It's difficult to move the eye around.
- Pain when moving your eyes There is a lot of blood in the white area of the eye (sclera).
- a change in the size or shape of the pupils
- Eyeball pain is severe.
- Sensitivity to light
- Vision is hazy
- Doubtful perception
- Deformity of the eyes
- An eye socket deformity is a condition in which the eye socket is distorted.
- There's numbness everywhere around you.
- The way you see things shifts.
- It's difficult to move the eye around.
- Pain when moving your eyes^[6]
- There is a lot of blood in the white area of the eye (sclera).
- a change in the size or shape of the pupils
- Eyeball pain is severe.
- Sensitivity to light
- Vision is hazy
- Doubtful perception

Complications:

Complications may vary depending on the nature and amount of the eye trauma, as well as the location and depth of the injury. Superficial injuries will lead to corneal scarring, retinal detachment,, cataracts whereas deeper injuries can result in choroidal rupture, post-traumatic glaucoma, , and endophthalmitis. There may be varying degrees of vision loss. Enucleation may be required in cases of severe trauma that is not susceptible to ophthalmologic surgical healing.^[7]

Differential Diagnosis

Traumatic glaucoma, foreign body, scleral disruption Acute eye trauma can result in globe rupture, retrobulbar hematoma, , hyphema, orbital blowout fracture with entrapment, , and vitreous bleeding are all possible causes of vitreous haemorrhage.^[7]

Treatment / Management

The emergency department's therapy for globe rupture includes supportive measures to prevent the damage from deteriorating or the expulsion of intraocular fluids., Valsalva from vomiting could cause raised intraocular pressure and aqueous fluid loss so antiemetics should be administered to prevent,^[8]. As needed, analgesia should be administered. Additional manipulation of the eye should be prevented by using a stiff eye shield. The patient should be positioned semi-recumbently.^[8]

Analgesia and antiemetic should also be given in the case of a retrobulbar hematoma. However, rapid decompression with a lateral canthotomy and inferior cantholysis is the most effective treatment. If there are no delays in the consultant's ability to execute this treatment, it can be done by an emergency medicine specialist or an ophthalmologist.^[9] Delays of more than 4 hours, is associated with poorer outcome hence vision prognosis is time-sensitive found in from the If you have a globe damage or a retrobulbar hematoma, you should see an ophthalmologist right away. Surgical repair by a qualified ophthalmologic expert is the definitive treatment for these illnesses. Onset of symptoms. Antibiotics can be administered as a preventative measure to avoid subsequent endophthalmitis.^[9]

PROGNOSIS

The prognosis of blunt eye trauma is largely determined by the trauma's consequences. According to one study, ocular damage causes monocular blindness in one-quarter of patients. Although glaucoma is more common in children who have had blunt ocular trauma, research has revealed that visual acuity is often greater in blunt ocular injury than in penetrating ocular injury.^[9] Blunt ocular trauma, on the other hand, may result in the poorest visual prognosis if the eye is burst, as this indicates that the damage happened at a high velocity. Traumatic optic neuropathy also indicates a poor visual outcome. A relative afferent pupillary insufficiency, poor visual prognosis is indicated by the absence of a red reflex, initial visual acuity of less than 20/200, and an eyelid laceration. According to another study, a quarter of people with commotio retinae or sclopetaria retinae following acute ocular trauma had a visual acuity of less than 20/30 in the eye that was injured. Following a blunt ocular trauma, visual acuity is severely impaired if there is a hyphema, retinal detachment, and/or vitreous haemorrhage.^[9]

The severity of the initial injury and the mechanism of injury are frequently used to predict whether or not unfavourable outcomes are likely. The Ocular Trauma Score is a validated approach for predicting the functional result of an eye after trauma to provide the best forecast of an individual's visual prognosis^[9]

The nature and extent of the eye trauma, as well as the location and depth of the injury, can all affect the complications. Corneal scarring can develop from very minor injuries, but more serious injuries can cause choroidal rupture, post-traumatic glaucoma, cataracts, retinal detachment, and endophthalmitis are all conditions that can affect the eyes.. Vision loss can range from mild to severe. In cases of severe trauma that does not respond to ophthalmologic surgical healing, enucleation may be required.^[9-16]

CONCLUSION:

Eye damage is highly prevalent, and many people lose their vision as a result of it. Without vision, one becomes disabled, making it difficult to find suitable employment. Ocular eye

injury is preventable in many circumstances, and it is the responsibility of all practitioners to educate patients about eye safety. The most effective strategy to educate and monitor patients with ocular trauma is to form an interprofessional team. Most patients are followed up on as outpatients by their general physician provider or nurse practitioner due to a significant lack of eye surgeons.

Eye trauma is a typical occurrence in the emergency room. However, other than a cursory exam that includes a visual acuity test, investigation of deeper eye injuries is not usually possible in the emergency room. As a result, healthcare professionals, such as, general physician should always consult with the on-call ophthalmologist for proper evaluation of the eye.

Although a superficial cut around the eye may be treated in the emergency room, all patients with vision loss should be sent to an ophthalmologist. If any vision-related concerns arise during follow-up, the general physician and primary care physician should contact the ophthalmologist. Missed eye injuries might result in irreversible vision loss and long-term litigation.

Finally, all practitioners should inform patients about eye protection when working with splashing liquids or flying debris, such as wearing face helmets and safety goggles.^[10] Physical examination commonly reveals the presence of a scleral hole of the globe following ocular trauma, but hidden perforations are also common. Computed tomography of the orbit can detect intraorbital foreign bodies and concomitant facial bone fractures as well as an occult scleral rupture. The "flat tyre" sign is caused by posterior sclera collapse, which results in a flattening of the globe's posterior contour. Intraocular foreign material or gas, thickening of the sclera posteriorly, and a blood-vitreous fluid-fluid level are other signs of scleral rupture. Ocular traumas are a serious public health issue with little understanding of the consequences on both an individual and a community level. In the event of a closed globe injury, any of the ocular structures can be injured. These lesions, which are frequently numerous, can occur suddenly or gradually. Recently, classifications were created in order to better advise patients about their visual prognosis. On the one hand, major efforts are still needed to review and develop new medicines, and on the other hand, effective policies to prevent ocular damage are also needed.

To avoid any extrusion of intraocular contents, avoid any unnecessary globe manipulation (including tonometry). To rule out simultaneous bone injury or cerebral trauma, obtain suitable imaging. To avoid Valsalva manoeuvres that could aggravate globe rupture or retrobulbar hematoma, give analgesics and antiemetics.

To avoid further harm, a hard protective eye cover should be worn; eye patches are not recommended. Antibiotics should be given as a preventative measure to help avoid endophthalmitis. For decisive measures, seek urgent Ophthalmology consultation, but lateral canthotomy for individuals with known retrobulbar hematoma should not be delayed.

Ethical Approval:

As per international standard or university standard ethical approval has been collected and preserved by the authors.

REFERENCES

1. Rao, N. A., Riffenburgh, R. S., & Snyder, A. (1999). Scleral Rupture. *Ophthalmology*, 106(9), 1643. [https://doi.org/10.1016/s0161-6420\(99\)90376-7](https://doi.org/10.1016/s0161-6420(99)90376-7)
2. Sevel, D., Krausz, H., Ponder, T., & Centeno, R. (1983). Value of computed tomography for the diagnosis of a ruptured eye. *Journal of Computer Assisted Tomography*, 7(5), 870–875. <https://doi.org/10.1097/00004728-198310000-00022>
3. RIFFENBURGH, R. S. (1963). Contusion rupture of the Sclera. *Archives of Ophthalmology*, 69(6), 722–726. <https://doi.org/10.1001/archopht.1963.00960040728007>
4. WILLIAMS, D. A. V. I. D. F., MIELER, W. I. L. I. A. M. F., & WILLIAMS, G. E. O. R. G. E. A. (1990). Posterior segment manifestations of ocular trauma. *Retina*, 10. <https://doi.org/10.1097/00006982-199010001-00006>
5. Han, D. P., Mohsin, N. C., Guse, C. E., Hartz, A., & Tarkanian, C. N. (1998). Comparison of pneumatic retinopexy and scleral buckling in the management of Primary Rhegmatogenous Retinal Detachment. *American Journal of Ophthalmology*, 126(5), 658–668. [https://doi.org/10.1016/s0002-9394\(98\)00181-0](https://doi.org/10.1016/s0002-9394(98)00181-0)
6. Yanoff, M. (2014). Commotio Retinae (Berlin's edema) (921.3). *Ophthalmic Diagnosis and Treatment*, 104–104. https://doi.org/10.5005/jp/books/12179_30
7. Doi, M., Osawa, S., Sasoh, M., & Uji, Y. (2000). Retinal pigment epithelial tear and extensive exudative retinal detachment following blunt trauma. *Graefes Archive for Clinical and Experimental Ophthalmology*, 238(7), 621–624. <https://doi.org/10.1007/s004170000155>
8. Olsen, T. W., Chang, T. S., & Sternberg, P. (1995). Retinal detachments associated with blunt trauma. *Seminars in Ophthalmology*, 10(1), 17–27. <https://doi.org/10.3109/08820539509059976>
9. Ayalon, A., Okrent, L., & Rubowitz, A. (2020). Posterior pole retinal tears following blunt ocular trauma. *American Journal of Ophthalmology Case Reports*, 18, 100642. <https://doi.org/10.1016/j.ajoc.2020.100642>
10. Williamson, T. H. (2012). Different presentations of Rhegmatogenous retinal detachments. *Vitreoretinal Surgery*, 163–187. https://doi.org/10.1007/978-3-642-31872-6_7
11. Yoshikawa, Y., Shoji, T., Kanno, J., Ibuki, H., Ozaki, K., Ishii, H., Ichikawa, Y., Kimura, I., & Shinoda, K. (2018). Evaluation of microvascular changes in the macular area of eyes with Rhegmatogenous retinal detachment without macular involvement using swept-source optical coherence tomography angiography. *Clinical Ophthalmology*, Volume 12, 2059–2067. <https://doi.org/10.2147/oph.s177933>
12. Gajbhiye, Varsha, and Yeshwant Lamture. “Minoxidil a Youth Elixir for Eyebrow Hypotrichosis.” *JOURNAL OF CLINICAL AND DIAGNOSTIC RESEARCH* 14, no. 2 (February 2020). <https://doi.org/10.7860/JCDR/2020/42801.13474>.
13. Kedia P, and Madke B. “Unilateral Molluscum Contagiosum Following Eyebrow Grooming.” *JOURNAL OF CLINICAL AND DIAGNOSTIC RESEARCH* 13, no. 11 (November 2019): WD01–2. <https://doi.org/10.7860/JCDR/2019/42600.13283>.
14. Dangore S. and Bhake A. “Cervical Lymphadenopathy in a Dental Patient: An Eye Opener Case Report.” *SPECIAL CARE IN DENTISTRY* 39, no. 1 (February 2019): 59–64. <https://doi.org/10.1111/scd.12336>.
15. Laad, G., Madke B., and Nikam B. “Cirroid Aneurysm of Upper Eyelid.” *JOURNAL OF DERMATOLOGY DERMATOLOGIC SURGERY-JDDS* 23, no. 2 (December 2019): 109–110. https://doi.org/10.4103/jdds.jdds_30_19.

16. Mahatme KG, Deshmukh P, Sable P, Chakole V. Ultrasonography: The Third Eye of Anaesthesiologist. JOURNAL OF PHARMACEUTICAL RESEARCH INTERNATIONAL. 2021;33(37A):235–8.

UNDER PEER REVIEW