

# MUCORMYCOSIS: A CO-INFECTION ASSOCIATED WITH - COVID-19 AND DIABETES

## **ABSTRACT**

**BACKGROUND** Rhino-orbital mucormycosis cases in patients with coronavirus disease are on the rise, particularly in India. In severe Mucormycosis and COVID-19, Diabetes mellitus is a risk factor on its own. The use of steroids and different immunosuppressive drugs to handle significantly ill sufferers has broadly spread because the COVID-19 pandemic has advanced, which has probably contributed to a boom in subordinate infections and uncontrolled blood glucose levels. Initial symptoms include fever, headache, nausea, and widespread weakness. With the start of sinusitis, purulent discharge with or without epistaxis and congestion and reduced feeling within the nose may be present. Mucormycosis is an uncommon, difficult to identify condition with high morbidity and mortality rates. Patient survival depends on early detection, rapid treatment, and consideration of the limitations of continually updating COVID-19 therapeutic recommendations.

**OBJECTIVE** – ‘The purpose of the study was to conduct a systemic review of the literature’ for determining the severity and co-relation of diabetes with mucormycosis.

**METHODOLOGY** – Keywords were used to search the articles from the electronic databases of PubMed, Cochrane and Google Scholar upto August, 2021. All details of case reports/articles of mucormycosis in COVID-19 were utilized for this review article.

**STUDY DESIGN** – Systemic Review article

**CONCLUSIONS** – 1. Using a literature review of all documented cases, we can comment on the correlation of diabetes with Mucormycosis in covid-19 patients.

2. Based on the observations gained from the literature examined in this study, we are able to decide the clinical diagnostic strategy for mucormycosis in diabetic patients affected by covid-19.

**STUDY IMPLICATION** – This review article ensured the clinical diagnostic strategy and management in such cases affected by covid-19.

**KEYWORDS** – Rhino-orbital cerebral Mucormycosis (ROCM), Diabetes Mellitus, SARS-COV2, COVID-19.

## INTRODUCTION

COVID-19 has wreaked havoc on human health as well as on the world economy. SARS CoV-2 has infected around 220 countries and the death numbers reached to 4 millions. It is thought that the increased use of indiscriminate steroids, antibiotics, and zinc medications taken by self during the COVID-19 outbreak may have exacerbated gut microbiota dysbiosis, resulting in immunosuppression and rendering the risk group more susceptible to this mycotic disease.<sup>1</sup>

Another factor might be an overabundance of uncontrolled precautions. Repeated steaming, for example, may disrupt the beneficial virome and microbiome of the nasal tract. Mucormycosis was found in a large number of individuals who were getting medical care but were not on oxygen therapy. As a result, there appears to be no definitive relationship between oxygen treatment and infection susceptibility. Mucormycosis is also affected by environmental variables such as ambient temperature, seasonal changes and humidity.<sup>2</sup>

According to an epidemiological study done roughly two decades ago, Mucormycosis may be deadly if left untreated, with a death rate of up to 54 percent.<sup>2,3</sup> Etiologically, mucormycosis is an invading and opportunistic mycosis caused by molds called mucoromycetes.

Mucormycosis has become more common in patients with coronavirus infection. The use of steroids and different immunosuppressive drugs to handle significantly ill sufferers has broadly spread because the COVID-19 pandemic has advanced, which has probably contributed to a boom in subordinate infections and uncontrolled blood glucose levels. Also, immunosuppressive medicines and corticosteroids to manage critical patients had become extensively spread as the COVID pandemic progressed, contributing to a rise in subordinate infections with uncontrolled blood glucose levels.<sup>2</sup>

Mucormycosis (also called black fungus) and COVID-19 have produced comorbidities that exacerbate infection and increase mortality rates. Mucormycosis is aggressive and infect the brain, nose and eyes. In critical circumstances, patients' eyes are removed to save their lives.<sup>3</sup> Mucormycosis has a strong proclivity for invading blood arteries, causing thrombosis, necrosis, and tissue infarction. Histopathology and culture are used to diagnose mucormycosis. Blood tests are only useful for a restricted number of diagnoses. Mucormycosis can spread quickly, and even a few days' delay in starting therapy can significantly aggravate the situation.<sup>4</sup>

The corona virus directly infects T cells, leaving patient prone to repeated infections and severe COVID-19 infection.<sup>5</sup> India accounts for 15.3% of the world's diabetic population. Diabetic people and recovered Covid-19 infection are highly susceptible to fungal infections. On the contrary, it has been shown that about 85% of mucormycosis patients have diabetes or diabetes that is not controlled.<sup>5,6</sup>

Uncontrolled diabetes is the one risk factor for post-Covid mucormycosis that may be changed fast. In populations with high risk of diabetes, to evaluate and regulate diabetes, mass urine sugar testing can assist diagnose and treat the diabetes which is not controlled.<sup>5</sup> The commonest type of mucormycosis in population with diabetes is rhinocerebral mucormycosis where the lung involvement is uncommon. It is a fast deadly infection.<sup>6</sup>

Rhino-orbital mucormycosis is a rare and severe angioinvasive fungal infection that affects people with diabetes, chronic renal failure, hematological malignancies, and deferoxamine treatment.<sup>6</sup>

In rhino-orbital cerebral mucormycosis (ROCM), the initial site of infection is the nasal turbinates. The nature of fungus being angioinvasive, an acute bout of sinusitis quickly develops to pan sinus involvement with adjacent dissemination to the orbit, palate and brain, evolving to necrosis and severe tissue ischemia.<sup>7</sup> On examining the eyes, swelling with tenderness of the eyelids, painful proptosis as symptoms of orbital invasion, can be noticed. Due to edema, common symptoms include eyelid abscesses, ocular numbness, and ptosis. A deeper examination discloses symptoms of endophthalmitis, optic disc edema and vitritis.<sup>7</sup>

Any occurrence of non-bacterial sinusitis in a diabetic patient, even if there is no ketoacidosis, should raise suspicion of mucormycosis. ROCM symptoms are typically inadequate, with a wide range of severity. Mucormycosis of ROCM type is a surgical as well as medical emergency that requires immediate attention. The longer it takes to start therapy, the higher the risk of morbidity and death.<sup>8</sup>

According to a recent evaluation for the year 2019–2020, the occurrence of mucormycosis ranged from 0.005-1.7 per million people worldwide, with the incidence in India approximately 80 times greater (0.14) than in industrialized nations. Persistent use of corticosteroids is related to opportunistic fungal infections such as mucormycosis and aspergillosis, even short term use of corticosteroids in the diabetic population is linked to mucormycosis. Mucormycosis with intracranial involvement can result in a death rate of up to 90%.<sup>8</sup>

Initial symptoms include fever, headache, nausea, and widespread weakness. With the start of sinusitis, purulent discharge with or without epistaxis and congestion and reduced feeling within the nose may be present. Nasal ulceration and necrosis are very common complaints. Pain and numbness are two common facial complaints. 93.8 percent of patients with Covid Associated Mucormycosis(CAM) experienced a headache, 62.5 percent had nasal symptoms such as nasal stuffiness and rhinorrhea, and 59.4 percent had ocular symptoms such as redness or discomfort/pain.<sup>9</sup> Retro-orbital or peri-orbital discomfort, impaired or double vision, as well as partial or entire loss of vision in both or one eyes can all lead to cause blindness. Alterations in awareness, unsteady walking, and/or convulsions can all be signs of brain involvement.<sup>9</sup>

Direct microscopy of nasal aspirate and histopathological investigation were used to diagnose mucormycosis. Intravenous liposomal amphotericin B, surgical debridement, and supportive care were all used to successfully treat our patient. Renal failure, hypokalemia, hepatic impairment, fever, and chills have all been reported as side effects of amphotericin B usage.<sup>10</sup> According to various studies, the patients treated with surgical debridement and use of intravenous amphotericin b have a good prognosis and hence a better chance of survival.<sup>11</sup>

It's crucial to have a high suspicion for fungal infections in patients of covid with previous medical conditions. On imaging, augmentation and thickening of soft tissue on right side, temporal lobe infiltration, muscles of mastication, lacrimal gland, and cerebellar infarcts were found, as well as pansinusitis of the sphenoid and maxillary sinuses.<sup>12</sup>

Mucormycosis has a distinct preference for certain anatomical locations. For example, Patients with severe neutropenia and GVHD disease develop pulmonary mucormycosis which is commonly seen in diabetic patients. Antifungal treatment is a medical intervention in mucormycosis, and liposomal amphotericin B is the medication of choice. The recommendations also advocate surgical debridement in conjunction with antifungal treatment wherever possible, but caution against antifungal combination therapy.<sup>13</sup>

After clinical suspicion, CT was the predominant mode of diagnosis in all of the studies examined. The most prevalent presentation in all of the studies considered is paranasal sinus involvement, in which the most commonly affected and involved sinus is ethmoid sinus, followed by the maxillary sinus. All of the investigations predominantly address the extraocular muscle have orbital involvement. Only a few investigations have reported the occurrence of bony erosion and involvement of the orbit's apex. The involvement of the brain is the rarest radiological characteristic. Infarction, cavernous sinus involvement, and internal cranial artery involvement are the most common radiological presentations.<sup>14</sup>

Acute invasive fungal rhinosinusitis is an uncommon yet deadly illness that mostly affects immunocompromised people. In the case of SARS-CoV-2 infection and coronavirus disease 2019 (COVID-19)-related acute respiratory distress syndrome, the same group is at a very high risk of complications and fatality.<sup>15</sup>

The most common complications of mucormycosis reported are

(1) those caused by the infection itself, such as palatine ulcers, disseminated infection, cavernous sinus thrombosis, osteomyelitis, periorbital destruction, and death;

(2) those resulting in anatomical or functional deformities, like chronic rehabilitation, requiring prosthesis, reconstructive surgeries and orbital exenteration after debulking surgery, but not limited to bacterial superinfection, hypokalemic syndromes, nephrotoxicity and long hospital stays (due to IV antifungal treatment and surgeries, 15–30 days are required.)<sup>16</sup>

Mucormycosis is an uncommon, difficult to identify condition with high morbidity and mortality rates. Patient survival depends on early detection, fast treatment, and consideration of the limitations of continually updating COVID-19 therapeutic recommendations.<sup>16</sup>

Mucormycosis infections are marked by widespread angioinvasion, which leads to vascular thrombosis and tissue necrosis. Infected tissue necrosis can hinder the transport of leukocytes and antifungal medicines to infection foci. The ability of the organism to hematogenously disperse to additional target organs is presumably aided by this angioinvasion<sup>17</sup>. As a result, endothelial cell injury and penetration through the extracellular matrix proteins lining blood arteries is thought to be a significant stage in *R. Oryza*'s pathogenetic approach. As a result, gaining a better knowledge of the mechanisms that cause these processes might lead to novel ways to prevent and/or cure.<sup>18</sup>

On radiographs, opacification of the sinuses can be seen together with patchy effacement of the bone walls of the sinuses. A CT scan with contrast or a magnetic resonance imaging scan can show bone erosion or disintegration and assist determine the severity of the illness. According to histopathology, the lesion has wide aseptate fungal hyphae that branch at right angles. The same histology was discovered in this instance. Aspergillosis is a histological differential diagnosis in

which *Aspergillus* species hyphae are septate, smaller in width, and branch at more sharp angles. Mucormycosis can be treated with a combination of surgical debridement of the diseased region and systemic treatment of amphotericin B for three months if caught early. The care of the underlying disease is also critical in determining the treatment's success.<sup>19</sup>

### **OBJECTIVE** –

This study aimed to conduct a systematic review of the literature to determine the severity and co-relation of diabetes with mucormycosis.

### **METHODOLOGY** –

Keywords were used to search the articles from the databases of Google scholar, Pubmed, Cochrane upto August, 2021. All information of case reports and mucormycosis articles throughout the world was accessed for this review article.

### **RESULTS** –

All the cases with covid-19 and mucormycosis reported till august 2021 were reviewed for their association with diabetes. We got to know the percentage of diabetes if it is pre-existing or due to corticosteroids use. Also, we can assess if the severity of disease is related to blood sugar levels.

For Google Scholar and pubmed databases, we used a MeSH method and keywords to find articles. We found 1040 articles in the PubMed database using the MeSH technique. We removed 460 articles from PubMed due to irrelevant content and duplication. Before screening, we were left with 580 articles from PubMed. 563 articles were removed from the PubMed database due to poor quality, the lack of free text and inclusion-exclusion rules. On the basis of relevancy and full text, we chose 19 articles from the PubMed database. We used the Google Scholar database to make up for the missing articles. 'COVID-19', 'Mucormycosis' and 'Diabetes Mellitus' were utilised as keywords in the google scholar database.

### **DISCUSSION** –

The prevalence of mucormycosis in diabetic people in India is highlighted in this review article. According to this study, in individuals with diabetes, mucormycosis is a fatal and deadly illness having a significant death rate.<sup>1,17</sup>

Another reason for the link between COVID-19 and mucormycosis is the "endothelialitis" seen in people with severe COVID-19. According to autopsy studies, patients who died with COVID-19 had more serious vascular endothelial damage than those who died of influenza A. Multi-organ dysfunction patients who died had extensive endothelial damage, according to another postmortem study. Early phases in Mucormycosis include endothelial adhesion and penetration. Hyperglycemia causes spores of mucorales adhesin to coat the homologs of proteins and the glucose-regulated protein receptors of endothelium to be produced, resulting in a absolute storm for penetration to endothelium and enhanced Mucorales adherence.<sup>2</sup>

The Krichner and Smith criteria for the clinical diagnosis of mucormycosis, published in 1950, are still regarded the gold standard and include the following:

- i) Facial discomfort and Blood-tinged nasal discharge on the same side.
- ii) Necrotic, black turbinates readily misinterpreted for crusted, dried blood.
- iii) Ophthalmoplegia, Proptosis of eyeball and Ptosis of eyelid.
- iv) Pulpy peri-nasal or peri-orbital swelling with induration along with discoloration.
- v) Multiple cranial nerve palsies with no apparent cause.<sup>8</sup>

The most common fungal infection is mucormycosis in India. According to a computer model, the incidence is 140/million of population of mucormycosis in INDIA . The current increase in cases of mucormycosis is likely due to the country's high COVID-19 burden. In India, diabetes is the most common co-morbidity in Mucormycosis, accounting for 73.5 percent of cases. Mucormycosis is seen in about 1.6 instances per 1000 diabetic people.<sup>9</sup>

Mucormycosis has shown in COVID 19 for a variety of causes. COVID-19 and diabetes mellitus have a bidirectional association with negative effects. Diabetes is a pro-inflammatory condition that leads to poor SARS virus replication control and severe COVID infections.<sup>9</sup>

Five incidences of rhino-orbital mucormycosis were described in an Indian retrospective interventional investigation in which COVID-19-positive patients with uncontrolled diabetes were treated with systemic corticosteroids.

COVID-19 co-infections are becoming more recognized due to their influence on illness prognosis. According to a recent study, 8% of people have secondary fungal or bacterial infections, and 72% of people take broad-spectrum antibiotics, even though there is no sign of illness. Co-infections may be caused by a complex interaction of several variables, including the risk of hospital-acquired infections, immunosuppressive medication, and comorbidities.<sup>12</sup>

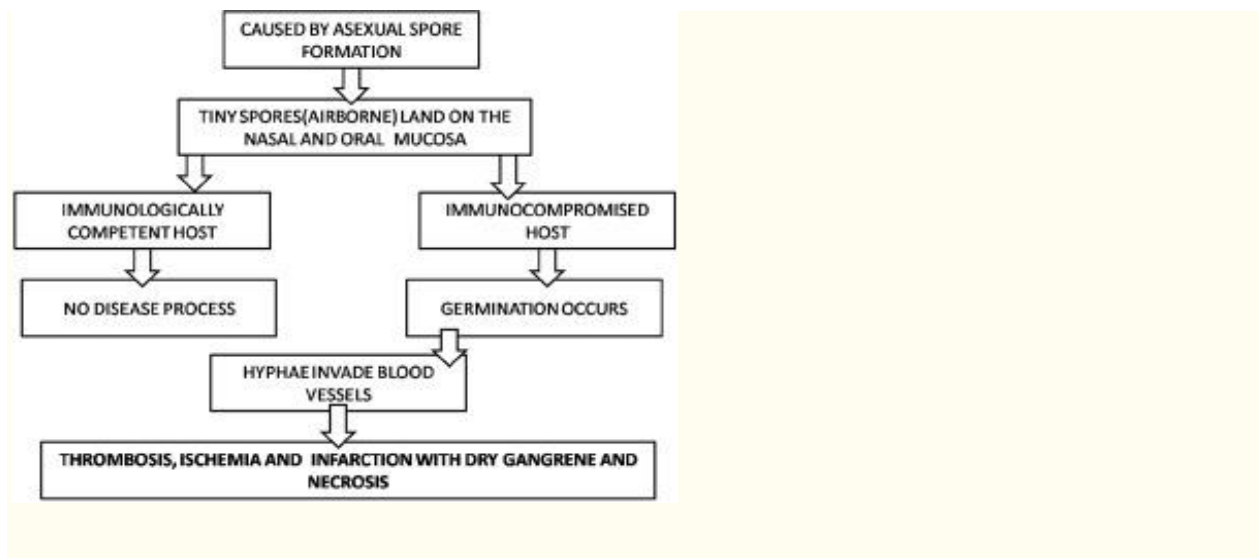
As a result, in patients with COVID and previously existing medical issues, it's critical to have a high index of suspicion and a low threshold for fungal co-infection. Suspected patients should also be submitted to immediate imaging and accurate diagnostic testing by multidisciplinary teams from otorhinolaryngology, infectious diseases, neurosurgery, critical care, ophthalmology, a pathology and microbiology. In cases of invasive cerebral mucormycosis, prompt diagnosis and treatment are critical, since a 6-day delay in diagnosis can increase the 30-day death rate to 66% from 35%.<sup>12, 13, 14</sup>

Therefore, immunomodulators and corticosteroids should be used with caution and evidence in COVID-19 individuals to prevent initiating and exacerbating fungal infections. Also, rhino-orbital mucormycosis morbidity and deaths are considerably reduced when detected early and treated appropriately in conjunction with multidisciplinary teams.<sup>12</sup>

Mucormycosis is a fungus that may be lethal, with ROCM being the most dangerous kind. Despite a thorough grasp of its pathogenicity, new diagnostic tools, and a variety of therapy choices, survival rates remain low.<sup>13</sup>

Antifungal treatment is a life-saving medical intervention in mucormycosis, and liposomal amphotericin B is the medication of choice. In the event of intolerance or a bad overall state, Posaconazole and Isavuconazole are the rescue medications. The recommendations also advocate surgical debridement in conjunction with antifungal treatment wherever possible, but caution against antifungal combination therapy. Combination therapy for mucormycosis, on the other hand, had amazing results in diabetic and leukemic patients.<sup>13</sup>

Asexual spore production causes mucormycosis infection. The minuscule spores go airborne, fall on the mucosa of the human mouth and nose. In the majority of immunocompetent hosts, a phagocytic response will limit the spread of these spores. If this reaction fails, germination and the formation of hyphae will occur. In immunocompromised patients, the infection persists because PMN leukocytes are less effective at eliminating hyphae. As the hyphae infiltrate arteries, they proliferate inside the artery lumens along with walls, producing ischemia, infarction, thrombosis, and dry gangrene of the afflicted tissues. Sepsis can develop from other organs like lung, brain through hematogenous spread [Chart 1].<sup>20-28</sup>



**Chart 1. Development of sepsis**

**CONCLUSION-**

This review article reflects on the clinical diagnostic strategy and management in such cases affected by covid-19. Antifungal treatment is a lifesaving medical intervention in mucormycosis, and liposomal amphotericin B is the medication of choice.

**Disclaimer regarding Consent and Ethical Approval:**

As per university standard guideline, participant consent and ethical approval have been collected and preserved by the authors

**REFERENCES**

1. Kumar M, Sarma DK, Shubham S, Kumawat M, Verma V, Singh B, Nagpal R, Tiwari RR. Mucormycosis in COVID-19 pandemic: Risk factors and linkages. *Curr Res Microb Sci.* 2021 Dec;2:100057. doi: 10.1016/j.crmicr.2021.100057. Epub 2021 Aug 8. PMID: 34396355; PMCID: PMC8349419.
2. John TM, Jacob CN, Kontoyiannis DP. When Uncontrolled Diabetes Mellitus and Severe COVID-19 Converge: The Perfect Storm for Mucormycosis. *J Fungi (Basel).* 2021 Apr 15;7(4):298. doi: 10.3390/jof7040298. PMID: 33920755; PMCID: PMC8071133.
3. Roglic G. WHO Global report on diabetes: A summary. *Int J Non-Commun Dis* 2016;1:3-8.
4. Reid G, Lynch JP 3rd, Fishbein MC, Clark NM. Mucormycosis. *Semin Respir Crit Care Med.* 2020 Feb;41(1):99-114. doi: 10.1055/s-0039-3401992. Epub 2020 Jan 30. PMID: 32000287.
5. Bonates P, João GAP, Cruz KS, Ferreira MS, Baía-da-Silva DC, Farias MEL, Brito-Sousa JD, Santana MF, Oliveira LA, Cortez ACA, Souza JVB, Lacerda MVG. Fatal rhino-orbito-cerebral mucormycosis infection associated with diabetic ketoacidosis post-COVID-19. *Rev Soc Bras Med Trop.* 2021 Jul 12;54:e03582021. doi: 10.1590/0037-8682-0358-2021. PMID: 34259759; PMCID: PMC8282253.
6. Singh V, Singh M, Joshi C, *et al* Rhinocerebral mucormycosis in a patient with type 1 diabetes presenting as toothache: a case report from Himalayan region of India
7. *Case Reports* 2013;2013:bcr2013200811.
8. AK AK, Gupta V. Rhino-orbital Cerebral Mucormycosis. [Updated 2021 May 1]. In: StatPearls [Internet]. Treasure Island (FL): StatPearls Publishing; 2021 Jan
9. Singh AK, Singh R, Joshi SR, Misra A. Mucormycosis in COVID-19: A systematic review of cases reported worldwide and in India. *Diabetes Metab Syndr.* 2021 Jul-Aug;15(4):102146. doi: 10.1016/j.dsx.2021.05.019. Epub 2021 May 21. PMID: 34192610; PMCID: PMC8137376.
10. Mishra Y, Prashar M, Sharma D, Akash, Kumar VP, Tilak TVSVGK. Diabetes, COVID 19 and mucormycosis: Clinical spectrum and outcome in a tertiary care medical center in Western India. *Diabetes Metab Syndr.* 2021 Jul-Aug;15(4):102196. doi: 10.1016/j.dsx.2021.102196. Epub 2021 Jul 3. PMID: 34246939; PMCID: PMC8253699.
11. Hayat M, Mushtaq S, Saba S, Saif R. Rhino-orbital-mucormycosis as a presenting manifestation of gestational diabetes mellitus. *Indian J Endocrinol Metab.* 2011 Jul;15(Suppl 1):S65-6. doi: 10.4103/2230-8210.83055. PMID: 21847460; PMCID: PMC3152181.
12. Ferry AP, Abedi S. Diagnosis and management of rhino-orbitocerebral mucormycosis (phycomycosis). A report of 16 personally observed cases. *Ophthalmology.* 1983 Sep;90(9):1096-104. doi: 10.1016/s0161-6420(83)80052-9. PMID: 6646648.
13. Shakir M, Maan MHA, Waheed S Mucormycosis in a patient with COVID-19 with uncontrolled diabetes *BMJ Case Reports CP* 2021;14:e245343.

14. Ahmadikia K, Hashemi SJ, Khodavaisy S, Getso MI, Alijani N, Badali H, Mirhendi H, Salehi M, Tabari A, Mohammadi Ardehali M, Kord M, Roilides E, Rezaie S. The double-edged sword of systemic corticosteroid therapy in viral pneumonia: A case report and comparative review of influenza-associated mucormycosis versus COVID-19 associated mucormycosis. *Mycoses*. 2021 Aug;64(8):798-808. doi: 10.1111/myc.13256. Epub 2021 Mar 5. PMID: 33590551; PMCID: PMC8013756.
15. Bhattacharyya A, Sarma P, Sharma DJ, Das KK, Kaur H, Prajapat M, Kumar S, Bansal S, Prakash A, Avti P, Thota P, Reddy DH, Gautam BS, Medhi B. Rhino-orbital-cerebral-mucormycosis in COVID-19: A systematic review. *Indian J Pharmacol* 2021;53:317-27.
16. Mekonnen ZK, Ashraf DC, Jankowski T, Grob SR, Vagefi MR, Kersten RC, Simko JP, Winn BJ. Acute Invasive Rhino-Orbital Mucormycosis in a Patient With COVID-19-Associated Acute Respiratory Distress Syndrome. *Ophthalmic Plast Reconstr Surg*. 2021 Mar-Apr 01;37(2):e40-e80. doi: 10.1097/IOP.0000000000001889. PMID: 33229953; PMCID: PMC7927902.
17. Dora E Corzo-León, Luis D Chora-Hernández, Ana P Rodríguez-Zulueta, Thomas J Walsh, Diabetes mellitus as the major risk factor for mucormycosis in Mexico: Epidemiology, diagnosis, and outcomes of reported cases, *Medical Mycology*, Volume 56, Issue 1, January 2018, Pages 29–43
18. Khanna M, Challa S, Kabeil A S, et al. (October 16, 2021) Risk of Mucormycosis in Diabetes Mellitus: A Systematic Review. *Cureus* 13(10): e18827. doi:10.7759/cureus.18827
19. Ashraf S. Ibrahim, Brad Spellberg, Thomas J. Walsh, Dimitrios P. Kontoyiannis, Pathogenesis of Mucormycosis, *Clinical Infectious Diseases*, Volume 54, Issue suppl\_1, February 2012, Pages S16–S22
20. Afroze SN, Korlepara R, Rao GV, Madala J. Mucormycosis in a Diabetic Patient: A Case Report with an Insight into Its Pathophysiology. *Contemp Clin Dent*. 2017 Oct-Dec;8(4):662-666. doi: 10.4103/ccd.ccd\_558\_17. PMID: 29326525; PMCID: PMC5754995.
21. Acharya S, Shukla S, Acharya N. Gospels of a pandemic-A metaphysical commentary on the current COVID-19 crisis. <https://doi.org/10.7860/JCDR/2020/44627.13774>.
22. Arora D, Sharma M, Acharya S, Shukla S, Acharya N. India in “Flattening the Curve” of COVID-19 Pandemic-Triumphs and Challenges Thereof. *Journal of Evolution of Medical and Dental Sciences*. 2020 Oct 26;9(43):3252-6. <https://doi.org/10.14260/jemds/2020/713>.
23. Bawiskar N, Andhale A, Hulkoti V, Acharya S, Shukla S. Haematological Manifestations of Covid-19 and Emerging Immunohaematological Therapeutic Strategies. *Journal of Evolution of Medical and Dental Sciences*. 2020 Nov 16;9(46):3489-95. <https://doi.org/10.14260/jemds/2020/763>.
24. Burhani TS, Naqvi WM. Telehealth--A Boon in the Time of COVID 19 Outbreak. *Journal of Evolution of Medical and Dental Sciences*. 2020 Jul 20;9(29):2081-5. <https://doi.org/10.14260/jemds/2020/454>.

25. Butola LK, Ambad R, Kute PK, Jha RK, Shinde AD, DMIMS W. The Pandemic of 21st Century-COVID-19. *Journal of Evolution of Medical and Dental Sciences*. 2020 Sep 28;9(39):2913-9. (September 28, 2020): 2913–18. <https://doi.org/10.14260/jemds/2020/637>.
26. Dasari V, Dasari K. Nutraceuticals to Support Immunity: COVID-19 Pandemic-A Wake-up Call. *Journal of Clinical & Diagnostic Research*. 2020 Jul 1;14(7). <https://doi.org/10.7860/JCDR/2020/44898.13843>.
27. Dhok A, Butola LK, Anjankar A, Shinde AD, Kute PK, Jha RK. Role of Vitamins and Minerals in Improving Immunity during Covid-19 Pandemic-A Review. *Journal of Evolution of Medical and Dental Sciences*. 2020 Aug 10;9(32):2296-301. <https://doi.org/10.14260/jemds/2020/497>.
28. Ghungrud, D., Sharma, R., Singh, S. and Ankar, R. (2021) “A Rare Case of Pansinusitis Fungal Mucormycosis with Orbital Involvement in Post COVID-19 Patient and Its Treatment”, *Journal of Pharmaceutical Research International*, 33(44B), pp. 114-118. doi: 10.9734/jpri/2021/v33i44B32656.

UNDER PEER REVIEW