

PERTROCHANTERIC FRACTURE NECK OF THE FEMUR PRESENTING AS AVASCULAR NECROSIS WITH GAIT ABNORMALITY - A CASE

ABSTRACT

The pertrochanteric femoral fracture is a highly common kind of femoral fracture. It is generally the consequence of a fall. A high-energy mechanism, such as a motor vehicle accident, is more likely to cause Pertrochanteric fractures in 16-30 year age group people. A 45year old man had a history of a bike crash that resulted in a pertrochanteric fracture of the right hip 2 years back, for which he was operated. The patient right now came to the AVBRH with the complaint of right hip discomfort and edema after surgery and was referred for physiotherapy. Avascular necrosis of the femoral head is a pathological condition that occurs when the blood supply to the bone is cut off, and it is a common consequence of fractures, dislocations, and other injuries and especially occurs in adult post road traffic accidents.

Key Words: Fracture, edema, avascular necrosis, blood supply, pertrochanteric.

REPORT.

INTRODUCTION:

Avascular necrosis of the femoral head is followed by a reduction in blood supply to bone tissue. If the condition is not addressed, it worsens over time. The inferior metaphysical and lateral epiphysial vessels are the two basic types of vessels that nourish the femoral head's perimeter. The common reason for femoral head avascular necrosis is damage to the lateral epiphysial arteries. This consequence is more common in intracapsular hip fractures than extracapsular hip fractures. If the condition is not addressed, it will worsen over time, eventually leading to femoral head collapse and severe arthritis. Non-traumatic occurrences such as steroid therapy,

excessive alcohol use, blood coagulation difficulties, and any other intimacy that results in inadequate blood flow to the femoral head in the youth population can induce avascular necrosis(1). Avascular necrosis of the femoral head (AVN) is a painful condition that impairs a young adult's function, mobility, and quality of life. Its pathophysiology includes femoral head blood circulation disturbance and bone ischemic field(2). As the world's ageing population grows, hip fractures are gaining a lot of attention. For internal fixation of pertrochanteric/intertrochanteric fractures, surgeons currently are using cephalomedullary nails as an implant(3). Complications such as nonunion and osteonecrosis of the femoral head (ONFH) can readily arise following fracture due to the anatomical structure and biomechanical features of the femoral neck, resulting in significant disability and mortality. Due to the increased rate of traffic accidents, femoral head necrosis is becoming more significant in adults(4). Bone scans are simple and inexpensive to do, and cold uptake can be used to predict the incidence of ONFH. This can be determined as early as two weeks post surgery, which could be useful in assessing patients' treatment progress and determining future treatment strategies(5).

CASE REPORT:

Due to an unintentional fall off his bike, a 45-year-old man reported to the casualty with severe right hip pain and difficulty walking. A typical emergency anteroposterior radiograph (Fig. 1) revealed an Evans type II pertrochanteric fracture of the right hip. The patient was operated on with a dynamic interlocking trochanteric gamma nail (Fig. 2). Neither the procedure nor the recovery was marred by problems. The patient was able to walk unaided after three months of the operation. On radiographs, the right hip fracture had healed after six months (Fig. 3). With no recent trauma, the patient exhibited minor pain and limited joint mobility two years following the operation. The recent x-ray of the patient is showed in (fig. 4) suggesting of avascular necrosis of the right femoral head and implant sensitivity. Therefore the implant was removed and then after the removal of implant soon physiotherapy was started.

CLINICAL FINDING :

Proper informed consent was taken from the patient. The patient was conscious and well oriented to time, place and person. The patient was in supine position. The patient was mesomorphically built and had no history of alcohol intoxication or tobacco chewing. He was an attendant in engineering college by profession. He was not a known case of diabetes, hypertension, asthma or tuberculosis.

On examination, temperature was normal, pulse was 76 beats per minute pulse, respiratory rate was 21 beats per minute and blood pressure was 120/80 mmHg.

The patient was alert and aware of time, place, and person. The temperature was normal, the pulse was 76 beats per minute, the respiration rate was 21 beats per minute, and the blood pressure was 120/80 mmHg on physical examination.

Pain assessment was done on the Visual analog scale and the score was 7/10. On inspection, the patients right leg was affected due to a road traffic accident, there was a scar mark present at the anterior aspect of the hip joint and the range of motion was affected due to pain. There was stiffness present at the hip joint and the patient had difficulty in walking and ascending of stairs.

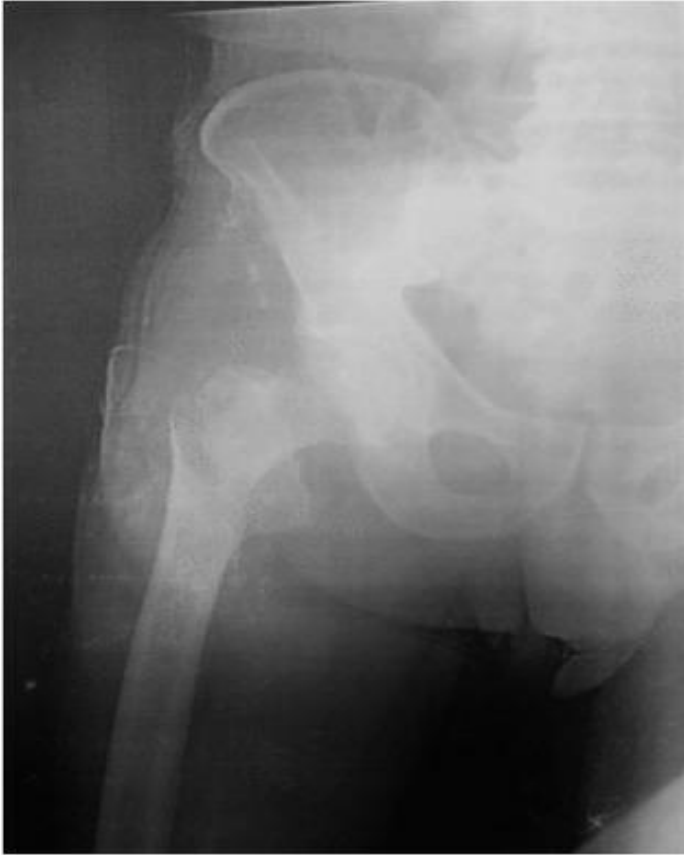

Fig 1.

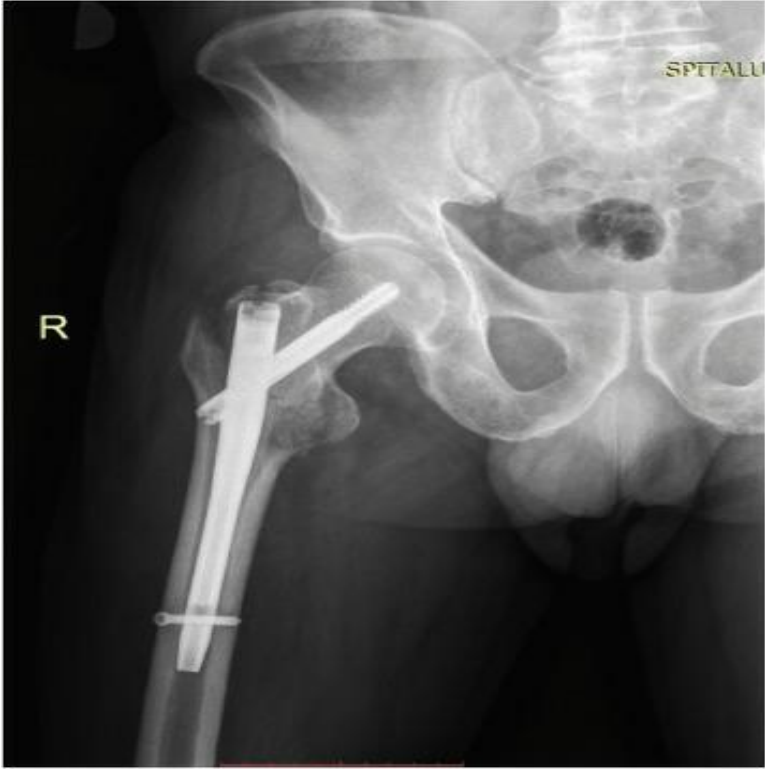


Fig 2.

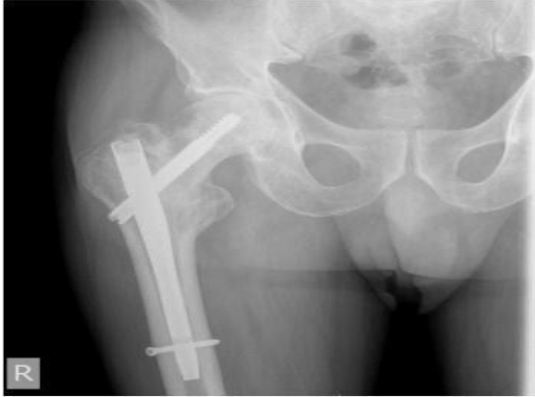

Fig 3.

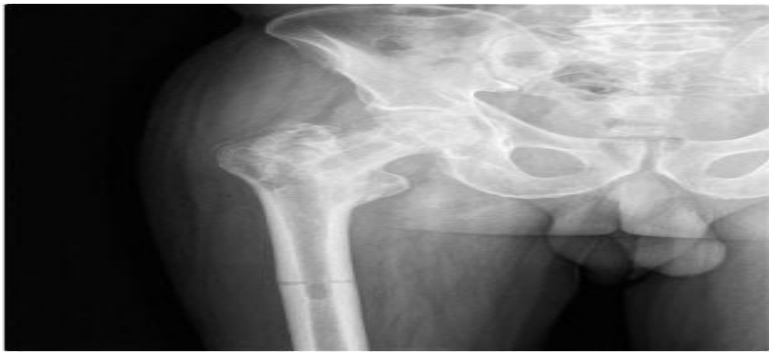

Fig.4

Physiotherapy Management :

Non-weight-bearing phase: After the surgery exercises to the ankle and foot were given, along with isometrics to the quadriceps and hamstrings were begun.

After reduction of pain isometrics to the glutes were started.

Gentle mobilization in the form of relaxed passive movement was initiated gradually and then worked up to the maximal pain-free range.

Isometrics with longer holds helps in minimising muscle atrophy. After regaining a good range of motion isotonic exercises were started including all movements of the hip joint and then progressed to isokinetic exercises.

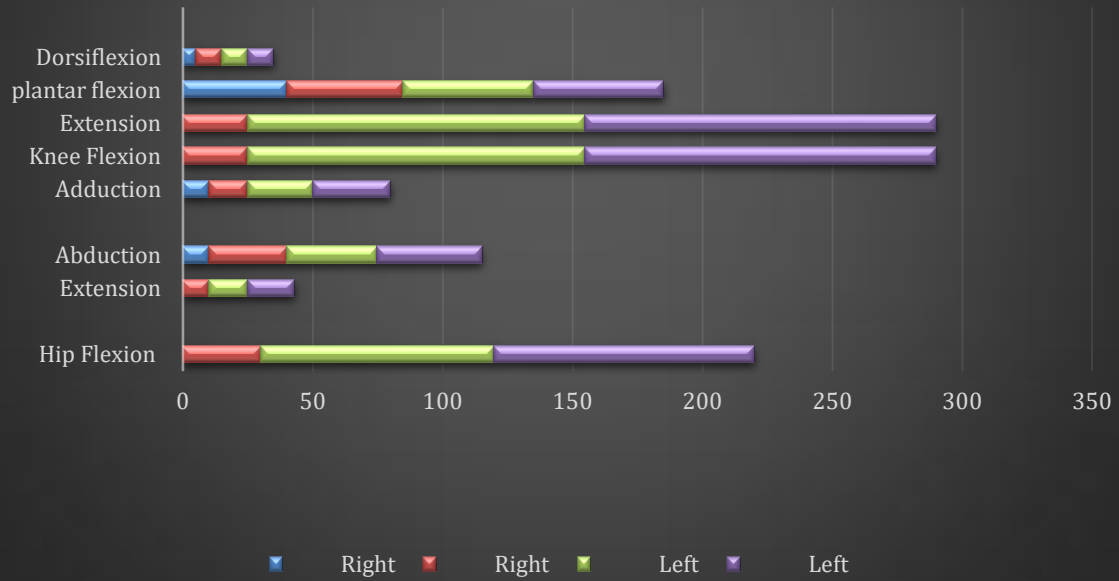
Weight-bearing-phase: Weight-bearing was taught in standing with axillary crutches and a walker. Gradually weight transfers on one leg were taught.

Four-point crutch walking was initiated to minimize weight on the hip joints.

After reduction of pain one crutch was discarded. The exercise programme was also progressed to improve the strength and endurance of the muscles at the hip and knee joints. Proper gait training was given, after an acceptable gait and balance achieved by the patient ambulation was progressed to a single cane without compromising the pattern of gait.

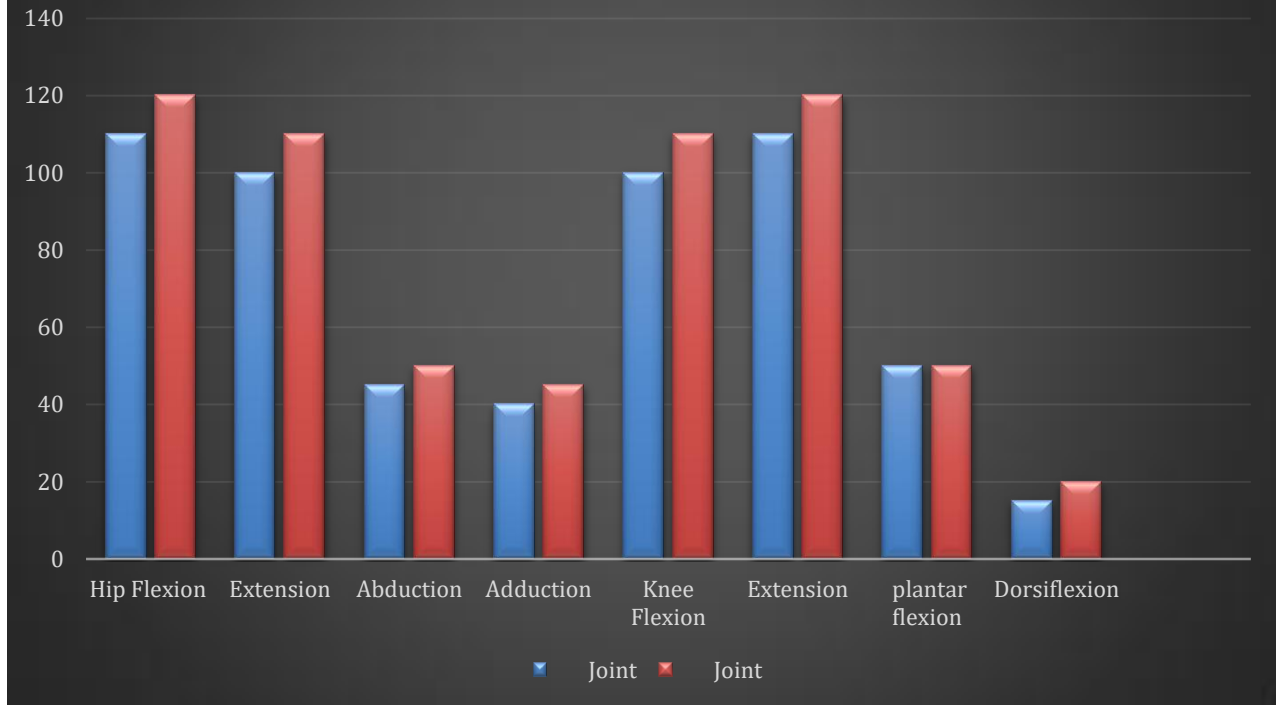
Adequate independence in functional activities is regained by 12-16 weeks post-surgery.

Range of motion assessment pre physiotherapy rehabilitation



Exercise protocol	Duration and Frequency	Rationale
	Phase A: non- weight-bearing phase	
Ankle toe movements	10 repetitions 3 times a day	To prevent pedal oedema
Isometrics to quadriceps, hamstrings and glutes	10 repetitions with 5 sec hold for 3 times a day	To minimize muscle atrophy and maintain contractility of the muscle
Strengthening exercises to hip, knee and ankle	10 repetitions with 5 sec hold for 3 times a day	To improve muscle strength and endurance
	Phase B: weight bearing phase	
Ambulation with walker	For 10 mins 3 times a day.	To improve the patient's functional independence and pulmonary circulation.

Rom assessment post physiotherapy rehabilitation



Home Program :

Active Range of motion exercises, bilateral upper limb strengthening, pursed lip breathing, static and dynamic hamstrings and quadriceps, ankle toe movements , walking with crutches was educated to the patient as well as to the family members.

DISCUSSION:

Avascular necrosis affects young people, most of them are males(6). Joint or bone injuries (femoral neck fractures, hip dislocation), certain drugs and idiopathic symptoms (which account for 25% of cases) are the most prevalent causes of this condition (7). Avascular necrosis after pertrochanteric fractures is a fairly uncommon complication that occurs in 0.3 percent to 0.5 percent of patients (8). In a thorough investigation, it was discovered that this condition occurred in 1.37 percent in patients undergoing trochanteric fracture surgery within the first two years of injury (9). A loss of blood flow in the metaphyseal cancellous bone causes intertrochanteric fractures (10). As a result of a nail insertion, an adolescent with a femoral diaphyseal fracture developed avascular necrosis of the femoral head (11). No investigations have indicated that mechanical failure may produce avascular necrosis, even if a brief ischemic episode occurs after surgery (12). The femoral head avascular necrosis can be treated in a variety of methods. Weight-bearing on the afflicted hip joint may result in spontaneous remission of osteonecrosis if the condition is asymptomatic and the lesion is modest(13). Accidents involving slips and falls are linked to 87 percent of hip fractures in the elderly . Falls in the elderly are connected with factors such as muscular weakening, decreased postural control, and balance(14). Piriformis stretching will help the patient which will allow him to reduce discomfort, increase strength and reintegrate into everyday activities(15). Weight-bearing exercise in quadruped posture was found to be beneficial for improving weight-bearing and proprioception, as well as for correct ambulation(16). Hamstring tightness is a rather frequent problem. Injuries are frequently related with poor hamstring flexibility. Both active release method and muscular energy technique assist patients improve their hamstring flexibility and discomfort (17). Early mobilisation and complete weight bearing in femur fracture patients often result in rapid recovery of the patient(17).

CONCLUSION

Avascular necrosis of the femoral head is an unusual condition that cannot be predicted or prevented following pertrochanteric fractures. Patients with risk factors should be closely monitored and treated as soon as possible if osteonecrosis advances. Uncemented total hip arthroplasty is the best surgical option in advanced stages, followed by physiotherapy rehabilitation. From the findings it can be concluded that physiotherapy plays an important role in the management of pertrochanteric fracture patients followed by avascular necrosis .

Conflict of interest: The authors have no conflict of interest.

Informed consent: Informed consent has been obtained from the patient included in the study.

Funding : Nil

Acknowledgement: Authors are grateful for the patient's active support and also thank to his care givers for there time and support.

References

1. Ficat RP. Idiopathic bone necrosis of the femoral head. Early diagnosis and treatment. *J Bone Joint Surg Br.* 1985 Jan;67(1):3–9.
2. Salas AP, Mazek J, O'Donnell J, Mendez-Perez E, Brizuela-Ventura M, Velasco-Vazquez HA, et al. Hip Arthroscopy and Core Decompression for Avascular Necrosis of the Femoral Head Using a Specific Aiming Guide: A Step-by-Step Surgical Technique. *Arthrosc Tech.* 2021 Dec;10(12):e2775–82.
3. Chang S-M, Hou Z-Y, Hu S-J, Du S-C. Intertrochanteric Femur Fracture Treatment in Asia: What We Know and What the World Can Learn. *Orthop Clin North Am.* 2020 Apr;51(2):189–205.
4. Wang Y, Ma J-X, Yin T, Han Z, Cui S-S, Liu Z-P, et al. Correlation Between Reduction Quality of Femoral Neck Fracture and Femoral Head Necrosis Based on Biomechanics. *Orthop Surg.* 2019 Apr;11(2):318–24.
5. Noh JH, Lee JY, Hwang S, Lee KH. Prediction of femoral head avascular necrosis following femoral neck fracture: “pin-tract sign” of 99mTc-HDP pinhole bone scan after metallic fixation. *Hip Int.* 2020 Sep;30(5):641–8.
6. Atsumi T, Kuroki Y. Role of impairment of blood supply of the femoral head in the pathogenesis of idiopathic osteonecrosis. *Clin Orthop Relat Res.* 1992 Apr;(277):22–30.
7. Khan SH. Imaging avascular necrosis of bone: “The shifting paradigm.” *Indian J Nucl Med.* 2016;31(1):1–2.
8. Baixauli EJ, Baixauli F, Baixauli F, Lozano JA. Avascular necrosis of the femoral head after intertrochanteric fractures. *J Orthop Trauma.* 1999 Feb;13(2):134–7.

9. Barquet A, Mayora G, Guimaraes JM, Suárez R, Giannoudis PV. Avascular necrosis of the femoral head following trochanteric fractures in adults: a systematic review. *Injury*. 2014 Dec;45(12):1848–58.
10. Gupta V, Kaplia A, Kaur M, Kundu ZS, Singh D. Traumatic anterior hip dislocation in a 12-year-old child. *Chinese Journal of Traumatology*. 2013 Apr 1;16(2):122–5.
11. O'Malley DE, Mazur JM, Cummings RJ. Femoral head avascular necrosis associated with intramedullary nailing in an adolescent. *J Pediatr Orthop*. 1995 Feb;15(1):21–3.
12. Necrosis of the femoral head after fixation of trochanteric fractures with Gamma Locking Nail - *Injury* [Internet]. [cited 2022 Jan 23]. Available from: [https://www.injuryjournal.com/article/S0020-1383\(02\)00171-7/fulltext](https://www.injuryjournal.com/article/S0020-1383(02)00171-7/fulltext)
13. Cheng EY, Thongtrangan I, Laorr A, Saleh KJ. Spontaneous resolution of osteonecrosis of the femoral head. *J Bone Joint Surg Am*. 2004 Dec;86(12):2594–9.
14. Revision of total hip replacement surgery in elderly patient and its recovery based on periprosthetic fracture rehabilitation [Internet]. [cited 2022 Jan 23]. Available from: http://www.discoveryjournals.org/medicalseience/current_issue/v24/n104/A114.htm
15. BiblioMed.org - Deposit for Medical Articles [Internet]. [cited 2022 Jan 23]. Available from: <https://www.bibliomed.org/?term=MITUSHI%20DESHMUKH&sarea=author&b1=Search+ScopeMed>
16. A case of fracture shaft femur in a patient with transtibial amputation Dhankar S, Bele A - *J Datta Meghe Inst Med Sci Univ* [Internet]. [cited 2022 Jan 23]. Available from: <http://www.journaldmims.com/article.asp?issn=0974-3901;year=2019;volume=14;issue=4;spage=394;epage=396;aulast=Dhankar>
17. Gaur VV, Kapoor AA, Phansopkar PA. Short Term Effects of Muscle Energy Technique vs. Active Release Technique in Improving Hamstring Flexibility and Pain in Patients with Acute Anterior Cruciate Ligament (ACL) Tear - A Randomized Control Trial. *jemds*. 2021 Jan 18;10(3):137–42.

