

HOLISTIC APPROACH VIA PHYSIOTHERAPEUTIC INTERVENTION IN A COMPLEX MULTIPLE FRACTURE HAMPERING A MIDDLE- CLASS MAN'S LIFE- A CASE REPORT

Abstract:

Ankle fractures contribute to almost nine percent of all fractures of the weight-bearing joints, with uni, bi, and trimalleolar fractures being the most prevalent. Weber's and (AO/ASIF) classifications are commonly used for easy analysis. Tibial plateau fractures can range in severity from stable to severely comminuted unstable fractures with extensive tissue injury, putting the extremities' at risk, according to the Schatzker grading system. The ulna is a long bone in the forearm that extends parallel to the radius and travels medially. The severity of proximal ulna fractures ranges from basic AO/OTA Classification fractures to severe Monteggia fractures or Monteggia-like lesions. After a road accident, a 35-year-old man with compound grade 3B ankle dislocation, Schatzker type 1 fracture of tibia, and proximal 1/3 ulnar shaft fracture of the left side were diagnosed on x-ray with external application of a delta fixator over the ankle, open reduction and internal fixation on the tibial plateau with screws and the nail was impacted over the ulna fracture. After the procedure, the patient was treated with physical therapy for 12 weeks, beginning with static regimens and proceeding to dynamic exercises, electrotherapeutic modalities, strengthening exercises, and gait exercises. The purpose of this study was to explore potential favorable rehabilitation effects in the use of exercises following operatively treated unstable ankle fractures requiring partial weight-bearing in the first six postoperative weeks.

Conclusion: It could be shown that Immediate Postoperative Physical Therapy protocol in a proper scheduled manner helped the Patient to return to his daily activities with improved ranges, strength, and motivation to work again without any difficulties.

Keywords – Ankle fractures, Schatzker Classification, Delta fixator, Physical Therapy, Postoperative Rehabilitation.

Abbreviations:

CPM-Continuous Passive Motion

ORIF- Open Reduction Internal Fixation

NPRS- Numerical Pain Rating Scale

NT- Not-Testable

VAC-Vacuum-assisted closure

VMO-Vastus Medialis Oblique

VAS- Visual Analog Scale

INTRODUCTION

Ankle fractures contribute to almost nine percent of all fractures of the weight-bearing joints, with uni, bi, and trimalleolar fractures being the most prevalent(1). Ankle fracture-dislocations are more common in young males and are caused by vehicle accidents, sports injuries, or falls(2). These injuries are typically caused by trauma with high energy(2)(3). Mortise fractures or syndesmotic disruption, the total displacement of the tibial astragaloid joint, capsuloligamentous structural instability, and significant soft-tissue injury are the most prevalent ankle injuries(4). The radiographic classifications Danis-Weber and Association for Osteosynthesis/Association for the Study of Internal Fixation are simple to employ daily and in clinical settings. (5) Fractures are classified as infratransyndesmotic or suprasyndesmotic in the DanisWeber classification. The AO/ASIF also includes information on the involvement of the medial and posterior malleoli. As a result, the AO/ASIF categorization is quite useful (6). Tibial plateau fractures can range in severity from stable to severely comminuted unstable fractures with extensive tissue injury, putting the extremities' survival in jeopardy(7) (8). **The ulna is a** long bone in the forearm that runs medially and parallel to the second forearm bone, the radius, and functions as a stabilizing bone, with the radius turning to give mobility(9)(10). The severity of proximal ulna fractures ranges from basic AO/OTA Classification to severe Monteggia fractures or Monteggia-like lesions including damage to the elbow's supporting components(11). These fractures can occur at any age in the upper extremity, they are most prevalent in people in their

seventh decade(9).To reestablish unrestricted elbow function, anatomical restoration of ulnar alignment must be the primary focus of surgical therapy(12).

Postoperative non-weight-bearing and immobilization following an unstable traumatic ankle fracture emphasize the need of reducing stresses at the fracture site to limit the risk of subsequent fracture displacement and hardware failure(13). Immobilization, on the other hand, can be linked to a reduced range of motion, ankle stiffening, and muscular weakness(14). Early mobility, on either hand, is thought to be critical for most fractures' healing, as well as minimizing joint stiffness and problems associated with extended immobilization, which may also help to speed up recovery and enhance overall function and quality of life (15). Joint manipulation, gradual exercise performance, gait training plan, electrotherapy, and good health education have all been demonstrated to be useful in physiotherapy rehabilitation (16) (17).

Patient's information:

On September 3, 2021, at 6:00 p.m., a 35-year-old male with right-handed dominance, who is a chef by profession, was injured in a road traffic collision while his way back home on a two-wheeler, and his bike was hit in the front by a four-wheeler. The patient was knocked from his bike and passed out as a result of the incident. He had no recollection of the incident after that. Passers-by on the road assisted him and phoned the police station, which dispatched an ambulance to transport him to the AVBRH emergency room at 7:30 p.m. Someone contacted the patient's house from his phone, and his family arrived by 8:00 p.m. There was a history of loss of consciousness from the moment he fell till hospitalization. He was diagnosed with Compound grade 3B Ankle joint dislocation with lateral condyle fracture proximal tibia schatzker type 1 left side and proximal 1/3 ulna shaft fracture left side. On 05-09-2021, a fractured lateral condyle of the tibia was seen under the c arm. Condyles were kept together using patellar clamps, and two guide wires were inserted through the proximal tibia and were later removed. The reduction was carried out beneath the c arm and was deemed to be acceptable, with the VAC application an external delta fixator was applied. Under the c-arm, the talus was reduced and seen. On September 6, 2021, there was ORIF of the proximal 1/3 shaft of the left ulna fracture. A 4mm square nail was impacted. The reduction shown beneath the c arm was deemed to be satisfactory. A 90-degree flexion slab was applied above the elbow, and a sterile dressing was applied. Following surgery, physical rehabilitation sessions began. Pain, swelling, discomfort,

and stiffness at the fracture site and suture site at the elbow, as well as pain at the ankle and a wound over the left ankle, were the patient's major complaints following surgery. The pain was dull and painful, rated an 8/10 on the NPRS at rest and a 9/10 while moving slightly. The patient is unable to walk because he was unable to lift his leg off the bed.

Clinical findings:-

The patient signed a written consent form. Physical examination and treatments were explained to the patient. On general examination, the patient appeared to be awake, well-oriented in terms of time, location, and person, and cooperative. The patient was hemodynamically stable, afebrile, and had a blood pressure of 129/76 mm Hg, a pulse rate of 74 beats per minute, and a respiratory rate of 19 breaths per minute. There were no signs of cyanosis, icterus, clubbing, or edema in the patient. In a supine posture, the patient was examined. The patient's left leg was gently raised on a pillow during the examination, and an external Delta fixator was attached to the ankle with VAC. Joints in the knees and hips are in a neutral posture. Near the ankle and the tibial tuberosity, there are scars and abrasions. On palpation temperature was normal. The swelling was visible throughout the knee and ankle. Tenderness of grade 2 was found on bony landmarks below the knee. On both limbs, range of motion and muscular strength were measured and compared. All sensations and reflexes were intact on neurological evaluation. There was no difference in limb length. X-rays are taken before and after surgery, as well as clinical pictures are shown in figure 1, 2, 3, 4, 5, 6

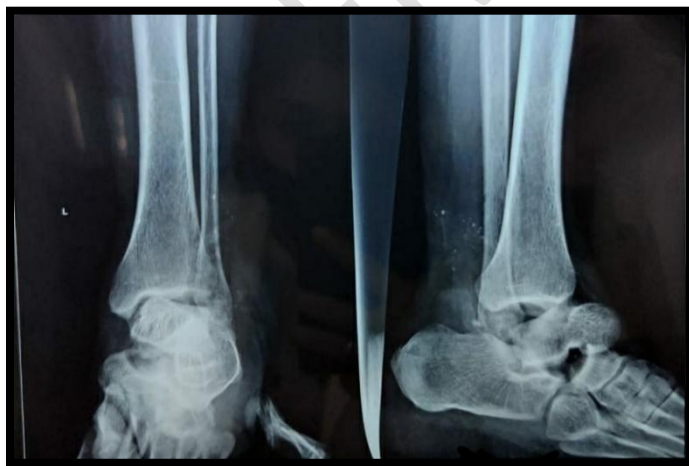

Figure 1 Pre-operative X-Ray of Compound grade 3B Ankle joint dislocation

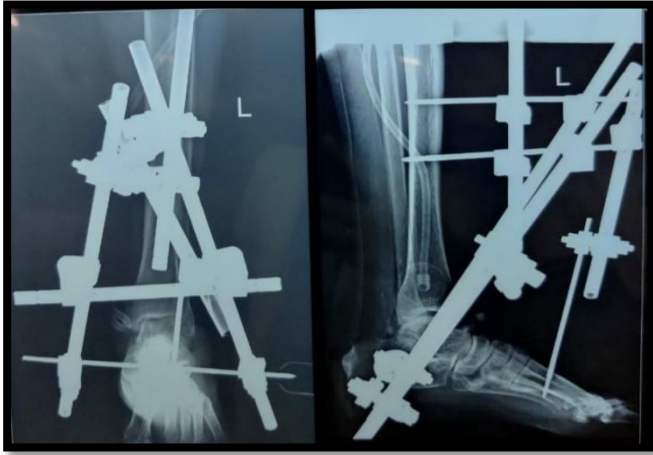


Figure 2: Post-operative X-Ray of Delta fixator on Ankle joint

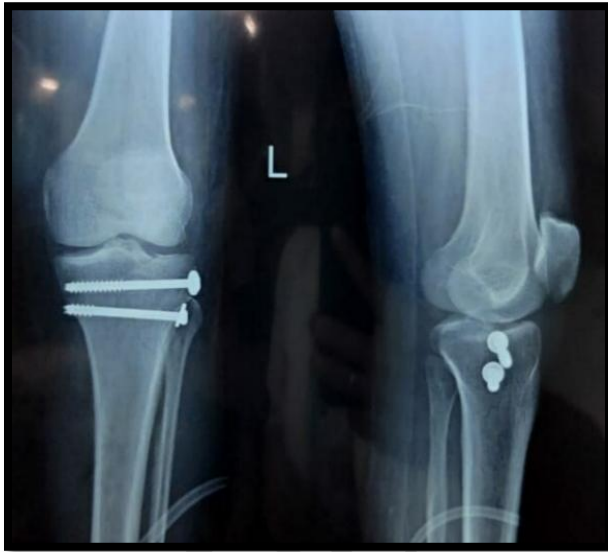

Figure 3 Post-operative X-Ray of tibial condyle where the screw was inserted from lateral to medial.

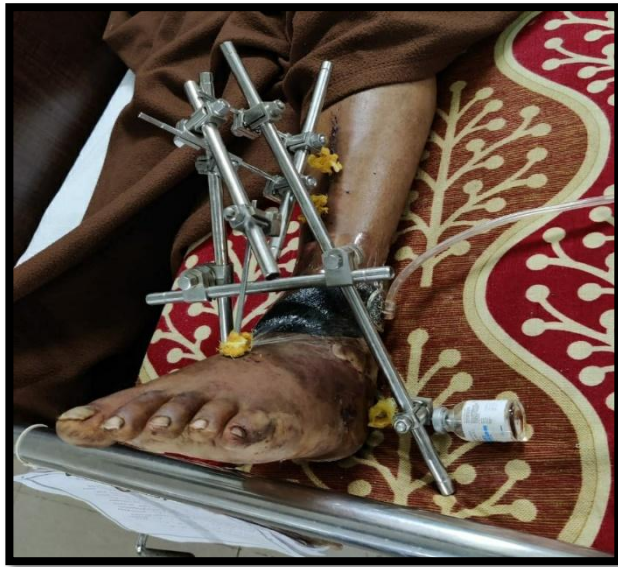

Figure 4 Post-operative clinical presentation of the ankle joint by using delta fixator

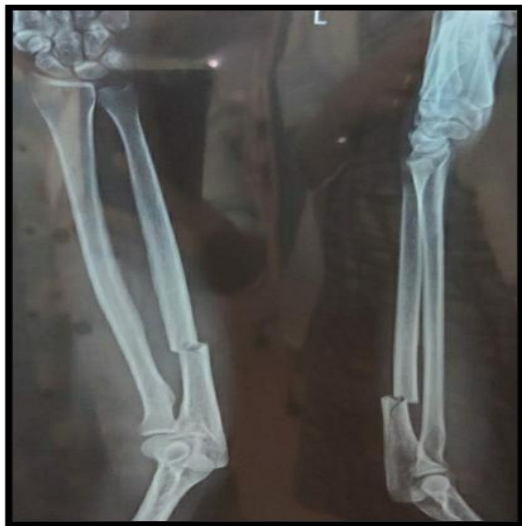

Figure 5 Pre-operative X-Ray of proximal 1/3 shaft of ulna fracture left side

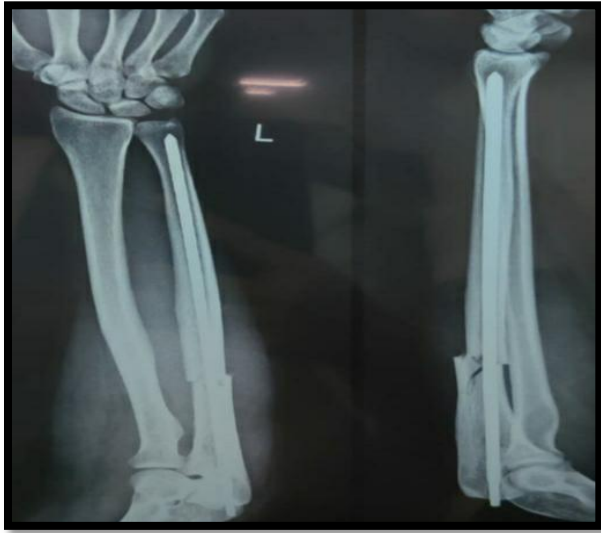

Figure 6 Post-operative x-ray of Open reduction Internal fixation for ulna shaft fracture.

Table 1: Timeline

OCCURRENCES	DATES
Date of Injury:	03-09-2021
Date of surgery:	05-09-2021 06-09-2021
Starting of physiotherapy rehabilitation:	08-09-2021
Date of Cast and fixator removal (2 rings)	11-10-2021
Whole fixator removal	25-10-2021

Initial Examination Finding:

Joint movement	Left		Right		
	Active	Passive	Active	Passive	
Shoulder joint	Flexion	0-160°	0-170°	0-160°	0-170°
	Extension	0-40°	0-50°	0-40°	0-50°
	Abduction	0-160°	0-170°	0-160°	0-170°
	Adduction	160°-0	170°-0	160°-0	170°-0
	Internal rotation	NT	NT	0-40°	0-45°
	External rotation	NT	NT	0-90°	0-90°
	Elbow joint	Flexion	NT	NT	0-140°
Extension		NT	NT	140° -0	150° -0
Forearm	Supination	NT	NT	0-90°	0-90°
	Pronation	NT	NT	0-90°	0-90°
Wrist joint	Flexion	NT	NT	0-80°	0-90°
	Extension	NT	NT	0-60°	0-70°
	Radial deviation	NT	NT	0-20°	0-25°
	Ulnar deviation	NT	NT	0-30°	0-40°
Hip joint	Flexion	0-40°	0-50°	0-100°	0-100°
	Extension	0-15°	0-20°	0-25°	0-30°
	Abduction	0-30°	0-35°	0-45°	0-45°
	Adduction	30°-0	35°-0	45° -0	45° -0
	Internal rotation	0-20°	0-20°	0-40°	0-40°
	External rotation	0-20°	0-20°	0-40°	0-45°
Knee joint	Flexion	0-30°	0-35°	0-130°	0-135°
	Extension	30 °-0	35°-0	130° -0	135° -0
Ankle joint	Plantar flexion	NT	NT	0-40°	0-45°
	Dorsiflexion	NT	NT	0-20°	0-20°
	Inversion	NT	NT	0-30°	0-35°
	Eversion	NT	NT	0-15°	0-15°

Table 2: Range of motion assessment on day one of physiotherapy treatment

TABLE 3: Manual muscle testing on day one

JOINTS	LEFT SIDE	RIGHT SIDE
HIP		
Flexors	4/5	5/5
Extensors	4/5	5/5
Abductors	4/5	5/5
Adductors	4/5	2/5
Internal Rotators	3/5	5/5
External Rotators	3/5	5/5
KNEE		
Flexors	2/5	5/5
Extensors	2/5	5/5
ANKLE		
Plantarflexors	NT	5/5
Dorsiflexors	NT	5/5

Therapeutic Intervention:

For optimum recovery, precise post-operative care is critical. The physiotherapist's functional purpose is to regain and normalize daily living activities.

Short-term goals: Patient education, To reduce edema, To reduce the pain on the NPRS, To prevent hazards of bed rest, To increase the functional range of motion, To increase the strength of muscles on evaluation by manual muscle testing.

Long-term goals: Prevent the deformity at the joints, Achieve full weight-bearing bilaterally, improve endurance capacity of patient Assist the patient in gaining independent living in activities of daily life, such as independent walking without the need of mobility aids.

Phase 1: [Zero to Two Weeks] Chest physiotherapy was prescribed to minimize hospital-acquired pneumonia and enhance inspiratory lung capacity. Spirometry and breathing exercises were used to achieve this goal. For ten minutes, cryotherapy was used to minimize inflammation and swelling. For edema reduction, RICE PROTOCOL is recommended, which stands for Rest, Ice, Compression, and Elevation. A cast was applied at 90-degree elbow flexion for stabilization and the healing process. Begin range of motion activities and prehension exercises for the left upper extremity (with the cast on), as well as all active exercises for the right upper limb. Teach the patient functional adaptations, such as using the unaffected extremity for self-care. To maintain proper blood circulation and prevent complications in the lower limb, strong ankle and toe motions were prescribed. To avoid extension lag, keep the limb in extension (with the heel or lower leg resting on a pillow). 10 repetitions of active assisted left hip and knee ROM exercises twice a day. With weight cuffs, perform a complete range of motion actively resisted right lower and upper extremity movements. Isometric exercises for quadriceps, calves, and glutei muscles with 10 repetitions and 10-second holds. VMO activation with static exercises which initiate end range extension. All of the workouts were done twice a day. Non-weight bearing with a walker was used to begin gait training.

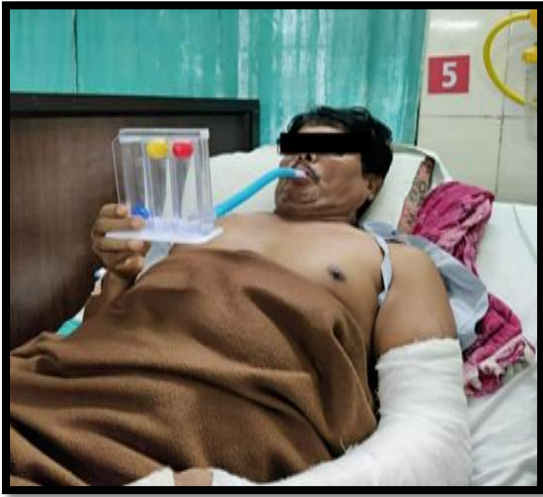

Figure 7: Patient performing Spirometry,
Upper limb in a cast.

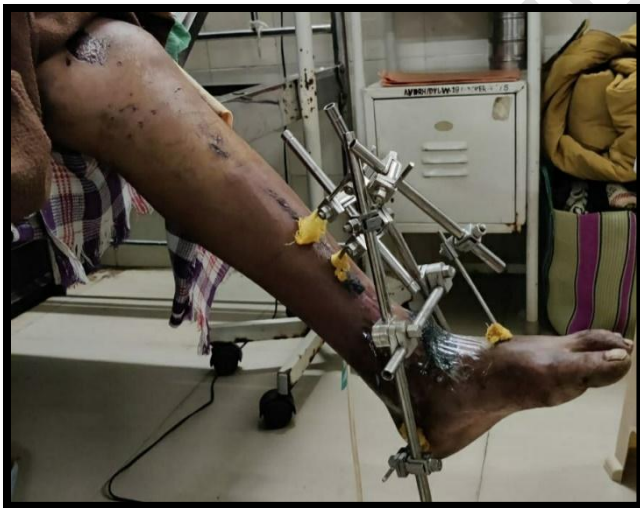

Figure 8: Patient performing active lower limb movement

Phase 2: [Two to Six Week] Many aspects of the phase one regime have been maintained as needed. The active and active-assistive ranges of motion in the left shoulder were initiated. Isometric flexion and extension exercises for the elbow and wrist. Isotonic digit exercises, Daily

routines: Uses the affected limb for self-care and stability. To initiate weight-bearing, just 10% of the body weight was used. The advancement of phase 1 rehabilitation was added in phase 2 to enforce the weight-bearing activities. Cryotherapy has remained effective at reducing inflammation. Stabilization Efforts in the core have been completed. **Strengthening of the unaffected right upper and lower extremities was carried out with the help of practicing active movements with half kg weight cuffs.** The non-weight bearing activities were continued and progressed into separate assessment tasks, including monitoring. Active and aided movement of the back, hip, knee, and ankle with 10 repetitions and 10-second holds. Three-point gait with crutch or walker suggested toe-touch weight-bearing were started.

Phase 3: [Six to Eight Weeks]: Swelling had reduced by this time, but discomfort remained, which was controlled by using a hydro collar pack for 10-15 minutes. It had aided in the induction of relaxation and the reduction of discomfort. The same phase-2 exercises were carried out again. After a gentle elbow mobilization, the myofascial release was given to the fascia, which was in a contraction state following the removal of the cast. Isometric flexion and extension exercises for the elbow and wrist. In a supine position, active aided ROM was gradually introduced within a pain-free range. CPM and other modalities were utilized to improve knee range of motion. Quadriceps and hamstrings were delivered electrotherapy accelerated faradic stimulation to help recruit muscle fibers for functional training. Beginning with passive movement and progressing to the patient's tolerance, range of motion exercises included heel slides, hip flexion, abduction, ankle plantarflexion, and dorsiflexion of an afflicted extremity. To counteract the muscular weakness produced by the fracture in the afflicted extremity, the patient was taught strengthening exercises such as static hamstrings, quadriceps, and calves. In gait training, weight-bearing was started at 25% and increased by 25% every two weeks.

Phase 4: [9-12 Weeks]: All of the initial range of motion and strengthening activities were performed and progressed. The active aided movement was substituted by passive motions. Advanced upper limb strengthening and stretching activities, as well as their band and weight cuff resistant workouts, were started. Proprioception was improved by implementing weight transfers and weighing scale presses. Increased repetitions and hold durations were used to develop strength training for the lower limb muscles on the left side. After achieving good

quadriceps, hamstrings, and VMO muscle strength, the use of the brace was discontinued. We began partial weight-bearing exercises with crutches after nine weeks under our supervision, as well as timely gait pattern modification. This level included gait re-education. The phases of the gait cycle were gradually taught to the patient, who then advanced to weight-bearing. This therapy plan also included balance training and proprioception. Weight-bearing was increased by 50% in gait training, which improved the patient's confidence in ambulating independently. Only after radiological confirmation that the fracture parts had fused and a physiotherapy follow-up to teach the necessary progressions was the patient instructed to commence full weight-bearing.

Follow up and outcome:

The Range of Motion and Manual Muscle Testing results before and after therapy are as follow given in table 3 and 4. The patient's health had improved linearly over 12 weeks, and early recovery had been observed.

Table 4: Comparison of range of motion pre and post physiotherapy rehabilitation

	Joint movement	Pre-rehabilitation left side		Post-rehabilitation left side	
		Active	Passive	Active	Passive
Shoulder joint	Flexion	0-160°	0-170°	0-160°	0-170°
	Extension	0-40°	0-50°	0-40°	0-50°
	Abduction	0-160°	0-170°	0-160°	0-170°
	Adduction	160°-0	170-0	160°-0	170-0
	Internal rotation	NT	NT	0-40°	0-45°
	External rotation	NT	NT	0-90°	0-90°
	Elbow joint	Flexion	NT	NT	0-130°
	Extension	NT	NT	130° -0	140° -0
Forearm	Supination	NT	NT	0-90°	0-90°
	Pronation	NT	NT	0-90°	0-90°
Wrist joint	Flexion	NT	NT	0-80°	0-90°
	Extension	NT	NT	0-60°	0-70°

	Radial deviation	NT	NT	0-20°	0-25°
	Ulnar deviation	NT	NT	0-30°	0-35°
Hip joint	Flexion	0-40°	0-50°	0-100°	0-100°
	Extension	0-15°	0-20°	0-25°	0-30°
	Abduction	0-30°	0-35°	0-45°	0-45°
	Adduction	30°-0	35°-0	45° -0	45° -0
	Internal rotation	0-20°	0-20°	0-40°	0-40°
	External rotation	0-20°	0-20°	0-40°	0-45°
Knee joint	Flexion	0-30°	0-35°	0-120°	0-125°
	Extension	30 °-0	35°-0	120° -0	125° -0
Ankle joint	Plantar flexion	NT	NT	0-35°	0-40°
	Dorsiflexion	NT	NT	0-20°	0-20°
	Inversion	NT	NT	0-25°	0-30°
	Eversion	NT	NT	0-15°	0-15°

Table 5: Manual Muscle Testing on last day of physiotherapy

	Muscles of the left side	Muscle strength	
		Preoperative rehabilitation	Postoperative rehabilitation
Shoulder joint	Flexors	4/5	5/5
	Extensors	4/5	5/5
	Abductors	4/5	5/5
	Adductors	4/5	5/5
	Internal rotators	NT	4/5
	External rotators	NT	4/5
	Elbow joint	Flexors	NT
Extensors		NT	4/5
Forearm	Supinators	NT	4/5

	Pronators	NT	4/5
Wrist joint	Flexors	NT	4/5
	Extensor	NT	4/5
Hip joint	Flexors	4/5	5/5
	Extensors	4/5	5/5
	Abductors	4/5	5/5
	Adductors	4/5	5/5
	Internal rotators	3/5	4/5
	External rotators	3/5	4/5
Knee joint	Flexors	2/5	4/5
	Extensors	2/5	4/5
Ankle joint	Plantarflexors	NT	4/5
	Dorsiflexors	NT	4/5

Discussion:

In this case, the patient complained of discomfort, edema, limited range of motion, and power in the left lower and upper extremities. Following a clinical examination, a treatment plan was developed that comprised range-of-motion exercises, strength training, resistive exercises, therapeutic techniques, modalities, and gait re-education(18). Few studies discuss the critical function of rehabilitation after an ankle dislocation, tibial plateau fracture, and proximal ulnar shaft fracture. Interestingly, there is a limitation of information in the literature about the rehabilitation of such patients. As a result, **this** study will be immensely useful in treating patients with these fractures. Physical therapy has been studied about ankle fractures in several research. Pure ankle dislocation is an uncommon injury that needs immediate reduction and immobilization for six weeks, followed by intense physiotherapy and recovery. Ice therapy, incremental range of motion exercises, soft tissue activation, static exercises, open and close chain strengthening exercises, stretching, and gait training have all been shown to aid in the recovery of tibial plateau fractures(19) (20). Several proprioception and stability activities were started to increase proprioception and weight transfer (7). Proprioception exercises are an important part of the rehabilitation process for people who have had knee injuries or operations

(21). Neuromuscular training is often utilized in the recovery of lower limb problems and has been demonstrated to be beneficial(5). The common problem in all of these rehabilitation programs is the limitation of the beginning moment: because most unstable ankle fractures are immobilized and only allowed partial weight-bearing for the first six weeks, there is a delay at the beginning of rehabilitation and training, and objects such as a training disc cannot be used during this time(22).

Conclusion:

The results of the study show that combining a definitive surgical approach with early physiotherapy rehabilitation improved the patient's functional outcome and gave him a detailed recovery program that helped him in reducing pain, regaining range of motion, strength, and bearing weight on his injured upper and lower extremity. The patient was able to carry out his daily activities in a much more efficient manner.

References:

1. Wang Z, Tang X, Li S, Wang X, Gong L, Zhong T, Et Al. Treatment And Outcome Prognosis Of Patients With High-Energy Transsyndesmotoc Ankle Fracture Dislocation—The “Logsplitter” Injury. *J Orthop Surg.* 2017 Jan 10;12(1):3.
2. Utomo P, Arimuqti Z, Santoso A, Sibarani T, Anwar I. High Energy Injury Ankle Fracture-Dislocation Without Neurovascular Involvement. *Indones J Med.* 2020 Jan 1;5:259–64.
3. Natoli RM, Summers HD. Irreducible Ankle Fracture-Dislocation Due To Tibialis Anterior Subluxation: A Case Report. *J Foot Ankle Surg.* 2015 Mar;54(2):268–72.
4. Ye T, Chen A, Yuan W, Gou S. Management Of Grade III Open Dislocated Ankle Fractures. *J Am Podiatr Med Assoc.* 2011 Jul 1;101(4):307–15.
5. Jansen H, Jordan M, Frey S, Hölscher-Doht S, Meffert R, Heintel T. Active Controlled Motion In Early Rehabilitation Improves Outcome After Ankle Fractures: A Randomized Controlled Trial. *Clin Rehabil.* 2018 Mar 1;32(3):312–8.
6. Briet JP, Hietbrink F, Smeeing DP, Dijkgraaf MGW, Verleisdonk EJ, Houwert RM. Ankle Fracture Classification: An Innovative System For Describing Ankle Fractures. *J Foot Ankle Surg.* 2019 May;58(3):492–6.

7. Arvanitakis AV, Mian KC, Kreienkamp R, Rhoades CE. Tibial Plateau Fracture Following Low Energy Fall In The Rocky Mountains. *Kans J Med.* 2019 Aug 21;12(3):91–3.
8. Pawar A, Pathan H, Rao R, Mishra G. Early Physiotherapy Approach After Surgical Stabilization Of Proximal One-Third Tibial Fracture Improved Recovery Of The Patient: Case Report. *Eur J Mol Clin Med.* 7(11):2020.
9. Siebenlist S, Buchholz A, Braun KF. Fractures Of The Proximal Ulna: Current Concepts In Surgical Management. *EFORT Open Rev.* 2019 Jan 7;4(1):1–9.
10. Small RF, Yaish AM. Radius And Ulnar Shaft Fractures. In: Statpearls [Internet]. Treasure Island (FL): Statpearls Publishing; 2021 [Cited 2021 Dec 7]. Available From: [Http://Www.Ncbi.Nlm.Nih.Gov/Books/NBK557681/](http://www.ncbi.nlm.nih.gov/books/NBK557681/)
11. Bado JL. The Monteggia Lesion. *Clin Orthop.* 1967 Feb;50:71–86.
12. Sahajpal D, Wright TW. Proximal Ulna Fractures. *J Hand Surg.* 2009 Feb 1;34(2):357–62.
13. Tan EW, Sirisreetreerux N, Paez AG, Parks BG, Schon LC, Hasenboehler EA. Early Weightbearing After Operatively Treated Ankle Fractures: A Biomechanical Analysis. *Foot Ankle Int.* 2016 Jun;37(6):652–8.
14. Firoozabadi R, Harnden E, Krieg JC. Immediate Weight-Bearing After Ankle Fracture Fixation. *Adv Orthop.* 2015;2015:491976.
15. Pyle C, Kim-Orden M, Hughes T, Schneiderman B, Kay R, Harris T. Effect Of Early Weightbearing Following Open Reduction And Internal Fixation Of Unstable Ankle Fractures On Wound Complications Or Failures Of Fixation. *Foot Ankle Int.* 2019 Dec;40(12):1397–402.
16. Bawiskar D, Dhote S, Phansopkar P. Early Physical Rehabilitation Post-Surgery In A Complex Type 5 Schatzker Tibial Plateau Fracture Improves Functional Outcomes: A Case Report. 2020;8.
17. Phansopkar P, Naqvi WM. Early Physiotherapy Rehabilitation Approach Enhances Recovery In Rare Acute Tibial Osteomyelitis Post-Operative In A 9 Year Old Child. 2020;5.
18. Jawade S, Naidu N, Vardharajulu GG. EFFICACY OF STRENGTH TRAINING PROGRAM ON MUSCLE PERFORMANCE BY DETERMINING 1 REPETITION MAXIMUM IN ADULTS. *Eur J Mol Clin Med.* 2020 Nov 23;7(2):1946–54.
19. Linehan RF. DOCTOR OF PHYSICAL THERAPY. :47.
20. Vaidya L, Kumar K, Naqvi W, Narang S, Pisulkar G, Dadlani M. Revision Of Total Hip Replacement Surgery In Elderly Patient And Its Recovery Based On Periprosthetic Fracture Rehabilitation. 2020;11.

21. Edwards SG, Argintar E, Lamb J. Management Of Comminuted Proximal Ulna Fracture-Dislocations Using A Multiplanar Locking Intramedullary Nail. Tech Hand Up Extrem Surg. 2011 Jun;15(2):106–14.
22. Effect Of Ankle Disk Training Combined With Tactile Stimulation To The Leg And Foot On Functional Instability Of The Ankle - Pubmed [Internet]. [Cited 2022 Jan 29]. Available From: <https://pubmed.ncbi.nlm.nih.gov/11206252/>

UNDER PEER REVIEW