

Type of Article: REVIEW Article

Title of Article: WILKODONTICS: A Meteoric Rise to Faster Orthodontic Treatments.

Authors :

1] Janhvi Bhosle, BDS Third Year Student, Sharad Pawar Dental College And Hospital, DMIMS (Deemed To Be University), Sawangi (Meghe), Wardha 442001, Maharashtra, India,

2] Prasad Dhadse- Professor & Head of Department of Periodontics, Sharad Pawar Dental College & Hospital, Datta Meghe Institute of Medical Sciences (Deemed to be University) Sawangi (Meghe), Wardha.

3] Netal Rathi-BDS Final year student, Sharad Pawar Dental College & Hospital, Datta Meghe Institute of Medical Sciences (Deemed to be University) Sawangi(Meghe). Wardha.

**Corresponding author:**

JANHVI BHOSLE

UG Student , Sharad Pawar Dental College & Hospital

Datta Meghe Institute of Medical Sciences

(Deemed to be University )

Sawangi (Meghe) , Wardha.

Total number of pages: 8

Total words count (abstract): 93

Total words count (Text): 2930

## **WILKODONTICS: A METEORIC RISE TO FASTER ORTHODONTIC TREATMENTS**

### **ABSTRACT:**

A tremendous amount of advances has been made in the past few decades. In spite of these advances, the average orthodontic treatment lasts 1.5 to 3 years. "Wilkodontics," often called Periodontally Accelerated Osteogenic Orthodontics is a procedure that helps in accelerating tooth movement as well as in providing an increase for rendering extensive dental services and care to the patients in bone activation through selective decortication and osteotomies as well as alveolar augmentation using a particulate bone graft. Thus, this article attempts to review the main indications, contraindications, and modifications of wilkodontics.

Keywords: wilkodontics, bone, periodontics, orthodontics.

### **INTRODUCTION:**

Wilkodontics, also known as Periodontically accelerated osteogenic orthodontics, uses periodontal methods to soften and transplant the bone surrounding the teeth. The orthodontist can rapidly reposition the teeth into normal alignment when the bone is soft. The grafting will be completed in a few months. The bone grafting material such as deproteinized bovine bone, autogenous bone, will be converted into strong bone, which will be able to support the straightened teeth. Furthermore, the softening. The use of bone shortens the therapy time.

During this course of action, surgical stress leads to the release of inflammatory mediators, which causes blood vessel dilatation and enhances osteoclast recruitment at the site of surgery. Thus, enhances remodeling of bone, although corticotomy causes a decrease in bone mineral density, diminishing the protection of dentoalveolar tissue towards the orthodontic stresses and elevating the root resorption risk.[1]. The collaborative effort of the orthodontic and the periodontic sectors in the wilkodontics can lessen the traditional orthodontic treatment length to 4 to 8 months. This treatment may be dated back to the early 1900s in orthopedics. It was only recently that it was enhanced to help with teeth straightening and bite stabilization.[2]

The periodontium is made up of PDL, gingiva and alveolar bone. The most mineralized structure among all is alveolar bone, which is not easily bendable, and regulating its remodeling capability has long been a difficulty in both periodontics and orthodontics.[3] Conventional orthodontic tooth movement protocols have been reconstructed with the engineering of periodontal tissue and regenerative resection, not just on the method of quick orthodontic tooth movement, but also toward providing every dentist with a guideline that decreases the harmful effects like root resorption, relapses, insufficient basal bone, bacterial caries, and infection. Furthermore, shortened treatment times using the newly devised approach is indubitably advantageous to the patient's periodontal health.[4]

As a result, this paper emphasizes the intrinsic assessment of the literature, which includes the historical context, current clinical procedures, indications, contraindications, problems, benefits, and downsides of this innovative approach.

## **HISTORICAL REVIEW:**

Dr. Gabriel Ilizarov, a Russian orthopaedic surgeon, pioneered the method of Distraction Osteogenesis (DO) — the production of new osseous matter by “distorting” the osseous matter by resection – in the 1950s. L.C. Bryan presented corticotomy-aided tooth movement for the first time in a textbook published by S. H. Guilford in 1893. [5] Periodontists began employing a corticotomy procedure to accelerate tooth movement. In 1959, Henrich Kole was the first individual to emphasize the latest corticotomy-supported orthodontics. The width and progression of the denser layer of compact bone, according to Kole, gave the highest resistance to tooth movement. He postulated that by interrupting the continuity of the cortical layer of bone, he was forming and transferring blocks of bone in which teeth were implanted. He postulated this as ‘bony block movement’ [6] Craniofacial surgeons started to adopt DO methods to quickly extend palates in growing patients in the early 1960s.. In the 1980s, prominent orthopaedist Harold Frost observed that there is seen a definite interrelation in-between the degree of damage caused to the bone and also the power of its healing reaction. This was named the Rapid acceleratory phenomenon by him (RAP) [7]. Dr. Thomas Wilcko and Dr. William Wilcko of Erie, PA, both were periodontists and orthodontists respectively, later refined the corticotomy augmented orthodontic method in 1995 by adding Orthodontics (Periodontically accelerated osteogenic orthodontics ), which was eventually based on the Wilcko brothers' emerging concepts, patented as "Wilckodontics". In May 1998, the American Society of Orthodontists held its 98th Annual Session, and the AOOTM therapy was introduced. As mentioned in Hajji SS (2000) research, the minimal orthodontic duration for non-extraction PAOO was 6.1 months, whereas the minimal orthodontic period for extraction treatments without PAOO was 18.7 and 26.6 months. Wilko et al. presented an updated quicker orthodontic corticotomy induced method which consisted periodontal alveolar accession in 2001, signalling that orthodontic treatment might be finished in one-third of the standard time. [8] According to Wilko et al., corticotomies may facilitate tooth mobility via increased bone turnover and decreased bone density in cases of rapid orthodontics with corticotomies.[9]

## **What is Rapid Acceleratory Phenomenon? (RAP):**

The Regional Acceleratory Phenomenon (RAP) is an intricate action of body cells to multiple painful stimulus. This affects both hard and soft tissues and is distinguished through the fast-tracking and dominance of continuing typical vital tissue functions. RAP in human long bones commences a few days after surgery, spikes in 1 - 2 months, and can take 6 to 24 months to fully stop. [10] It might be an "SOS machinery that made progress to improve tissue repair and local tissue protection. When a RAP goes blunted, healing is hindered and the resilience to trauma and infection is reduced. When this phenomenon is overlooked in experimental design, it can substantially compromise research of osteopenia and the impact of powered, endocrinologic, and biological variables on skeletal functioning.[7] Any localized harmful stimulus of sufficient size appears to elicit a RAP in a normal body. The area in which the region is affected and the severity of its reaction appear to be proportional to the amount of the stimulus, albeit to various degrees in different people. RAP includes the area in which the stimulus began such as soft and hard tissue components. RAP can affect the whole frozen region of the body following acute paraplegia, hemiplegia, or monoplegia, whether provoked by trauma, poliomyelitis, or another acute disorder, or by lower motor neuron or central lesions. [11,12] Switch from uninvolved to involved zones seems subtle

rather than sharp, and RAP distribution appears to mimic regional vascular structure and transmission. Abscopic involvement can arise in response to strong stimuli, implying that continuing tissue turnover and perfusion might just be amplified in contralateral areas of the body.

The RAP could have originated to quicken injury repair and tissue defense responses to localized infection, infarction, mechanical stresses, and other harmful processes. This type of function indicates an "SOS"-like a spectacle that just might benefit a species' survival throughout development in a substantially competitive atmosphere. Once initiated, it seems to favor other constant processes as well as the endocrine, pharmacological, and mechanical influences that have a tendency to suppress or to augment those happenings in vigorous persons.

2 separate categories of medical events exemplify RAP's anticipated "SOS" role. The first depicts its beneficial impacts, while the second reflects its impairment.

#### **OTHER CLINICAL EXAMPLES OF THE RAP EFFECT INCLUDES:**

1. Potentiated bone healing.
2. The pathological RAP
3. Arthrofibrosis
4. Neuropathic soft tissue problems
5. The Charcot's joint.
6. Rheumatoid phenomena

#### **PATIENT SELECTION CRITERIA:**

Wilkodontics can be performed on patients of any age as long as they have adequate periodontal health. It responds well for class I malocclusions with reasonable to harsh crowding. Also useful in class II malocclusions needing extension or extraction. PAOO can also be performed on individuals with severe bimaxillary protrusion, minor class III malocclusion, molar up righting, and other problems.

If the patient is having dental bone loss, periodontal disease, root injury, or root resorption, then he/she may not be a good candidate for this operation. Furthermore, if the patient is having any illness that requires the patient to take NSAIDs on a daily basis, such as rheumatoid arthritis, then he/she will not be considered a good candidate for PAOO.

#### **INDICATIONS:**

- I. Corrects open bites
- II. Provides a conservative alternative to orthognathic surgery
- III. Corrects moderate to severe class II and class III malocclusions
- IV. Improves post-orthodontic stability V. Allows for progressive orthodontic expansion

#### **CONTRAINDICATIONS:**

- A. people who are diagnosed with severe active periodontal disease.
- B. Endodontic patients who have not received proper treatment.
- C. Patients who are using long-term treatments that impede bone metabolisms, for example bisphosphonate and nonsteroidal anti-inflammatory drugs (NSAIDs). The suppression of prostaglandins caused due to NSAIDs results in reduced osteoclastic activity, which compromises bone remodeling.
- D. Patients who have had long-term steroid therapy as a result of devitalized bone areas.

**PROCEDURE:**

A week before the surgical procedure, braces for orthodontics are inserted and the light wire is connected. after the orthodontist and periodontist have thoroughly discussed the treatment plan. The orthodontist is accountable for devising and managing the treatment plan. The following steps can be followed to perform surgery with or without sedation:

1. FLAP DESIGN
2. DECORTICATION
3. PARTICULATE GRAFTING
4. CLOSURE TECHNIQUES

**FLAP DESIGN:**

In the coronal area, flaps with full-thickness are precisely reflected both labially and lingually, whereas a partial-thickness flap is raised up in the apical area to improve flap agility at the site of the suture. By giving access to the alveolar bone for corticotomies, the flap design aims to cover the bone graft, retain the length of the interdental tissues, and also improve the cosmetic look of the gingiva. Local anesthetic is administered before lingual and labial sulcular releasing incisions are done. If at all possible, avoid vertical cuts or incisions at the base of the flaps. Between the maxillary central incisor, the interdental papilla is kept in situ for cosmetic reasons. The inflamed tissue is then extensively debrided and curettement is performed.

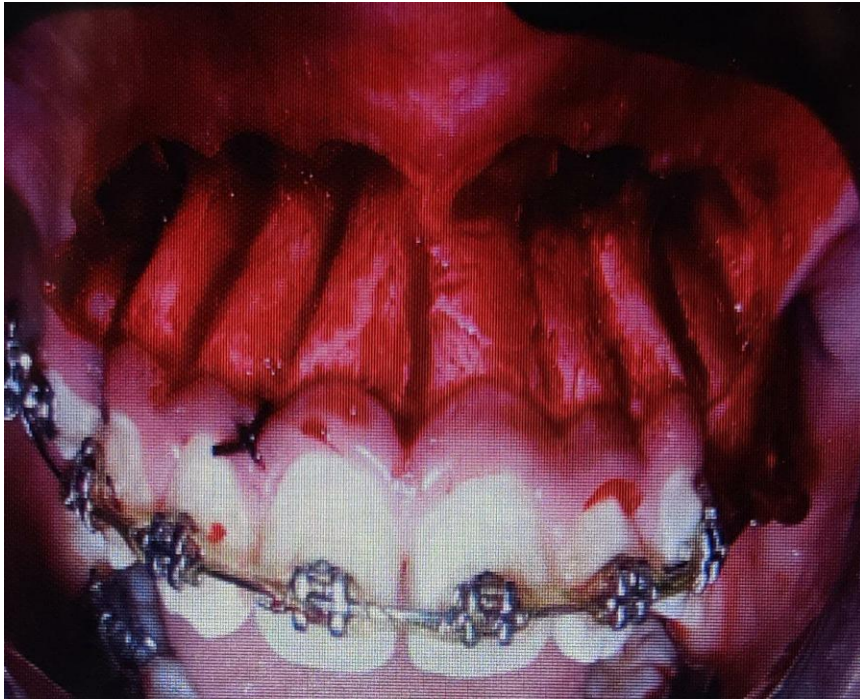


Figure 1: modified incision is made and the flaps are elevated

#### **DECORTICATION:**

Careful alveolar enhancement is performed on each of the lingual and labial sides using a no. 1 or no. 2 round bur or a piezoelectric knife to stimulate alveolar bone (piezocision). [13,14]. To begin RAP, no mobile bone segments should be produced. All anatomic structures must be treated with care, and all general surgical principles must be observed. The vertical groove is established in between the inter radicular gap, halfway in the root distinctions of the alveolar consonant bone. From 2 to 3 mm below the bone's crest to 2 mm beyond the root apices, this groove runs.[15] If the alveolar bone is thick sufficiently, single holes can be placed without avoiding vital neurovascular networks. To avoid damaging basic assemblies as the maxillary sinus and mandibular canal, proper Corticotomy cuts and punctures should pass throughout the whole depth of the cortical plate but scarcely into the cancellated bone.

The basic aspect of the corticotomy procedure is that it decorticates the bone, leading to acute osteopenia as well as a temporary drop in mineral content. Within 20 to 55 days, the osteogenic cells begin laying down large calcium deposits, succeeded by bone mineralization.[16]

#### **PARTICULATE GRAFTING:**

The particulate bone graft material is placed on to the active bone after it has been activated. Bacteriostatic water solution or clindamycin containing about 5 mg/mL of plasma which is rich in platelet or clindamycin phosphate is used in the process of wetting the particulate bone grafting material, enabling insertion.[17] It is performed in the vast majority of corticotomy sites. The volume of particulate bone graft utilized per tooth ranges from 0.25 to 0.5 ml, which depends on pre-treatment width, orthodontic pressure course and amplitude, and lip support. The most often utilized materials which are used for grafting post decortication are freeze-dried bone, allograft, deproteinized bovine cancellous matter, or even the mixture of all these materials. [15]

## **CLOSURE TECHNIQUES:**

The flaps are approached with materials that are non-resorbable using intermittent loop sutures. The flap should be closed with the least amount of force possible. A two-week timeframe is excellent for the formation of the joint of epithelium, and only after this period of time is passed the sutures are removed. [18] The overall procedure takes up to 8 to 10 days to finish. Analgesics and antibiotics are administered for 5 days, in the company of orthodontic apparatus, to permit flap manipulation and suturing. [15]

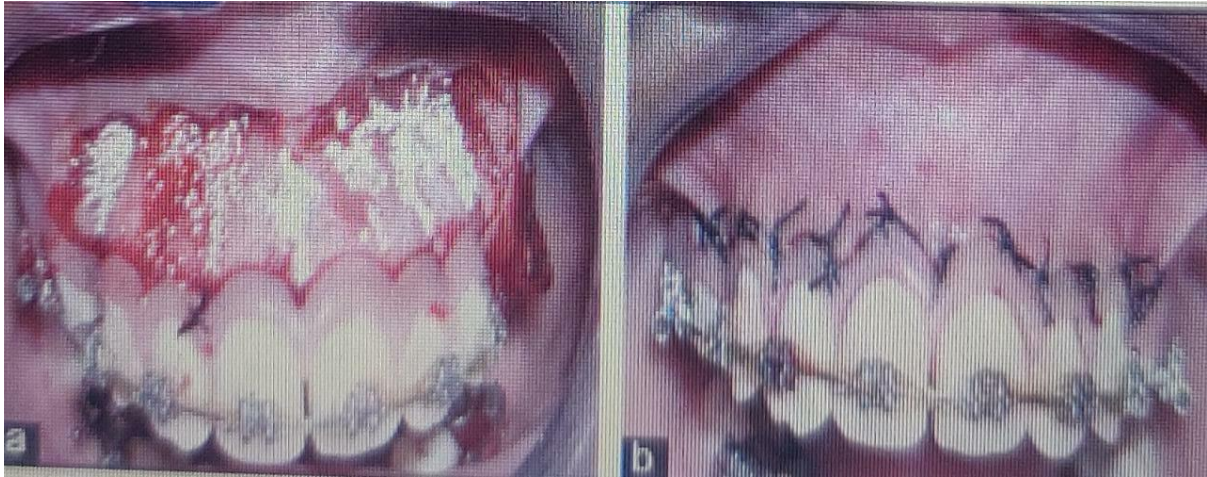

Figure2: (a and b) Sutures are put in the decorticated region and a particle alloplastic bone replacement is used.

## **ADVANTAGES:**

1. Faster tooth movement, shorter treatment time, and decreased recurrence risk.
2. There is decreased root resorption risk.
3. Ceramic brackets, gold, or metal can be employed.
4. Because tooth mobility arises via softening. As a consequence of the bone, the patient has less pain.

## **DISADVANTAGES:**

1. Expensive when compared to traditional braces.
2. Further operation is required.
3. An increased chance of discomfort, inflammation, and infection following surgery.

## **MODIFICATIONS IN WILKODONTICS:**

One limitation of this approach is that the root surface in some of the regions is exposed, which maybe be generated by a slim gingival biotype as well as a thin cortical plate of bone.

As a result, usage of autogenous soft tissue grafts, such as connective tissue grafting, which is nowadays acknowledged as the benchmark amongst all approaches of tissue grafting, may be represented in the full-thickness flap. From the palatal side that has been keratinized, a graft can be taken out. Under the flap, platelet-rich plasma and fibrin and all other growth factors can be used. By use of platelet-rich fibrin improves the graft's stability [15]

Corticotomy which is assisted by laser is considered advantageous because it is a non-invasive process. It employs laser radiation consisting of erbium, chromium-doped yttrium scandium gallium garnet for cortical bone lessening without flap reflection, declining the requirements for surgical intervention. [19]

### **THE TECHNIQUE OF MONOCORTICAL TOOTH DISLOCATION AND LIGAMENT DISTRACTION (MTDLD):**

The monocortical tooth dislocation and ligament distraction (MTDLD) therapy combine 2 distinct dental activities that work on opposite root surfaces at the same time. A piezosurgical micro saw is often used to execute both vertical and parallel microsurgical corticotomies to reduce cortical bone resistance. Continued by the quick application of substantial biomechanical pressures, resulting in a complete displacement of the bones and roots.

### **CONCLUSION:**

The good synchronization of the periodontist, orthodontist, and OMF surgeon is required for successful treatment by wilkodontics or the Periodontically accelerated osteogenic orthodontics technique. Proper case selection also plays a key role in this. The technique governing Wilckodontics or the PAOO method can be said to be characterized as the initiation of metabolism of bone by the migration of decortication points and lines surrounding the teeth to stimulate periodontal and bone turnover, subsequent to a transitory state of low bone mass throughout treatment. If continued by a brief term of orthodontic appliance therapy, which in turn improves and also accelerates tooth movement.

This method not only deals with the alignment of teeth but also facial features. Given the growing urge of new orthodontics patients to lessen their treatment period, this approach of wilkodontics will upshoot in a spike in the number of patients who receive orthodontic treatment. Wilckodontics' long-term therapy outcomes are presently unclear because the approach is still comparatively new. An additional experimental study is required to establish the best and most longstanding outcomes of this method.

- [1] Mostafa MM. Developing a Corticopuncture System to Accelerate the Rate of Tooth Movement. UCLA Electronic Theses and Dissertations. Los Angeles, CA: University of California; 2014
- [2] Frost HM. The biology of fracture healing an overview for clinicians. *Clin Orthop Relat Res*1989;248:283-28
- [3] Ispas A, Craciun A, Kui A, Lascu L, Constantiniuc M. Occlusal forces and their transmission to the periodontium. *HVM Bioflux* 2019;11(1):18-21.
- [4] Wilcko WM, Wilcko T, Bissada NF. An evidence-based analysis of periodontally accelerated orthodontic and osteogenic techniques: A synthesis of scientific perspectives. *Semin Orthod* 2008;14:305-16
- [5] . Amit G, JPS K, Pankaj B, Suchinder S, Parul B. Periodontally accelerated osteogenic orthodontics (PAOO) - A review. *J Clin Exp Dent*.2012; 4(5):292- 6.
- [6] Kole H. Surgical operation on the alveolar ridge to correct occlusal abnormalities. *Oral Surg Oral Med Oral Pathol*.1959; 12:515-29
- [7] .Frost HM. The regional acceleratory phenomenon: a review.*Henry Ford Hosp Med J*.1983; 31:3-9.
- [8] Hajji SS The influence of accelerated osteogenic response on mandibular decrowding (thesis). St Louis University; 2009
- [9] Wilcko WM, Fergusson DJ, Bouquot JE, Wilcko MT. Rapid orthodontic decrowding with alveolar augmentation: case report. *World J Orthod* 2003; 4: 197-205
- [10] Sethiya, K.R., Dhadse, P., V., 2020. Healing after Periodontal Surgery - A Review. *JOURNAL OF EVOLUTION OF MEDICAL AND DENTAL SCIENCESJEMDS* 9, 3753–375
- [11].Ring PA. The influence of the nervous system on the growth of bones. *J Bone Joint Surg* 1961;43B:121-40.
- [12]. Ring PA, Ward BCH. Paralytic bone lengthening following poliomyelitis. *Lancet* 1958;2:551-3
- [13]. Wilcko WM, Ferguson DJ, Bouquot JE, et al. Rapid orthodontic decrowding with alveolar augmentation:Case report. *World J Orthodont*, 2003; 4: 197-505.
- [14]. Dibart S, Surmenian J, Sebaoun JD, Montesani L. Rapid treatment of Class II malocclusion with piezocision: two case reports. *Int J Periodontics Restorative Dent.*, 2010; 30(5): 487-93
- [15]. Murphy KG, Wilcko MT, Wilcko WM, Ferguson DJ. Periodontally accelerated osteogenic orthodontics: a description of the surgical technique. *J Oral Maxillofac Surg*. 2009;67:2160-6.
- [16] Sethiya, K.R., Dhadse, P., V., 2020. Healing after Periodontal Surgery - A Review. *JOURNAL OF EVOLUTION OF MEDICAL AND DENTAL SCIENCESJEMDS* 9, 3753–375

[17]. Wilcko MT, Wilcko WM, Pulver JJ, Bissada NF, Bouquot JE. Accelerated osteogenic orthodontics technique: a 1-stage surgically facilitated rapid orthodontic technique with alveolar augmentation. *J Oral Maxillofac Surg* 2009;67(10):2149–2159

[18]. Binderman I, Gadban N, Bahar H, Herman A, Yaffe A. Commentary on Periodontally accelerated osteogenic orthodontics [PAOO]-a clinical dilemma. *International Orthodontics*, 2010; 43: 1-10

[19]. Khurana R, Kudva PB, et al. Wilckodontics—a gift of time. *EC Dent Sci* 2016;4(5):869–873