

NEWER TREATMENT MODALITIES IN URTICARIA

ABSTRACT

Wheals (hives), angioedema, or both are symptoms of urticaria, a chronic clinical disorder. Urticaria has a complicated pathogenesis, as well as a large disease burden, a negative effect on health-care expenditures and quality of living. Urticaria could also be a chronic condition that affects up to 1% of the general population at some stage in their lives and can drastically impair quality life . The use of second-generation , non-sedating antihistamines has replaced antihistamines to use as the first-line therapy. However, urticaria can be difficult to manage in some cases; in these cases, alternate treatment approaches must be considered. This article reviews antihistamines, leukotriene antagonists, anti-inflammatory drugs, biologicals, subcutaneous autologous serum therapy , doxepin , cyclosporine ,tranexamic acid and other newer treatment modalities.

Key words: urticaria , wheals, histamine

INTRODUCTION

Urticaria which is characterised by the onset of angioedema and transitory hives (wheals), or both . A wheal is a cutaneous edema that is confined that is usually engulfed by a bright red erythema along with a heavy scratching or burning sensation. In urticaria wheals occur after a few minutes and are temporary, as the skin comes back to its natural appearance after 1–24 hours. Angioedema manifests as a edema in the deep dermis and subcutis, as well as mucosal membranes, that is painful and burning, that is not itchy and less well-defined. Angioedema usually swellings that are skin-colored or somewhat red that develop slowly and may last for several days, unlike wheals. (1)

CLINICAL CLASSIFICATION

Acute urticaria is defined by a repeated appearance of wheals with or without angioedema over a period of up to 6 weeks.

Chronic urticaria wherein the recurrence of lesions over more than 6 weeks.

Urticarias are also further classified as (1)

- 1) Chronic spontaneous urticaria
- 2) Chronic inducible urticaria
 - Acquired Cold Urticaria
 - Heat-Induced Urticaria
 - Delayed Pressure Urticaria
 - Solar Urticaria
 - Cholinergic Urticaria
 - Vibratory Angioedema
 - Contact Urticaria

- Aquagenic Urticaria

PATHOGENESIS

A perivascular leukocyte infiltration and mast cell degranulation consisting of lymphocytes eosinophils neutrophils and basophils that have spread to the lesions are two underlying pathologies shown in urticaria. On activation, Histamine and other inflammatory mediators (prostaglandins, leukotrienes, cytokines) are released by both mast cells and basophils which can induce local vasodilation, itch, and skin swelling.(2)(3)

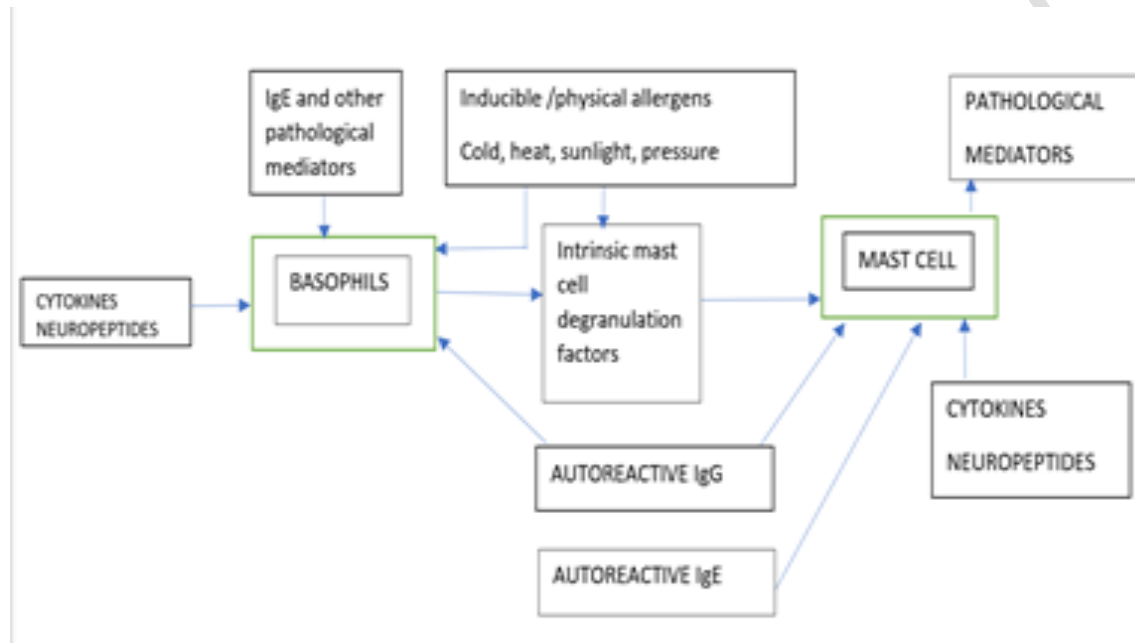


Fig 1. perivascular leukocyte infiltration and mast cell degranulation

CLINICAL FEATURES

Characteristic redness, and scratching are three characteristics of the urticaria. There could be a burning feeling as well. Lesions can appear anywhere on the body and heal in 2–3 hours without establishing a mark. The spontaneous recovery will last anywhere from a few hours to a day.

Angioedema is characterised by a sudden onset of skin swelling, exclusively in eyelids and lip mucosae.

Erythema and edema are symptoms of dermographism that appears 10–20 minutes after mechanical trauma is applied to the skin.[4,5]

THE NEWER TREATMENT MODALITIES OF URTICARIA

ANTI-HISTAMINICS

Second generation H1 anti histaminics has proved to be better than first generation.

- Fexofenadine

It is a piperidine type antihistamine and a terfenadine metabolite. In dose 20mg BD daily, There was a significant difference **There was a significant difference.** in pruritus ratings, number of wheals, overall sleep rate, patient confirmed symptoms, and total symptom ranking. Better results were shown in the DLQI and the work productivity and activity Impairment Questionnaire (WPAI).[6]

➤ Desloratadine

Desloratadine was associated with a slightly greater mean decrease in DLQI score than placebo between baseline and 6 weeks of therapy in a French multicentre trial of 137 urticaria patients treated for 6 weeks. Finally, the level of evidence supporting desloratadine's safety and efficacy in urticaria is high.[5]

➤ Levocetirizine

In a multicentre trial, 166 urticaria patients were randomly assigned to receive levocetirizine 5 mg daily HS or placebo for four weeks. The magnitude of pruritus, length of pruritus, amount of wheals, and scale of wheals all decreased dramatically in the levocetirizine community. Headache and exhaustion were "slightly more common" in the levocetirizine party. However, the evidence is high for levocetirizine being safe and effective in urticaria.(6)(7)

LEUCOTRIENE ANTAGONISTS

➤ Peptide leukotrienes are active inflammatory mediators generated by the 5 LOX pathway from arachidonic acid. Zafirlukast along with Montelukast are two antagonists of leukotriene receptor.

Experiments in (vitro) have shown that human mast cells produce and release peptide – leukotriene in response to IgE mediated stimulation. Many individuals with chronic urticaria have anti-IgE autoantibodies, stimulate human skin mast cells in vivo. Zafirlukast (20mg twice daily), Montelukast (10mg OD) have shown to be better than placebo in randomised trials.(9)

CYCLOSPORINE

➤ It is Immune suppressant and anti-inflammatory medication. From 19 patients receiving cyclosporine (4 mg/kg/day) in a new randomised, double-blind trial, the serum histamine-releasing action was reduced. However, because of the potential for negative side effects, its use should be limited.(9)

ANTI-INFLAMMATORY DRUGS

➤ Dapsone

At dosages of 25–50mg/day, dapsone has been shown to provide an efficient reaction. It is normally well tolerated, although it can cause anaemia, peripheral neuropathy, and skin rash in some people. It is not recommended for people who are G6PD deficient.[4]

➤ Sulfasalazine

For proper care and reaction to occur in one month of therapy, up to 2g/day is needed. In a case study and a single retrospective observation, this was proposed.[5]

➤ Hydroxychloroquine

Patients with urticaria treated with hydroxychloroquine have a substantial improvement in (according to a randomised, double-blind, placebo-controlled study) quality of life .(9)

BIOLOGICALS

Omalizumab

Omalizumab which is a recombinant humanised monoclonal IgG antibody leads to binding of free Ige. More recently, the medication has shown to be an effective therapy for various antihistamine subtypes. Numerous clinical reviews, series of cases along with multi-centre double-blind, placebo-controlled trials have shown chronic urticaria and angioedema . It's been suggested that omalizumab helped patients with chronic urticaria who couldn't get relief from H1 antihistamines. 336 patients with H1-antihistamine-resistant urticaria were randomised to undergo six injections subcutaneously of 300 mg omalizumab or placebo at 4-week intervals, accompanied by a 16-week monitoring cycle, in a recent phase III trial. Omalizumab toleration was good and decreased urticaria signs and symptoms. The recurrence of symptoms, as well as the high cost, are the most significant drawbacks.[8]

Intravenous Immunoglobulin

Patients with urticaria who do not react to other treatments and have a positive basophil histamine release assay and positive autologous serum skin test can benefit from intravenous immunoglobulin.

Nine out of ten patients of a large trial responded to a dosage of 0.4 g/kg/day for five days in a row, and three patients experienced extended recovery after a three-year follow-up. Intravenous immunoglobulin is generally effective, although it does have certain drawbacks, like anaphylactic reactions, aseptic meningitis, and renal dysfunction, which are usually uncommon. The high cost is also a drawback.[9]

Rituximab

Rituximab (chimeric monoclonal antibody) targets antigen CD20, which is often present on the surface of B cells. It kills B cells, which decreases antibody activity, including autoantibodies. It was successful in two of the three patients that were immune to H1-antihistamines, but not in the other.(8)

TRANEXAMIC ACID

Practice of anticoagulants in clinical practice and fibrinolysis inhibitors including tranexamic acid in patients with urticaria produces mixed effects, as shown by a recent systematic study of five trials involving a total of 39 patients . There was no disparity between placebo and tranexamic acid therapy in a double-blind trial of 17 patients with urticaria. Tranexamic acid was shown to be effective in another study In 5 of 8 patients with nadroparin, the combination was successful. D-dimer levels in urticaria are elevated.(9)

SUBCUTANEOUS AUTOLOGOUS SERUM THERAPY

A randomised, controlled trial with a single blind, placebo-controlled parallel group was conducted. In both categories, on an as-needed basis, twenty-four CSU patients (11 M: 13 F) were administered subcutaneous AST and seventeen patients (7 M: 10F) were administered with subcutaneous saline (placebo) with levocetirizine. At the end of 9 weeks, the DLQI reported a substantial drop in the serum group, from 14.26 to 4.(10)

DOXEPIN

It is a tricyclic antidepressant that blocks H1- and H2-receptors, is particularly helpful in patients who are depressed or anxious as a result of their urticaria symptoms. In comparison to placebo-treated patients, doxepin-treated patients required less frequent antihistamine use. However, doxepin's biggest downside is that it induces sedation, which can hinder its application.(10)

OTHER TREATMENTS

It has been suggested that plasmapheresis can be used as a treatment choice for patients with serious urticaria. However, it is not recommended that such a treatment be used on a regular basis. Miltefosine, a lipid raft modulator, was shown in a randomised, controlled, multicentre study to enhance symptoms in urticaria patients who did not respond to H1-antihistamines.(10)

DISCUSSION AND CONCLUSION

Antihistamines are the most effective treatment for urticarial infections. In certain cases of the condition, effectiveness variations between younger, nonsedating antihistamines and older agents, according to evidence based analysis. To further understand the function of these agents in the treatment of urticaria, more well-controlled clinical trials with a greater number of patients are clearly needed studies promoting the option of one antihistamine over another remain limited, provided the degree and length of their use in urticaria. Because of the brief length of the analysis (i.e., chronic idiopathic urticaria) or the limited number of patients examined, even in such diagnoses where a strong advantage of one agent over another has been shown. The findings must be treated with caution (i.e. symptomatic dermographism, cold urticaria). To make evidence-based decisions in the management of patients with urticarial syndromes, further research is required, according to these results.

COMPETING INTERESTS DISCLAIMER:

Authors have declared that no competing interests exist. The products used for this research are commonly and predominantly use products in our area of research and country. There is absolutely no conflict of interest between the authors and producers of the products because we do not intend to use these products as an avenue for any litigation but for the advancement of knowledge. Also, the research was not funded by the producing company rather it was funded by personal efforts of the authors.

REFERENCES

1 Radonjic-Hoesli S, Hofmeier KS, Micaletto S, Schmid-Grendelmeier P, Bircher A, Simon D. Urticaria and Angioedema: an Update on Classification and Pathogenesis. Clin Rev Allergy Immunol. 2018 Feb;54(1):88-101. doi: 10.1007/s12016-017-8628-1. PMID: 28748365.

- 2 Saini SS. Chronic spontaneous urticaria: etiology and pathogenesis. *Immunol Allergy Clin North Am*. 2014 Feb;34(1):33-52. doi: 10.1016/j.iac.2013.09.012. Epub 2013 Oct 28. PMID: 24262688.
- 3 Sabroe RA. Acute urticaria. *Immunol Allergy Clin North Am*. 2014 Feb;34(1):11-21. doi: 10.1016/j.iac.2013.07.010. Epub 2013 Aug 24. PMID: 24262686.
- 4 Kayiran MA, Akdeniz N. Diagnosis and treatment of urticaria in primary care. *North Clin Istanbul*. 2019 Feb 14;6(1):93-99. doi: 10.14744/nci.2018.75010. PMID: 31180381; PMCID: PMC6526977.
- 5 Abajian M, Schoepke N, Altrichter S, Zuberbier T, Maurer M. Physical urticarias and cholinergic urticaria. *Immunol Allergy Clin North Am*. 2014 Feb;34(1):73-88. doi: 10.1016/j.iac.2013.09.010. Epub 2013 Oct 28. Erratum in: *Immunol Allergy Clin North Am*. 2014 May;34(2):xix. Zuberbier, H C Torsten [corrected to Zuberbier, Torsten]. PMID: 24262690.
- 6 Lee EE, Maibach HI. Treatment of urticaria. An evidence-based evaluation of antihistamines. *Am J Clin Dermatol*. 2001;2(1):27-32. doi: 10.2165/00128071-200102010-00005. PMID: 11702618.
- 7 Deza G, Giménez-Arnau AM. Itch in Urticaria Management. *Curr Probl Dermatol*. 2016;50:77-85. doi: 10.1159/000446047. Epub 2016 Aug 23. PMID: 27578075.
- 8 Tedeschi A, Airaghi L, Lorini M, Asero R. Chronic urticaria: a role for newer immunomodulatory drugs? *Am J Clin Dermatol*. 2003;4(5):297-305. doi: 10.2165/00128071-200304050-00001. PMID: 12688835.
- 9 Kolkhir P, Altrichter S, Munoz M, Hawro T, Maurer M. New treatments for chronic urticaria. *Ann Allergy Asthma Immunol*. 2020 Jan;124(1):2-12. doi: 10.1016/j.anai.2019.08.014. Epub 2019 Aug 23. PMID: 31446134.
- 10 Asero R, Tedeschi A, Cugno M. Treatment of refractory chronic urticaria: current and future therapeutic options. *Am J Clin Dermatol*. 2013 Dec;14(6):481-8. doi: 10.1007/s40257-013-0047-3. PMID: 24085572.
- 11 Godse KV, Nadkarni N, Patil S, Mehta A. Subcutaneous Autologous Serum Therapy in Chronic Spontaneous Urticaria. *Indian J Dermatol*. 2017 Sep-Oct;62(5):505-507. doi: 10.4103/ijd.IJD_710_16. PMID: 28979013; PMCID: PMC5618838.