

# **Lights and Shadows of Rituximab in Dermatology**

---

## **ABSTRACT**

Rituximab is a CD 20 monoclonal antibody drug used in various spectrum of diseases today. It has proven to be a boon, especially in the field of dermatology. Although Rituximab was initially introduced as a novel method to treat B-cell Non Hodgkin Lymphoma, its use has rapidly expanded to include a number of other Lymphomas and Autoimmune diseases. This review is to give a bird's eye view of updates on rituximab.

**Conclusion:** With its horizons expanding in dermatology, and with better information regarding its efficacy and safety profile, Rituximab has now become an approved first-line therapy for pemphigus. In conclusion, Rituximab has proven to be a substantial boon for dermatologists in difficult to treat cases.

*Keywords: monoclonal antibodies, CD20, Lymphoma protocol, Rheumatoid arthritis protocol, non-Hodgkin's lymphoma (NHL), pemphigus vulgaris (PF), Pemphigus foliaceus (PF), RTX (Rituximab)*

## **1. INTRODUCTION**

### **1.1 Journey of Discovery**

Rituximab was a monoclonal antibody drug brought to market in 1996 and revolutionized the field of therapeutics with monoclonal antibodies. The journey to the discovery and approval of Rituximab has been long and slow. The seed of the idea to use monoclonal antibodies to treat cancer occurred to Dr. César Milstein and Dr. Georges Köhler, two NCI(National Cancer Institute) funded researchers who perceived that the cancer cells could be attacked by isolating proteins specific to these cells. So, they came up with the idea of producing antibodies which would selectively eliminate target cells with those proteins. They called these "monoclonal antibodies" (1). Monoclonal antibodies were first used in trials in 1980 on patients with Non-Hodgkin's Lymphoma. This won the two Researchers, the 1984 Nobel Prize in Physiology and Medicine. (2)

The search began in earnest for a target protein that was specific to cancer cells and would selectively eliminate cancer without causing much damage to healthy cells. In 1986, Muromonab, the first monoclonal antibody was released which targeted CD03 proteins(2). It had a clinical use in treatment acute graft rejection of kidney transplant. But it suffered from issues of target choice.

In 1988, CD20 was identified as a protein on B cells. In spite of both healthy and cancerous cells having CD20, it was realised that immature cells would be spared which could

replenish the healthy cells(3). Efforts to create a monoclonal antibody to target this protein to treat B cell lymphomas began.

Rituximab was created by Ronal Levy as a drug that could target B-cells. A pharmaceutical company conducted the first clinical trial and was granted Food and Drug Administration (FDA) approval in 1997 and a United States patent in 1998(4). After its release, a number of clinical trails reinforced the efficacy of Rituximab in lymphomas (5). Currently it has been used in various conditions which involve the pemphigus group of disorders and a number of other cutaneous disorders which we have discussed below.

## **1.2 CD 20 as a Target**

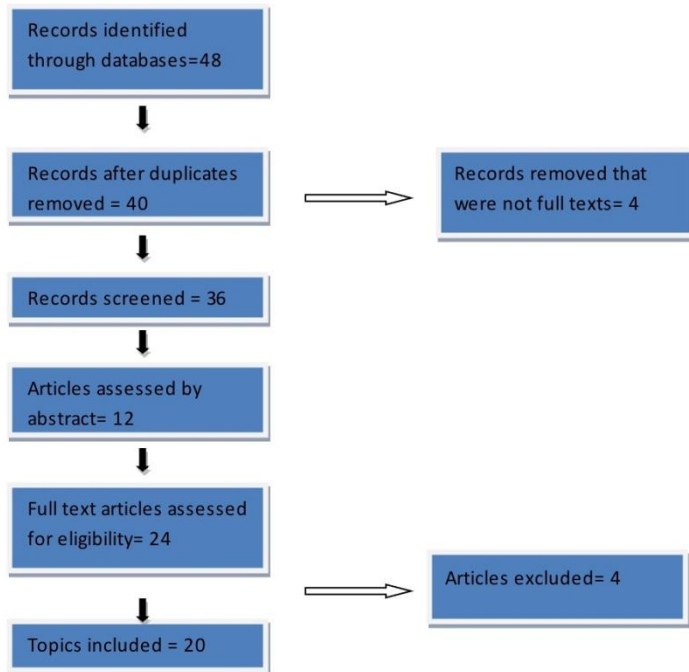
CD20 is a tetra-transmembrane protein found chiefly in B cell lineages. CD20 is a non-glycosylated phosphoprotein which weights 33-37 kDa(6). It has two extracellular loops and an N and C terminal regions. The two loops (small and large loops) are the standard target for therapeutics. The expression of CD20 begins at the pre-B cell stage and is present till Plasma cell stage(7). The biological function of CD20 remains largely unknown, though some research has shed light on its possible functions (8)

CD20 is thought to act as an ion channel for Calcium and regulates intake and storage of calcium in the B-cells. The role that it plays in differentiation of B-cells is believed to be mediated by calcium. Ectopic expression on fibroblast also lead to increased calcium conductance (9). Mice who have had their CD20 knocked out, did not have any gross retardation of growth and development (10). Various other potential functions have also been studied such as effects on the growth cycle and tyrosine and other protein kinase activation. New data suggests that CD20 could also be responsible for the organisation of receptors on the B-cell surface. (Clustered regularly interspaced short palindromic repeats) CRISP/Cas9 mediated ablation led to delocalisation of the IgM antigens receptor and CD19 receptors. This led to activation of B cells transiently. Rearrangement of receptors on a nano scale was also noted(11). This shows that CD20 may also have a significant role in membrane organisation of other receptors and general mediator of B-cell activation as well.

## **2. Review Methodology**

The review article was done by exploring numerous review articles, original articles and related books from various databases. Duplicates were removed and finally 20 full text articles were screened after assessing eligible articles.

Limitations of the study: Most of this review is done for the value of rituximab in dermatology. The limitations of the review are that it has not delved much in fields other than dermatology.



## 2.1 Mechanism of Rituximab action.

Rituximab binds to CD20 receptors and facilitates cell death. It binds to CD20 forming a cap which acts as an effective mediator for NK cell dependent cell death as well.

In vitro studies have shown that cell death can be triggered without the need for immune based effectors. A Caspase dependent and Caspase independent pathway have been elucidated. When Rituximab binds to CD20, lipid rafts are rearranged and alters the localisation of CD20 (12). This rearrangement is believed to lead to caspase dependent cell death, though the exact mechanism isn't fully understood.(13). Caspase independent pathways such as lysosome mediated cell death has been found in the absence of lipid raft formation (14).

Rituximab opsonizes target B cells which are bound by the C1 complement. The Classical complement cascade is activated leading to the formation of C5-9 Membrane Attack Complexes that insert into the tumour cell and lead to cell death.(15) CDC completes with ADCC in vitro which may compromise the therapeutic goals (16).

Antibody dependent cell mediated cytotoxicity (ADCC) has proven to be a much more effective mode of cell death than complement dependent cytotoxicity (CDC). The monoclonal antibody binds to CD20 which caused the binding of Fc region to FcRIII on NK cell which triggers them to release perforin. Perforin creates pore in the cell wall leading to cell death. Despite its effectiveness ADCC remains hard to quantify in vitro.(17, 18)

## 2.2 PHARMACOKINETICS:

Rituximab is administered as intravenous infusion. Following the lymphoma protocol, it can be detected in the serum of patients even after 6 months of completion of therapy. The half life of median terminal elimination is 22 days. (20)

## 2.3 Spectrum of Clinical Use

### **Food and Drug Administration approved for**

- Non Hodgkin's B Cell lymphoma
- Chronic lymphocytic leukemia
- Rheumatoid arthritis
- Pemphigus group of disorders (21)

### **2.3.1 Rituximab in Pemphigus**

Heizmann *et al*, in 2001 reported a case of paraneoplastic pemphigus successfully treated by rituximab which was used for the first time for an autoimmune bullous disease.(20) Subsequent to this, many physicians used rituximab for treating various immunobullous disorders.(21)

*Children:* Currently rituximab is not recommended for use in children due to limited experience. However, there have been few authors who have used rituximab in childhood pemphigus which showed no long term adverse affects.(22,23) It is therefore essential to analyse the advantages of the drug with its potential for causing adverse effects in pediatric age group.

*Pregnancy and Lactation:* Rituximab is a pregnancy category C drug, where it is not recommended in pregnancy or lactation. (24)

### **Treatment Protocols**

The various treatment protocols followed for administration of rituximab include:

1. Lymphoma protocol- Administration of intravenous Rituximab at a weekly dose of  $375\text{mg}/\text{m}^2$  body surface area for four weeks. (25)
2. Rheumatoid arthritis protocol- Administration of two doses of rituximab 1000 mg at an interval of 15 days. This is the protocol currently followed in our institute. Advantage of this protocol include less cost and fewer infusions. (26)
3. Combination therapy- Rituximab has been used in combination with IVIg, immunoadsorption and dexamethasone pulse therapy. (25)
4. Modified rheumatoid arthritis protocol- A study was done in 2020 where a single treatment course ranging from 2 to 5 infusions of 1gm rituximab during an interval of four weeks was considered safe in pemphigus treatment. (26)

### **Pre-medication and rituximab administration**

Before starting an infusion, baseline investigations should be done which include screening for tuberculosis, hepatitis B and C, Human immunodeficiency virus, Cardiopulmonary disease. A complete blood count, liver function test, renal function test should be investigated.(25) Patient is pre-medicated 30 minutes prior to infusion, with intravenous (IV) hydrocortisone 100mg, along with intravenous pheneramine maleate 22.75mg and oral paracetamol 500mg. 100ml of normal saline is emptied and 1000mg of rituximab is added to the 400ml of normal saline. First infusion is administered intravenously at a rate of 50mg/h, escalated every 30min by 50mg/h to a maximum infusion rate of 400mg/h. The total time for the infusion is 5 to 6 hours.(25)

### **2.3.2 Rituximab in mucous membrane pemphigoid**

Owing to its rarity, literature on the use of rituximab (RTX) in mucous membrane pemphigoid (MMP) is limited. Le Roux-Villet et al. [27] in their study on 25 patients with severe refractory MMP have demonstrated rituximab to be a valuable therapeutic agent for MMP, administered according to the lymphoma protocol. In the study, within 3 months of the first RTX cycle, complete response was seen for both ocular and extraocular manifestations in 68% of patients. In 20% of patients, a second cycle of RTX was required to obtain complete clinical remission. In 88% of patients who developed complete clinical remission, 40% of patients relapsed within 4 months after completion of treatment, thereby suggesting that the effects of RTX in MMP are short lived. [27]

### **2.3.3 Rituximab in dermatomyositis**

RTX has been utilized in treating both adult and juvenile dermatomyositis (DM). In the study by Cooper et al.,[28] with RTX on four children for recalcitrant juvenile DM, utilizing the standard lymphoma protocol, three reported clinical improvement with the fourth patient demonstrating progression of the disease. Of these, one patient who was positive for anti-Mi-2 demonstrated a dramatic response to two cycles of RTX given at an interval of 1 year. Along with Rituximab, this patient also received weekly methotrexate. In adult Dermatomyositis also, Rituximab has demonstrated good results. Levine [29] has expressed that both muscle symptoms and cutaneous signs improve following Rituximab administration according to the lymphoma protocol.

### **2.3.4 Rituximab in cutaneous lupus erythematosus**

RTX has been introduced in those patients who are unresponsive or intolerant to standard conventional treatment. It has been proven that CD20+ B cells play an important role in the pathogenesis of Systemic lupus erythematosus and Subacute Cutaneous Lupus Erythematosus. Apart from being an antigen presenter, B cells produce autoantibodies and are responsible for secreting a number of inflammatory cytokines that enhance inflammation. (33,34) As RTX plays an antagonistic role against these B cells, it may be of value in these patients. There have been various reports describing the successful use of RTX in Cutaneous Lupus Erythematosus. Both lymphoma and rheumatoid arthritis protocols have been utilized with equal efficacy.(33) Marks et al. [27] have utilized a modified protocol wherein 2 weekly infusions of 750 mg/m<sup>2</sup> of RTX was administered with good results.

### **2.3.5 Rituximab in vasculitis**

RTX has been utilized in treating ANCA-associated vasculitis (AAV).[54] The rationale behind using RTX in AAV is secondary to findings that B cell-targeted therapy reduced ANCA levels and in this way blocked disease pathogenesis.[55,56]

### **2.3.6 Rituximab in graft-versus-host disease**

Teshima et al. [60] have utilized RTX according to the lymphoma protocol in seven patients following hematopoietic stem cell transplantation. Following 1 year of treatment, partial response was seen in three patients, three patients had stable disease, and in the remaining one patient, the disease was progressive. It was, therefore, concluded that RTX is mainly effective in those cases of steroid refractory graft-versus-host disease that is not advanced, and if the manifestations involving the skin, eye, and fascia are severe, the role of RTX in this scenario is minimal.

### **2.3.7 Rituximab in atopic dermatitis**

Although T cells are the prime players in the pathogenesis of atopic dermatitis (AD), B cells too have a role here. RTX administered according to the rheumatoid arthritis protocol has demonstrated a significant improvement both clinically and histologically along with a slight reduction in the level of IgE. These effects were evident within 1–2 months of initiating treatment with RTX. [32]

### **2.3.8 Rituximab in melanoma**

Schlaak et al. [34] have used intralesional injections of RTX along with low-dose systemic dacarbazine therapy for melanoma. Long-lasting remission of tumor lesions was demonstrated by RTX.

### **2.3.9 Rituximab in primary cutaneous B cell lymphoma**

Only in aggressive forms of PCBCL does RTX have a role, which too at present is in the evolving phase. RTX has been administered both intralesionally (10 mg/lesion)[35] and systemically for PCBCL. In the systemic therapy, apart from the usual four doses at weekly intervals, in a selected subset of patients, six doses of RTX had been administered in the study by Valencak et al. [36] In their study, it was found that 87.5% of patients achieved complete clinical resolution, making them postulate that a single-agent treatment with IV RTX does result in a high rate of durable remissions and can be comparable to radiotherapy. Similarly, the response seen with intralesional RTX has been satisfactory.

### **2.3.10 Diffuse large B cell lymphoma (DLBCL)**

Diffuse large B cell lymphoma is the most common type of NHL constituting 40% of the global cases. It constitutes 60-70% of B-cell lymphomas in Asia, with an incidence of 38% in India. In western countries, DLBCL accounts for about 30-40% of all NHLs (20, 21). The tumour is generally considered to be fairly malignant with poor prognosis. The initially of Rituximab therapy in DLBCL has been extremely beneficial and has been shown to improve the prognosis. In 2001, the first trial using Rituximab to treat untreated DLBCL was published. It showed 94% response rate compared to historic CHOP controls (cyclophosphamide: H = Doxorubicin Hydrochloride (Hydroxydaunomycin) O = Vincristine Sulfate (Oncovin) P = Prednisone) (22). The first Phase 3 trial was conducted in 2002 which established the superiority of R-CHOP (rituximab-CHOP) over CHOP regimen (23). Despite

many further studies establishing the efficacy of R-CHOP in DLBCL, no guidelines on dosage has been agreed upon (24,25). Meta-analysis shows that Rituximab also improves Event free survival (EFS) and Progression Free Survival (PFS) of the patients (26).

### **2.3.11 Burkitt Lymphoma**

Burkitt's lymphoma discovered by Dr. Denis Burkitt in Africa, was an Epstein-Barr Virus associated lymphoma found in children. Extensive further research has shown many other types, identifying genetic mutation of MYC and establishing it as an aggressive lymphoma. It accounts for about 1-5% of adult Non-Hodgkin Lymphoma (NHL). A mixture of Cyclophosphamide, Methotrexate, Doxorubicin and Vincristine has been very effective in curing the disease in paediatric age groups (27). Research regarding Rituximab use in Burkitt lymphoma has shown that PFS and Overall Survival (OS) of the patients were improved. 3-year EFS was also improved, shown by another study (28). Meta-analysis has shown that there is a significant increase in overall survival with Rituximab (29).

### **2.3.12 Follicular Lymphoma**

Follicular lymphoma is a follicular centre B-cell malignancy. It is the second most common lymphoma in adults in India. It accounts for 20% of cases in the west. Follicular Lymphoma was the first cancer for which the FDA approved Rituximab (30). Phase 2 trial showed a 46% response rate and established the safety of its use and showed clear efficacy (31,32). This has firmly established R-CHOP as the gold standard in follicular lymphoma therapy.

### **2.3.13 Marginal Zone Lymphoma (MZL)**

Marginal zone lymphoma is an indolent lymphoma that accounts for 5-10% of NHL. Rituximab is added to treatment regimens for MZL but studies to prove the absolute efficacy have been minimal. Systemic treatment includes Rituximab and combination of other drugs like Bendamustine and Chlorambucil (33,34).

### **2.3.14 Mantle Cell Lymphoma**

MCL accounts for 2-4% of all NHL. It has an aggressive course. Rituximab has been proven efficacious as a maintenance therapy. R-CHOP has a PFS of 16-17 months which is shorter than expected (35). Rituximab has also been used in combination with Bendamustine, Cytarabine and Fludrabine to treat MCL (36).

### **2.3.15 Lymphocytic Lymphomas**

Lymphocytic lymphomas are a rare type of tumour with a median survival of 5-10 years. The most common LL is Waldenström's macroglobulinemia (37, 38). Many drugs are used including Rituximab, Fludrabine, Cyclophosphamide etc. Rituximab causes an IgM flare and

cannot be used unless the IgM levels are below 4000mg/dL (39).MR regimane has shown to improve the survival of these patients (40,41,42).

### **2.3.16 Autoimmune disease.**

Rituximab as a treatment has now entered the domain of non malignant disease, specifically autoimmune diseases such as rheumatoid arthritis (43), pemphigus (44), vasculitis and even neuromyelitis optica (45).The mechanism in autoimmune disease is depletion of normal B-cells and reduction of the adaptive immunity. FDA approval for use in Rheumatoid arthritis was obtained in 2006. Meta-analysis show that Rituximab helps to give symptomatic relief and can even be refractory in some cases. Remission occurs even in patients of Pemphigus, Neuromyelitis optics, Pemphigoid and Myasthenia gravis. But Rituximab has been not been found to be effective in Lupus (46).

### **2.3.17 Rituximab and Sars COVID 19**

In the post-Rituximab period, it is not advisable to get vaccinated for COVID 19 for a period of atleast 6 months. A period of 4 weeks interval must be maintained between second vaccine dose and next cycle of Rituximab.(49)

### **3.Contraindications**

- Hypersensitivity to the drug
- Hypersensitivity to murine proteins
- Severe heart failure
- HIV infection with CD4 count (47)

### **4.Adverse effects:**

#### **4.1. Cutaneous**

- Frequent but not so serious: Night sweats, skin rash, urticaria, and pruritis.
- Serious side effects: Paraneoplastic pemphigus, toxic epidermal necrolysis, Stevens–Johnson syndrome, vasculitis, lichenoid dermatitis, and delayed proinflammatory syndrome which occurs at or near completion of a 4-week intense course of Rituximab.[49]

#### **4.2 Noncutaneous**

- Fatal infusion reactions usually in the first infusion
- Tumor lysis syndrome

- Hepatitis B reactivation with related fulminant hepatitis
- Cardiac arrhythmias
- Cytopenias
- Rarely, progressive multifocal leukoencephalopathy.

5. **CONCLUSION:**

The success of Rituximab has led to the creation of dozens of monoclonal antibodies that have birthed a new field of medical therapeutics. Through this review, we would like to tell and encourage our fellow colleagues to the use of rituximab in dermatology. The use of Rituximab in a patient may lead to varied forms of outcome, as some may respond well and show excellent improvement. There is also a possibility of recurrence or sometimes, no improvement at all. With its horizons expanding in dermatology, and with better information regarding its efficacy and safety profile, Rituximab has now become an approved first-line therapy for pemphigus. In conclusion, Rituximab has proven to be a substantial boon for dermatologists in difficult to treat cases.

**CONSENT:** Not applicable

**ETHICAL APPROVAL:** Not applicable

**COMPETING INTERESTS DISCLAIMER:**

Authors have declared that no competing interests exist. The products used for this research are commonly and predominantly use products in our area of research and country. There is absolutely no conflict of interest between the authors and producers of the products because we do not intend to use these products as an avenue for any litigation but for the advancement of knowledge. Also, the research was not funded by the producing company rather it was funded by personal efforts of the authors.

**REFERENCES**

1. Cambier JC, Gauld SB, Merrell KT, Vilen BJ, B-cell anergy: from transgenic models to naturally occurring anergic B cells? *Nat Rev Immunol.* 2007 Aug; 7(8):633-43
2. Butler LA, Tam CS, Seymour JF, Dancing partners at the ball: Rational selection of next generation anti-CD20 antibodies for combination therapy of chronic lymphocytic leukemia in the novel agents era. *Blood Rev.* 2017 Sep; 31(5):318-327.
3. Li H, Ayer LM, Lytton J, Deans JP, Store-operated cation entry mediated by CD20 in membrane rafts. *J Biol Chem.* 2003 Oct 24; 278(43):42427-34.
4. Uchida J, Lee Y, Hasegawa M, Liang Y, Bradney A, Oliver JA et al. Mouse CD20 expression and function. *Int Immunol.* 2004 Jan; 16(1):119-29.
5. Katherine Kläsener, Julia Jellusova, Geoffroy Andrieux, Ulrich Salzer, Chiara Böhrer, Sebastian N Stein. CD20 as gatekeeper of the resting state of human B cells. *PNAS* Feb 16 2021, 118(7) e2021342118.
6. Bezombes C, Fournié JJ, Laurent G, Direct effect of rituximab in B-cell-derived lymphoid neoplasias: mechanism, regulation, and perspectives. *Mol Cancer Res.* 2011 Nov; 9(11):1435-42.
7. Unruh TL, Li H, Mutch CM, Shariat N, Grigoriou L, Sanyal R et al. Cholesterol depletion inhibits src family kinase-dependent calcium mobilization and apoptosis induced by rituximab crosslinking. *Immunology.* 2005 Oct; 116(2):223-32.
8. Ivanov A, Beers SA, Walshe CA, Honeychurch J, Alduaij W, Cox KL et al. Monoclonal antibodies directed to CD20 and HLA-DR can elicit homotypic adhesion followed by lysosome-mediated cell death in human lymphoma and leukemia cells. *J Clin Invest.* 2009 Aug; 119(8):2143-59.
9. Golay J, Introna M. Mechanism of action of therapeutic monoclonal antibodies: promises and pitfalls of in vitro and in vivo assays. *Arch Biochem Biophys.* 2012 Oct 15; 526(2):146-53.
10. Beers SA, Cragg MS, Glennie MJ. Complement: help or hindrance? *Blood.* 2009 Dec 24; 114(27):5567-8; author reply 5568.
11. Osińska I, Popko K, Demkow U. Perforin: an important player in immune response. *Cent Eur J Immunol.* 2014; 39(1):109-15.
12. Clynes RA, Towers TL, Presta LG, Ravetch JV. Inhibitory Fc receptors modulate in vivo cytotoxicity against tumor targets. *Nat Med.* 2000 Apr; 6(4):443-6.
13. Timothy M Pierpont, Candice B Limper, Kristy L Richards. Past, Present and Future of Rituximab-The Worlds First Oncology Monoclonal Antibody Therapy *Front Oncol*, 2018; 8: 163
14. Heizmann M, Itin P, Wernli M, Borradori L, Bargetzi MJ. Successful treatment of paraneoplastic pemphigus in follicular NHL with rituximab: report of a case and review of treatment for paraneoplastic pemphigus in NHL and CLL. *Am J Hematol* 2001;66:142-4.

15. Goebeler M, Herzog S, Brocker EB, Zillikens D . Rapid response of treatment-resistant pemphigus foliaceus to the anti-CD20 antibody rituximab. *Br J Dermatol* 2003;149:899-901.
16. Kanwar AJ, Tsuruta D, Vinay K, Koga H, Ishii N, Dainichi T, *et al.* Efficacy and safety of rituximab treatment in Indian pemphigus patients. *J Eur Acad Dermatol Venereol* 2011.
17. Reguiat Z, Tabary T, Maizieres M, Bernard P . Rituximab treatment of severe pemphigus: Long-term results including immunologic follow-up. *J Am Acad Dermatol* 2012.
18. Chakravarty EF, Murray ER, Kelman A, Farmer P . Pregnancy outcomes after maternal exposure to rituximab. *Blood* 2011;117:1499-506.
19. Craythorne EE, Mufti G, DuVivier AW . Rituximab used as a first-line single agent in the treatment of pemphigus vulgaris. *J Am Acad Dermatol* 2011;65:1064-5.
20. Sakhiya J, Sakhiya D, Khambhati R, Patel M, Darji P, Gajjar T *et al.* Modified Rheumatoid Arthritis Protocol for Rituximab in Pemphigus: A Retrospective Case Series. *J Clin Aesthet Dermatol.* 2020 Feb;13(2):47-52. Epub 2020 Feb 1. PMID: 32308784; PMCID: PMC7158908.
21. Rhee EP, Laliberte KA, Niles JL. Rituximab as maintenance therapy for anti-neutrophil cytoplasmic antibody-associated vasculitis. *Clin J Am Soc Nephrol* 2010;5:1394-400.
22. Xiao H, Heeringa P, Hu P, Liu Z, Zhao M, Aratani Y, *et al.* Antineutrophil cytoplasmic autoantibodies specific for myeloperoxidase cause glomerulonephritis and vasculitis in mice. *J Clin Invest* 2002;110:955-63.
23. Specks U, Fervenza FC, McDonald TJ, Hogan MC. Response of Wegener's granulomatosis to anti-CD20 chimeric monoclonal antibody therapy. *Arthritis Rheum* 2001;44:2836-40.
24. Popa ER, Stegeman CA, Bos NA, Kallenberg CG, Tervaert JW. Differential B- and T-cell activation in Wegener's granulomatosis. *J Allergy Clin Immunol* 1999;103:885-94.
25. Jones RB, Ferraro AJ, Chaudhry AN, Brogan P, Salama AD, Smith KG, *et al.* A multicenter survey of rituximab therapy for refractory antineutrophil cytoplasmic antibody-associated vasculitis. *Arthritis Rheum* 2009;60:2156-68.
26. Martinez Del Pero M, Chaudhry A, Jones RB, Sivasothy P, Jani P, Jayne D. B-cell depletion with rituximab for refractory head and neck Wegener's granulomatosis: A cohort study. *Clin Otolaryngol* 2009;34:328-35
27. Schlaak M, Schmidt P, Bangard C, Kurschat P, Mauch C, Abken H. Regression of metastatic melanoma in a patient by antibody targeting of cancer stem cells. *Oncotarget* 2012;3:22-30.
28. Peñate Y, Hernández-Machín B, Pérez-Méndez LI, Santiago F, Rosales B, Servitje O, *et al.* Intralesional rituximab in the treatment of indolent primary cutaneous B-cell lymphomas: An epidemiological observational multicentre study. The Spanish working group on cutaneous lymphoma. *Br J Dermatol* 2012;167:174-9.
29. Ferri C, Govoni M, Calabrese L. The A, B, Cs of viral hepatitis in the biologic era. *Curr Opin Rheumatol* 2010;22:443-50.

30. Nie M, Wang Y, Bi XW, Xia Y, Sun P, Liu PP. Effect of rituximab on adult Burkitt's lymphoma: a systematic review and meta-analysis. *Ann Hematol*. 2016 Jan; 95(1):19-26.
31. Sorigue M, Sancho JM. Current prognostic and predictive factors in follicular lymphoma. *Ann Hematol*. 2018 Feb; 97(2):209-227.
32. Risselada AP, Kallenberg CG. Therapy-resistant lupus skin disease successfully treated with rituximab. *Rheumatology (Oxford)* 2006;45:915-6.
33. Raderer M, Jäger G, Brugger S, Püspök A, Fiebiger W, Drach J et.al. Rituximab for treatment of advanced extranodal marginal zone B cell lymphoma of the mucosa-associated lymphoid tissue lymphoma. *Oncology*. 2003; 65(4):306-10.
34. Dreyling M, Aurer I, Cortelazzo S, Hermine O, Hess G, Jerkeman M et.al. PL. Treatment for patients with relapsed/refractory mantle cell lymphoma: European-based recommendations. *Leuk Lymphoma*. 2018 Aug; 59(8):1814-1828.
35. Chang JE, Carmichael LL, Kim K, Peterson C, Yang DT, Traynor AM. VcR-CVAD Induction Chemotherapy Followed by Maintenance Rituximab Produces Durable Remissions in Mantle Cell Lymphoma: A Wisconsin Oncology Network Study. *Clin Lymphoma Myeloma Leuk*. 2018 Jan; 18(1):e61-e67.
36. Leleu X, Gay J, Roccaro AM, Moreau AS, Poulain S, Dulery R. Update on therapeutic options in Waldenström macroglobulinemia. *Eur J Haematol*. 2009 Jan; 82(1):1-12.
37. Benevolo G, Nicolosi M, Santambrogio E, Vitolo U. Current options to manage Waldenström's macroglobulinemia. *Expert Rev Hematol*. 2017 Jul; 10(7):637-647.
38. Dimopoulos MA, Zervas C, Zomas A, Kiamouris C, Viniou NA, Grigoraki V. Treatment of Waldenström's macroglobulinemia with rituximab. *J Clin Oncol*. 2002 May 1; 20(9):2327-33.
39. Treon SP, Hanzis C, Manning RJ, Ioakimidis L, Patterson CJ, Hunter ZR. Maintenance Rituximab is associated with improved clinical outcome in rituximab naïve patients with Waldenström Macroglobulinaemia who respond to a rituximab-containing regimen. *Br J Haematol*. 2011 Aug; 154(3):357-62.
40. Grever MR, Abdel-Wahab O, Andritsos LA, Banerji V, Barrientos J, Blachly JS. Consensus guidelines for the diagnosis and management of patients with classic hairy cell leukemia. *Blood*. 2017 Feb 2; 129(5):553-560.
41. Gomes LC, Ferrão ALM, Evangelista FCG, de Almeida TD, Barbosa RC, Carvalho MDG. Advances in chronic lymphocytic leukemia pharmacotherapy. *Biomed Pharmacother*. 2018 Jan; 97():349-358.
42. Schioppo T, Ingegnoli F. Current perspective on rituximab in rheumatic diseases. *Drug Des Devel Ther*. 2017; 11():2891-2904.
43. Wang HH, Liu CW, Li YC, Huang YC. Efficacy of rituximab for pemphigus: a systematic review and meta-analysis of different regimens. *Acta Derm Venereol*. 2015 Nov; 95(8):928-32.

44. Collongues N, Brassat D, Maillart E, Labauge P, Ouallet JC, Carra-Dalliere C, OFSEP and CFSEP. Efficacy of rituximab in refractory neuromyelitis optica. *Mult Scler*. 2016 Jun; 22(7):955-9.

45. Merrill JT, Neuwelt CM, Wallace DJ, Shanahan JC, Latinis KM, Oates JC et al. Efficacy and safety of rituximab in moderately-to-severely active systemic lupus erythematosus: the randomized, double-blind, phase II/III systemic lupus erythematosus evaluation of rituximab trial. *Arthritis Rheum*. 2010 Jan; 62(1):222-33.

46. Coiffier B, Sarkozy C. Diffuse large B-cell lymphoma: R-CHOP failure—what to do? *Hematology Am Soc Hematol Educ Program* (2016) 2016:366–78. [10.1182/asheducation-2016.1.366](https://doi.org/10.1182/asheducation-2016.1.366)

47. Schmidt E, Goebeler M, Zillikens D . Rituximab in severe pemphigus. *Ann N Y Acad Sci* 2009;1173:683-91.

48. Buda-Okreglak EM, Drabick JJ, Delaney NR. Proinflammatory syndrome mimicking acute rheumatoid arthritis in a patient with Waldenstrom's macroglobulinemia treated with rituximab. *Ann Hematol* 2004;83:117-9.

49. Munisamy M, Singh BS, Pandhi D. Recommendations for COVID vaccination for dermatological patients on immunosuppressive/ immunomodulatory therapy. *Indian Dermatol Online J* 2021;12:S4-11.

UNDER PEER REVIEW