

Original Research Article

Evaluation of anti-inflammatory and antioxidant effects of punicalagin (Pomegranate Extract) on IL-1 beta and superoxide dismutase levels in patients with chronic periodontitis – A Randomized Controlled Trial

Tamilselvan Kumar¹, Jacob Raja S A², Johnson Raja James³, Ravi Sankar M S⁴, Fairlin P⁵ and Dhivya Surendhar⁶.

¹Senior Lecturer, Department of Periodontics and Implantology, Rajas Dental College and Hospital, Kavalkinaru Junction, Tirunelveli, Tamilnadu, India.

²Professor and Chairman, Department of Periodontics and Implantology, Rajas Dental College and Hospital, Kavalkinaru Junction, Tirunelveli, Tamilnadu, India.

³Head of the Department, Department of Periodontics and Implantology, Rajas Dental College and Hospital, Kavalkinaru Junction, Tirunelveli, Tamilnadu, India.

⁴Reader, Department of Conservative Dentistry and Endodontics, Rajas Dental College and Hospital, Kavalkinaru Junction, Tirunelveli, Tamilnadu, India.

⁵Senior Lecturer, Department of Periodontics and Implantology, Rajas Dental College and Hospital, Kavalkinaru Junction, Tirunelveli, Tamilnadu, India.

⁶Senior Lecturer, Department of Periodontics and Implantology, JKK Nattraja Dental College and Hospital, Komarapalayam, Namakkal dt, Tamilnadu, India.

ABSTRACT

Purpose: Pomegranates have been shown to possess anti-inflammatory and antioxidant **properties**. This study aimed to evaluate the effects of Punicalagin (Pomegranate extract) on IL-1 β and SOD levels in chronic periodontitis patients. **Materials and Methods:** 30 patients were included in the study. The sites were randomly divided into control site and test site. Control sites were treated with Scaling and Root Planing (SRP) alone and test sites were treated with punicalagin gel along with SRP. Clinical **parameters** such as probing pocket depth, Clinical Attachment Level (CAL), Gingival Index (GI), Plaque index (PI), Sulcus Bleeding Index (SBI) and biochemical markers such as IL-1 β and **Superoxide** Dismutase levels were compared between baseline and at 21 days post therapy. **Results:** Test sites showed significant differences when compared to control sites in relation to all clinical and biochemical parameters. **Conclusion:** Within the limitations of this study, there is an improvement in the clinical parameters with an increase in the anti-oxidant marker level and a decrease in inflammatory marker level when punicalagin gel was placed along with Scaling and Root Planing in patients with Chronic Periodontitis.

KEYWORDS: Punicalagin, IL-1 β , Superoxide Dismutase **and Chronic periodontitis**.

INTRODUCTION

Periodontitis is an inflammatory condition which results in the destruction of the tooth supporting structures. The fundamental mechanisms of this destructive process which involves the both direct tissue damage resulting from the plaque bacterial products, and the indirect damage caused through the bacterial induction of the host inflammatory and immune responses. [1]

The elimination of periodontopathogens containing biofilm remains the first goal of periodontal therapy. Although mechanical debridement such as Scaling and Root Planning (SRP) reduces the level of subgingival bacteria and thereby inflammatory mediators, it does not completely eliminate the pathogens that resides deep into the connective tissue. [2]

The restrictions of this conventional periodontal therapy led to the development of many chemical agents such as antiseptics, NSAIDS and antibiotics. The Systemic delivery requires the administration of a larger doses and also has led to the development of bacterial resistance, drug interactions and also the inconsistent patient compliance. [3] In order to overcome the drawbacks of systemic administration, local drug delivery system was introduced.

In the Local Drug Delivery systems, the drug can be delivered to the site of the disease activity at a required concentration and can facilitate the prolonged drug delivery system. [4] Among the many herbs available, Pomegranate extracts have been reported to have many beneficial health effects, exhibiting antioxidant, anti-inflammation, antiproliferative, and DNA repair activities, which are generally attributed to the high polyphenol content. [5]

Cytokines are one of the soluble proteins which is produced by the structural and inflammatory cells, into extracellular fluid, and their role in maintenance of tissue homeostasis requires the delicate balance between the catabolic and the anabolic activities. Cytokines evident potent pro-inflammatory and the catabolic activity, which may play a key role in local amplification of immune response as well as periodontal tissue breakdown. Among the chemical mediators released by the host cells in response is to inflammatory stimulus, IL-1 beta plays a major role in the pathogenesis of periodontal diseases. IL-1 beta has been demonstrated at increased the levels in inflamed gingival tissues and gingival crevicular fluid. It is one of the most potent inducers of bone resorption and promotes connective tissue degradation through the induction of Matrix metalloproteinase (MMPs) gene expression. [6]

Pomegranate extract have been shown to inhibit the IL-1 β induced destruction of proteoglycan, which expression of MMPs at the cellular level, NO and PGE₂ production. [7] Pomegranate therefore could be beneficial in treating periodontitis as it possess excellent anti-inflammatory effect.

Reactive oxygen species (ROS) plays an important role in tissue destruction when produced in excess. Antioxidants are groups of substances that are able to prevent the oxidation reaction of ROS, thereby offering protection. Currently, there is a growing interest in the linkage between antioxidants and periodontal disease. Superoxide Dismutase (SOD) an important antioxidant enzyme has been localized within the human periodontal ligament which may represent an important defence mechanism within the gingival cells against the superoxide release.[8]

The Superoxide Dismutase activity significantly improved following periodontal therapy, suggesting a positive response to nonsurgical periodontal therapy. Therefore, treatment of periodontal disease reduces oxidative stress by a concomitant reduction in inflammatory load by enhancing antioxidant levels. Pomegranate was found to exert potent antioxidant activity against lipid peroxidation. [9] The free radical scavenging activity of pomegranate depends on the polyphenols that involves electron donation to free radicals that converts them to relatively more stable compounds. Pomegranate extract exhibits inhibition of LPS induced oxidative stress by reducing ROS and NO generation and increasing Superoxide Dismutase 1 mRNA expression.

Pomegranate is rich in polyphenols such as Ellagitanins, Punicalagins, Punicallin and Gallotanin. The high antioxidant and anti inflammatory activity of pomegranate is due to high content of punicalagin. [10] Although various forms of pomegranate extract has been used, in our present study it is used as a gel form since they can deliver the drug to the site of disease activity at a required concentration and also can facilitate prolonged drug delivery.

Based on the anti-inflammatory and antioxidant properties of punicalagin, the present study is designed to analyse the levels of IL-1 beta and Superoxide Dismutase in GCF after 21 days of subgingival application with punicalagin gel, as an adjunct to Scaling and Root Planing in patients with Chronic Periodontitis.

MATERIALS AND METHODS

A randomized controlled, split mouth clinical study was conducted to evaluate the effectiveness of subgingival application of punicalagin gelatin film as an adjunct to Scaling and Root Planning compared with scaling and root planning alone in patients with chronic periodontitis. The protocol was reviewed and approved by institutional ethical board. The study related procedures were explained to the patients before they sign an informed consent form. A total of 30 subjects each with bilateral 5-6 mm probing pocket depth (PPD) were recruited (as shown in Figures 1A and 1B) from the outpatient in Department of Periodontics, J.K.K. Nattraja Dental College and Hospitals, Kumarapalayam, Tamilnadu.

Inclusion criteria were chronic periodontitis patients between the age group of 30 – 50 years having atleast 20 teeth. patients should have a minimum of 2 sites with more than 5mm of pocket depth as assessed by Williams periodontal probe and atleast 6 sites which shows bleeding on probing. Exclusion criteria were patients who are affected by known systemic diseases, pregnant and lactating women, smokers, alcoholics and who received any chemotherapeutic agents, mouth rinse or oral irrigation during past 6 months. Patients who received surgical or non surgical therapy in last 6 months and patients with Aggressive Periodontitis were also excluded.

Selected sites were randomly divided into control sites and experimental sites as follows

Group I and Group II are consist of different sites from the same patients (Split mouth trial).

- **Group I** - It consists of 30 sites, in which Scaling and Root Planning (SRP) was done (control sites) as shown in Figure 2.
- **Group II** - It consists of 30 sites, in which scaling and root planning was followed by the placement of the punicalagin gelatin film inside the pocket (SRP + Punicalagin gelatin film) (Test sites).

CLINICAL PARAMETERS

The following variables were measured at baseline and at 21 days

- Plaque index (PI) (Silness and Loe 1964)
- Gingival index (GI) (Loe and Silness 1963)
- Sulcus Bleeding Index (SBI) (Muhlemann HR and Sen S 1971)

- Probing Pocket Depth (PPD)
- Clinical attachment level (CAL)

Minimum Inhibitory Concentration (MIC) was determined with 96-well plate microdilution method. Film formulations were prepared using the solvent casting technique (Table 1).

Non-Surgical Periodontal Therapy

At baseline full mouth ultrasonic scaling was done. Under local anesthesia with 2% lignocaine solution (1:80,000), root planning was done in the test and control sites using area-specific double-ended Gracey curettes (Hu-Friedy). The test site was isolated with cotton rolls to prevent contamination with saliva. **The Gingival Crevicular Fluid (GCF) sample was collected using microcapillary glass.** The Punicalagin gel was carried with a tweezer and placed in the periodontal pocket as shown in Figure 3. The pocket opening was covered with Coe-pak to retain the material in the pocket, as well as to prevent the ingress of oral fluids.

Oral hygiene maintenance instructions were given as in Appendix I. Subjects were recalled at 7th and 14th day for application of punicalagin gelatin film and after 21 days post operative GCF samples were collected. Clinical parameters recordings were repeated after 21 days as shown in Figures 4A and 4B.

Determination of IL-1 β level in GCF using ELISA

Level of IL-1 β and SOD in the GCF was **assayed by using commercially available Human IL-1 beta ELISA reagent set (e-Bioscience) and SOD kit respectively.**

STATISTICAL ANALYSIS

The consort flow chart of this study is shown in the Figure 5. The results obtained were analyzed statistically and comparisons were made between groups using Paired samples t test. 'p value' between Group I and Group II post-operatively were evaluated. $p < 0.001$ denoted statistically significant and also denotes less than one in a thousand chance of being wrong. $p < 0.05$ denotes that there is only 5% chance that the null hypothesis is true. The statistical analysis was done using SPSS software Version 19.

RESULTS

The composition of the Punicalagin gelatin film is shown in the Table 1.

Clinical evaluation

A total of 30 subjects were selected for the study and were divided in a split mouth design. Group I subjects were treated with SRP alone, whereas in Group II subjects local delivery of punicalagin gel along with SRP was done. No patient reported any discomfort or adverse reaction.

Plaque index (PI)

The mean Plaque Index score at baseline was found to be 2.37 ± 0.62 . After 21 days of treatment the value was reduced to 1.39 ± 0.58 as shown in Table 2. Statistically significant difference was found between baseline to 21 days post-treatment ($p < 0.001$).

Gingival Index (GI)

At baseline, the mean Gingival Index score was 2.53 ± 0.67 , and was reduced to 1.43 ± 0.52 after 21 days post-treatment as shown in Table 2. There was statistically significant reduction in gingival index after 21 days post-treatment ($p < 0.001$).

Sulcus Bleeding Index (SBI)

SBI at baseline was 2.75 ± 0.28 and was decreased to 1.75 ± 0.29 after 21 days post-therapy as shown in Table 2. There was statistically significant decrease in bleeding after 21 days post-therapy ($p < 0.001$).

Probing pocket depth (PPD)

In Group I the mean PPD at baseline was 5.69 ± 0.00 mm and after 21 days of post-treatment the value reduced to 2.92 ± 0.17 mm. In Group II, at baseline the mean PPD was 5.74 ± 0.00 mm, and at 21 days reduced to 2.05 ± 0.62 mm as shown in Table 3. Group II showed more statistically significant reduction in PPD at 21 days post-therapy, compared to group I ($p < 0.001$).

Clinical Attachment Level

In Group I, at baseline the mean CAL was 3.69 ± 0.22 mm and at 21 days reduced to 1.82 ± 0.48 mm. In Group II, at baseline the mean CAL was 3.74 ± 0.38 mm and at 21 days reduced to 0.82 ± 0.22 mm as shown in Table 4. Group II showed more statistically significant gain in CAL at 21 days post-therapy, compared to group I ($p < 0.001$).

IL-1 β level in GCF

At baseline, the mean level of IL-1 β in GCF in Group I was 78.23 ± 0.36 pg/ml and decreased to 59.53 ± 0.22 pg/mL 21 days after therapy. In Group II, the baseline value was 79.36 ± 0.18 pg/ml and decreased to 37.9 ± 0.83 pg/ml after 21 days post-therapy as shown in Table 5. There was statistically significant decrease in the level of IL-1 β after 21 days post-therapy in both the groups ($p < 0.001$). When comparing both the groups, Group II has more statistically significant ($p < 0.05$) decrease in the level of IL-1 β than Group I post-therapy.

SOD Levels

In Group I, at baseline the superoxide dismutase levels were 111.83 ± 0.97 U/0.5ml and 21 days after treatment SOD levels improved to 189.73 ± 0.27 U/0.5ml. In Group II, the superoxide dismutase levels at baseline was 124.56 ± 0.74 U/0.5ml and 21 days after treatment SOD levels improved to 263.36 ± 0.23 U/0.5ml. When comparing both the groups, Group II has more statistically significant ($p < 0.05$) increase in the level of SOD than Group I after 21 days post-therapy as shown in Table 6.

DISCUSSION:

The ultimate goal of periodontal therapy is to reconstitute the tissues destroyed by periodontal disease. Scaling and Root Planing has been the ideal choice of procedure to treat periodontal disease but complete elimination of periodontopathogens and tissue destruction is impossible. [11] Local delivery of drugs along with Scaling and Root Planing offers greater advantage of high accessibility at the target site with limited side effects. Punicalagin is the major polyphenol isolated from pomegranate, shown to possess anti-inflammatory and anti-oxidant properties. [12] In the present study, punicalagin is used as a Local Drug Delivery, mode in the form of a gel along with Scaling and Root Planing for the treatment of Chronic Periodontitis patients.

In this study, there was a statistically significant decrease in the mean plaque index score after 21 days post-treatment ($p < 0.001$). This was in accordance with the study done by Bhadbhade et al [13] who showed significant reduction in plaque formation following mouth rinsing with Punica granatum mouthwash when compared to placebo. Punicalagin suppresses the ability of the microorganisms to adhere to the surface of the tooth and prevents the formation of plaque. Pomegranate also prevents the ability to adhere by interfering with substances such as extracellular polysaccharides that the bacteria use as a glue.

In the present study, there was a statistically significant reduction in both Sulcus Bleeding Index and gingival index after 21 days post-treatment ($p < 0.001$). This was in accordance with the study done by Sahgal et al [14] who reported that Punica granatum applied in a gel form was efficient in reducing the Gingival Index score because of its strong styptic action. The reduction in Sulcus Bleeding Index was in accordance with the study by Ahuja et al [15] where pomegranate mouthwash used two times daily for fifteen days resulted in more efficient decrease in bleeding on probing scores due to its strong styptic action when compared to Chlorhexidine mouthwash.

In the present study, group II showed more statistically significant reduction in Probing pocket depth and gain in Clinical Attachment level at 21 days post-therapy when compared to group I. Similar results were shown by Sastravaha et al [16] and reported that pomegranate extract provided significantly better results in decreasing the probing depth and attachment loss. Punicalagin has been shown to provide a synergistic action in collagen stabilization as they have the affinity for proteins and forming bonds with collagen fibers.

When comparing between the groups, Group II showed more statistically significant ($P < 0.05$) decrease in the level of IL-1 β than group I at 21 days post-therapy. Similar results were observed in a study done by Xu et al [17] who reported that punicalagin reduced the levels of secreted proinflammatory cytokines such as IL-1 β , IL-6 and TNF- α . Pomegranate extract exhibited anti inflammatory activity through inhibition of NF-kB activity and prevention of ERK-1 and ERK-2 activation. Pomegranate extract have been shown to inhibit the IL 1 beta induced destruction of proteoglycan, and also inhibits the expression of MMPs, Nitric Oxide and PGE₂ production. Ahmed et al [18] also showed that Pomegranate extract exhibited anti-inflammatory property by inhibiting the IL-1 β -induced expression of MMP-1, -3, and -13 mRNA expression. Recently Xu et al [19] showed that Pomegranate extract produced potential anti-inflammatory effect through modulating the synthesis of several mediators and cytokines that are involved in the inflammatory process such as IL-1 β and TNF- α .

In the present study, When comparing between the groups, Group II showed more statistically significant ($P < 0.05$) increase in the level of SuperOxide Dismutase than Group I after 21 days post-therapy. This was supported by a study done by Gil et al [20] who showed that high antioxidant activity of Punica granatum was due to the presence of punicalagin isomers, ellagic acid derivatives and anthocyanins. Pomegranate extract inhibits lipopolysaccharide induced oxidative stress by reducing Reactive Oxygen Species, Nitric Oxide generation and by increasing Superoxide Dismutase 1 mRNA expression. [12]

CONCLUSION

Based on the above results obtained in this study, there is an improvement in the clinical parameters with an increase in the anti-oxidant marker level and a decrease in inflammatory marker level when punicalagin gel was used along with Scaling and Root Planing in patients with Chronic Periodontitis.

UNDER PEER REVIEW

REFERENCES

1. Berezow BA and Darveau PR. Microbial shift and periodontitis. *Periodontology* 2000 2011; 55: 36–47.
2. Bhardwaj A, Mahajan A, Thakur N and Kumar N. Mechanical non surgical therapy: an indispensable tool. *IOSR Journal of Dental and Medical Sciences (JDMS)* 2012; 1: 36-41.
3. Walker CB. The acquisition of antibiotic resistance in the periodontal microflora. *Periodontol* 2000 1996; 10: 78-88.
4. Singh G, Navkiran, Kaur S and Singh ST. Local Drug Delivery In Periodontics: A Review. *J Periodontal Med Clin Pract* 2014; 01: 272-284.
5. Kala SB, Gunjan C, Disha N and Shobha P. Treatment of Periodontal Disease – A Herbal Approach. *Int. J. Pharm. Sci. Rev. Res* 2015; 33(2): 126-136.
6. Page RC. The role of inflammatory mediators in the pathogenesis of periodontal disease. *J Periodont Res* 1991; 26: 230-242.
7. Karim S, Pratibha PK, Kamath S, Bhat SG, Kamath U, Dutta B, Sharma N, Archana B, Bhat MK and Guddattu V. Superoxide dismutase enzyme and thiol antioxidants in gingival crevicular fluid and saliva. *Dental Research Journal* 2012; 9(3): 266-272.
8. Malik A, Afaq F, Sarfaraz S, Adhami MV, Syed DN, and Mukhtar H. Pomegranate fruit juice for chemoprevention and chemotherapy of prostate cancer. *PNAS* 2005; 102(41): 14813–14818.
9. Naz S, Siddiqi R, Ahmad S, Rasool SA, and Sayeed SA. Antibacterial Activity Directed Isolation of Compounds from *Punica granatum*. *Journal Of Food Science* 2007; 72(9): 341-345.
10. Jurenka JMT. Therapeutic Applications of Pomegranate (*Punica granatum* L.) : A Review. *Alternative Medicine Review* 2008; 13(2): 128-144.
11. Bosshardt DD and Sculean A. Does Periodontal Tissue Regeneration Really Work? *Periodontology* 2000 2009; (51): 208–219.
12. Xu X, Li H, Hou X, Li D, He S, Wan C, Yin P, Liu M, Liu F and Xu J. Punicalagin Induces Nrf2/HO-1 Expression via Upregulation of PI3K/AKT Pathway and Inhibits LPS-Induced Oxidative Stress in RAW264.7 Macrophages. *Mediators of Inflammation* Volume 2015: 1-11.
13. Bhadbhade SJ, Acharya AB, Rodrigues SV and Thakur SL. The antiplaque efficacy of pomegranate mouthrinse. *Quintessence Int* 2011; 42: 29–36.

14. Sahgal A, Chaturvedi SS, Bagde H, Agrawal P, Suruna R and Limaye M. A Randomized Control Trial To Evaluate Efficacy Of Anti-Bacterial And Anti-Inflammatory Effect Of Aloe Vera, Pomegranate And Chlorhexidine Gel Against Periodontopathogens. *Journal Of International Oral Health* 2015; 7(11): 33-36.
15. Ahuja S, Dodwad V, Kukreja BJ, Mehra P and Kukreja P. A comparative evaluation of efficacy of *Punica granatum* and chlorhexidine on plaque and gingivitis. *J Int Clin Dent Res Organ* 2011; 3: 29-32.
16. Sastravaha et al. Adjunctive Periodontal Treatment with Centella Asiatica and Punica Granatum Extracts in Supportive Periodontal Therapy. *Journal of the International Academy of Periodontology* 2005; 7(1): 1-10.
17. Xu X, Yin P, Wan C, Chong X, Liu M, Cheng P, Chen J, Liu F And Xu J. Punicalagin Inhibits Inflammation In LPS - Induced Raw264.7 Macrophages Via The Suppression Of Tlr4-Mediated MAPKS And NF- κ B Activation. *Inflammation* 2014; 37(3): 956-965.
18. Ahmed S, Wang N, Hafeez BB, Cheruvu VK and Haqqi TM. Punica granatum L. Extract Inhibits IL-1 β -Induced Expression of Matrix Metalloproteinases by Inhibiting the Activation of MAP Kinases and NF- κ B in Human Chondrocytes In Vitro. *J Nutr* 2005; 135(9): 2096-2102.
19. Xu J, Zhao Y and Aisa HA. Anti-Inflammatory Effect Of Pomegranate Flower In Lipopolysaccharide (LPS)-Stimulated RAW264.7 Macrophages. *Pharmaceutical Biology* 2017; 55(1): 2095-2101.
20. Gil M, Barbera FAT, Pierce BH, Holcroft DM and Kader AA. Antioxidant Activity Of Pomegranate Juice And Its Relationship With Phenolic Composition And Processing. *J. Agric Food Chem* 2000; 48: 4581-4589.

Tables Description

Table 1: Composition of Punicalagin gelatin films

Table 2 : Mean Gingival index, Plaque Index and Sulcus Bleeding Index at baseline and 21 days

Table 3 : Comparison of mean in PPD between Group I and Group II post-therapy.

Table 4 : Comparison of mean in CAL between Group I and Group II post-therapy

Table 5 : Comparison of IL-1 β levels between group I and group II at baseline and at 21 days post therapy

Table 6 : Comparison of SOD levels between group I and group II at baseline and at 21 days post therapy

UNDER PEER REVIEW

Table 1: Composition of Punicalagin gelatin films

Composition	Concentration (%)
PC	10mg/film
Gelatin	20
Glycerine	3
Triethanolamine	0.3

UNDER PEER REVIEW

Table 2 : Mean Gingival index, Plaque Index and Sulcus Bleeding Index at baseline and 21 days

Indices	Baseline	21 days	p – value
Gingival index	2.53 ± 0.67	1.43 ± 0.52	< 0.001*
Plaque index	2.37 ± 0.62	1.39 ± 0.58	< 0.001*
Sulcus Bleeding Index	2.75 ± 0.28	1.75 ± 0.29	< 0.001*

UNDER PEER REVIEW

Table 3 : Comparison of mean in PPD between Group I and Group II post-therapy.

Probing pocket depth	Group I Mean±SD	Group II Mean±SD	P Value
Baseline	5.69 ± 0.00	5.74 ± 0.00	–
21 days	2.92 ± 0.17	2.05 ± 0.62	< 0.001*

UNDER PEER REVIEW

Table 4 : Comparison of mean in CAL between Group I and Group II post-therapy

CLINICAL ATTACHMENT LEVEL	Group I Mean±SD	Group II Mean±SD	P Value
Baseline	3.69 ± 0.22	3.74 ± 0.38	–
21 days	1.82 ± 0.48	0.82 ± 0.22	< 0.001*

UNDER PEER REVIEW

Table 5 : Comparison of IL-1 β levels between group I and group II at baseline and at 21 days post therapy

IL-1β	Group I Mean \pm SD	Group II Mean \pm SD	P Value
BASELINE	78.23 \pm 0.36	79.36 \pm 0.18	–
21 Days	59.53 \pm 0.22	37.9 \pm 0.83	< 0.05*

UNDER PEER REVIEW

Table 6 : Comparison of SOD levels between group I and group II at baseline and at 21 days post therapy

SOD	Group I Mean±SD	Group II Mean±SD	P Value
BASELINE	111.83 ± 0.97	124.56 ± 0.74	–
21 Days	189.73 ± 0.27	263.36 ± 0.23	< 0.05*

UNDER PEER REVIEW

Figure Legends

Figure 1: PreOperative probing depth. (A) Control site. (B) Test site

Figure 2: Scaling and Root Planing.

Figure 3: Placement of Punicalagin Film

Figure 4: PostOperative probing depth . (A) Control site. (B) Test site

Figure 5: Consort Flow chart

UNDER PEER REVIEW

Figure 1: PreOperative probing depth. (A) Control site. (B) Test site

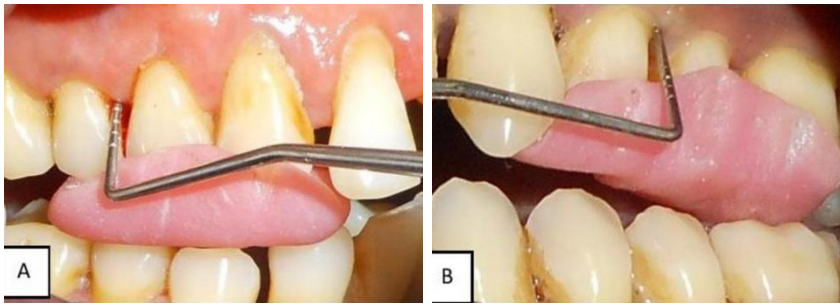


Figure 2: Scaling and Root Planing.

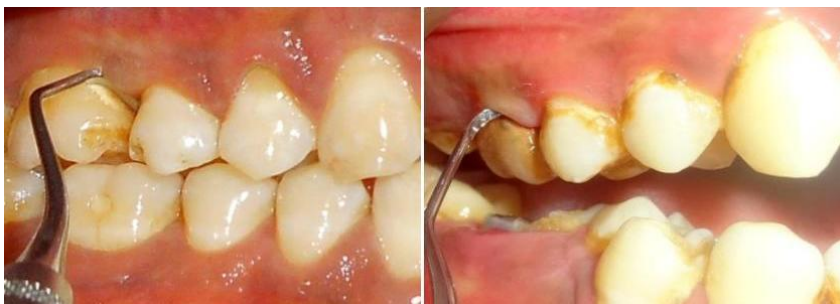

Figure 3: Placement of Punicalagin Film

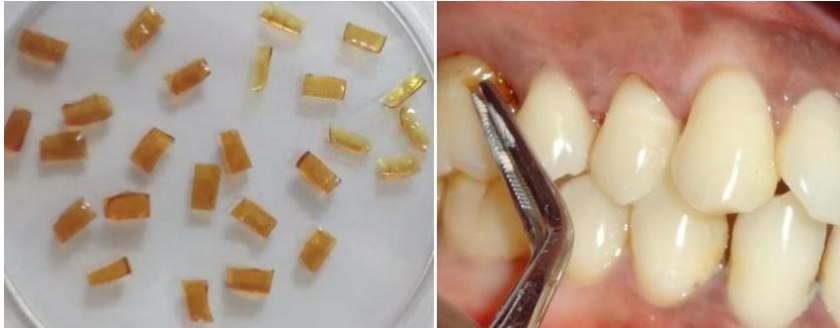

Figure 4: PostOperative probing depth . (A) Control site. (B) Test site

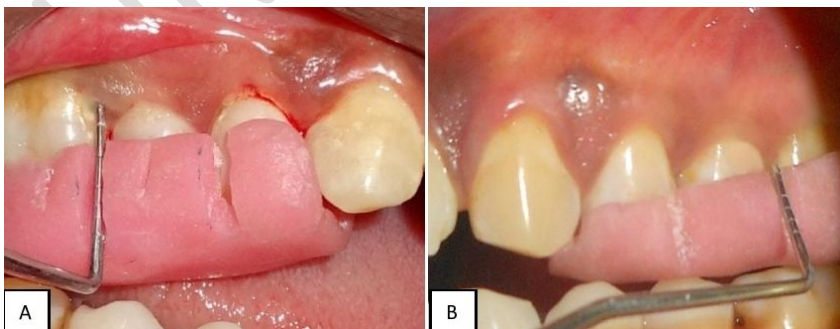


Figure 5: Consort Flow chart

