

MORPHOMETRIC ANALYSIS OF ORBITAL CAVITY IN SOUTH INDIAN POPULATION

Running title: Morphometric analysis of orbital cavity in south Indian population.

ABSTRACT :

INTRODUCTION:

Each orbital cavity is actually meant as a socket for the eyeball. The human orbit is a complicated anatomic area, which performs predominant position in the craniofacial complex.

AIM:

The aim of the study is to provide the normal reference orbital parameters for the south Indian population.

MATERIAL & METHODS:

The present study has adopted 30 south Indian dry skulls. An orbital cavity was measured using vernier callipers. With the help of vernier calliper and ruler, the measurements such as length, breadth of the orbital cavity and biorbital breadth, interorbital breadth of the orbital cavity were measured. The paired t-test is the statistical method used in this study.

RESULT :

The mean orbital breadth of the right orbit is 34.6 ± 1.777 and left orbit was 34.701 ± 1.711

The mean orbital height of the right orbit is 33.417 ± 1.494 and the left orbit is 33.38 ± 1.560 .

The mean biorbital breadth of the orbital cavity is 94.16 ± 2.533 and means interorbital breadth of the orbital cavity is 20.615 ± 1.172 . Paired t test demonstrated no significant statistical difference between the right and left orbit.

CONCLUSION :

The orbital cavity additionally used for determination of sex and ethnic courses of a cadaver and its phase of the cranium that possess manipulate over sexual dimorphic traits .

KEYWORDS: orbital height, orbital breadth, interorbital breadth, biorbital breadth .

INTRODUCTION:

The orbit is a complex anatomic region of our human body. The orbit is a bony pyramid with four walls: roof, lateral wall, floor, and medial wall. The orbit is a chief component; moreover it is used for determination of sex and ethnic courses of a cadaver and its part of the skull that possess the control over sexual dimorphic characteristics. The bony orbits or eye

sockets were bilateral and symmetrical cavities. The associated muscles, nerves, vessels, and the visual apparatus are enclosed in the eyeball which is intended as a socket in the orbital cavity for its protection (1). The orbital cavity of a female skull is normally rounded and orbits of the male skull are generally square-shaped. Orbit is a well designed and a protecting structure that protects our eye ball. The apex of the orbital pyramid is situated 44-50 mm posteriorly and contains important neurovascular structures packed into a very tight space (2). Orbital anatomy is necessary for surgical correction of the orbit to make certain an efficient structural disposition of visual equipment. Reconstruction surgeries for management of clinical conditions related to the orbit were essential for the knowledge of orbital region (3). The bony orbit were made in the combination of seven bones frontal bone (pars distalis), lacrimal bone, ethmoid bone (lamina papyracea), zygomatic bone (orbital process of zygomatic bone), maxillary bone (orbital surface of the body of maxilla), palatine bone and sphenoid bone (greater and lesser wings) (4). The expertise of the bony orbit is no longer necessary for the anatomists, however additionally vital for the clinicians and surgeons in the field of ophthalmology, oral, maxillofacial, and neurosurgery. Therefore the aim of the study is to determine the normal reference orbital parameters of the south Indian population (5).

Our team has extensive knowledge and research experience that has translate into high quality publications (6–13),(14),(15),(16),(17,18),(19),(20),(21–25). It is important for our better knowledge of anatomical disposition of the orbital structures and for the surgeries around the region.

MATERIALS AND METHODS:

In the present study has adopted 30 south Indian dry skull bones of unknown sex and without any gross abnormality will be collected from the department of anatomy, Saveetha dental college, Chennai for evaluation. The measurements such as length and breadth of the orbital cavity were measured with the help of vernier callipers. The results obtained were analyzed and tabulated and are represented graphically.

The measurements of orbital breadth, orbital height, biorbital breadth and interorbital breadth were taken.

Orbital height: The distance between the superior and inferior orbital margins perpendicular to orbital breadth and bisecting the orbit into equal medial and lateral halves.

Orbital breadth: the distance from dacryon to ectoconchion of the left and right.

Biorbital breadth: the distance from left and right ectoconchion.

Interorbital breadth: the distance between right and left dacryon.

In this study, a statistical method paired t-test was demonstrated to determine the p value for the comparison analysis between right and left orbital height, right and left orbital breadth as well as for the comparison analysis between biorbital and interorbital breadth. The present study was approved by Institutional Review Board, Saveetha Dental College and Hospitals, Saveetha Institute of Technical and Medical sciences.

RESULTS :

The present study observed that the mean orbital breadth on the right side is 34.6 ± 1.777 and 34.701 ± 1.711 on the left side; orbital height on the right side is 33.417 ± 1.494 and on the left side is 33.38 ± 1.560 . Then the mean biorbital breadth is 94.16 ± 2.533 and interorbital breadth is 20.615 ± 1.172 . Therefore the orbital index of the right orbit is 96.56 and the orbital index of the left orbit is 96.47 and The results of the paired -t test were as follows: the orbital height is 0.0931, the orbital breadth is 0.21402, and the biorbital and interorbital breadths are 146.694.

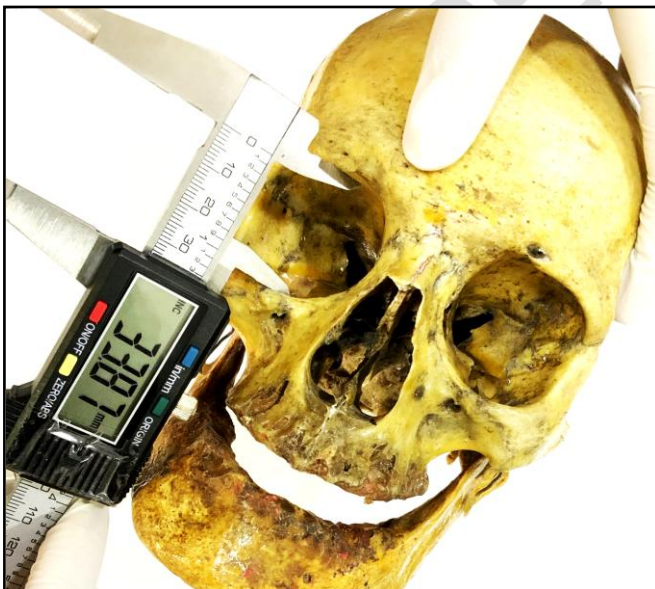

Figure 1 : The picture shows the measurement of orbital height. Orbital height is the distance between the superior and inferior orbital margins perpendicular to orbital breadth and bisecting the orbit into equal medial and lateral halves. Here the orbital height is 33.87

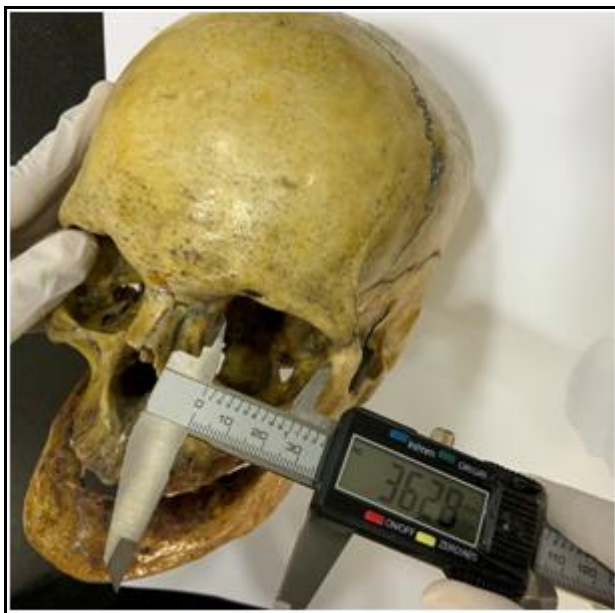

Figure 2 : The picture shows the measurement of orbital breadth. Orbital breadth is the distance from dacryon to ectoconchion of the left and right. Here the orbital breadth is 36.28.



Figure 3 : The picture shows the measurement of biorbital breadth. Biorbital breadth is the distance from left and right ectoconchion. Here the biorbital breadth is 89.71.

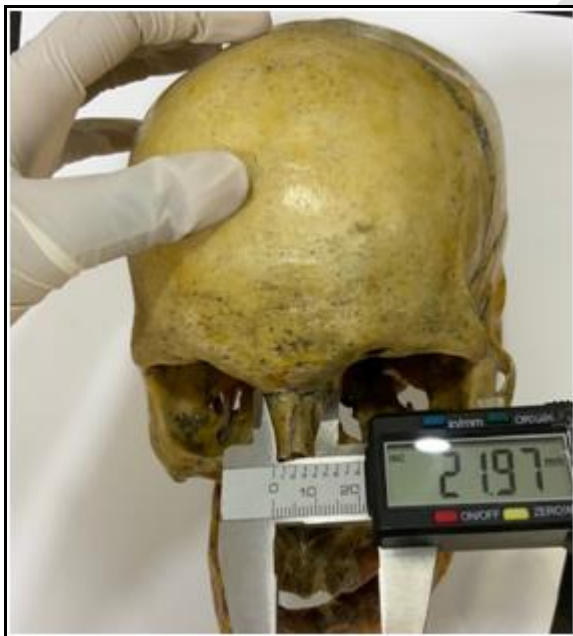

Figure 4 : The picture shows the measurement of the interorbital breadth. Interorbital breadth is the distance between right and left dacryon, Here the interorbital breadth is 21.97.

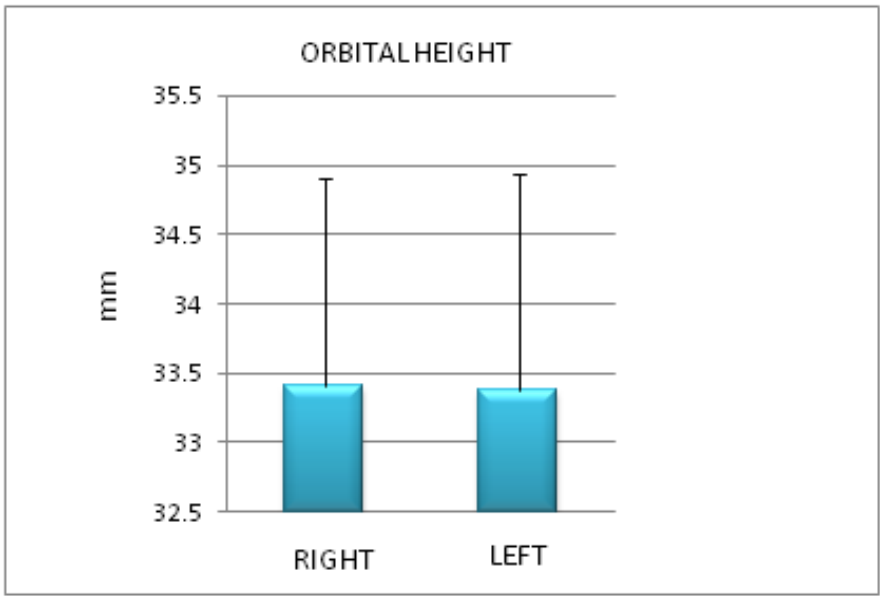


Figure 5: Represents the comparison analysis between right and left orbital height in mm. Here the t-value was analyzed for the orbital height is 0.0931 but its statistically insignificant $p < 0.05$. p- Value is .463066

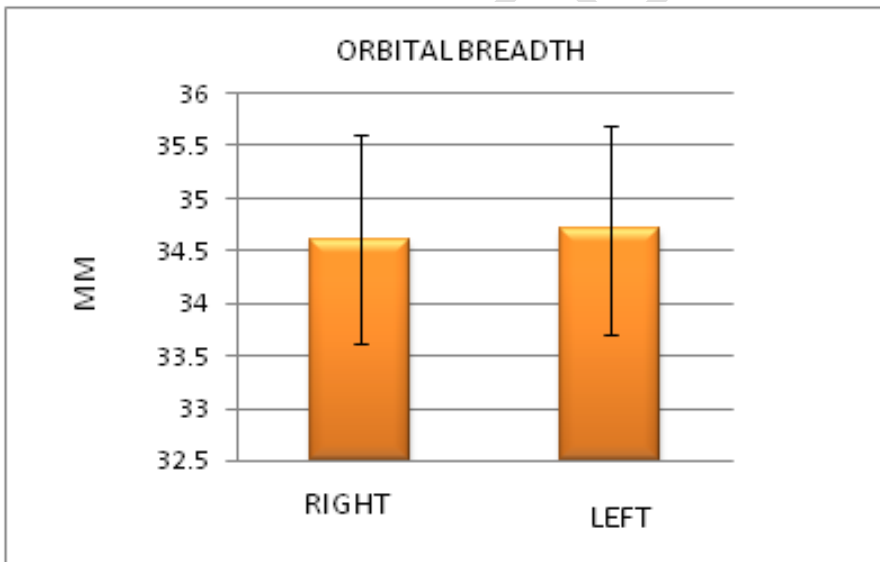


Figure 6: Represents the comparison analysis between right and left orbital breadth in mm. Here the t-value was analyzed for the orbital breadth is 0.21402 but the value is statistically insignificant $p < 0.05$. The p value is 0.415628

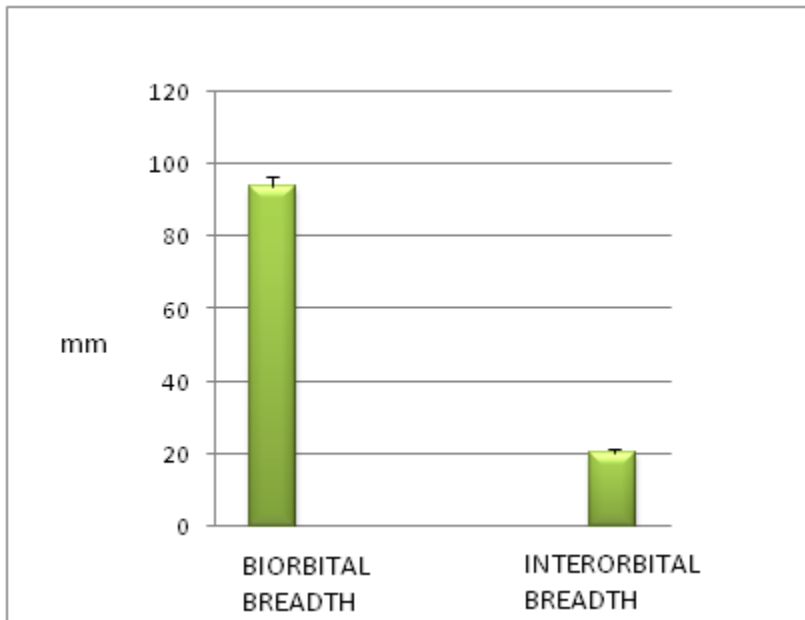


Figure 7: Represents the comparison analysis between biorbital breadth and interorbital breadth in mm. Here the t-value was analyzed for the biorbital breadth and interorbital breadth is 146.694 but the value is statistically significant $p < 0.05$ here the $p < 0.0001$

DISCUSSION :

Morphometric parameters of orbit are very important in ophthalmology, oral maxillofacial surgery and neurosurgery (26). Also knowledge of normal values for a particular population can be used to treat abnormalities to produce the best aesthetics and functional result. Therefore results of the present study are compared with the previous studies. When the mean and standard deviation values of height and breadth were compared, there is a difference between the values that is because the dry skulls vary from region to region among the human population. The orbital index was found between right orbit and left (27).

The orbital index was calculated by using the formula $OI = \text{orbital height} / \text{orbital breadth} \times 100$. The present study is to compare OI of Indian population with accessible information from other populaces of the world (28). On the contrary the left orbital breadth and right orbital breadth have similar averages (29). The OI index differs in race, areas amongst the same race and intervals in evolution (30). Traditional values of orbital indices serve as very vital measurements inside the analysis, and identification of craniofacial syndromes and post-traumatic deformities, and information of the installed values for a precise place may also be

accustomed to deal with abnormalities to grant the simplest aesthetics and beneficial end result.

For these purposes, well known reference values of OI are very important, in view that these requirements replicate the number of patterns of craniofacial increase ensuing from racial, ethnic, social, and dietary variations. Limitations of this study are that only 30 skulls could be taken for the research and only south **Indian** population chosen as the study population so there might be a change in the observation if north **Indian** population and more skulls are included.

CONCLUSION:

The present study was observed the OI of South Indian dry skull and it offers beneficial guiding principle of orbital morphometric data, for medical and surgical cure in ophthalmology, oral and maxillofacial surgery, plastic surgical operation and neurosurgery and additionally in the format of eye protecting equipment. Also these parameters in particular OI can be used at some stage in forensic and anthropological investigation of unknown persons for finding out gender, ethnicity, etc. Normal values of orbital indices are essential measurements in the evaluation, and prognosis of craniofacial syndromes and hectic deformities, and expertise of the regular values for a precise location or population can be used to deal with abnormalities to produce the high-quality aesthetics and useful result. Accurate measurements of orbital dimensions are very essential throughout plastic surgery, maxillofacial and neurosurgeries and additionally in the graph of eye protecting equipment.

Ethical Approval:

As per international standard or university standard ethical approval has been collected and preserved by the authors.

REFERENCE :

1. Ghorai S. A comparative study of orbital morphometry in dry skulls of a district in West Bengal [Internet]. International Journal of Medical Science and Public Health. 2019. p. 1. Available from: <http://dx.doi.org/10.5455/ijmsph.2019.0617721062019>
2. D M, Mekala D, Professor A, Department of Anatomy, Coimbatore Medical College, Coimbatore, et al. ORBITAL DIMENSIONS AND ORBITAL INDEX: A

- MEASUREMENT STUDY ON SOUTH INDIAN DRY SKULLS [Internet]. Vol. 3, International Journal of Anatomy and Research. 2015. p. 1387–91. Available from: <http://dx.doi.org/10.16965/ijar.2015.242>
3. Sreekanth C, Professor A, Dept. of Anatomy, Sri Padmavathi College For Women (SVIMS), Tirupathi, Pradesh A, et al. Morphometric Study of Orbit in Skull Bones: Direct Measurement Study [Internet]. Vol. 9, Indian Journal of Anatomy. 2020. p. 45–53. Available from: <http://dx.doi.org/10.21088/ija.2320.0022.9120.7>
 4. D M, Mekala D, Professor A, Department of Anatomy, Coimbatore Medical College, Coimbatore, et al. MORPHOMETRY OF ORBIT IN SOUTH INDIAN DRY SKULLS - DIMENSIONS OF ORBITAL ROOF AND FLOOR [Internet]. Vol. 6, International Journal of Anatomy and Research. 2018. p. 4876–9. Available from: <http://dx.doi.org/10.16965/ijar.2017.494>
 5. Riyaz ZH, Amjad F, Siddiqu AA, Ansari MDK. Orbital dimensions of Maharashtrian population a direct measurement study using dry skulls [Internet]. Vol. 7, International Dental Journal of Student's Research. 2020. p. 103–6. Available from: <http://dx.doi.org/10.18231/j.idjsr.2019.025>
 6. Sekar D, Lakshmanan G, Mani P, Biruntha M. Methylation-dependent circulating microRNA 510 in preeclampsia patients. *Hypertens Res.* 2019 Oct;42(10):1647–8.
 7. Princeton B, Santhakumar P, Prathap L. Awareness on Preventive Measures taken by Health Care Professionals Attending COVID-19 Patients among Dental Students. *Eur J Dent.* 2020 Dec;14(S 01):S105–9.
 8. Logeshwari R, Rama Parvathy L. Generating logistic chaotic sequence using geometric pattern to decompose and recombine the pixel values. *Multimed Tools Appl.* 2020 Aug;79(31-32):22375–88.
 9. Johnson J, Lakshmanan G, M B, R M V, Kalimuthu K, Sekar D. Computational identification of MiRNA-7110 from pulmonary arterial hypertension (PAH) ESTs: a new microRNA that links diabetes and PAH. *Hypertens Res.* 2020 Apr;43(4):360–2.
 10. Paramasivam A, Priyadharsini JV, Raghunandhakumar S, Elumalai P. A novel COVID-19 and its effects on cardiovascular disease. *Hypertens Res.* 2020 Jul;43(7):729–30.
 11. Pujari GRS, Subramanian V, Rao SR. Effects of *Celastrus paniculatus* Willd. and *Sida cordifolia* Linn. in Kainic Acid Induced Hippocampus Damage in Rats. *Ind J Pharm Educ.* 2019 Jul 3;53(3):537–44.
 12. Rajkumar KV, Lakshmanan G, Sekar D. Identification of miR-802-5p and its involvement in type 2 diabetes mellitus. *World J Diabetes.* 2020 Dec 15;11(12):567–71.
 13. Ravisankar R, Jayaprakash P, Eswaran P, Mohanraj K, Vinitha G, Pichumani M. Synthesis, growth, optical and third-order nonlinear optical properties of glycine sodium nitrate single crystal for photonic device applications. *J Mater Sci: Mater Electron.* 2020 Oct;31(20):17320–31.
 14. Wu S, Rajeshkumar S, Madasamy M, Mahendran V. Green synthesis of copper nanoparticles using *Cissus vitiginea* and its antioxidant and antibacterial activity against

- urinary tract infection pathogens. *Artif Cells Nanomed Biotechnol.* 2020 Dec;48(1):1153–8.
15. Vikneshan M, Saravanakumar R, Mangaiyarkarasi R, Rajeshkumar S, Samuel SR, Suganya M, et al. Algal biomass as a source for novel oral nano-antimicrobial agent. *Saudi J Biol Sci.* 2020 Dec;27(12):3753–8.
 16. Alharbi KS, Fuloria NK, Fuloria S, Rahman SB, Al-Malki WH, Javed Shaikh MA, et al. Nuclear factor-kappa B and its role in inflammatory lung disease. *Chem Biol Interact.* 2021 Aug 25;345:109568.
 17. Rao SK, Kalai Priya A, Manjunath Kamath S, Karthick P, Renganathan B, Anuraj S, et al. Unequivocal evidence of enhanced room temperature sensing properties of clad modified Nd doped mullite Bi₂Fe₄O₉ in fiber optic gas sensor [Internet]. Vol. 838, *Journal of Alloys and Compounds.* 2020. p. 155603. Available from: <http://dx.doi.org/10.1016/j.jallcom.2020.155603>
 18. Bhavikatti SK, Karobari MI, Zainuddin SLA, Marya A, Nadaf SJ, Sawant VJ, et al. Investigating the Antioxidant and Cytocompatibility of *Mimusops elengi* Linn Extract over Human Gingival Fibroblast Cells. *Int J Environ Res Public Health* [Internet]. 2021 Jul 4;18(13). Available from: <http://dx.doi.org/10.3390/ijerph18137162>
 19. Marya A, Karobari MI, Selvaraj S, Adil AH, Assiry AA, Rabaan AA, et al. Risk Perception of SARS-CoV-2 Infection and Implementation of Various Protective Measures by Dentists Across Various Countries. *Int J Environ Res Public Health* [Internet]. 2021 May 29;18(11). Available from: <http://dx.doi.org/10.3390/ijerph18115848>
 20. Barma MD, Muthupandiyani I, Samuel SR, Amaechi BT. Inhibition of *Streptococcus mutans*, antioxidant property and cytotoxicity of novel nano-zinc oxide varnish. *Arch Oral Biol.* 2021 Jun;126:105132.
 21. Vijayashree Priyadharsini J. In silico validation of the non-antibiotic drugs acetaminophen and ibuprofen as antibacterial agents against red complex pathogens. *J Periodontol.* 2019 Dec;90(12):1441–8.
 22. Priyadharsini JV, Vijayashree Priyadharsini J, Smiline Girija AS, Paramasivam A. In silico analysis of virulence genes in an emerging dental pathogen *A. baumannii* and related species [Internet]. Vol. 94, *Archives of Oral Biology.* 2018. p. 93–8. Available from: <http://dx.doi.org/10.1016/j.archoralbio.2018.07.001>
 23. Uma Maheswari TN, Nivedhitha MS, Ramani P. Expression profile of salivary micro RNA-21 and 31 in oral potentially malignant disorders. *Braz Oral Res.* 2020 Feb 10;34:e002.
 24. Gudipani RK, Alam MK, Patil SR, Karobari MI. Measurement of the Maximum Occlusal Bite Force and its Relation to the Caries Spectrum of First Permanent Molars in Early Permanent Dentition. *J Clin Pediatr Dent.* 2020 Dec 1;44(6):423–8.
 25. Chaturvedula BB, Muthukrishnan A, Bhuvaraghan A, Sandler J, Thiruvengatachari B. *Dens invaginatus*: a review and orthodontic implications. *Br Dent J.* 2021

Mar;230(6):345–50.

26. Nathan V, Jain A, Kaur P. A study of orbital dimensions in adult human skulls of North Indian population [Internet]. Vol. 67, Journal of the Anatomical Society of India. 2018. p. S68. Available from: <http://dx.doi.org/10.1016/j.jasi.2018.06.131>
27. Vishal K, Vinay KV, Johny IP. Morphology and morphometry of infra orbital foramen in South Indian adult dry skulls [Internet]. Vol. 3, National Journal of Clinical Anatomy. 2014. p. 122. Available from: <http://dx.doi.org/10.4103/2277-4025.297371>
28. Patil GV. Study of orbital index in human dry skulls of south Indian origin [Internet]. Vol. 64, Journal of the Anatomical Society of India. 2015. p. S15. Available from: <http://dx.doi.org/10.1016/j.jasi.2015.07.293>
29. Dryden SC, Eder A, Meador AG, Schofield M, Fleming JC, Fowler BT. Prevalence of Pediatric Orbital Roof Fractures as a Function of Orbital Dimensions [Internet]. 30th Annual Meeting North American Skull Base Society. 2020. Available from: <http://dx.doi.org/10.1055/s-0040-1702656>
30. Shukla A. Measurement of Orbital Dimensions (Orbital Height, Breadth and Length of Superior Orbital Fissure) using Dry Skull's [Internet]. Vol. 31, Delhi Journal of Ophthalmology. 2020. Available from: <http://dx.doi.org/10.7869/djo.566>