

Determination of the accuracy of linear Height bone for implant placement in panoramic radiography relative to CBCT in the posterior areas of the jaws

Amendments

Important protocol amendments post registration will be recorded and included in dissemination.

Ethical Approval

IR.LUMS.REC.1399.138 , Research Ethics Committees of Lorestan University of medical Sciences2020-08-26

ABSTRACT

Purpose: In the levels of implant treatment in the posterior region, determining the height of the bone has particular importance. The aim of the study was to compare the accuracy of linear bone height measurement for implant placement on panoramic view compared to CBCT in posterior jaw area.

Materials and Methods: The study was performed on 20 patients. In each of the posterior edentulous areas, a surgical guide for each patient was marked with gutta-percha (a total of 70 points). Panoramic radiographs and CBCTs were obtained from the patients and then the distance between the marked points in the maxilla to the maxillary sinus and in the mandible to the upper border of the alveolar canal was measured by Romaxis software and analyzed by Statistical software Stata 14. The obtained measurements of panoramic view were compared to CBCTs using t-test. $P \leq 0.05$ was considered significant.

Result: The mean difference between the sizes obtained from panoramic radiography and CBCT radiography in the maxilla was 0.34 mm ($P = 0.57$) and the mean difference between the sizes obtained from panoramic radiography and CBCT radiography in the mandible was 0.86 mm ($P = 0.004$).

Conclusion: According to the results of study, it is logical panoramic radiography just used to pre-assessment of implant procedures in posterior area of mandible were as it could be more reliable in maxilla.

Key word: implant, panoramic radiography, CBCT,

INTRODUCTION

Nowadays, implants have become a Toothless areas treatment plan which have accepted widely in dentistry and became a

desirable option to replace lost teeth; The cause of this matter is due to the high ability of implants to return the function of mastication [1]. The initial stability of implant is an important factor that affects

the survival rate of the implant [2]. Although the prognosis of this treatment is highly predictable, complications of it are still observed [3-5]. However, clinical examination and preoperative radiography are effective to prevent complications and increase the success of implant treatment [6]. Preoperative radiography is necessary for quantitative and qualitative evaluations of determining appropriate location of implants [7]. Intraoral radiographs; panoramic radiographs, CT (Computed Tomography) and CBCT (Cone Beam Computed Tomography) are common imaging techniques which are used in implant treatment to improve long-term success [8]. Panoramic radiographs are widely used as primary assessment to evaluate the factors which have effect in implant treatment [9]. The more widely using of these radiographs is due to their availability, low radiation dose, and cost-effectiveness [9-11]. Distortion in the horizontal plane and magnification in the vertical plane are also unavoidable complications of panoramic radiographs [11]. Furthermore, panoramic radiographs prepare two-dimensional view of the bone and does not show accurate relationships with anatomical structures [12]. CBCT has found its place in dental imaging in recent years [13, 14]. CBCT images have high spatial resolution and prepare three-dimensional view [13] and have various advantages over 2D radiographs and CT images, such as showing the actual size of the data, the potential to create a full set of 2D images, the ability to carry out vertical scans in case with normal sitting position, having isotropic voxels, fewer metal artifacts, and preparing with digital imaging

technique [15]. In addition, CBCT obtains high-resolution information in various orthogonal planes for exact measurement in a short dose period [16]. Both of panoramic radiography and CBCT are the most common imaging techniques in implant treatment plan [5].

Assuming that CBCT prepares the enough measurement accuracy which is required in clinical treatment, this study tried to determine accuracy of panoramic images compared to CBCT till clear panoramic ability and accuracy measurement for implant procedures.

METHODS AND MATERIALS

We first got started our study after proper approval from the ethics committee. In order to primary examination of patients that were candidate for dental implant treatment at posterior areas of upper and lower jaw, periodontist prescribed panoramic images. After the review of panoramic images, periodontist distinguished CBCT images for some patients that need several implants. Among these patients 20 were selected. After the molding of the patients' mouth with alginate and plastic tray, the gypsum cast was prepared. After that, a surgical guide was made for each patient so that did not interference with intraoral radiographs. Seventy points of each indexes were pierced with a green round high-speed fissure mill. The created holes were filled by gutta-percha 60 as marker.

Panoramic imaging and CBCT were performed when the index is placed in the patient's mouth. All panoramic radiographs (Planmeca, Promax Finland) were prepared

under the following conditions according to company:

- i) Voltage: 60-84 kv
- ii) Intensity: 1-16 mA
- iii) Duration: 14-16 seconds

CBCT imaging were made using a Planmeca Promax 3D device (Planmeca-Finland-Helsinki). All CBCT radiographs were prepared under the following conditions according to company instructions:

- i) Voltage 75-84 kv
- ii) Intensity: 10-14 mA
- iii) Duration: 10-12 seconds
- iv) Field of view 8x8 cm

Romaxis software was used to analyze and measure the parameters of the study. After imaging, the points marked with gutta-percha were appeared on

the graphs. Then the points in the upper jaw were measured from the maxillary sinus and in the mandible were measured from the upper border of the inferior alveolar canal, parallel to the longitudinal axis of the tooth, adjacent to the hypothetical axis of the implant. Distances were measured by an oral and maxillofacial radiologist.

Stata 14 statistical software was used for data analysis. To describe the data, depending on the distribution of variables, central indices including mean and median and scatter indices including standard deviation and interquartile range are used. To compare the average available bone length for implant placement with two methods of panoramic and CBCT Paired T-test was used ($P\alpha = 0.05$).

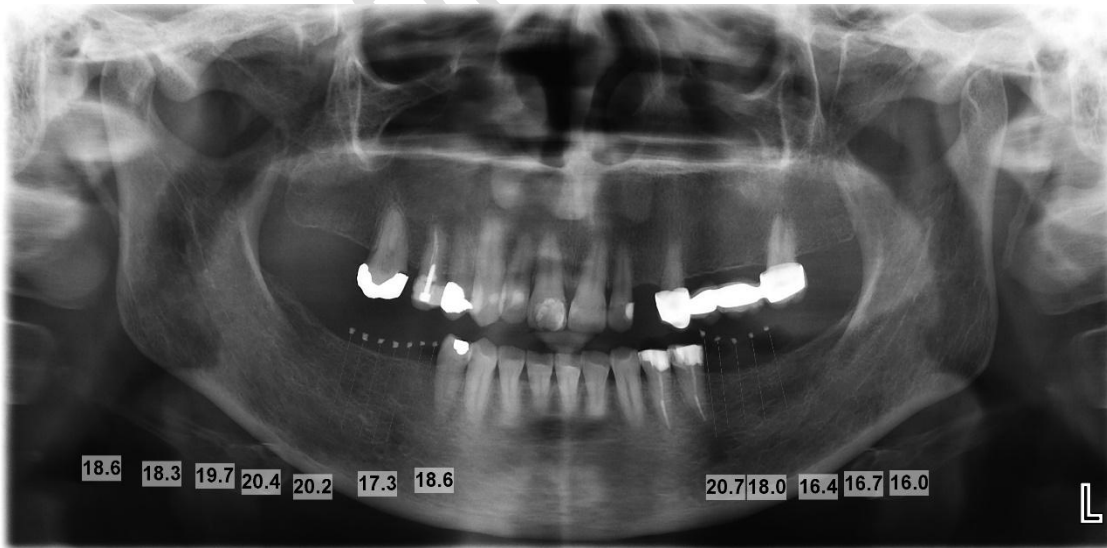

Figure1. Panoramic radiography and measurement of specified points

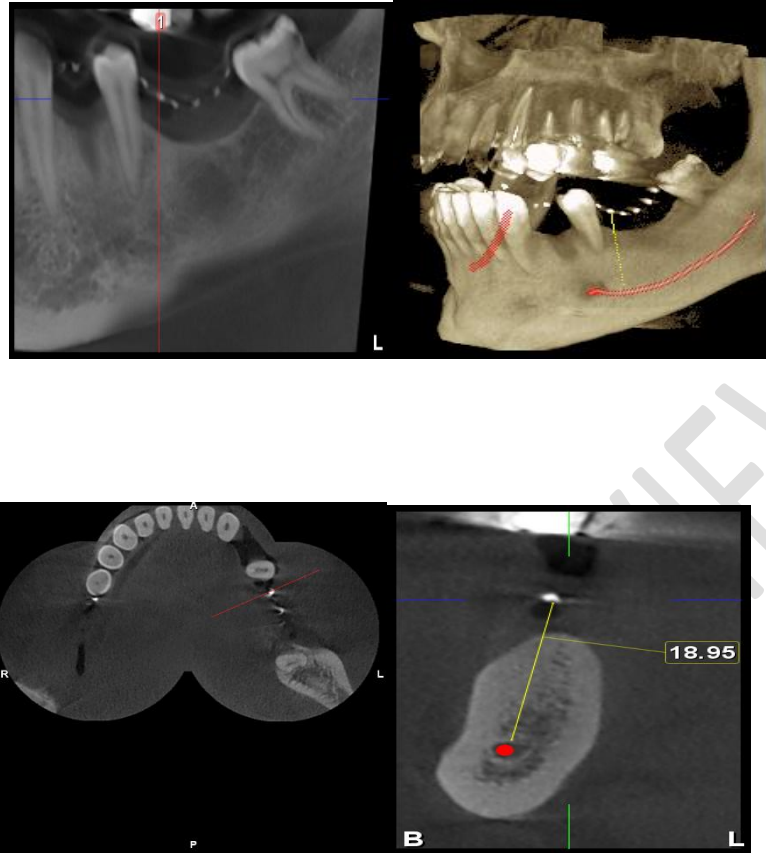


Figure2. CBCT radiography and measurement of specified points

RESULTS

Accurate measurement of bone height in the posterior region of both jaws

According to Table 1, the minimum and maximum bone height in the posterior areas of both jaws was measured as 5.48 mm and 29.35 mm in CBCT images with an average of 18.15 mm. The minimum and maximum bone height in the posterior areas of both jaws were measured in panoramic radiography in 5.8 mm and 34.1 mm in panoramic imaging and its mean was measured in panoramic radiography in 17.54 mm. According to Table 2, the mean difference between the sizes obtained from panoramic radiography and CBCT

radiography was 0.69 mm ($P = 0.089$). There was no significant difference in the posterior areas of upper and lower jaws, and the dimensions obtained from CBCT imaging were largely similar to those obtained from panoramic images.

Accuracy of measuring bone height in the posterior region of the maxilla

According to Table 1, the minimum and maximum bone height in the posterior region of the maxilla from the index to the lower border of the maxillary sinus was measured at 5.48 mm and 29.35 mm in CBCT whereas in panoramic images these were 5.8 mm and 34.1 mm respectively. According to Table 2, the mean difference

between the data obtained from panoramic radiography and CBCT radiography was 0.34 mm (P = 0.57). The results showed that there was no significant difference between the **measurements** of CBCT imaging in the posterior region of the maxilla from the index to the lower border of the maxillary sinus and the sizes of panoramic imaging in this area.

Accuracy of measuring bone height in the posterior region of the mandible

According to Table 1, the minimum and maximum bone height in the posterior regions of the mandible from the index to the upper border of the alveolar inferior

canal were measured 13.72 mm and 24.42 mm in CBCT images, **whereas these measurements were 13.7 mm and 23.2 mm in panoramic imaging.** According to Table 2, the mean difference between the sizes obtained from panoramic radiography and CBCT radiography was 0.86 mm (P = 0.004) The results showed that there was a significant difference between the size obtained from CBCT imaging in the posterior region of the mandible compared to panoramic. The results obtained from CBCT imaging were much more accurate than the measurements obtained from panoramic images.

Table 1. CBCT and Panoramic Measurements

	CBCT Measurements			Panoramic Measurements		
	Both Jaws	Maxilla	Mandible	Both Jaws	Maxilla	Mandible
Number	70	36	34	70	36	34
Mean(SD)	18.15(5.12)	17.74(6.70)	18.59(2.63)	17.54(5.00)	17.37(6.58)	17.72(2.49)
Min-Max	5.48-29,35	5.48-29,35	13.72-24.42	5.8-34.1	5.8-34.1	13.7-23.2

Min= Minimum; Max= Maximum; SD= Standard Deviation

Table 2. Statistical interpretation

Both Jaws	0.69mm	0.089
Maxilla	0.34mm	0.57
Mandible	0.86mm	0.004

DISCUSSION

Before planning implant treatment, we should evaluate the pathological condition and surrounding structures and bone by radiography [13]. The aim of this study was to determine the accuracy of linear bone height measurement for implant placement

in panoramic radiography compared to CBCT in posterior jaw areas

On the other hand, panoramic has many inherent defects that have been studied in various studies, which estimate less than the distance from the crest to the upper channel border, The effect of calibration method by special software on measurement [9] The effect of head position on measurement, Horizontal distortion, disproportionate vertical magnification, Impossibility of observing real connections of anatomical factors,

influence of operator work, The effect Locality of the buccally or lingually nerve in the ridge on the measured linear distance from the crest to the upper nerve border [11] Among the weaknesses are Panoramic, Greenstein et al., believe that these limitations can lead to treatment failure [18] Tang et al., also suggest that when there is a risk of damage to pivotal structures or in cases of moderate or severe periodontitis, bone length should be examined by 3D radiographs [5]. Monsour et al., stated in part of their study that the alveolar inferior canal is not always well imaged on panoramic radiographs and that its relationship to the crest ridge may be distorted, For example, if the canal is close to the lingual cortex, it may be displayed at higher height on film [11]. In another study, Isidor et al., reported that bone margins could not be detected due to superimpositions in panoramic imaging [19] considering the Panoramic Magnification factors [20] and in accordance with the recommendations for placing the implant on top of the alveolar inferior canal, a safe margin of at least 2 millimeters from the end of the implant to the upper border of the alveolar inferior canal is recommended [9,21]. However, Gerlach et al., stated that this safe margin in CBCT imaging was 1.7 mm, which was very close to the recommended number for panoramic radiography [22].

Considering the above evidence and the many contradictions that have been raised in the use of Panoramic in pre-implant studies: This study was designed to check the validity of measurements in panoramic images. The characteristic of this study,

unlike many studies with a similar subject, is that instead of using metal balls, bone implants and dry skulls, the real condition of the patients is used to be similar to the usual measurements in the clinic. Further explanation that although precision studies using metal balls and implants are more accurate in terms of dimensions, but in the clinic and in the pre-implant surgery examination, how clinician works is closer to our study method and therefore, the results of our study are more similar to the work of clinicians in the clinic.

According to the results of this study, there were many similarities between the CBCT and panoramic imaging dimensions in the maxilla (from the index to the lower sinus border) and these finding endorse the results obtained in the studies done by Luangchana et al. [23] and Vazquez et al. [9]. Our study showed a significant difference between the measurements obtained from CBCT imaging and the measurements obtained from panoramic imaging in the mandible. In these areas, the measurements obtained in Panoramic were significantly lower than CBCT. Therefore, according to the results of this study, the use of panoramic radiography to evaluate bone height in the posterior regions of the mandible is not valid and can have negative consequences due to the presence of vital anatomical structures of the mandibular nerve. This finding is exactly in line with the conclusion of the study of El Fayoumy et al. [24] and also similar to the conclusion drawn of by Angelopoulos et al. [25] and Sirin et al. [26] and is contrary to the conclusion of the study of HU et al. [27]

which showed that the mandible has less error than the maxilla.

It should be noted that studies on the accuracy of Panoramic measurements have had very different results. Luangchana et al. [23] reported that there was not much difference between linear measurements of CBCT images taken with Accuitomo 170 and CS 9500 and images taken of digital panoramic devices before implant treatment. Vazquez et al. [9] reported that the mean distortion ratio was 0.99 for implants and 0.97 for metal balls, and concluded that vertical measurements were acceptable when a software-based calibration device was used and could be used with panoramic digital radiographic instruments and Panoramic digital radiographic instruments can be used to determine the length of preoperative implant implantation in the mandibular and molar sections .

Tang et al. [28] stated that despite the difference in magnification in different parts of the panoramic radiograph, the distances measured by the OPG were highly correlated with the CBCT measurements .

Yim et al. [29] reported that in panoramic images there was a magnification between 1.09 and 1.28 mm, while no specific magnification was seen at the location of the tooth imaged on CBCT radiography .

Angelopoulos et al. [25] done his study to diagnose the mandibular canal in pre-implant surgery, also reported that reconstructed panoramic images of CBCT were more accurate than other imaging modalities .

Renton et al. [30] also stated that 90% of idiopathic trigeminal neuropathies are found in patients who had only been evaluated by two-dimensional radiographs prior to implant surgery, whereas this was only the case when CBCT radiographs were evaluated before implantation which was of magnitude of 10%. whereas Sirin et al. [26] also reported that CBCT radiography was more accurate in determining the damage to the upper border of the IAN nerve canal during implant surgery .

CONCLUSION

Most of studies showed, the markers with specific dimensions such as spheres and implants or dry skulls have been used, the results of the measurements between Panoramic and CBCT are relatively similar [9, 23].

However, in studies in which measurements are made by anatomical and radiographic indices and landmarks, the validity of the posterior mandibular measurement based on Panoramic radiography is questioned and the use of CBCT is recommended [26, 31]. This conclusion was also confirmed by our study data.

According to the results of current study, it can be concluded that height assessment can be performed using panoramic radiography in the maxilla, while in the mandible, height measurement from the crest to the upper border of the IAN canal is not reliable and the use of CBCT is preferred.

COMPETING INTERESTS DISCLAIMER:

Authors have declared that no competing interests exist. The products used for this

research are commonly and predominantly use products in our area of research and country. There is absolutely no conflict of interest between the authors and producers of the products because we do not intend to use these products as an avenue for any litigation but for the advancement of knowledge. Also, the research was not funded by the producing company rather it was funded by personal efforts of the authors.

Reference

1. Alhassani AA, AlGhamdi AST. Inferior Alveolar Nerve Injury in Implant Dentistry: Diagnosis, Causes, Prevention, and Management. *Journal of Oral Implantology*. 2010;36(5):401-7.
2. Chatvaratthana K, Thaworanunta S, Seriwatanachai D, Wongsirichat N. Correlation between the thickness of the crestal and buccolingual cortical bone at varying depths and implant stability quotients. *PLoS One*. 2017;12(12):e0190293.
3. Lindquist LW, Carlsson GE, Jemt T. A prospective 15-year follow-up study of mandibular fixed prostheses supported by osseointegrated implants. Clinical results and marginal bone loss. *Clin Oral Implants Res*. 1996;7(4):329-36.
4. Belser UC, Schmid B, Higginbottom F, Buser D. Outcome analysis of implant restorations located in the anterior maxilla: a review of the recent literature. *Int J Oral Maxillofac Implants*. 2004;19 Suppl:30-42.
5. Özalp Ö, Tezerişener HA, Kocabalkan B, Büyükkaplan U, Özarslan MM, Şimşek Kaya G, et al. Comparing the precision of panoramic radiography and cone-beam computed tomography in avoiding anatomical structures critical to dental implant surgery: A retrospective study. *Imaging Sci Dent*. 2018;48(4):269-75.
6. Misch K, Wang HL. Implant surgery complications: etiology and treatment. *Implant Dent*. 2008;17(2):159-68.
7. SC w, MJ P. oral radiology principle and interpretation 2014.
8. Jaju PP, Jaju SP. Clinical utility of dental cone-beam computed tomography: current perspectives. *Clin Cosmet Investig Dent*. 2014;6:29-43.
9. Vazquez L, Nizamaldin Y, Combescure C, Nedir R, Bischof M, Dohan Ehrenfest DM, et al. Accuracy of vertical height measurements on direct digital panoramic radiographs using posterior mandibular implants and metal balls as reference objects. *Dentomaxillofac Radiol*. 2013;42(2):20110429.
10. Lecomber AR, Yoneyama Y, Lovelock DJ, Hosoi T, Adams AM. Comparison of patient dose from imaging protocols for dental implant planning using conventional radiography and computed tomography. *Dentomaxillofac Radiol*. 2001;30(5):255-9.
11. Monsour PA, Dudhia R. Implant radiography and radiology. *Aust Dent J*. 2008;53 Suppl 1:S11-25.
12. Jacobs R, Quirynen M. Dental cone beam computed tomography: justification for use in planning oral implant placement. *Periodontol 2000*. 2014;66(1):203-13.
13. Van Assche N, van Steenberghe D, Guerrero ME, Hirsch E, Schutyser F, Quirynen M, et al. Accuracy of implant placement based on pre-surgical planning of three-dimensional cone-beam images: a pilot study. *J Clin Periodontol*. 2007;34(9):816-21.
14. Sheikhi M, Ghorbanizadeh S, Abdinian M, Goroohi H, Badrian H. Accuracy of linear measurements of galileos cone beam computed tomography in normal and different head positions. *Int J Dent*. 2012;2012:214954.

15. Amarnath GS, Kumar U, Hilal M, Muddugangadhar BC, Anshuraj K, Shruthi CS. Comparison of Cone Beam Computed Tomography, Orthopantomography with Direct Ridge Mapping for Pre-Surgical Planning to Place Implants in Cadaveric Mandibles: An Ex-Vivo Study. *J Int Oral Health*. 2015;7(Suppl 1):38-42.
16. Klatt JC, Heiland M, Marx S, Hanken H, Schmelzle R, Pohlenz P. Clinical indication for intraoperative 3D imaging during open reduction of fractures of the mandibular angle. *J Craniomaxillofac Surg*. 2013;41(5):e87-90.
17. Allen F, Smith DG. An assessment of the accuracy of ridge-mapping in planning implant therapy for the anterior maxilla. *Clin Oral Implants Res*. 2000;11(1):34-8.
18. Greenstein G, Cavallaro J, Romanos G, Tarnow D. Clinical recommendations for avoiding and managing surgical complications associated with implant dentistry: a review. *J Periodontol*. 2008;79(8):1317-29.
19. Isidor F. Clinical probing and radiographic assessment in relation to the histologic bone level at oral implants in monkeys. *Clin Oral Implants Res*. 1997;8(4):255-64.
20. Vazquez L, Nizam Al Din Y, Christoph Belser U, Combescure C, Bernard JP. Reliability of the vertical magnification factor on panoramic radiographs: clinical implications for posterior mandibular implants. *Clin Oral Implants Res*. 2011;22(12):1420-5.
21. Buser D, von Arx T. Surgical procedures in partially edentulous patients with ITI implants. *Clin Oral Implants Res*. 2000;11 Suppl 1:83-100.
22. Gerlach NL, Meijer GJ, Maal TJ, Mulder J, Rangel FA, Borstlap WA, et al. Reproducibility of 3 different tracing methods based on cone beam computed tomography in determining the anatomical position of the mandibular canal. *J Oral Maxillofac Surg*. 2010;68(4):811-7.
23. Luangchana P, Pornprasertsuk-Damrongsri S, Kiattavorncharoen S, Jirajariyavej B. Accuracy of linear measurements using cone beam computed tomography and panoramic radiography in dental implant treatment planning. *Int J Oral Maxillofac Implants*. 2015;30(6):1287-94.
24. El Fayoumy HW, Saleh HAEK, Zayet MK, Dakhli I. Accuracy of Linear Measurements of Ultra-Low Dose Cone Beam Computed Tomography and Digital Panoramic Radiography Performed on Mandibular Anaesthetic Landmarks Versus Real Mandibular Measurements: A Diagnostic Accuracy Study. *EXECUTIVE EDITOR*. 2021;12(2):139.
25. Angelopoulos C, Thomas SL, Hechler S, Parissis N, Hlavacek M. Comparison between digital panoramic radiography and cone-beam computed tomography for the identification of the mandibular canal as part of presurgical dental implant assessment. *J Oral Maxillofac Surg*. 2008;66(10):2130-5.
26. Sirin Y, Yildirimturk S, Horasan S, Guven K. Diagnostic Potential of Panoramic Radiography and CBCT in Detecting Implant-Related Ex Vivo Injuries of the Inferior Alveolar Canal Border. *Journal of Oral Implantology*. 2020;46(3):206-13.
27. Hu KS, Kim S. Reply on "Reliability of two different presurgical preparation methods for implant dentistry based on panoramic radiography and cone-beam computed tomography in cadavers". *J Periodontal Implant Sci*. 2012;42(4):145.
28. Tang Z, Liu X, Chen K. Comparison of digital panoramic radiography versus cone beam computerized tomography for

measuring alveolar bone. *Head Face Med.* 2017;13(1):2.

29. Yim JH, Ryu DM, Lee BS, Kwon YD. Analysis of digitalized panorama and cone beam computed tomographic image distortion for the diagnosis of dental implant surgery. *J Craniofac Surg.* 2011;22(2):669-73.

30. Renton T, Dawood A, Shah A, Searson L, Yilmaz Z. Post-implant

neuropathy of the trigeminal nerve. A case series. *Br Dent J.* 2012;212(11):E17.

31. Guerrero ME, Noriega J, Castro C, Jacobs R. Does cone-beam CT alter treatment plans? Comparison of preoperative implant planning using panoramic versus cone-beam CT images. *Imaging science in dentistry.* 2014;44(2):121.

UNDER PEER REVIEW