

Original Research Article

EVALUATION OF INTERMENTAL FORAMINA DISTANCE AMONG SOUTH INDIAN POPULATION

ABSTRACT:

Background:

The intermental foramina distance varies between ethnicities, according to an OPG (orthopantomogram), which is a form of dental x-ray. The mandibular foramen has a bony canal developed in the mandible at two independent anatomies and its rim is 'v' shaped, that was its common form where the groove separating the anterior and posterior parts is horizontally orientated rim which is an oval shaped rim. The placement of the mandibular foramen varies by ethnicity; the intermental foramina distance is always measured from the mandibles' mid-line.

Materials & Methods:

The OPGs are collected from the private dental college and hospital in chennai. The location of mental foramen is identified and the intermental foramina distance is calculated by adobe photoshop. The collected data is analysed using SPSS software.

Results:

The average intermental foramen distance in the south Indian population was 4.93 cm. Males have a 5.14 cm inter mental foramen, whereas females have a 4.76 cm inter mental foramen. With a p value of 0.001, there is a significant difference in the intermental foramina distance between the genders in the south Indian population.

Conclusion:

Within the restrictions of the study, it may be stated that there is a significant difference in the intermental foramina distance between men and women in the south Indian population, with a p value of 0.001. The dentist's understanding of the intermental foramina difference is critical when performing implants, orthodontic surgery, and periodontal surgery. It aids the dentist in planning the drilling of the lower jaw bone.

KEYWORDS: Distance; Intermental foramina; Innovative technique; Mental foramen; Mandible; OPG; South Indian population;

Running Title: Inter-mental foramina distance using OPG

INTRODUCTION:

OPG (Orthopantomogram) is a type of dental x-ray in which it has been discovered that the intermental foramen differs by ethnicity. It's worth noting that the most visible area is below the second premolar. (1) The mandibular foramen is a bony canal developed in the mandible at two different anatomies, with a 'V' shaped rim. It has been revealed that the position of the mental foramen varies by ethnic group. (2) The mental foramen is most usually seen beneath the second premolar. Individual variation does exist, and it can be observed commonly anywhere between the premolar and mesial different planes, which are horizontal and thus vertical planes. (3) The horizontal position of the mental foramen was noted as being either parallel to the tooth's longitudinal axis or between two teeth. (4) The mental foramen's vertical location should be coronal to the apex, at the apex, or apical to the apex. (5)

Various markers on the jaw were used in some investigations to determine the position of the mental foramen. The symphysis menti, 6 posterior boundaries of the ramus of the mandible (in horizontal plane), and therefore the lower border of the body of the mandible are some of the most widely utilised landmarks (in vertical plane). (6) Using the midline of the jaw as an anatomical marker, numerous experiments are conducted to measure the distance between the interforamina. According to Shank-land, the mandibular foramen is located 28 mm from the mandible's midline and 14–15 mm from the inferior border. (7). The experience from our previous studies (8) (9,10) (9)(11)(12)(13)(14)(12,14)(15)(16) (17) have led us to focus on the current topic.

It also serves as a conduit for the evacuation of mental nerves and vessels, the majority of which are orientated postero-superiorly. An auxiliary mental foramen (AMF) is a foramen that is found below the first molar of teeth and is in addition or additional to the mental foramen (MF). The AMF transmits the branches of the mental nerves (18). Interforaminal distance is critical in evaluating the scenario and, as a result, the number of implants to be placed within the interforaminal area of a complete edentulous patient. (18,19) Our team has extensive

knowledge and research experience that has translate into high quality publications. (20–27),(28),(29),(30),(31,32),(33),(34),(35–39) The purpose of this study is to assess and investigate the distance between the intermental foramina in the south Indian population..

MATERIALS AND METHOD:

This is a retrospective panoramic radiography study conducted in a private dental college and hospital in Chennai and the study was approved by the institutional review board. Random sampling was done to select the participants for this study. A total of 100 panoramic radiographs orthopantomogram (OPG) of South Indian population of both sexes having visible mental foramina were collected. All panoramic radiographs were taken using Siemens Orthophos (Sirona) with magnification of 1.2. The radiographs were chosen based on the inclusion and exclusion criteria listed below. ethnicity of South India, In terms of geometric precision and visual contrast, the image is of high quality. The inclusion criteria include panoramic radiographs with bilaterally evident mental foramina. The exclusion criteria used in this study were poor OPG quality, radiopaque or radiolucent lesion within the lower arch, fractured mental foramen region, and a broken lower jaw that had been removed. Because unerupted teeth may hide the appearance of the mental foramen, the presence of supernumerary or unerupted teeth should be avoided.

Any radiographic exposure or processing artifacts. Adobe photoshop was used to view the x-ray, the magnification was 1.2, to calculate the intermental foramen the ruler option is selected on adobe photoshop and the vertical and horizontal markings done and the distance measured on each side of the mental foramen region. A vertical line marking the midline was drawn passing between the maxillary central incisors, the mandibular central incisors, or the septum (if the maxillary and mandibular central incisors were missing) by employing a ruler. The Collection of OPG's of mandibles is done, identifying the location of mental foramen in it and evaluating the intermental foramina distance and then entering the collected data into microsoft excel and analysing the data using the IBM SPSS software.

RESULTS:

Based on the selection criteria, 100 OPGs were chosen. Males made up 47 percent of the group, while females made up 53 percent. (fig1) The youngest patient was 11 years old, while

the oldest patient was 87. Females made up a greater percentage of the population, according to gender data (53 percent). The age group distribution of the people who participated in this study is as follows: people aged 1 to 15 belong to category 1 for 14 percent; people aged 16 to 30 belong to category 2 for 29 percent; people aged 31 to 45 belong to category 3 for 21 percent; people aged 46 to 60 belong to category 4 for 25 percent; and people aged 65 and over belong to category 5 for 11 percent. It is undeniable that the 16-to-30-year-old age range has a higher prevalence of on this study. (figure 2) The average inter-mental foramen distance in the South Indian population is 49.93 mm. (figure 3) Males have a 5.14 cm inter mental foramen, whereas females have a 4.76 cm inter mental foramen. With a p value of 0.001, there is a significant difference in the intermental foramina distance between the genders in the south Indian population.

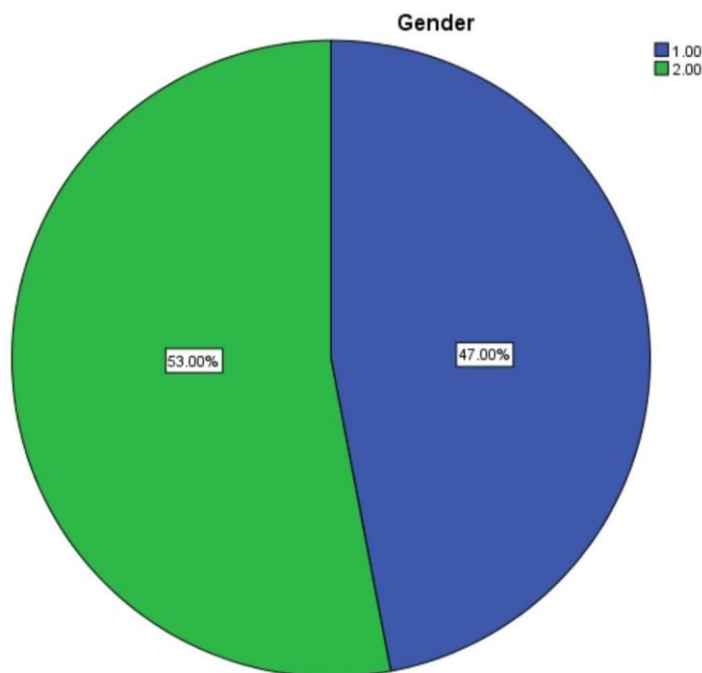


Fig 1: This pie chart represents the distribution of males and females who participated in this survey. Blue denotes male (1) for 47% and green denotes female (2) for 53% and Females participated more in this study.

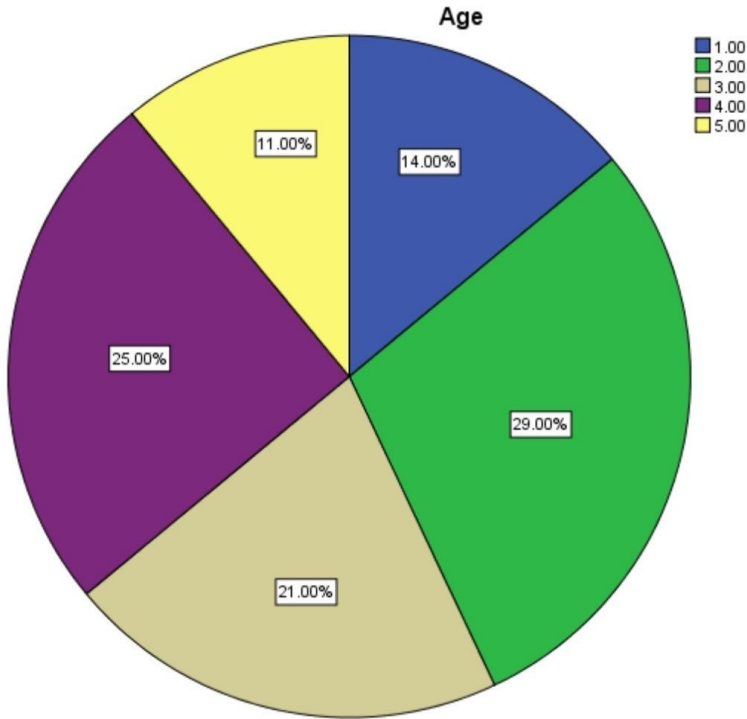


Fig 2: This pie chart represents the age group distribution of the people who are participated in this study age group of 1-15 belongs to category 1, blue denotes 1 for 14%; age group of 16-30 belongs to category 2, green denotes 2 for 29%; age group of 31 to 45 belongs to category 3, sandal colour denotes 3 for 21%; age group of 46 to 60 belongs to category 4, violet colour denotes 4 for 25%; people who were aged 65 & 65+ belongs to category 5, yellow colour denotes 5 for 11%. It is clear that the age group of 16 to 30 present more on this study.

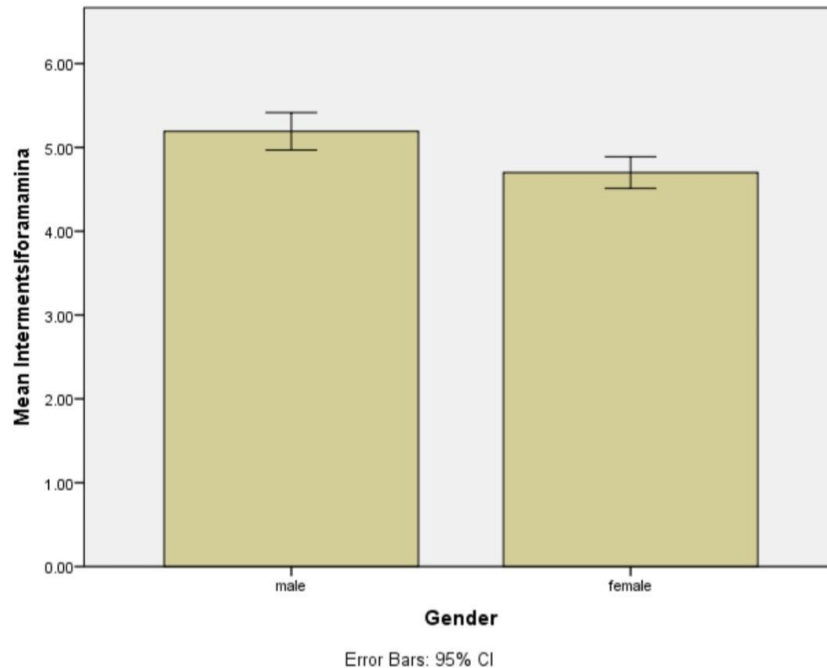


Fig 3: This bar chart represents the association between the gender and their intermental foramina distance. X axis represents gender and Y axis represents the mean intermental foramina distance. There is a significant difference in the intermental foramina distance between the gender with Males 5.14 cm and females it is 4.76 cm. with p value 0.001.

DISCUSSION:

This study has shown that the evaluation of the intermental foramina distance among the South Indian population has some little variations but it is statistically significant. The intermental foramina distance among the south Indian population varies from person to person and also has a huge difference between the geographical population when compared.

The determination of the intermental foramina distance among the various population has an important landmark for anatomical intrusions, there are little variations in different populations are proven by the failures of the anaesthesia in the mental foramen region, our study has demonstrated the most common position, which was similar to the North Americans, North Indians and Zimbabweans. (7,40,41)

Our study findings have coincided with those of Mohammed Jasim Al-Juboori and K.Udhaya., et al in different populations. These findings were significant with the higher prevalence of the position. The Nigerians and Kenyans have shown us the most common position followed by the Malays and Srilankan populations. They have shared the most similar intermental foramina distance. (42). The distance between the intermental foramina distance among south Indian population in males showed us 5.3 cm and in females it is 4.4 cm as the average distance and it is not significant for the both genders. (43)

In the previous investigation, accessory mental foramen were found on the left side of 3.33 percent of the mandibles and on the right side of 2.22 percent of the mandibles. Our findings were in contrast to those of Singh and Srivastava, who discovered 8% AMFs on the left side and 5% on the right side. (43,44) AMFs below the first molar have been reported by Cag Irankaya and Kansu, Singh et al. However, each AMF in our study had a variable position, such as between the 2nd premolar and the 1st molar, then between the first molar and thus the 2nd premolar (left side); between the 2nd premolar and the first molar, then between the first premolar and the 2nd premolar (right side); and finally between the first premolar and the 2nd premolar (right side). In Indian studies, there is a dearth of literature on this topic. There is very little material on the proportions of the AMF that matches ours. Our investigation found a vertical diameter of 2.26 mm with an HD of 1.58 mm on the left side, whereas Singh et al. found a mean diameter of 1mm. For each sex, the data was separated according to ethnicity. The most widely used approach for identifying mental foramen was proposed by Fishel et al and Greenstein et al. (45)

The intermental foramina distance was also researched by Neiva et al, who discovered that the distance between the left and right foramen was 55.23 ± 5.34 mm. Apinhasmit et al⁸ discovered that the mental foramen was 28.52 ± 2.15 mm from the root of the primary molar in another investigation. (46)The practitioner should constantly keep in mind that the IMF distance should not be set based on the patient's ethnicity or other independent variables.

Limitations of this study are low case study, random sampling, lesser time limit, ethical issues in identifying opg's and names that can't be revealed. The data collected are highly confidential. Dental implants and other major/minor surgery can be easily done with the identification of the intermental foramina distance, preparation for the surgery can be easily made according to the requirements. Future studies with large sample size should be conducted for more reliable results and to make the context evident.

CONCLUSION:

From the results of the study within the limitations it can be concluded that there is a significant difference in the intermental foramina distance between the gender among the south Indian population with p value 0.001. The knowledge on the intermental foramina difference is the important measure for the dentist while performing the implants, orthodontic surgery, and periodontal surgery. It helps the dentist to make the planning for drilling the lower jaw bone

• **COMPETING INTERESTS DISCLAIMER:**

- Authors have declared that no competing interests exist. The products used for this research are commonly and predominantly use products in our area of research and country. There is absolutely no conflict of interest between the authors and producers of the products because we do not intend to use these products as an avenue for any litigation but for the advancement of knowledge. Also, the research was not funded by the producing company rather it was funded by personal efforts of the authors.

REFERENCES:

1. Al-Juboori MJ, Department of Periodontology, Al-Rafidain University College, Baghdad, Iraq, Al-Juboori AJ, et al. The Relationship between the Lip Length and Smile Line in a Malaysian Population: A Cross-Sectional Study [Internet]. Vol. 3, Journal of Dentistry and Oral Care. 2017. p. 1–5. Available from: <http://dx.doi.org/10.15436/2379-1705.17.1385>
2. Al-Juboori MJ. The Importance of the Mental Foramen Location Detection by Using Different Radiographic Technique: Mini Review [Internet]. Vol. 2, International Journal of Medical Imaging. 2014. p. 63. Available from: <http://dx.doi.org/10.11648/j.ijmi.20140203.14>
3. Singh S, Suman P, Mahato R. Mental foramen and accessory mental foramen: a dry human mandibles study in South Indian population [Internet]. Vol. 7, National Journal of Clinical Anatomy. 2018. p. 182. Available from: <http://dx.doi.org/10.4103/2277-4025.294770>
4. Musrati A, Elhassan A, Ehtiwash N, Peeran S, Alzahrani F. Location of mental foramen in a group of Libyan patients: An orthopantomographic study [Internet]. Vol. 7, Dentistry and Medical Research. 2019. p. 45. Available from: http://dx.doi.org/10.4103/dmr.dmr_21_19
5. Singh R, Srivastav AK. Study of Position, Shape, Size and Incidence of Mental Foramen and Accessory Mental Foramen in Indian Adult Human Skulls [Internet]. Vol. 28, International Journal of Morphology. 2010. p. 1141–6. Available from: <http://dx.doi.org/10.4067/s0717-95022010000400025>
6. Singh R. Evaluation of position, shape, size and incidence of mental foramen and accessory mental foramen in Indian adult human skulls [Internet]. Vol. 5, Anatomy (International Journal of Experimental and Clinical Anatomy). 2011. p. 23–9. Available from:

<http://dx.doi.org/10.2399/ana.10.004>

7. Shah DMP, Shah MP, Associate professor: Dept. of Anatomy, AMC Met Medical College, Ahmedabad. A Study of position of mental foramen and accessory mental foramen in 300 mandibles of Gujurat population [Internet]. Vol. 2, International Journal of Scientific Research. 2012. p. 412–3. Available from: <http://dx.doi.org/10.15373/22778179/july2013/140>
8. Shruthi M, Preetha S. Effect of Simple Tongue Exercises in Habitual Snorers [Internet]. Vol. 11, Research Journal of Pharmacy and Technology. 2018. p. 3614. Available from: <http://dx.doi.org/10.5958/0974-360x.2018.00665.0>
9. Preetha S, Packyanathan J. Comparison of the effect of Yoga, Zumba and Aerobics in controlling blood pressure in the Indian population [Internet]. Vol. 9, Journal of Family Medicine and Primary Care. 2020. p. 547. Available from: http://dx.doi.org/10.4103/jfmpc.jfmpc_607_19
10. J SK, Saveetha Dental College and Hospitals, Road PH, Chennai, Tamilnadu, Preetha S, et al. Effect of aerobics exercise and yoga on blood pressure in hypertensives [Internet]. Vol. 6, International Journal of Current Advanced Research. 2017. p. 3124–6. Available from: <http://dx.doi.org/10.24327/ijcar.2017.3126.0200>
11. Prathap L, Suganthirababu P, Ganesan D. Fluctuating Asymmetry of Dermatoglyphics and DNA Polymorphism in Breast Cancer Population [Internet]. Vol. 10, Indian Journal of Public Health Research & Development. 2019. p. 3574. Available from: <http://dx.doi.org/10.5958/0976-5506.2019.04141.x>
12. Lavanya J, Prathap S, Alagesan J. Digital and palmar dermal ridge patterns in population with breast carcinoma. Biomedicine. 2014 Jul 1;34(3):315–21.
13. Prathap L, Jagadeesan V. Association of quantitative and qualitative dermatoglyphic variable and DNA polymorphism in female breast cancer population. Online J Health [Internet]. 2017; Available from: https://www.researchgate.net/profile/Prathap_Suganthirababu/publication/321606278_Association_of_Quantitative_and_Qualitative_Dermatoglyphic_Variable_and_DNA_Polymorphism_in_Female_Breast_Cancer_Population/links/5a28c8f1a6fdcc8e8671c0cd/Association-of-Quantitative-and-Qualitative-Dermatoglyphic-Variable-and-DNA-Polymorphism-in-Female-Breast-Cancer-Population.pdf
14. Lavanya J, Kumar VJ, Sudhakar N, Prathap S. Analysis of DNA repair genetic polymorphism in breast cancer population. Int J Pharma Bio Sci [Internet]. 2015; Available from: https://scholar.google.ca/scholar?cluster=8949053652564257518&hl=en&as_sdt=0,5&scio dt=0,5
15. Prathap L, Suganthirababu P. Estrogen Exposure and its Influence in DNA Repair Genetic Variants in Breast Cancer Population [Internet]. Vol. 13, Biomedical and Pharmacology Journal. 2020. p. 1321–7. Available from: <http://dx.doi.org/10.13005/bpj/2001>
16. Ravikumar H, Prathap L, Preetha S. ANALYSIS OF PALMAR ATD ANGLE IN POPULATION WITH MALOCCLUSION. 2020 Jan 1;1174–82.

17. Prathap L. INTERPLAY OF OXIDATIVE STRESS AND LIPOPROTEINS IN BREAST CARCINOMA INITIATION, PROMOTION AND PROGRESSION -A SYSTEMATIC REVIEW. *PalArch's Journal of Archaeology of Egypt/ Egyptology* [Internet]. 2021 Jan 7 [cited 2021 Mar 9];17(7). Available from: <http://dx.doi.org/>
18. Samanta PP, Kharb P. MORPHOMETRIC ANALYSIS OF MANDIBULAR FORAMEN AND INCIDENCE OF ACCESSORY MANDIBULAR FORAMINA IN ADULT HUMAN MANDIBLES OF AN INDIAN POPULATION. Análisis morfométrico del foramen mandibular e incidencia de la foramina mandibular accesoria en mandíbulas adult [Internet]. Vol. 5, *Revista Argentina de Anatomía Clínica*. 2016. p. 60–6. Available from: <http://dx.doi.org/10.31051/1852.8023.v5.n2.14059>
19. Seema, Seema, Verma P. Morphology and morphometry of mental foramen in adult human mandibles of North Indian population [Internet]. Vol. 4, *National Journal of Clinical Anatomy*. 2015. p. 76. Available from: <http://dx.doi.org/10.4103/2277-4025.297305>
20. Sekar D, Lakshmanan G, Mani P, Biruntha M. Methylation-dependent circulating microRNA 510 in preeclampsia patients. *Hypertens Res*. 2019 Oct;42(10):1647–8.
21. Princeton B, Santhakumar P, Prathap L. Awareness on Preventive Measures taken by Health Care Professionals Attending COVID-19 Patients among Dental Students. *Eur J Dent*. 2020 Dec;14(S 01):S105–9.
22. Logeshwari R, Rama Parvathy L. Generating logistic chaotic sequence using geometric pattern to decompose and recombine the pixel values. *Multimed Tools Appl*. 2020 Aug;79(31-32):22375–88.
23. Johnson J, Lakshmanan G, M B, R M V, Kalimuthu K, Sekar D. Computational identification of MiRNA-7110 from pulmonary arterial hypertension (PAH) ESTs: a new microRNA that links diabetes and PAH. *Hypertens Res*. 2020 Apr;43(4):360–2.
24. Paramasivam A, Priyadharsini JV, Raghunandhakumar S, Elumalai P. A novel COVID-19 and its effects on cardiovascular disease. *Hypertens Res*. 2020 Jul;43(7):729–30.
25. Pujari GRS, Subramanian V, Rao SR. Effects of *Celastrus paniculatus* Willd. and *Sida cordifolia* Linn. in Kainic Acid Induced Hippocampus Damage in Rats. *Ind J Pharm Educ*. 2019 Jul 3;53(3):537–44.
26. Rajkumar KV, Lakshmanan G, Sekar D. Identification of miR-802-5p and its involvement in type 2 diabetes mellitus. *World J Diabetes*. 2020 Dec 15;11(12):567–71.
27. Ravisankar R, Jayaprakash P, Eswaran P, Mohanraj K, Vinitha G, Pichumani M. Synthesis, growth, optical and third-order nonlinear optical properties of glycine sodium nitrate single crystal for photonic device applications. *J Mater Sci: Mater Electron*. 2020 Oct;31(20):17320–31.
28. Wu S, Rajeshkumar S, Madasamy M, Mahendran V. Green synthesis of copper nanoparticles using *Cissus vitiginea* and its antioxidant and antibacterial activity against urinary tract infection pathogens. *Artif Cells Nanomed Biotechnol*. 2020 Dec;48(1):1153–8.
29. Vikneshan M, Saravanakumar R, Mangaiyarkarasi R, Rajeshkumar S, Samuel SR, Suganya M, et al. Algal biomass as a source for novel oral nano-antimicrobial agent. *Saudi*

J Biol Sci. 2020 Dec;27(12):3753–8.

30. Alharbi KS, Fuloria NK, Fuloria S, Rahman SB, Al-Malki WH, Javed Shaikh MA, et al. Nuclear factor-kappa B and its role in inflammatory lung disease. *Chem Biol Interact*. 2021 Aug 25;345:109568.
31. Rao SK, Kalai Priya A, Manjunath Kamath S, Karthick P, Renganathan B, Anuraj S, et al. Unequivocal evidence of enhanced room temperature sensing properties of clad modified Nd doped mullite Bi₂Fe₄O₉ in fiber optic gas sensor [Internet]. Vol. 838, *Journal of Alloys and Compounds*. 2020. p. 155603. Available from: <http://dx.doi.org/10.1016/j.jallcom.2020.155603>
32. Bhavikatti SK, Karobari MI, Zainuddin SLA, Marya A, Nadaf SJ, Sawant VJ, et al. Investigating the Antioxidant and Cytocompatibility of *Mimusops elengi* Linn Extract over Human Gingival Fibroblast Cells. *Int J Environ Res Public Health* [Internet]. 2021 Jul 4;18(13). Available from: <http://dx.doi.org/10.3390/ijerph18137162>
33. Marya A, Karobari MI, Selvaraj S, Adil AH, Assiry AA, Rabaan AA, et al. Risk Perception of SARS-CoV-2 Infection and Implementation of Various Protective Measures by Dentists Across Various Countries. *Int J Environ Res Public Health* [Internet]. 2021 May 29;18(11). Available from: <http://dx.doi.org/10.3390/ijerph18115848>
34. Barma MD, Muthupandiyani I, Samuel SR, Amaechi BT. Inhibition of *Streptococcus mutans*, antioxidant property and cytotoxicity of novel nano-zinc oxide varnish. *Arch Oral Biol*. 2021 Jun;126:105132.
35. Vijayashree Priyadharsini J. In silico validation of the non-antibiotic drugs acetaminophen and ibuprofen as antibacterial agents against red complex pathogens. *J Periodontol*. 2019 Dec;90(12):1441–8.
36. Priyadharsini JV, Vijayashree Priyadharsini J, Smiline Girija AS, Paramasivam A. In silico analysis of virulence genes in an emerging dental pathogen *A. baumannii* and related species [Internet]. Vol. 94, *Archives of Oral Biology*. 2018. p. 93–8. Available from: <http://dx.doi.org/10.1016/j.archoralbio.2018.07.001>
37. Uma Maheswari TN, Nivedhitha MS, Ramani P. Expression profile of salivary micro RNA-21 and 31 in oral potentially malignant disorders. *Braz Oral Res*. 2020 Feb 10;34:e002.
38. Gudipani RK, Alam MK, Patil SR, Karobari MI. Measurement of the Maximum Occlusal Bite Force and its Relation to the Caries Spectrum of First Permanent Molars in Early Permanent Dentition. *J Clin Pediatr Dent*. 2020 Dec 1;44(6):423–8.
39. Chaturvedula BB, Muthukrishnan A, Bhuvanaraghavan A, Sandler J, Thiruvengatachari B. *Dens invaginatus*: a review and orthodontic implications. *Br Dent J*. 2021 Mar;230(6):345–50.
40. The Morphometric Analysis of the Mental Foramen in Adult Dry Human Mandibles : A Study on the South Indian Population [Internet]. *JOURNAL OF CLINICAL AND DIAGNOSTIC RESEARCH*. 2013. Available from: <http://dx.doi.org/10.7860/jcdr/2013/6060.3207>
41. Mohammad ZK, Shadid R, Kaadna M, Qabaha A, Muhamad AH. Position of the Mental Foramen in a Northern Regional Palestinian Population [Internet]. Vol. 2, *International*

Journal of Oral and Craniofacial Science. 2016. p. 057–64. Available from: <http://dx.doi.org/10.17352/2455-4634.000020>

42. Ilayperuma I, Nanayakkara G, Palahepitiya N. Morphometric Analysis of the Mental Foramen in Adult Sri Lankan Mandibles [Internet]. Vol. 27, International Journal of Morphology. 2009. Available from: <http://dx.doi.org/10.4067/s0717-95022009000400010>
43. Alrahabi M, Zafar M. Anatomical Variations of Mental Foramen: A Retrospective Cross-Sectional Study [Internet]. Vol. 36, International Journal of Morphology. 2018. p. 1124–9. Available from: <http://dx.doi.org/10.4067/s0717-95022018000301124>
44. Kim I-S, Kim S-G, Kim Y-K, Kim J-D. Position of the Mental Foramen in a Korean Population: A Clinical and Radiographic Study [Internet]. Vol. 15, Implant Dentistry. 2006. p. 404–11. Available from: <http://dx.doi.org/10.1097/01.id.0000243319.66845.15>
45. Chandramohan RV, Ramanathan S, Rethinasamy M, Muthulingam V. A COMPARATIVE STUDY OF MORPHOLOGICAL AND MORPHOMETRIC ANALYSIS OF MENTAL FORAMEN AND ITS CLINICAL IMPORTANCE ON HUMAN DRY MANDIBLES OF SOUTH INDIAN POPULATION [Internet]. Vol. 5, Journal of Evolution of Medical and Dental Sciences. 2016. p. 5439–44. Available from: <http://dx.doi.org/10.14260/jemds/2016/1232>
46. Suman P, Singh S, Mahato RK. Mental foramen and accessory mental foramen: a dry human mandibles study in South Indian population [Internet]. Vol. 7, National Journal of Clinical Anatomy. 2018. p. 182–91. Available from: <http://dx.doi.org/10.1055/s-0040-1701734>