

## Original Research Article

### **Morphological characteristic and incidence of elongate styloid process in south Indian population: A case series**

#### **ABSTRACT:**

**INTRODUCTION:** Styloid process is a slender osseous projection, cylindrical and sharp projection of the temporal bone, located in front of stylomastoid foramen. Styloid process is from Reichert's cartilage of the second branchial arch, this is a part of the splanchnocranium. This is connected to the hyoid bone through the Stylohyoid ligament. The morphology of the Styloid process is due to hormonal and genetic changes. Orthopantomography is a radiographic method used to visualise mandibles. It also provides a rotational view of the jaw. The aim of the study is to analyse the elongation of the Styloid process in the South Indian population.

**MATERIALS AND METHODS:** The study was conducted in dental institutions with convenience sampling. The random orthopantomogram sample was collected from a dental institution. Total number of orthopantomogram involved in the study was 80 (40-males and 40-females) that is used to examine elongation of the Styloid process in the South Indian population. The minimised sampling bias is done by stratification according to age and gender.

**STATISTICAL ANALYSIS :** The data were analysed by using SPSS software. The probability value  $p < 0.05$  is considered as significant and the value  $p > 0.05$  was considered as not significant.

**RESULT:** This study showed various types of Styloid processes in males and females. However we concluded that there is a difference in shape of Styloid processes. The most common type of the Styloid process found in males is pseudo articulated (32.5%) whereas in females the most common type of Styloid process found is uninterrupted (37.5%)

**CONCLUSION:** From the current study we have concluded that the pseudo articulated Styloid process is more in males whereas uninterrupted is more in females. Only retrospective studies were done so far. Therefore in future studies with live models and larger sample size should be conducted.

**KEYWORDS:** Elongated Styloid process; orthopantomogram; forensic identification; Innovative method.

## **INTRODUCTION:**

Styloid process is a slender osseous projection, cylindrical and sharp projection of the temporal bone, located in front of stylomastoid foramen. Styloid process is from Reichert's cartilage of the second branchial arch, this is a part of the splanchnocranium. This is connected to hyoid bone through the Stylohyoid ligament.(1) Different methods are there to evaluate morphological aspects of the styloid process, they are human dry skulls(2), digital panoramic radiographs(3)(4), computed tomography[CT](5)(6) and cone beam computed tomography[CBCT](7)(8). Digital panoramic radiographs are accurate enough for the diagnosis of elongated styloid process, even though they are having computed tomography and cone beam computed tomography. More over digital panoramic studies are the primary resource for epidemiological studies due to high distribution and easy interpretation.(9,10) Elongated styloid process is classified based on radiographic features by Langlais et al as follows: TYPE I as elongated, TYPE II pseudo articulated and TYPE III as segmented. The elongation of the styloid process is accompanied by calcification of stylohyoid and stylomandibular ligaments, potentially triggering a series of symptoms, they are pain when movement of head takes place, irritation /foreign body sensation in the throat, dysphagia, facial pain, earache, trismus. Eagle's syndrome is associated with these symptoms.(11) Diagnosis of elongated styloid process is confirmed by analysis of radiographs and clinical examination of the patient is considered as an important tool. The experience from our previous studies (12)(13)(14)(15)(16)(17)(18)(19)(20)(21)(22) have led us to focus on the current topic.(12)

There are many suggested hypotheses, exact etiology of calcified and ossified styloid processes are unknown. (23)(24) Eagle syndrome diagnosis is done by both radiographic and physical examination. For complementary information computed tomography is useful, which is provided by panoramic radiographs.(25) It was observed that the length of the styloid process increased with an increasing age and the length of the styloid process was more in males compared with females. Elongation of the styloid process may be a fortuitous asymptomatic radiographic observation. Although the panoramic radiograph is the more common radiographic view to detect the elongation of the styloid process, other views such as posterior–anterior projection of

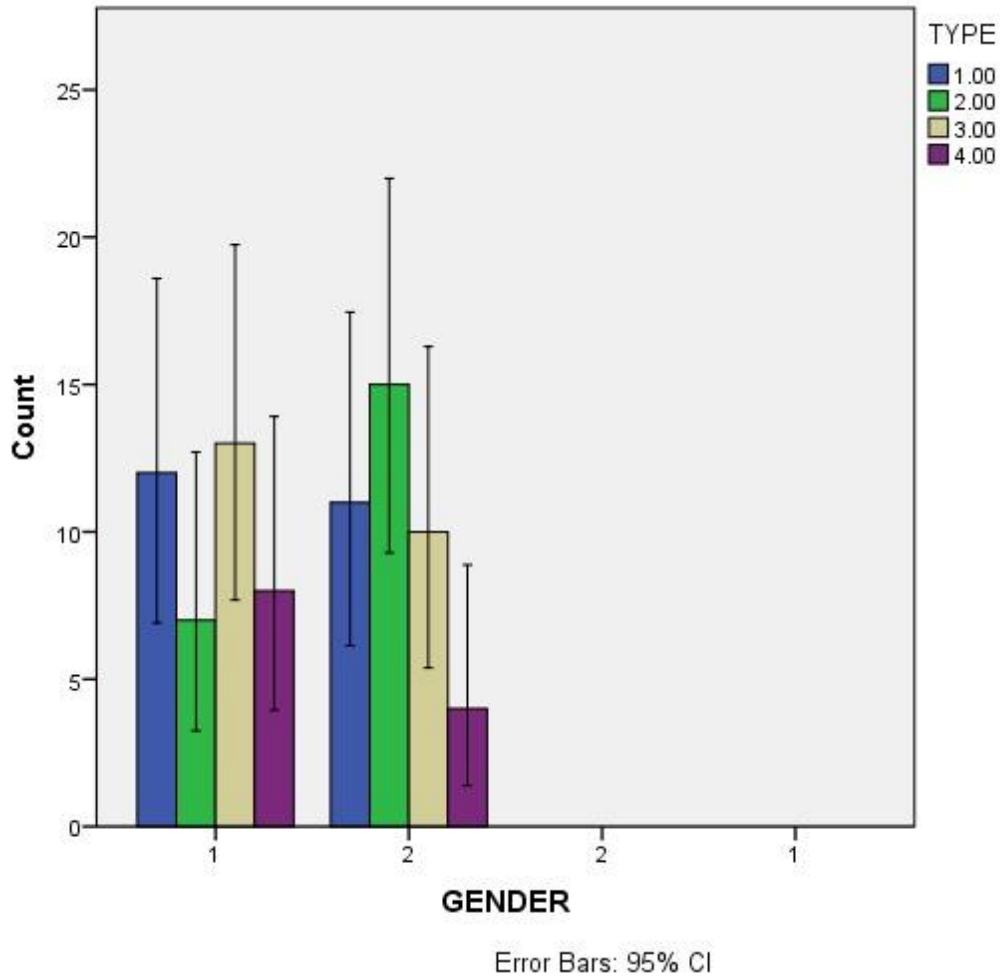
the mandible, lateral oblique projection of the mandible and axial and cephalometric radiographs can also aid in establishing the elongated process. Our team has extensive knowledge and research experience that has translate into high quality publications (26–33),(34),(35),(36),(37,38),(39),(40),(41–45). The present study was carried out in the south indian population to analyse the elongation of the Styloid process in the South Indian population

## **MATERIALS AND METHODS:**

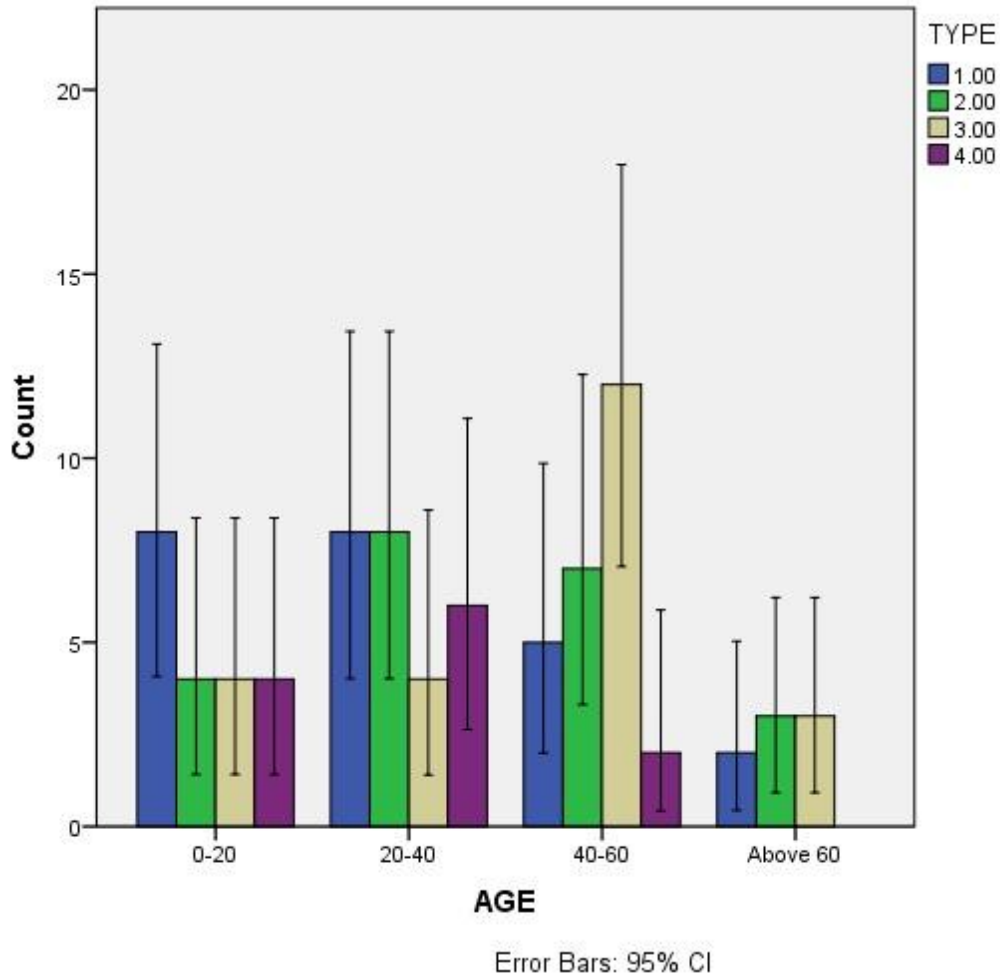
The study to determine the type of elongated styloid process on the panoramic radiographs and the incidence of elongated styloid process was conducted in dental institutions. The study is approved by the institutional review board. A total of 80 (40 males and 40 females ) radiographs were taken and included in the study. Stratification is done based on age and gender. There are four types of styloid process: normal, uninterrupted, pseudoarticulation and segmented styloid. The Variables are dependent on ethnicity and races among the south indian population. Patients aged 10 years and above and High quality OPG's with respect to coloration and angulation were included. Exclusion criteria-Patients affected with dental and maxillofacial fractures, joint disjunction, traumas, pathological lesions around temporomandibular joints were excluded and Patients undergoing surgery or orthodontic purposes were excluded from the study. Data were analyzed statistically by SPSS 2.3. by chi square test.

## **RESULTS:**

This study showed various types of Styloid processes in males and females. However we concluded that there is a difference in shape of Styloid processes. Out of 80, 40 were males and 40 were females. The most common type of the Styloid process found in males is pseudo articulated(32.5%) whereas in females the most common type of Styloid process found is uninterrupted (37.5%). Relation between gender and type shows that uninterrupted styloid is less in male and segmented styloid is less in females. The percentage of uninterrupted styloid in male is 17.5% whereas in females the percentage of Uninterrupted styloid is 37.5%. Males have 30% of normal Styloid whereas females have 27.5% of normal Styloid. The study relationship with age and type, between 0-20 normal is more, between 20-40 normal and uninterrupted is more, between 40-60 pseudoarticulation is more and above 60 uninterrupted and pseudo articulation is more. (Figure 1,2)



**Figure-1:** This graph shows the mean value of the elongated styloid process in males and females. X axis- 1 represents male and 2 represents female. In the Y axis represents number of samples TYPE I is normal [blue], TYPE II is uninterrupted [green], TYPE III is pseudo articulated [yellow], TYPE IV is segmented [purple].The mean value of the elongated styloid process is observed to be statistically significant with  $p < 0.05$



**Figure-2:** This graph shows the mean value of the elongated styloid process in males and females. The X axis represents the age group and Y axis represents the number of samples. TYPE I is normal [blue], TYPE II is uninterrupted [green], TYPE III is pseudo articulated [yellow], TYPE IV is segmented [purple]. The mean value of the elongated styloid process is observed to be statistically significant with  $p < 0.05$ .

## DISCUSSION:

Our study showed various types of Styloid processes in males and females. The result showed that the common type in males is pseudo articulated whereas in females the common type is uninterrupted. In radiographic presentation, TYPE III i.e pseudo articulation is more in males compared to others, whereas TYPE II is more in females i.e uninterrupted when compared to other types, in the South Indian population.

Prevalence and pattern of elongated styloid process among geriatric patients in Saudi Arabia-elongated type is more but , in the South Indian population among 80 patients pseudo articulation is more.(10) TYPE III comprises short or long non continuous portions. Styloid complex or interrupted segment mineralised styloid ligament. In radiographic presentation, TYPE III is less compared to other types in males. In females segmented styloid is less in number among 80 in the South Indian population. A study talked about morphological variations of styloid processes and reconstructive surgeries such as flooring and anthropology. The structure of styloid process is used in forensic identification and sex determination. It is also used for determination of heredity. But sex determination with shape and size of Styloid process is not reliable.(46,47))

A study showed various shapes of styloid processes in males and females using orthopantomogram. Orthopantomography[OPG] is a radiographic method used to visualize mandibles. It also provides a rotational view of the jaw. Out of all the methods OPG's were found to be cost efficient. OPG shows different shapes of the styloid process bilaterally which is appreciated. Previously evaluation of styloid process and elongated process were done using CBCT(Cone Beam Computed Tomography) ; they provide transition of dental diagnosis and possess 2D(two dimensional) and 3D(three dimensional)(48). Morphological variations are caused due to development and growth. Therefore morphology of the styloid process is due to chewing habits, hormonal factors, heredity and growth.(49). The traumas can be observed by panoramic radiographs. CBCT were used for identifying styloid fractures in accordance with previous study. Our study showed the various shapes of the elongated styloid process in the South Indian population using orthopantomogram.(50)

The limitations of the study is that only retrospective studies were done so far. Therefore in future studies with live models and larger sample size should be conducted. Therefore it gains a

vital importance in the source of graft material. mineralization in the site of elongated styloid process is a rather common anatomic abnormality, which is easily detected in panoramic radiographs. In future, studies with live specimens and large sample size should be conducted to make the context evident which may have more forensic and surgical relevance.

#### **CONCLUSION:**

The results of the study suggests that the pseudo articulated Styloid process is more in males whereas uninterrupted is more in females of the South Indian population. The data from our study will help the surgeons to know more about the Styloid process and plan surgeries accordingly. Future studies with live models and larger sample size should be conducted to make the context evident.

#### **COMPETING INTERESTS DISCLAIMER:**

Authors have declared that no competing interests exist. The products used for this research are commonly and predominantly use products in our area of research and country. There is absolutely no conflict of interest between the authors and producers of the products because we do not intend to use these products as an avenue for any litigation but for the advancement of knowledge. Also, the research was not funded by the producing company rather it was funded by personal efforts of the authors.

#### **REFERENCE:**

1. Natsis K, Repousi E, Noussios G, Papathanasiou E, Apostolidis S, Piagkou M. The styloid process in a Greek population: an anatomical study with clinical implications. *Anat Sci Int.* 2015 Mar;90(2):67–74.
2. Vadgaonkar R, Murlimanju BV, Prabhu LV, Rai R, Pai MM, Tonse M, et al. Morphological study of styloid process of the temporal bone and its clinical implications. *Anat Cell Biol.* 2015 Sep;48(3):195–200.
3. Vieira EMM, Guedes OA, Morais SD, Musis CRD, Albuquerque PAAD, Borges ÁH. Prevalence of Elongated Styloid Process in a Central Brazilian Population. *J Clin Diagn Res.* 2015 Sep;9(9):ZC90–2.
4. Sudhakara Reddy R, Sai Kiran C, Sai Madhavi N, Raghavendra MN, Satish A. Prevalence

of elongation and calcification patterns of elongated styloid process in south India. *J Clin Exp Dent*. 2013 Feb 1;5(1):e30–5.

5. Gözil R, Yener N, Calgüner E, Araç M, Tunç E, Bahcelioğlu M. Morphological characteristics of styloid process evaluated by computerized axial tomography. *Ann Anat*. 2001 Nov;183(6):527–35.
6. Başekim CC, Mutlu H, Güngör A, Silit E, Pekkafali Z, Kutlay M, et al. Evaluation of styloid process by three-dimensional computed tomography. *Eur Radiol*. 2005 Jan;15(1):134–9.
7. Andrei F, Motoc AGM, Didilescu AC, Rusu MC. A 3D cone beam computed tomography study of the styloid process of the temporal bone. *Folia Morphol* . 2013 Feb;72(1):29–35.
8. Oztunç H, Evlice B, Tatli U, Evlice A. Cone-beam computed tomographic evaluation of styloid process: a retrospective study of 208 patients with orofacial pain. *Head Face Med*. 2014 Feb 15;10:5.
9. Anbiaee N, Javadzadeh A. Elongated styloid process: is it a pathologic condition? *Indian J Dent Res*. 2011 Sep;22(5):673–7.
10. Shaik MA, Naheeda, Kaleem SM, Wahab A, Hameed S. Prevalence of elongated styloid process in Saudi population of Aseer region. *Eur J Dent*. 2013 Oct;7(4):449–54.
11. İlgüy D, İlgüy M, Fişekçioğlu E, Dölekoğlu S. Assessment of the Stylohyoid Complex with Cone Beam Computed Tomography [Internet]. Vol. 10, *Iranian Journal of Radiology*. 2012. p. 21–6. Available from: <http://dx.doi.org/10.5812/iranjradiol.4891>
12. Shruthi M, Preetha S. Effect of Simple Tongue Exercises in Habitual Snorers [Internet]. Vol. 11, *Research Journal of Pharmacy and Technology*. 2018. p. 3614. Available from: <http://dx.doi.org/10.5958/0974-360x.2018.00665.0>
13. Shruthi M, Preetha S. Effect of Simple Tongue Exercises in Habitual Snorers [Internet]. Vol. 11, *Research Journal of Pharmacy and Technology*. 2018. p. 3614. Available from: <http://dx.doi.org/10.5958/0974-360x.2018.00665.0>
14. Preetha S, Packyanathan J. Comparison of the effect of Yoga, Zumba and Aerobics in controlling blood pressure in the Indian population [Internet]. Vol. 9, *Journal of Family Medicine and Primary Care*. 2020. p. 547. Available from: [http://dx.doi.org/10.4103/jfmpc.jfmpc\\_607\\_19](http://dx.doi.org/10.4103/jfmpc.jfmpc_607_19)
15. J SK, Saveetha Dental College and Hospitals, Road PH, Chennai, Tamilnadu, Preetha S, et al. Effect of aerobics exercise and yoga on blood pressure in hypertensives [Internet]. Vol. 6, *International Journal of Current Advanced Research*. 2017. p. 3124–6. Available from: <http://dx.doi.org/10.24327/ijcar.2017.3126.0200>
16. Prathap L, Suganthirababu P, Ganesan D. Fluctuating Asymmetry of Dermatoglyphics and DNA Polymorphism in Breast Cancer Population [Internet]. Vol. 10, *Indian Journal of Public Health Research & Development*. 2019. p. 3574. Available from: <http://dx.doi.org/10.5958/0976-5506.2019.04141.x>
17. Lavanya J, Prathap S, Alagesan J. Digital and palmar dermal ridge patterns in population with breast carcinoma. *Biomedicine*. 2014 Jul 1;34(3):315–21.

18. Prathap L, Jagadeesan V. Association of quantitative and qualitative dermatoglyphic variable and DNA polymorphism in female breast cancer population. Online J Health [Internet]. 2017; Available from: [https://www.researchgate.net/profile/Prathap\\_Suganthirababu/publication/321606278\\_Association\\_of\\_Quantitative\\_and\\_Qualitative\\_Dermatoglyphic\\_Variable\\_and\\_DNA\\_Polymorphism\\_in\\_Female\\_Breast\\_Cancer\\_Population/links/5a28c8f1a6fdcc8e8671c0cd/Association-of-Quantitative-and-Qualitative-Dermatoglyphic-Variable-and-DNA-Polymorphism-in-Female-Breast-Cancer-Population.pdf](https://www.researchgate.net/profile/Prathap_Suganthirababu/publication/321606278_Association_of_Quantitative_and_Qualitative_Dermatoglyphic_Variable_and_DNA_Polymorphism_in_Female_Breast_Cancer_Population/links/5a28c8f1a6fdcc8e8671c0cd/Association-of-Quantitative-and-Qualitative-Dermatoglyphic-Variable-and-DNA-Polymorphism-in-Female-Breast-Cancer-Population.pdf)
19. Lavanya J, Kumar VJ, Sudhakar N, Prathap S. Analysis of DNA repair genetic polymorphism in breast cancer population. Int J Pharma Bio Sci [Internet]. 2015; Available from: [https://scholar.google.ca/scholar?cluster=8949053652564257518&hl=en&as\\_sdt=0,5&scio dt=0,5](https://scholar.google.ca/scholar?cluster=8949053652564257518&hl=en&as_sdt=0,5&scio dt=0,5)
20. Prathap L, Suganthirababu P. Estrogen Exposure and its Influence in DNA Repair Genetic Variants in Breast Cancer Population [Internet]. Vol. 13, Biomedical and Pharmacology Journal. 2020. p. 1321–7. Available from: <http://dx.doi.org/10.13005/bpj/2001>
21. Ravikumar H, Prathap L, Preetha S. ANALYSIS OF PALMAR ATD ANGLE IN POPULATION WITH MALOCCLUSION. 2020 Jan 1;1174–82.
22. Prathap L. INTERPLAY OF OXIDATIVE STRESS AND LIPOPROTEINS IN BREAST CARCINOMA INITIATION, PROMOTION AND PROGRESSION -A SYSTEMATIC REVIEW. PalArch's Journal of Archaeology of Egypt/ Egyptology [Internet]. 2021 Jan 7 [cited 2021 Mar 9];17(7). Available from: <http://dx.doi.org/>
23. Langlais RP, Miles DA, Van Dis ML. Elongated and mineralized stylohyoid ligament complex: a proposed classification and report of a case of Eagle's syndrome. Oral Surg Oral Med Oral Pathol. 1986 May;61(5):527–32.
24. Beder E, Ozgursoy OB, Karatayli Ozgursoy S. Current diagnosis and transoral surgical treatment of Eagle's syndrome. J Oral Maxillofac Surg. 2005 Dec;63(12):1742–5.
25. Gokce C, Sisman Y, Ertas ET, Akgunlu F, Ozturk A. Prevalence of Styloid Process Elongation on Panoramic Radiography in the Turkey Population from Cappadocia Region [Internet]. Vol. 02, European Journal of Dentistry. 2008. p. 18–22. Available from: <http://dx.doi.org/10.1055/s-0039-1697348>
26. Sekar D, Lakshmanan G, Mani P, Biruntha M. Methylation-dependent circulating microRNA 510 in preeclampsia patients. Hypertens Res. 2019 Oct;42(10):1647–8.
27. Princeton B, Santhakumar P, Prathap L. Awareness on Preventive Measures taken by Health Care Professionals Attending COVID-19 Patients among Dental Students. Eur J Dent. 2020 Dec;14(S 01):S105–9.
28. Logeshwari R, Rama Parvathy L. Generating logistic chaotic sequence using geometric pattern to decompose and recombine the pixel values. Multimed Tools Appl. 2020 Aug;79(31-32):22375–88.
29. Johnson J, Lakshmanan G, M B, R M V, Kalimuthu K, Sekar D. Computational identification of MiRNA-7110 from pulmonary arterial hypertension (PAH) ESTs: a new microRNA that

links diabetes and PAH. *Hypertens Res.* 2020 Apr;43(4):360–2.

30. Paramasivam A, Priyadharsini JV, Raghunandhakumar S, Elumalai P. A novel COVID-19 and its effects on cardiovascular disease. *Hypertens Res.* 2020 Jul;43(7):729–30.
31. Pujari GRS, Subramanian V, Rao SR. Effects of *Celastrus paniculatus* Willd. and *Sida cordifolia* Linn. in Kainic Acid Induced Hippocampus Damage in Rats. *Ind J Pharm Educ.* 2019 Jul 3;53(3):537–44.
32. Rajkumar KV, Lakshmanan G, Sekar D. Identification of miR-802-5p and its involvement in type 2 diabetes mellitus. *World J Diabetes.* 2020 Dec 15;11(12):567–71.
33. Ravisankar R, Jayaprakash P, Eswaran P, Mohanraj K, Vinitha G, Pichumani M. Synthesis, growth, optical and third-order nonlinear optical properties of glycine sodium nitrate single crystal for photonic device applications. *J Mater Sci: Mater Electron.* 2020 Oct;31(20):17320–31.
34. Wu S, Rajeshkumar S, Madasamy M, Mahendran V. Green synthesis of copper nanoparticles using *Cissus vitifolia* and its antioxidant and antibacterial activity against urinary tract infection pathogens. *Artif Cells Nanomed Biotechnol.* 2020 Dec;48(1):1153–8.
35. Vikneshan M, Saravanakumar R, Mangaiyarkarasi R, Rajeshkumar S, Samuel SR, Suganya M, et al. Algal biomass as a source for novel oral nano-antimicrobial agent. *Saudi J Biol Sci.* 2020 Dec;27(12):3753–8.
36. Alharbi KS, Fuloria NK, Fuloria S, Rahman SB, Al-Malki WH, Javed Shaikh MA, et al. Nuclear factor-kappa B and its role in inflammatory lung disease. *Chem Biol Interact.* 2021 Aug 25;345:109568.
37. Rao SK, Kalai Priya A, Manjunath Kamath S, Karthick P, Renganathan B, Anuraj S, et al. Unequivocal evidence of enhanced room temperature sensing properties of clad modified Nd doped mullite Bi<sub>2</sub>Fe<sub>4</sub>O<sub>9</sub> in fiber optic gas sensor [Internet]. Vol. 838, *Journal of Alloys and Compounds.* 2020. p. 155603. Available from: <http://dx.doi.org/10.1016/j.jallcom.2020.155603>
38. Bhavikatti SK, Karobari MI, Zainuddin SLA, Marya A, Nadaf SJ, Sawant VJ, et al. Investigating the Antioxidant and Cytocompatibility of *Mimusops elengi* Linn Extract over Human Gingival Fibroblast Cells. *Int J Environ Res Public Health* [Internet]. 2021 Jul 4;18(13). Available from: <http://dx.doi.org/10.3390/ijerph18137162>
39. Marya A, Karobari MI, Selvaraj S, Adil AH, Assiry AA, Rabaan AA, et al. Risk Perception of SARS-CoV-2 Infection and Implementation of Various Protective Measures by Dentists Across Various Countries. *Int J Environ Res Public Health* [Internet]. 2021 May 29;18(11). Available from: <http://dx.doi.org/10.3390/ijerph18115848>
40. Barma MD, Muthupandiyani I, Samuel SR, Amaechi BT. Inhibition of *Streptococcus mutans*, antioxidant property and cytotoxicity of novel nano-zinc oxide varnish. *Arch Oral Biol.* 2021 Jun;126:105132.
41. Vijayashree Priyadharsini J. In silico validation of the non-antibiotic drugs acetaminophen and ibuprofen as antibacterial agents against red complex pathogens. *J Periodontol.* 2019 Dec;90(12):1441–8.

42. Priyadharsini JV, Vijayashree Priyadharsini J, Smiline Girija AS, Paramasivam A. In silico analysis of virulence genes in an emerging dental pathogen *A. baumannii* and related species [Internet]. Vol. 94, Archives of Oral Biology. 2018. p. 93–8. Available from: <http://dx.doi.org/10.1016/j.archoralbio.2018.07.001>
43. Uma Maheswari TN, Nivedhitha MS, Ramani P. Expression profile of salivary micro RNA-21 and 31 in oral potentially malignant disorders. *Braz Oral Res.* 2020 Feb 10;34:e002.
44. Gudipani RK, Alam MK, Patil SR, Karobari MI. Measurement of the Maximum Occlusal Bite Force and its Relation to the Caries Spectrum of First Permanent Molars in Early Permanent Dentition. *J Clin Pediatr Dent.* 2020 Dec 1;44(6):423–8.
45. Chaturvedula BB, Muthukrishnan A, Bhuvanaraghan A, Sandler J, Thiruvengkatachari B. *Dens invaginatus*: a review and orthodontic implications. *Br Dent J.* 2021 Mar;230(6):345–50.
46. Rai SM, Nakarmi K, Basnet S, Shakya P, Nagarkoti K, Ghartimagar M, et al. Age of individuals undergoing cleft lip and cleft palate surgeries in Nepal. *JNMA J Nepal Med Assoc.* 2013 Oct;52(192):591–5.
47. Shakya S, Nagraj SK. Morphology of Coronoid Process and Sigmoid Notch in Orthopantomograms of South Indian Population [Internet]. Vol. 4, World Journal of Dentistry. 2013. p. 1–3. Available from: <http://dx.doi.org/10.5005/jp-journals-10015-1193>
48. Al-Ghurabi ZH, Al-Bahrani ZM. Cone Beam Computed Tomography Evaluation of the Morphological Variation and Width in Mandibular Condyle. *J Craniofac Surg* [Internet]. 2021 Jan 25; Available from: <http://dx.doi.org/10.1097/SCS.00000000000007465>
49. Ashwinirani SR, Suragimath G, Nayak A, Kamala KA, Sande A. Evaluation of coronoid process morphology in gender determination using orthopantomograms in western part of Maharashtra [Internet]. Vol. 2, International Journal of Forensic Odontology. 2017. p. 77. Available from: [http://dx.doi.org/10.4103/ijfo.ijfo\\_16\\_17](http://dx.doi.org/10.4103/ijfo.ijfo_16_17)
50. Gunduz K, Serindere G, Avsever H, Orhan K. A DETAILED CBCT STUDY OF “CORONOID FORAMINA” AND ACCESSORY FORAMINA OF THE MANDIBLE: A UNIQUE ANATOMIC VARIATION. *Acta Clin Croat.* 2019 Dec;58(4):693–700.