

Original Research Article

A RETROSPECTIVE STUDY ON IDENTIFICATION OF ANTERIOR LOOP PATTERN OF MENTAL NERVE ENTRY INTO MENTAL FORAMEN IN DIGITAL ORTHOPANTOMOGRAPHY AMONG SOUTH INDIAN POPULATION

Running Title: Identification of anterior loop pattern of entry of mental nerve.

ABSTRACT:

Background: In the premolar location of mandible, the mental nerve's entry into the mental foramen pattern is a significant landmark. Different patterns of mental nerve entrance have been discovered. The current experiment was attempted to detect the different entry routes of the mental nerve into the mandible using panoramic radiographs, which are employed in pre-surgical evaluation.

Materials and Methods: The current study used a total of 200 panoramic radiographs collected for diagnostic purposes. The location and entrance pattern of the mental nerve on the both sides were noted on the radiographs. Straight, looping, and perpendicular entry patterns were identified in the data. The data is tabulated and statistically analysed in SPSS software using Chi-square.

Results: The existence of an anterior loop was determined to be the most usual pattern of entry of the mental nerve, accounting for 79 percent of the total radiographs examined 21 percent , and a perpendicular pattern 6 percent. The p value is 0.432 and p value 0.309, with respect to age and gender respectively which is statistically not significant.

Conclusion: The findings obtained from the study within the limits, it can be stated that the straight pattern of anterior loop of mental nerve was the most common. A panoramic radiograph may be a viable radiological tool for detecting the existence of an anterior loop that should be confirmed in order to plan surgical treatments in the mandibular premolar region prior to surgery.

Key words: Anterior loop Pattern; panoramic radiography; emerging patterns; inventive technique; mental nerve;

INTRODUCTION:

The inferior alveolar nerve is a mandibular nerve branch that starts on the lingual side of the mandibular ramus and passes down to the mandibular canal, feeding teeth of mandible and adjoining gums (1). One of the terminal branches of the inferior alveolar nerve is the mental nerve, which arises from the mental foramen and supplies the skin and mucous membrane of the buccal vestibule from the medial border of the masseter muscle to the midline.(2)

Before the nerve emerges from the mental foramen, some authors documented an anterior loop. (3). The structure "where the inferior and anterior to the mental foramen has been crossed by mental neurovascular bundle then it doubles or loops back to exit the mental foramen" was first described by Bavitz and Misch. In around 11-60% of panoramic radiographs, this can be seen. More about the additional routes of the mental nerve as it escapes via the mental foramen has not been described. Some investigations classified the pattern as looped or non-looped, or defined it as posteriorly directed, anteriorly directed, or both.(4). The experience from our previous studies (5) (6,7) (6)(8)(9)(10)(11)(9,11)(12)(13) (14) have led us to focus on the current topic.

The most common problem during implant placement in the mandibular premolar region is neurosensory changes in the chin and lower lip. Complications can emerge when crucial critical structures like the mental foramen and anterior mental loop are not appropriately recognised and safeguarded. (15)Using proper radiography techniques, the exact location of the anatomical structures should be established prior to surgery to avoid harm to these essential structures. (15,16). Although a number of morphometric investigations have shown the mental nerve's entry pattern into the mental foramen, only a few radiography studies have been conducted in

this regard. (17) To plan these surgical procedures, anatomic landmarks are commonly discovered utilising panoramic radiography.

The purpose of this study is to see if a OPG is enough to detect the appearance of an anterior loop pattern and other related variable patterns of mental nerve entrance, or if more advanced imaging techniques are required. Our research team has published high-quality papers in the past(18–25),(26),(27),(28),(29,30),(31),(32),(33–37). The goal of this study is to use digital orthopantomography to discover the anterior loop pattern of the mental nerve's entry into the mental foramen.

MATERIALS AND METHODS:

This is a retrospective study conducted in a private dental college hospital in chennai and the study was approved by the institutional reveal board. Total 200 panoramic radiographs obtained from records maintained in the Department of Oral Medicine and Radiology were randomly selected for the study. Only high-quality radiographs with respect to geometric accuracy and contrast of image were selected for the study. Radiographs showing radiolucent or radiopaque lesions in the mental foramen region of mandible and evidence of fracture around the mental foramen and mandibular canal region, radiographs showing supernumerary or un-erupted teeth in the mental foramen region and radiographs showing processing or exposure errors and artifacts obscuring visibility of structures in the mandible were excluded from the study. The radiographs were evaluated for the pattern of entry of the mental nerve into the mental foramen on either side of the mandible. The observations thus made were recorded as Anterior loop(AL), straight(S), or Perpendicular(P) and the total numbers of patterns observed on both sides were recorded. Inter-observer variability was assessed using the kappa test. Tabulations for the presence of each pattern were done for both sides and the percentages calculated and analyzed using the SPSS tool.

RESULTS:

The most common pattern of mental nerve entry was found to be straight, accounting for seventy nine percent of all samples examined. The straight patterns is followed by the existence of an anterior loop (21%), and a perpendicular type of pattern. (6 percent). The p value is 0.432 and p value 0.309, with respect to age and gender respectively which is statistically not significant. (Figure 1,2)

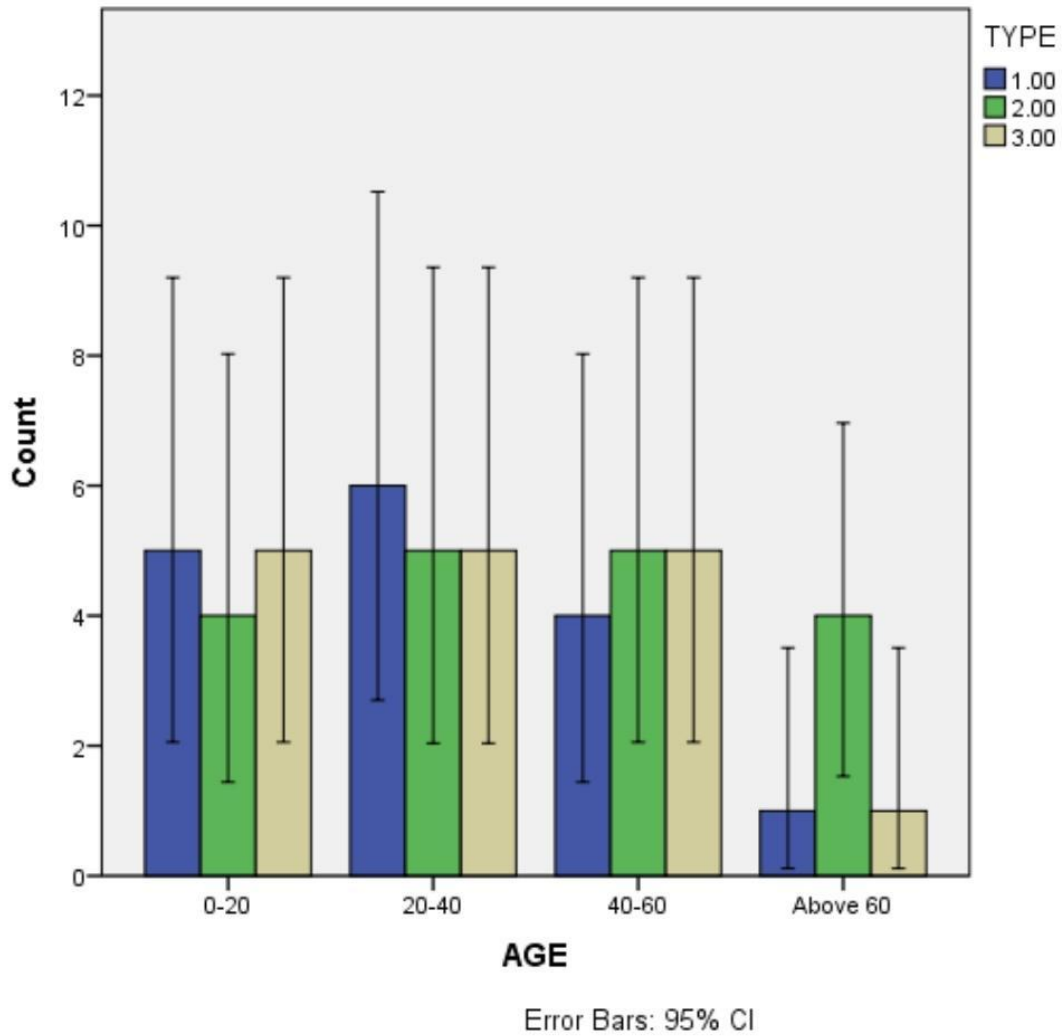


Fig 1- The frequency distribution with respect to age. The X axis presents the age and the y axis presents the number of samples. Type I is anterior loop (blue), type II is straight (green), type III is perpendicular (yellow). Anterior loop pattern is observed in more frequency among age group 20-40 yrs. The Chi square test was observed with p value 0.432, which is not significant.

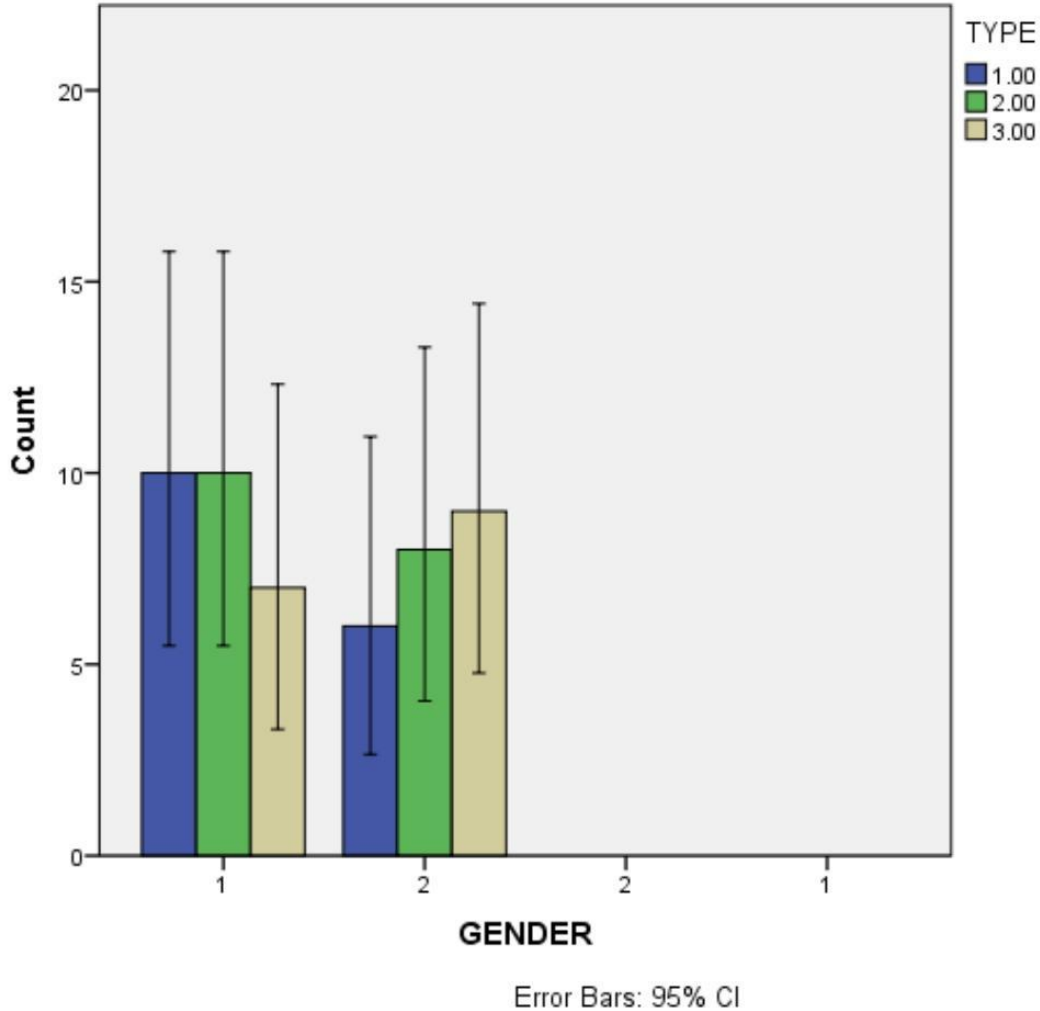


Figure 2: The frequency distribution with respect to gender. In the X axis, 1 presents male and 2 represents female. In the y axis the numbers represent the number of samples. Type I is anterior (blue), type II is straight (green), type III is perpendicular (yellow), among which anterior loop and straight pattern are more in males than females. Chi square test was done with p value 0.309, which is statistically not significant.

DISCUSSION:

Maximum samples account's for straight type of entrance of mental nerves into mental foramen, according to the findings of this study.

Few investigations in cadaveric mandibles have looked at the transitional section of the nerve, between the mandibular canal and the mental foramen is the inferior alveolar nerve. Solar and colleagues categorized their examples into loop and non-loop kinds. (38)The author looked at the real course of the mental nerve's emergence and classified it as with various patterns. An investigation of the origins of the mental nerve in a varied populations. A straight pattern of the mental canal entering into the mental foramen directly was discovered.(39)

So yet, no radiographic tests have been conducted to see if such patterns are detectable on radiographs. Despite the fact that radiographic studies have not reported the numerous forms of the mental nerve's entrance into the mental foramen. Dissimilar diagnostic techniques, equipment, and poor radiography quality may explain the diversity in the radiographic assessment of the anterior loop when reported for the varied rule used to describe the anterior loop. The inability to tell it apart from normal trabecular patterns is the most probable explanation.(40) The appearance of the anterior loop pattern on three-dimensional cone beam tomography has been determined to be significantly better in studies.(41)

The MF was nearer to the alveolar crest in the imaging with an anterior loop than in the radiographs with no loop, according to the current study. As a result of this discovery, It's possible that the mental nerve must loop back to enter the foramen when the mental foramen is little higher in the vertical planar line.

Finally, because of the existence of the anterior loop, the morphology of the premolar region of mandible has clinical relevance in preliminary assessment of surgical treatments. Neurosensory changes in the chin and lower lip may result from damage to this nerve bundle. The implantation of endosseous implants in the anterior inter-foraminal area has piqued researchers' curiosity. The most posterior implant should be positioned as near to the mental foramen as possible to maximise the space between implants (42).

The distal aspect of an implant in the mental region should be 1mm anterior to the anterior edge of the mental foramen., according to Bavitz et al (43). However, some writers suggest that the MF and the most dorsal implant be separated by at least 6 mm.. However, the study can be expanded to a larger scale in the future.

CONCLUSION:

The findings obtained from the study within the limits, it can be stated that the straight pattern of anterior loop of mental nerve was the most common. A panoramic radiograph may be a viable imaging tool for detecting the existence of an anterior loop that needs to be confirmed in order to plan surgical treatments in the premolar region of mandible prior to surgery. The exact design of premolar region of mandible, which is crucial for planning any surgical operations in this region, may need studies involving a range of ethnic groups.

REFERENCES:

1. Kieser J, Kuzmanovic D, Payne A, Dennison J, Herbison P. Patterns of emergence of the human mental nerve [Internet]. Vol. 47, Archives of Oral Biology. 2002. p. 743–7. Available from: [http://dx.doi.org/10.1016/s0003-9969\(02\)00067-5](http://dx.doi.org/10.1016/s0003-9969(02)00067-5)
2. Arzouman MJ, Otis L, Kipnis V, Levine D. Observations of the anterior loop of the inferior alveolar canal. Int J Oral Maxillofac Implants. 1993;8(3):295–300.
3. Bavitz JB, Harn SD, Hansen CA, Lang M. An anatomical study of mental neurovascular bundle-implant relationships. Int J Oral Maxillofac Implants. 1993;8(5):563–7.
4. Ngeow WC, Dionysius DD, Ishak H, Nambiar P. Effect of ageing towards location and visibility of mental foramen on panoramic radiographs. Singapore Dent J. 2010 Jun;31(1):15–9.
5. Shruthi M, Preetha S. Effect of Simple Tongue Exercises in Habitual Snorers [Internet]. Vol. 11, Research Journal of Pharmacy and Technology. 2018. p. 3614. Available from: <http://dx.doi.org/10.5958/0974-360x.2018.00665.0>
6. Preetha S, Packyanathan J. Comparison of the effect of Yoga, Zumba and Aerobics in controlling blood pressure in the Indian population [Internet]. Vol. 9, Journal of Family Medicine and Primary Care. 2020. p. 547. Available from: http://dx.doi.org/10.4103/jfmpc.jfmpc_607_19
7. J SK, Saveetha Dental College and Hospitals, Road PH, Chennai, Tamilnadu, Preetha S, et al. Effect of aerobics exercise and yoga on blood pressure in hypertensives [Internet]. Vol. 6, International Journal of Current Advanced Research. 2017. p. 3124–6. Available from: <http://dx.doi.org/10.24327/ijcar.2017.3126.0200>
8. Prathap L, Suganthirababu P, Ganesan D. Fluctuating Asymmetry of Dermatoglyphics and DNA Polymorphism in Breast Cancer Population [Internet]. Vol. 10, Indian Journal of Public Health Research & Development. 2019. p. 3574. Available from: <http://dx.doi.org/10.5958/0976-5506.2019.04141.x>
9. Lavanya J, Prathap S, Alagesan J. Digital and palmar dermal ridge patterns in population

with breast carcinoma. *Biomedicine*. 2014 Jul 1;34(3):315–21.

10. Prathap L, Jagadeesan V. Association of quantitative and qualitative dermatoglyphic variable and DNA polymorphism in female breast cancer population. *Online J Health [Internet]*. 2017; Available from: https://www.researchgate.net/profile/Prathap_Suganthirababu/publication/321606278_Association_of_Quantitative_and_Qualitative_Dermatoglyphic_Variable_and_DNA_Polymorphism_in_Female_Breast_Cancer_Population/links/5a28c8f1a6fdcc8e8671c0cd/Association-of-Quantitative-and-Qualitative-Dermatoglyphic-Variable-and-DNA-Polymorphism-in-Female-Breast-Cancer-Population.pdf
11. Lavanya J, Kumar VJ, Sudhakar N, Prathap S. Analysis of DNA repair genetic polymorphism in breast cancer population. *Int J Pharma Bio Sci [Internet]*. 2015; Available from: https://scholar.google.ca/scholar?cluster=8949053652564257518&hl=en&as_sdt=0,5&sciodt=0,5
12. Prathap L, Suganthirababu P. Estrogen Exposure and its Influence in DNA Repair Genetic Variants in Breast Cancer Population [Internet]. Vol. 13, *Biomedical and Pharmacology Journal*. 2020. p. 1321–7. Available from: <http://dx.doi.org/10.13005/bpj/2001>
13. Ravikumar H, Prathap L, Preetha S. ANALYSIS OF PALMAR ATD ANGLE IN POPULATION WITH MALOCCLUSION. 2020 Jan 1;1174–82.
14. Prathap L. INTERPLAY OF OXIDATIVE STRESS AND LIPOPROTEINS IN BREAST CARCINOMA INITIATION, PROMOTION AND PROGRESSION -A SYSTEMATIC REVIEW. *PalArch's Journal of Archaeology of Egypt/ Egyptology [Internet]*. 2021 Jan 7 [cited 2021 Mar 9];17(7). Available from: <http://dx.doi.org/>
15. Ulm CW, Solar P, Blahout R, Matejka M, Watzek G, Watzek G, et al. Location of the mandibular canal within the atrophic mandible [Internet]. Vol. 31, *British Journal of Oral and Maxillofacial Surgery*. 1993. p. 370–5. Available from: [http://dx.doi.org/10.1016/0266-4356\(93\)90193-z](http://dx.doi.org/10.1016/0266-4356(93)90193-z)
16. Hu K-S, Yun H-S, Hur M-S, Kwon H-J, Abe S, Kim H-J. Branching patterns and intraosseous course of the mental nerve. *J Oral Maxillofac Surg*. 2007 Nov;65(11):2288–94.
17. Juodzbalys G, Wang H-L, Sabalys G. Anatomy of mandibular vital structures. Part I: mandibular canal and inferior alveolar neurovascular bundle in relation with dental implantology. *J Oral Maxillofac Res*. 2010 Apr 1;1(1):e2.
18. Sekar D, Lakshmanan G, Mani P, Biruntha M. Methylation-dependent circulating microRNA 510 in preeclampsia patients. *Hypertens Res*. 2019 Oct;42(10):1647–8.
19. Princeton B, Santhakumar P, Prathap L. Awareness on Preventive Measures taken by Health Care Professionals Attending COVID-19 Patients among Dental Students. *Eur J Dent*. 2020 Dec;14(S 01):S105–9.
20. Logeshwari R, Rama Parvathy L. Generating logistic chaotic sequence using geometric pattern to decompose and recombine the pixel values. *Multimed Tools Appl*. 2020 Aug;79(31-32):22375–88.

21. Johnson J, Lakshmanan G, M B, R M V, Kalimuthu K, Sekar D. Computational identification of MiRNA-7110 from pulmonary arterial hypertension (PAH) ESTs: a new microRNA that links diabetes and PAH. *Hypertens Res.* 2020 Apr;43(4):360–2.
22. Paramasivam A, Priyadharsini JV, Raghunandhakumar S, Elumalai P. A novel COVID-19 and its effects on cardiovascular disease. *Hypertens Res.* 2020 Jul;43(7):729–30.
23. Pujari GRS, Subramanian V, Rao SR. Effects of *Celastrus paniculatus* Willd. and *Sida cordifolia* Linn. in Kainic Acid Induced Hippocampus Damage in Rats. *Ind J Pharm Educ.* 2019 Jul 3;53(3):537–44.
24. Rajkumar KV, Lakshmanan G, Sekar D. Identification of miR-802-5p and its involvement in type 2 diabetes mellitus. *World J Diabetes.* 2020 Dec 15;11(12):567–71.
25. Ravisankar R, Jayaprakash P, Eswaran P, Mohanraj K, Vinitha G, Pichumani M. Synthesis, growth, optical and third-order nonlinear optical properties of glycine sodium nitrate single crystal for photonic device applications. *J Mater Sci: Mater Electron.* 2020 Oct;31(20):17320–31.
26. Wu S, Rajeshkumar S, Madasamy M, Mahendran V. Green synthesis of copper nanoparticles using *Cissus vitiginea* and its antioxidant and antibacterial activity against urinary tract infection pathogens. *Artif Cells Nanomed Biotechnol.* 2020 Dec;48(1):1153–8.
27. Vikneshan M, Saravanakumar R, Mangaiyarkarasi R, Rajeshkumar S, Samuel SR, Suganya M, et al. Algal biomass as a source for novel oral nano-antimicrobial agent. *Saudi J Biol Sci.* 2020 Dec;27(12):3753–8.
28. Alharbi KS, Fuloria NK, Fuloria S, Rahman SB, Al-Malki WH, Javed Shaikh MA, et al. Nuclear factor-kappa B and its role in inflammatory lung disease. *Chem Biol Interact.* 2021 Aug 25;345:109568.
29. Rao SK, Kalai Priya A, Manjunath Kamath S, Karthick P, Renganathan B, Anuraj S, et al. Unequivocal evidence of enhanced room temperature sensing properties of clad modified Nd doped mullite Bi₂Fe₄O₉ in fiber optic gas sensor [Internet]. Vol. 838, *Journal of Alloys and Compounds.* 2020. p. 155603. Available from: <http://dx.doi.org/10.1016/j.jallcom.2020.155603>
30. Bhavikatti SK, Karobari MI, Zainuddin SLA, Marya A, Nadaf SJ, Sawant VJ, et al. Investigating the Antioxidant and Cytocompatibility of *Mimusops elengi* Linn Extract over Human Gingival Fibroblast Cells. *Int J Environ Res Public Health* [Internet]. 2021 Jul 4;18(13). Available from: <http://dx.doi.org/10.3390/ijerph18137162>
31. Marya A, Karobari MI, Selvaraj S, Adil AH, Assiry AA, Rabaan AA, et al. Risk Perception of SARS-CoV-2 Infection and Implementation of Various Protective Measures by Dentists Across Various Countries. *Int J Environ Res Public Health* [Internet]. 2021 May 29;18(11). Available from: <http://dx.doi.org/10.3390/ijerph18115848>
32. Barma MD, Muthupandiyani I, Samuel SR, Amaechi BT. Inhibition of *Streptococcus mutans*, antioxidant property and cytotoxicity of novel nano-zinc oxide varnish. *Arch Oral Biol.* 2021 Jun;126:105132.
33. Vijayashree Priyadharsini J. In silico validation of the non-antibiotic drugs acetaminophen

and ibuprofen as antibacterial agents against red complex pathogens. *J Periodontol.* 2019 Dec;90(12):1441–8.

34. Priyadharsini JV, Vijayashree Priyadharsini J, Smiline Girija AS, Paramasivam A. In silico analysis of virulence genes in an emerging dental pathogen *A. baumannii* and related species [Internet]. Vol. 94, *Archives of Oral Biology*. 2018. p. 93–8. Available from: <http://dx.doi.org/10.1016/j.archoralbio.2018.07.001>
35. Uma Maheswari TN, Nivedhitha MS, Ramani P. Expression profile of salivary micro RNA-21 and 31 in oral potentially malignant disorders. *Braz Oral Res.* 2020 Feb 10;34:e002.
36. Gudipani RK, Alam MK, Patil SR, Karobari MI. Measurement of the Maximum Occlusal Bite Force and its Relation to the Caries Spectrum of First Permanent Molars in Early Permanent Dentition. *J Clin Pediatr Dent.* 2020 Dec 1;44(6):423–8.
37. Chaturvedula BB, Muthukrishnan A, Bhuvanaraghan A, Sandler J, Thiruvengkatachari B. Dens invaginatus: a review and orthodontic implications. *Br Dent J.* 2021 Mar;230(6):345–50.
38. Rosenquist B. Fixture placement posterior to the mental foramen with transpositioning of the inferior alveolar nerve. *Int J Oral Maxillofac Implants.* 1992 Spring;7(1):45–50.
39. Mardinger O, Chaushu G, Arensburg B, Taicher S, Kaffe I. Anterior loop of the mental canal: an anatomical-radiologic study. *Implant Dent.* 2000;9(2):120–5.
40. Yosue T, Brooks SL. The appearance of mental foramina on panoramic radiographs. I. Evaluation of patients [Internet]. Vol. 68, *Oral Surgery, Oral Medicine, Oral Pathology*. 1989. p. 360–4. Available from: [http://dx.doi.org/10.1016/0030-4220\(89\)90224-7](http://dx.doi.org/10.1016/0030-4220(89)90224-7)
41. Chau A. Comparison between the use of magnetic resonance imaging and conebeam computed tomography for mandibular nerve identification [Internet]. Vol. 23, *Clinical Oral Implants Research*. 2012. p. 253–6. Available from: <http://dx.doi.org/10.1111/j.1600-0501.2011.02188.x>
42. von Arx T, Lozanoff S. *Clinical Oral Anatomy: A Comprehensive Review for Dental Practitioners and Researchers*. Springer; 2016. 561 p.
43. Jacobs R, Mraiwa N, vanSteenberghe D, Gijbels F, Quirynen M. Appearance, location, course, and morphology of the mandibular incisive canal: an assessment on spiral CT scan [Internet]. Vol. 31, *Dentomaxillofacial Radiology*. 2002. p. 322–7. Available from: <http://dx.doi.org/10.1038/sj.dmfr.4600719>