

ORAL CANDIDIASIS WITH SUBCUTANEAOUS EMPHYEMA ASSOCIATED WITH SARI FOLLOWING POST COVID 19 : A CASE REPORT

Ms. Shiwani Padmakarrao Dandade¹, Prof. Vaishali Taksande²

1. Shiwani P.Dandade, Basic B. Sc. Nursing Final Year Student, Smt.Radhikabai Meghe Memorial College of Nursing, Datta Meghe Institute of Medical Sciences, (Deemed to be University), Sawangi (M) Wardha, Maharashtra, India.

2. Vaishali Taksande , Vice Principal , Dept. of OBGY Nursing, Smt.Radhikabai Meghe Memorial College of Nursing, Datta Meghe Institute of Medical Sciences, (Deemed to be University), Sawangi (M) Wardha, Maharashtra, India.

Abstract:

Background: Over the last few decades, the covid 19 has increased all over the world. More issues are likely to be observed as covid 19 rate increases. The major cause of morbidity and mortality is infection. Oral Candidiasis With Subcutaneous Emphyema and SARI are very rare complications in Covid 19 patient. The final cause is infection ,but sometimes it causes due to allergic or inflammatory reaction of the drugs. If it occurs after post covid 19 then creates very serious issues with the peoples health.

Case presentation: Here we are mentioning a very rare case of Oral Candidiasis With Subcutaneous Emphyema and SARI after Covid 19 positive patient. In this case, on physical examination and investigation, it was found that, after covid 19 patient has developed Oral Candidiasis ,Subcutaneous Emphysema , severe breathlessness, cough, fever, nausea,vomiting, throat infection and loss of appetite. To overcome this sudden issue, emergency exploratory medical and surgical treatment was done.

During Covid 19 treament her HRCT Score was 21/25 and the infection was severe. There was no any sign of oral candidiasis, subcutaneous emphysema, or tissue or organ damage or no any other abnormality was detected during Covid 19 tratment. No bacterial growth or fungal growth observed on investigation. After some days and treatment of covid 19 the patient was developed a Oral Candidiasis and Subcutaneous Emphysema and SARI. The working diagnosis was finalized by doctors i.e. Oral Candidiasis With Subcutaneous Emphyema and SARI. After expert medical management and excellent nursing care patient was discharged with full recovery.

Conclusion: In this study, we mainly focus on expert medical management and excellent nursing care helped in managing the complicated case very nicely. All the patient response was positive for conservative and nursing management and after treatment the patient was discharged without any complications and satisfaction with full recovery.

Keywords: Oral Candidiasis, Subcutaneous Emphyema, SARI, Covid 19.

Introduction:

Over the last few decades, the covid 19 has increased all over the world. More issues are likely to be observed as covid 19 rate increases. Infection is the leading cause of morbidity and mortality. Oral Candidiasis With Subcutaneous Emphyema associated with SARI very rare complications in Covid 19 patient. The final cause is infection ,but sometimes it causes due to allergic or

inflammatory reaction of the drugs. If it occurs after post covid 19 then creates very serious issues with the peoples health. ¹

It's a life threatening situation and is a very serious issue with respect to Covid 19 .

The main cause of Oral Candidiasis and Subcutaneous Emphysema SARI is mostly bacterial or fungal infection, foreign bodies or any chemical agents. Due to these factors, organs or tissues may perforate and becomes infected. Sometimes in this situation the patient was death also .

In these cases,the patient was admitted in hospital for the treatment of Covid 19,during the treatment he developed the oral candidiasis,subcutaneous emphysema and SARI also, i.e. any bacterial or fungal infection of tissue damage of the Oropharyngeal tract. To improve patient survival and decrease mortality rate of the client a medical and surgical treatment given to the client. Sometimes, the exact cause cannot be found after an extensive diagnostic work-up. In these cases, very rarely allergic and inflammatory reaction may be the final diagnosis. ²

Case history:

A case was taken from the Acharya Vinoba Bhave Rural Hospital, Datta Meghe Institute of Medical Sciences, (Deemed to be University), Sawangi (Meghe), Wardha, Maharashtra, India. After covid 19 infection, this complicated case was taken care nicely by the hospital because of expert medical team management and excellent nursing care. ³

Patient information

We report a 59 year-old-male was post covid-19 infection, complete covid-19 period. During covid 19 infection, he was developed severe Odynophagia and Candidia flaky whitish over the tongue and postpharyngeal wall. After contrast-enhanced computed tomography (CECT) of the neck extensive subcutaneous emphysema dissecting into the deeper soft tissue and musculature,extending from chest wall to Superior mediastinum and neck space bilaterally are present .Crepitus noted in anterior neck and both supraclavicular region. After all the investigation the patient was diagnosed as Oral Candidiasis With Subcutaneous Emphysema and Severe Acute Respiratory Infection (SARI) followed Covid -19 infection. ⁴

Patient belonged to middle class family. His family members had no any complaints of communicable and non-communicable diseases. He maintained a good interpersonal relationship with family members and relatives and neighbours also. But due to this condition he had developed some symptoms like irritability, anxiety, crying and restlessness and found it difficult cooperate. He was behaving like this due to separation from her family and community. Previously and at the time of admission patient doesn't have the communicable and noncommunicable disease . ⁵

After admission Ryle's tube intubation was inserted. On admission, his vital sign was temperature 98.8⁰F, Pulse rate 108/min , Blood pressure 110/70 mm of Hg. Overall, this condition was managed by administration of intravenous fluid and antibiotic treatment. Blood investigation and the contrast - enhanced computed tomography (CECT) were done, CECT report the neck extensive subcutaneous emphysema dissecting into the deeper soft tissue and musculature,extending from chest wall to Superior mediastinum and neck space bilaterally present. ⁶

Physical Examination:

His Physical examination was done and on examination swelling is present on the neck region. And in the mouth candida flake (whitish) over tongue is present. Other than there were no any abnormality was detected.⁷

Diagnostic assessment:

The laboratory test was conducted and results were: Hemoglobin 12.5 gm /dl (12.1-15.1 gm/dl), and total leukocyte count was 11,400 cell/m³ (5000-11,000 cell/m³), total RBC 3.78 cell/m³, total platelet count 1.3 per microliter and radiologist mentioned in CECT report, i.e. the neck extensive subcutaneous emphysema dissecting into the deeper soft tissue and musculature, extending from chest wall to Superior mediastinum and neck space bilaterally present.⁸

Preoperative care

Doctors tried to treat this condition with the help of conservative management, i.e. Inj Ceftriaxone 1 gm antibiotic intravenously, inj. Metronidazole 100ml antimicrobial intravenously, Inj tramadol pain killer in IV drip, Inj neomol 100ml antipyretic intravenously given, but only operation was next choice for surgeon to handle this case and before start surgical operation preparation written consent was taken by his son and physical and psychological preparation was done preoperatively. All these conditions were very threatenful to patient because he was so much worried about her health. On observation he looked very tensed.

But exact cause was not found and finally on respiratory opinion ICD placement was done for management of subcutaneous emphysema.⁹

Postoperative care

Postoperatively the patient shifted in the surgery Intensive Care Unit; semi fowler's position was given, 4 hourly Ryle's tube aspiration and abdominal girth was measured. Post operatively continuous cardiac monitoring was done, Inj. Piptaz 4.45 gm higher antibiotic intravenously, inj. Metronidazole 100ml antimicrobial intravenously, Inj Pantoprazole antacid 40 mg intravenously, Inj. Emset 4 mg antiemetic intravenously, Inj Tramadol pain killer in an IV drip, Inj Neomol 100ml antipyretic intravenously given as per doctors ordered.¹⁰

But exact cause was not found and finally on respiratory opinion ICD placement was done for management of subcutaneous emphysema.¹¹

Nursing management

Postoperatively the patient was under strict observation of on duty staff. Intravenous fluid administered as per calculation. Vital signs were recorded strictly. Overall her response was positive for treatment and patient condition too improved progressively.

Excellent nursing care was given and the patient herself reported to nursing staff that. He was very satisfied about nursing care.¹² Complete discharge procedure was explained by nursing staff to the patient and his family members along with medication prescribed at home as advised by the surgeon. The patient was discharged without any complications.¹³

Discussion:

This was a very rare medical case of exact cause is unknown. No any additional medical treatment was given other than intravenous antibiotics and antimicrobial injections. Pain killer and antiemetic.¹⁴

A previously healthy 25-year-old female dentist was quarantined because SARS-CoV-2 conformingly infected some members of her household. A few days later, the patient started to feel fatigued, headache, anosmia and ageusia; therefore, she was instructed to follow a medical protocol composed of moxifloxacin, pantoprazole (Zurcal), and multivitamins. Two weeks after losing taste and smell, the patient had a severe burning sensation, and she immediately sought a teleconsultation and sent us her intra-oral images (Figure 1).

The images revealed a typical presentation of erythematous candidiasis over the tongue dorsum. The patient was managed by topical antifungal only, miconazole (Daktarin Gel) four times/day. The candida pain has degraded within four days without further complications.¹⁵

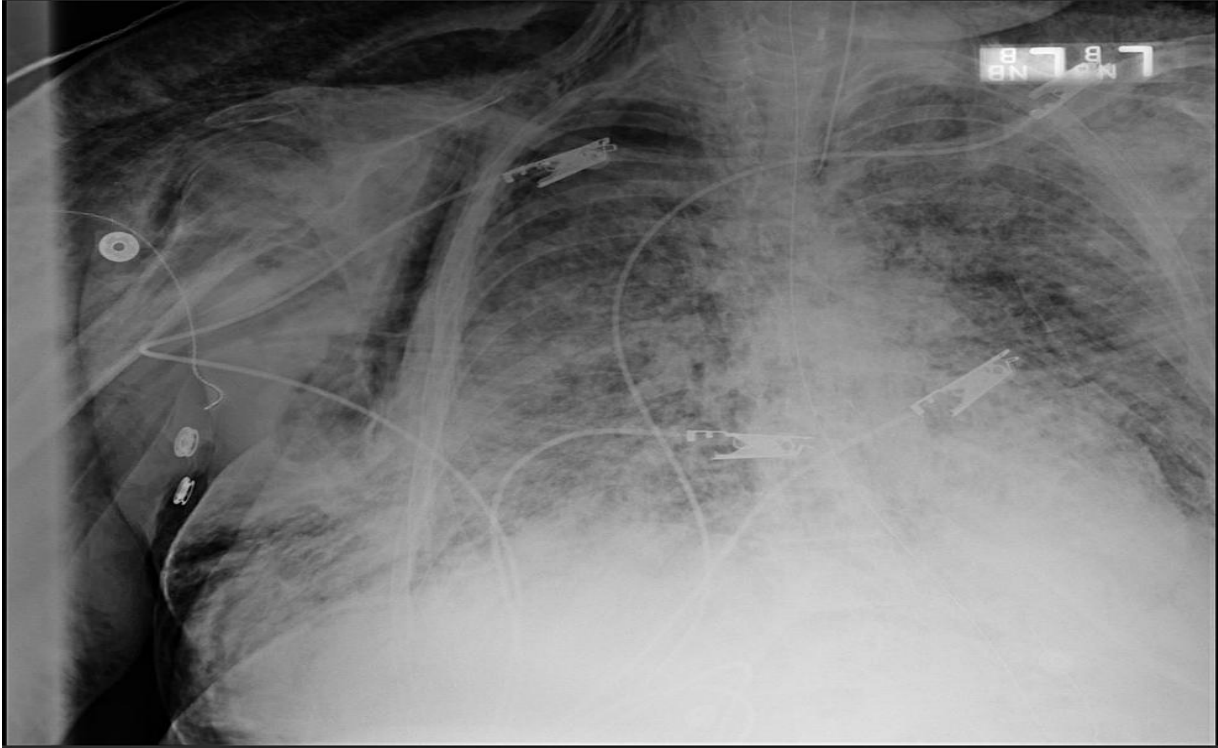
A 64-year-old male admitted with two weeks of non-productive cough, fever, and chills. He did not have any underlying medical conditions and was a non-smoker. On arrival, SaO₂ was 76% on room air and he required oxygen through HFNC 40 L/minute and O₂ at 100% with improvement in SaO₂ to 95%. CXR showed diffuse bilateral patchy airspace opacities indicative of multifocal pneumonia (Figure 2), and he had a positive test for SARS-CoV-2.¹⁶

The patient was treated with hydroxychloroquine, azithromycin, and methylprednisolone for five days and piperacillin/tazobactam for seven days.

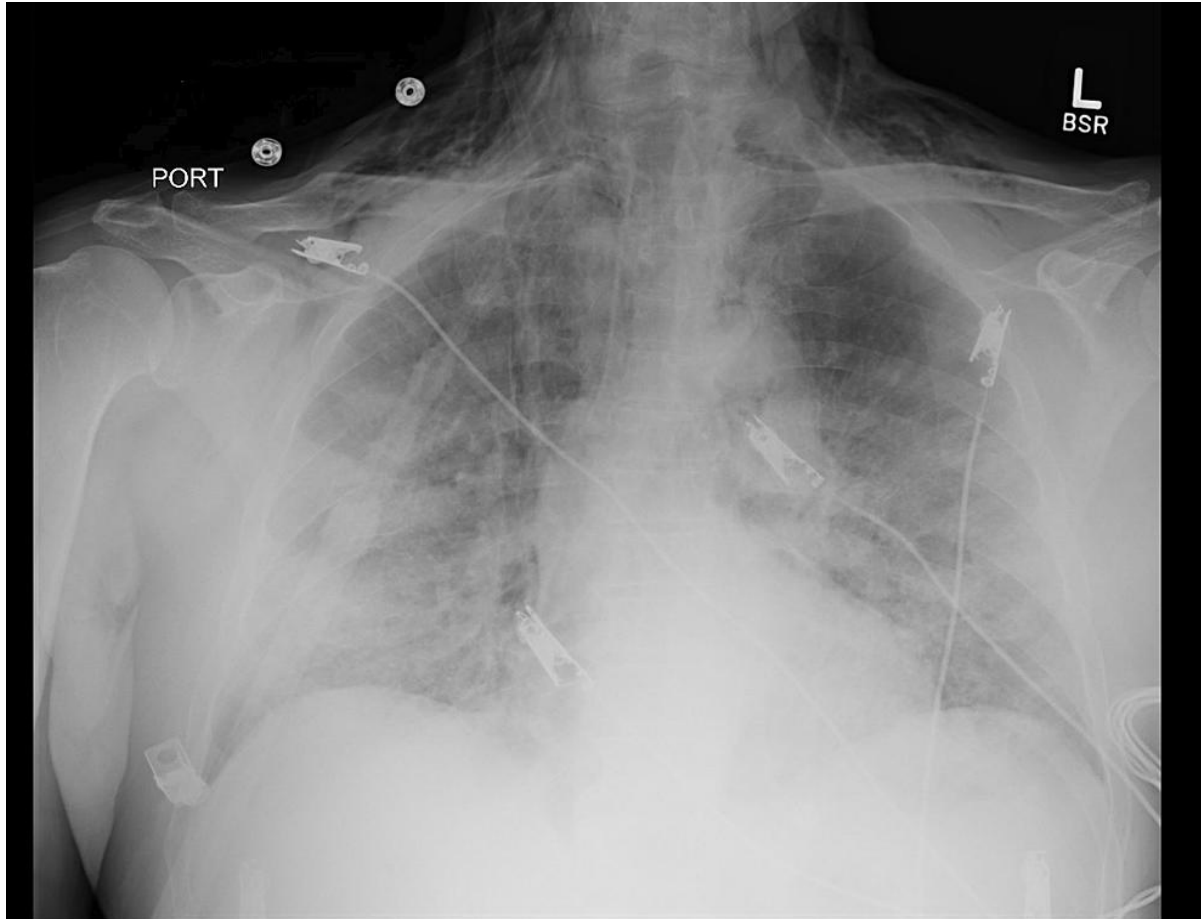
On a follow-up CXR on day 3 of admission, SE was seen along the lower neck and upper lung apices with no pneumothorax while on HFNC 40 L/minute and 100% O₂.

The patient did not require any interventions. The patient had ARDS from SARS-CoV-2 pneumonia and was intubated on day 5 of admission. He eventually developed septic shock and acute renal failure. The patient succumbed on day 14 of hospitalization.¹⁷

Till now, there is no any exact information in the literature to assume the possibility of allergic reaction or any other inflammatory reaction due to handling of Oral Candidiasis With Subcutaneous Emphyema and SARI. The cause and effects of the disease have not been identified, it is limited to isolated case reports only. Most of the reports are related to this topic are based on patients undergoing Covid 19 patients. Different studies on Covid 19 were reported . Few of the related studies were reviewed .¹⁸



(Figure No :1)



(Figure No :- 2)

Conclusion:

A case of Oral Candidiasis With Subcutaneous Emphysema and SARI secondary to post covid - 19, it's is very important to diagnosed in early stage so that the patient will not be develop complications from the disease. It is also very important to take preventive measure like avoid going to dusty area or construction site, wear N95 mask, avoid activities that has direct contact with dust or soil, clean oxygen mask, humidifier. My patient show great improvement after getting the treatment and the treatment was still going on discharge.¹⁹

In this study, we mainly focus on expert medical management and excellent nursing care helped in managing the complicated case very nicely. All the patient response was positive for conservative and nursing management and after treatment the patient was discharged without any complications and satisfaction with full recovery.²⁰

Ethical approval

Not applicable

Conflict of Interest

The Author declares that there are no conflicts of interest.

Funding

Not applicable

References:-

1. Centers for Disease Control and Prevention. Centers for Disease Control and Prevention Coronavirus disease 2019 (COVID-19) 2020.
2. Wu J, Wu X, Zeng W, Guo D, Fang Z, Chen L, Huang H, Li C. Chest CT findings in patients with coronavirus disease 2019 and its relationship with clinical features. *Investigative radiology*. 2020 May;55(5):257.
3. Kukuruzza K, Aboeed A. Subcutaneous Emphysema.[Updated 2019 May 12]. StatPearls [Internet]. Treasure Island (FL): StatPearls Publishing. 2020.
4. Chen N, Zhou M, Dong X, Qu J, Gong F, Han Y, Qiu Y, Wang J, Liu Y, Wei Y, Yu T. Epidemiological and clinical characteristics of 99 cases of 2019 novel coronavirus pneumonia in Wuhan, China: a descriptive study. *The lancet*. 2020 Feb 15;395(10223):507-13.
5. Ojha V, Mani A, Pandey NN, Sharma S, Kumar S. CT in coronavirus disease 2019 (COVID-19): a systematic review of chest CT findings in 4410 adult patients. *European radiology*. 2020 Nov;30:6129-38.
6. Byun CS, Choi JH, Hwang JJ, Kim DH, Cho HM, Seok JP. Vacuum-assisted closure therapy as an alternative treatment of subcutaneous emphysema. *The Korean journal of thoracic and cardiovascular surgery*. 2013 Oct;46(5):383. Hsu CW, Sun SF: Iatrogenic pneumothorax related to mechanical ventilation.
7. Riad A, Gomaa E, Hockova B, Klugar M. Oral candidiasis of COVID- 19 patients: Case report and review of evidence. *Journal of Cosmetic Dermatology*. 2021 Jun;20(6):1580-4.
8. Verma V, Talwar D, Kumar S, Acharya S, Verma A. Oral candidiasis as rare complication of COVID-19: A case series. *MEDICAL SCIENCE*. 2021 Jun;25(112):1397–401.
9. Shah D, Talwar D, Kumar S, Acharya S, Dubey A. Mucormycosis as a complication of LOIN G COVID: A case series. *MEDICAL SCIENCE*. 2021 Jun;25(112):1331–7.
10. Hapat S, Wadekar A, Goyal A, Shukla S, Acharya S, Kumar S. Garcin syndrome: A rare complication of rhinocerebral mucormycosis in post covid patient. *MEDICAL SCIENCE*. 2021 Jul;25(113):1788–94.
11. Khanna S, Talwar D, Kumar S, Acharya S, Hulkoti V, Madan S. Facial colliculus syndrome with inflammatory cranial neuritis in a patient with covid 19 with mucormycosis superinfection. *MEDICAL SCIENCE*. 2021 Jul;25(113):1517–21.
12. Patel M, Talwar D, Kumar S, Acharya S, Dubey A, Hulkoti V, et al. Cutaneous mucormycosis with maxillary sinus fistula as a presenting feature of COVID-19: A rare case report. *MEDICAL SCIENCE*. 2021 Jul;25(113):1507–12.

13. Dronamraju S, Nimkar S, Damke S, Agrawal S, Kumar S. Angioinvasion of anterior cerebral artery by rhinocerebral mucormycosis leading to intraparenchymal hemorrhage: A rare case report. *MEDICAL SCIENCE*. 2021 May;25(111):1088–91.
14. Kute, V., Guleria, S., Prakash, J., Shroff, S., Prasad, N., Agarwal, S., Varughese, S., Gupta, S., K Gokhale, A., Sahay, M., Sharma, A., Varma, P., Bhalla, A., Vardhan, H., Balwani, M., Dave, S., Bhadauria, D., Rathi, M., Agarwal, D., Shah, P., Ramesh, V., Garg, R., 2020b. NOTTO transplant specific guidelines with reference to COVID-19. *IndianJournalofNephrology*30,215–220.
https://doi.org/10.4103/ijn.IJN_299_20
15. Deshpande, Meghana Ajay, Sudhindra Baliga, Sapna Randad, Nilima Thosai, and Nilesh Rathi. “Probiotic Bacteriotherapy and Its Oral Health Perspective.” *JOURNAL OF EVOLUTION OF MEDICAL AND DENTAL SCIENCES-JEMDS* 9, no. 34 (August 24, 2020): 2479–83. <https://doi.org/10.14260/jemds/2020/538>.
16. Khubchandani, Sheetal Rameshlal, and Trupti Madhav Dahane. “Emerging Therapeutic Options for COVID-19.” *JOURNAL OF EVOLUTION OF MEDICAL AND DENTAL SCIENCES-JEMDS* 9, no. 41 (October 12, 2020): 3082–85. <https://doi.org/10.14260/jemds/2020/677>
17. Hande, Alka Harish, Archana Sonone, Roshni Porwar, Vidya Lohe, Suwarna Dangore, and Mrunal Meshram. “Evaluation of Oral Microbial Flora in Saliva of Patients of Oral Submucous Fibrosis.” *JOURNAL OF EVOLUTION OF MEDICAL AND DENTAL SCIENCES-JEMDS* 9, no. 7 (February 17, 2020): 409–12. <https://doi.org/10.14260/jemds/2020/93>.
18. Gondivkar, Shailesh M., Rahul R. Bhowate, Amol R. Gadabail, Sachin C. Sarode, and Rima S. Gondivkar. “Assessment of Oral Health-Related Quality of Life Instruments for Oral Submucous Fibrosis: A Systematic Review Using the Consensus-Based Standards for the Selection of Health Measurement Instruments (COSMIN) Checklist.” *ORAL ONCOLOGY* 93 (June 2019): 39–45. <https://doi.org/10.1016/j.oraloncology.2019.04.009>.
19. Gondivkar, Shailesh M., Rahul R. Bhowate, Amol R. Gadabail, Sachin C. Sarode, and Shankargouda Patil. “Quality of Life and Oral Potentially Malignant Disorders: Critical Appraisal and Prospects.” *WORLD JOURNAL OF CLINICAL ONCOLOGY* 9, no. 4 (August 13, 2018): 56–59. <https://doi.org/10.5306/wjco.v9.i4.56>.
20. Gupta, Bharti, Shekhar Gupta, Minal Chaudhary, A. Thirumal Raj, Kamran Habib Awan, and Shankargouda Patil. “Oral Candida Prevalence and Species Specificity in Leprosy.” *DM DISEASE-A-MONTH* 66, no. 7, SI (July 2020). <https://doi.org/10.1016/j.disamonth.2019.100920>