

A case report on Stoneman syndrome

Abstract

Fibrodysplasia ossificans **progressive** is a debilitating autosomal dominant disease **characterized** by postnatal progressive heterotopic ossification which connects things together and congenital deformities of the big toes.

Fibrodysplasia ossificans progressiva affects about one out of every two million newborns born world wide.

Almost

ninetypercent of people with fibrodysplasia ossificans progressiva are misdiagnosed and treated wrongly, resulting in ineffective treatments. Approximately 700 cases have been identified so far around the world. Clinical examinations, radiographic evaluations, and ACVR1 gene mutation testing are all considered confirmatory approaches for early illness diagnosis.

Case presentation:

We're reporting on the case of a 45-year-old man who was admitted in our facility.

He had clinical and radiological evidence of fibrodysplasia ossificans progressing, as well as multiple painful lumps on his back due to hard masses and rigidity of his shoulders, neck, and left hip. His left hip ossification was surgically removed, but he experienced an increased ossification reaction and early impairment as a result.

Conclusion:

Fibrodysplasia ossificans **progressive** is an uncommon and severe illness that, if misdiagnosed, can result in inappropriate surgical intervention and early paralysis with disastrous consequences.

We need to educate clinicians and patients' families concerning the disease, as well as its symptoms for early detection and how to prevent flare-ups, in order to improve quality of life.

Keywords:

Fibrodysplasia ossificans **progressive**; Myositis ossificans **progressive**; Stone man syndrome.

Introduction

FOP (fibrodysplasia (myositis) ossificans progressiva) is a rare hereditary condition characterised by progressive ossification of muscles and connective tissue, which causes pain and impairment.

1. With about 700 instances reported, the incidence is about 1 in 2 million.
2. There have been no reports of sexual, racial, or ethnic preferences.
3. FOP manifests itself as an autosomal dominant **characterized** with complete penetrance in the first decade of life
4. Shore et al. found the FOP gene in 2006.
5. Guy Patin first defined this condition as "stone man" in 1648, and it can lead to full ossification of the muscular system.
6. Trauma to a body part can lead to the formation of a painful inflammatory tumour that eventually calcifies.

Presentation of case :-

After all the investigation On the 14th of March 2021, a 45-year-old man was admitted to AVBRH Wardha with the major complaint of many painful lumps on his back due to hard **syndromed** stiffness of his shoulder, neck, and left hip for the past two months. The patient was diagnosed with Stoneman syndrome after a radiological test.

Present medical history :-

A 45-year-old man was admitted to Acharya Vinoba Bhave Hospital on the basis of a radiological assessment. The main complaint was many uncomfortable lumps on his neck due to hard masses on the 14th of March, 2021. Since 2 months, he has had stiffness in his shoulder, neck, and left hip, and after inspection, the patient was diagnosed with Stoneman syndrome. On admission, the patient is weak and idle.

Past medical history :-

Patient was diagnosed with Stoneman syndrome two months ago and was hospitalised to the hospital because of many painful lumps on his neck caused by hard masses and stiffness in his shoulder, neck, and left hip. He was admitted to the hospital for further management on a regular basis till then.

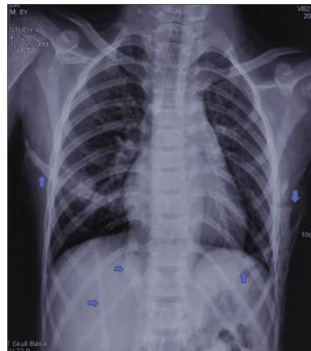
Family history :-

The family consists of four members.

My patient was diagnosed with Stoneman syndrome, and none of the other members of the family had any health issues, except for my patient, who was admitted to the hospital.

Clinical diagnosis

The clinic radiological syndrome FOP is named after. Congenital abnormality of the great toes, heterotrophic soft tissue ossification, and disease progression in a predictable temporal pattern are used to make the diagnosis. In roughly 79–90 percent of cases, bilateral great toe anomalies are present.



Pathological discussion:-

FOP is an extremely rare autosomal dominant connective tissue disorder also known as Munchmeyer disease or Stoneman syndrome. The great toes and thumbs are malformed, and there is greater heterotopic ossification of skeletal muscles and connective tissue with this syndrome. FOP is a relatively rare disease, with only one case in every 2 million individuals in the globe. Gender and race have no bearing on it.

Physical Examination :-

FOP is often diagnosed by the presence of two key criteria: great toe deformity and growing heterotopic endochondral ossification. Laboratory tests may demonstrate a significant rise in ESR during the “flare-ups.” The majority of FOP sufferers, on the other hand, do not live a life that is unnaturally short.

Medical Management:-

Currently, there is no cure for FOP. Exacerbations can be managed with corticosteroids, nonsteroidal anti-inflammatory drugs, and bisphosphonates, according to open studies. Cyclooxygenase 2 (COX2) inhibitors and leukotriene inhibitors are two other options. Unfortunately, there is no effective treatment for fibrodysplasia ossificans progressiva (FOP). Surgical excision of the excess bones is not a viable option because surgery frequently leads to more bone formation. These extra bones do not disappear on their own. FOP symptoms such as pain and inflammation can also be treated with medications. FOP is a progressive condition that normally gets worse with age, though the rate of new bone formation varies from person

to person and the disease's progression is mostly unexpected. Even if a person is born with FOP, extra bone may not form right away, and he or she may go months or years without a flare-up, which suggests new bone production.

Surgical Management:-

Surgical removal of the excess bones is not an option because surgery often leads to further bone development. These new bones don't just vanish.

Nursing management

- Bisphosphonates may be used to treat patients with metastatic bone disease to prevent or delay skeletal consequences such as pathologic fracture, radiation to the bone, and malignancy-related hypercalcemia.
- Nurses can help patients understand their treatment options and support or encourage the use of bisphosphonates throughout their treatment.
- Relevant effectiveness information on bisphosphonates and adverse events that may occur with bisphosphonate therapy were found in the literature in congress reports.
- Patients can benefit from bisphosphonates, and zoledronic acid is now licenced for the treatment of bone metastases caused by any solid tumour.
- Nurses can track pain scores, mobility changes, adverse events, and serum creatinine levels to improve care.
- A patient diary is a good tool for tracking these information.
- Before starting therapy, the nurse should fill out the diary at each patient visit and compare it to the baseline data.
- Patients should be educated on the need of proper hydration, oral cleanliness, the need for calcium and vitamin D supplements, and how to appropriately manage potential adverse effects.
- Bisphosphonates are good at reducing and delaying skeletal issues, while zoledronic acid has shown to be effective in preventing skeletal complications in a variety of solid malignancies and multiple myeloma patients.
- Nurses are critical in assisting patients in optimising bisphosphonate therapy and in encouraging them to continue treatment in order to maintain their functional independence.

Conclusion:-

- The patient was taken to Acharya Vinoba Bhave Rural Hospital with several tumors on his neck and soreness in his shoulder, neck, and left hip.
- Consent with knowledge
- The patient gave his informed consent and signed the case report before it was created.

Conflict of interest

Nil.

References :-

- 1)Al-Salmi I, Raniga S, Al Hadidi A. Fibrodysplasia ossificans progressiva-radiological findings: A case report. Oman Med J. 2014;29:368.
- 2)Deirmengian GK, Hebel NM, O'Connell M, Glaser DL, Shore EM, Kaplan FS. Proximal tibial osteochondromas in patients with fibrodysplasia ossificans progressiva. J Bone Joint Surg Am. 2008;90:366.
- 3)Hashemi J, Shahfarhat A, Beheshtian A. Fibrodysplasia ossificans progressiva: Report of a case and review of articles. Iran J Radiol. 2011;8:113.
- 4)Kaplan FS, Le Merrer M, Glaser DL, Pignolo RJ, Goldsby RE, Kitterman JA, et al. Fibrodysplasia ossificans progressiva. Best Pract Res Clin Rheumatol. 2008;22:191-205.
- 5)Kitterman JA, Kantanie S, Rocke DM, Kaplan FS. Iatrogenic harm caused by diagnostic errors in fibrodysplasia ossificans progressiva. Pediatrics. 2005;116:e654-61.
- 6)Sferopoulos NK, Kotakidou R, Petropoulos AS. Myositis ossificans in children: A review. Eur J Orthop Surg Traumatol. 2017;27:491-5
- 7) Kaplan FS, Zasloff MA, Kitterman JA, Shore EM, Hong CC, Rocke DM. Early mortality and cardiorespiratory failure in patients with fibrodysplasia ossificans progressiva. J Bone Joint Surg Am. 2010;92:686.
- 8) Takahashi M, Katagiri T, Furuya H, Hohjoh H. Disease-causing allele-specific silencing against the ALK2 mutants, R206H and G356D, in fibrodysplasia ossificans progressiva. Gene Ther. 2012;19:781-5.
- 9) Pignolo RJ, Suda RK, Kaplan FS. The fibrodysplasia ossificans progressiva lesion. Clin Rev Bone Miner Metab. 2005;3:195-200.
- 10) Nakashima Y, Haga N, Kitoh H, Kamizono J, Tozawa K, Katagiri T, et al. Deformity of the great toe in fibrodysplasia ossificans progressiva. J Orthop Sci. 2010;15:804-9.

11. Santoro AS, Cooper MG, Cheng A. Failed intubation and failed oxygenation in a child. *Anaesth Intensive Care*. 2012;40:1056–8.
12. Wadenya R, Fulcher M, Grunwald T, Nussbaum B, Grunwald Z. A description of two surgical and anesthetic management techniques used for a patient with fibrodysplasia ossificans progressiva. *Spec Care Dentist*. 2010;30:106–9.
13. Nussbaum BL, O’Hara I, Kaplan FS. Fibrodysplasia ossificans progressiva: Report of a case with guidelines for pediatric dental and anaesthetic management. *ASDC J Dent Child*. 1996;63:69
14. Stark WH, Krechel SW, Eggers GW., Jr Anesthesia in “stone man”: Myositis ossificans progressiva. *J Clin Anesth*. 1990;2:332–5.
15. Mitsdarffer B, Browder M. Comparison of the force required to perform endotracheal intubation on healthy adult patients utilizing the GlideScope® videolaryngoscope and Macintosh laryngoscope: A systematic review protocol. *JB I Database System Rev Implement Rep*. 2015;13:35–44.