

Surgical Management of Acute Sphenoid Sinusitis; Systematic Review Article:

Abstract:

Sphenoidal sinusitis is usually described as acute inflammation of the sphenoid sinuses - either one or both - (the two large cavities just behind the nose and between the eyes). The disease is relatively uncommon—comparatively, chronic sphenoid sinusitis is more common—and may be limited to the sphenoid sinus or, more commonly, may involve multiple sinuses or pansinusitis. Acute sphenoid sinusitis can lead to symptoms such as headaches, nausea, and even complications in the orbit. For low vision, early diagnosis and treatment is essential to preserve vision and life. This study aims to learn about surgical approaches to the treatment of acute sinusitis.

Keywords:

Paranasal sinuses - acute sphenoid sinuses - inflammation - surgical treatment - headache.

Introduction:

Sphenoid sinusitis is an uncommon infection that accounts for approximately 3% of all cases of acute sinusitis.[1] It is usually accompanied by pansinusitis, but, rarely, occurs alone. The sphenoid sinus is in close proximity to the cortical venous system, cranial nerves and meninges, so the infection may spread to these structures and the patient may present with complications. These include intractable headache, mono-ocular visual impairment and other cranial nerve disturbances, such as III, IV, VI, V1 and V2 involvement. Sphenoid sinusitis, also known as sphenoiditis, is caused by an acute inflammatory response in the sphenoid sinus.

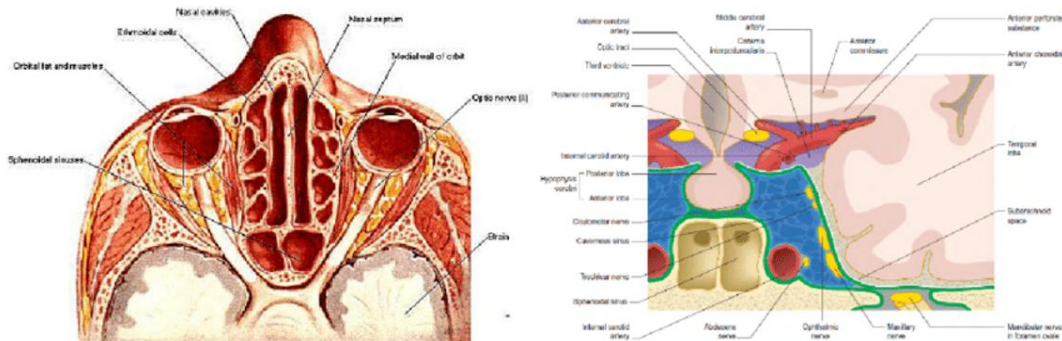
The disease is relatively uncommon—comparatively, chronic sphenoid sinusitis is more common—and may be limited to the sphenoid sinus or, more commonly, may involve multiple sinuses or pansinusitis. Early diagnosis and treatment are essential, because the disease can be rapidly progressive and complications arising from the relationship of the sphenoid sinus to vital vascular, neurologic, and optic structures can be devastating.[3]

The pathophysiology of sphenoid sinusitis involves blockage of the sinus ostia and impaired mucociliary clearance leading to stasis and secondary bacterial infection. Similarly, obstruction of the ostium of the paranasal sinus leads to the development of a mucocele, which may result from incomplete removal of the sinus mucosa. Isolated sphenoid sinus involvement is relatively uncommon and may occur due to inflammatory, neoplastic, fibro-osseous, traumatic or developmental disorders.[4]

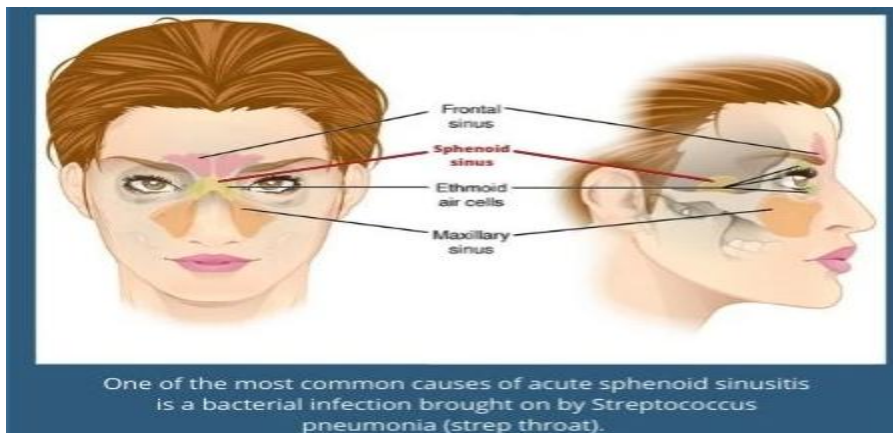
Among infections, bacteria (Gram-positive cocci) are the most common organisms in acute situations. There are many structures in close relation to sphenoid sinus that may be involved in complications secondary to sphenoid sinus disease. They include second through sixth cranial nerve, cavernous sinus, internal carotid artery, pituitary gland, sphenopalatine artery, adjacent dura mater, etc. [5]

The sphenoid sinus has been referred as the “neglected sinus” and is absent until the age of 1 year. It becomes visible through imaging and is clinically relevant between the ages of 5 and 15 [6]. The low incidence of isolated sphenoiditis compared with infection in other paranasal sinuses may be due to fewer drainage problems secondary to few mucous secreting cells along the pseudostratified ciliated epithelium lining of the sphenoid sinus. [7], When the inflammatory response is in the sphenoid sinus, the condition is known as sphenoid sinusitis or sphenoiditis.

The disease may be limited to the sphenoid sinus or, more commonly, involve multiple sinuses, The condition is classified as acute if the symptoms persist for 4 weeks or less[8]. Acute sphenoid sinusitis is an uncommon disease with a significant morbidity Isolated sphenoid sinusitis represents 1–2% of sinus infections [9]. The sphenoid sinus is at the center of important structures: the dura mater, the pituitary gland, the cavernous sinus, the internal carotid as well as cranial nerves II, III, IV, V and VI [10].



Sphenoid Sinus Anatomical Relations and their Implications in Endoscopic Sinus



Anatomy of sphenoid sinus:

The sphenoid sinus develops after birth. The pneumatization progresses at the age of 6 years and is completed by the ninth to 12th year.[12] The youngest known patient who was diagnosed and reported as having sphenoiditis was 10 years old.[11] The sphenoid sinus lies posteriorly the nasal cavity. The walls of this sinus adhere to the optic canal, dura mater, pituitary gland and cavernous sinus, which contain the internal carotid arteries, and the third, fourth, fifth and sixth cranial nerves. Infection of the cavity may directly spread to these structures due to the close proximity to the sinus cavity itself, often resulting in serious consequences.

The sphenoid sinus originates in the sphenoid bone at the center of the head. It arises not from an outpouching of the nasal cavity but from the nasal embryonic lining. The sinus reaches its full size by the late teenage years. The sphenoid sinus is variably pneumatized and may extend as far as the foramen magnum in some patients, The thickness of the walls of the sphenoid sinus is variable, with the anterosuperior wall and the roof of the sphenoid sinus (the planum sphenoidale) being the thinnest bones. The sphenoid sinus ostium is located on the anterosuperior surface of the sphenoid face, usually medial to the superior turbinate. The sphenoid sinus is supplied by the sphenopalatine artery, except for the planum sphenoidale, which is supplied by the posterior ethmoidal artery. Innervation of the sphenoid sinus comes from branches of the first and second divisions of the trigeminal nerve.[13]

Clinical symptoms:

Symptoms of sphenoid sinus disease are often vague and difficult to characterize. Despite the presence of several critical structures surrounding the sphenoid sinus, including the carotid artery, optic nerves, dura mater, and cranial nerves III to VI, symptoms related to these structures occur less frequently than nonspecific complaints, such as headache. The most common associated symptoms reported in the literature are headache and visual compromise, which may occur with both inflammatory and neoplastic processes. Acute sphenoid sinusitis can result in symptoms such as headache, characteristically creating deep or vertex pain, nausea, and even orbital complications. Orbital complication of acute rhinosinusitis typically affects children and young adults [14]. Visual disturbances are rare but serious. Anatomically, there is only a thin plate of bone that separates the optic nerve from the sphenoid sinuses, and hence sphenoid sinus inflammation can infringe the optic nerve and cause retrobulbar optic neuritis. Major clinical manifestations include decreased vision or loss. Furthermore, delayed diagnosis in all age groups is a threat to both vision and life [15]

Diagnostic methods:

Sphenoid sinus disease is frequently detected radiographically as an incidental finding in the evaluation of some other abnormality. Varied pathologic findings in the region, including vascular neoplasms, vascular malformations, and encephaloceles, can increase the risks of surgery in this region [16].

Nasal endoscopy should be performed as part of the examination of patients with primary sphenoid sinus disease. It is helpful in obtaining culture material and defining any extension into the nasal cavity. For patients presenting with CSF rhinorrhea, nasal endoscopy can be helpful in localizing the site of the leak to the sphenoid sinus. Endoscopy can also be helpful in identifying any anatomic obstructions that may need to be addressed at the time of surgery. However, even in cases where the lesion extends into the nasal cavity, minimal information may be obtained regarding the cause of the process. Given the possible devastating consequences, endoscopic biopsy should be avoided until the workup is complete and a treatment plan is in place [17].

Sinonasal Computer Tomographic (CT) is indicated in all cases of isolated sphenoid sinus disease. Computed tomographic imaging in the axial plane, in addition to standard coronal scanning, can provide important information. The axial plane clearly demonstrates the relationship of the optic nerves and internal carotid arteries to the sphenoid sinus walls. Computed tomography is helpful for defining the extent of the lesion and for identifying focal dehiscences within the sinus walls. Although frequently associated with malignant neoplastic processes, bony erosion may be associated with a wide variety of pathologic conditions. [18,19] In addition, lesions within the sphenoid sinus that originate from adjacent structures almost invariably demonstrate bony destruction.[18] Computed tomography is somewhat limited when compared with MR imaging, and certainly angiography, in its ability to determine the vascularity of a lesion. Biopsy in the case of hypervascular mass can be catastrophic, and death has been reported as a complication of diagnostic biopsy. [20].

Surgical Treatment:

Surgical intervention is indicated in patients with symptoms for longer than 3 months. In addition, the presence of foreign materials on MR imaging is another indication for surgery. Enlarged sphenoidotomy for drainage and removal of debris is usually performed. this concurs with previous reports on treatment of isolated sphenoid sinusitis [16, 21, 22].

Unlike the treatment of other chronic rhinosinusitis, the treatment of isolated sphenoid opacification is mainly surgical. Several surgical techniques have been described to address the sphenoid sinus with variable reoperation rates. However, only a few studies reporting the recurrence rates with long-term follow-ups are available in the literature. Sphenoid sinus can be opened with several techniques. The ostia can be directly approached. The sphenoid rostrum is approached between the middle and superior turbinate laterally and the septum medially. Unlike tumor surgery, resecting the

inferior portion of the middle turbinate is usually not necessary. The sphenoid ostium is then widely opened and enlarged so that the infective or inflammatory content inside the sphenoid sinus cavity can be completely removed. Full inspection of the sphenoid sinus cavity is then performed to assure complete removal [25].

Very few contraindications to urgent surgical decompression of the sphenoid sinus exist if a patient is having complications or is unresponsive to medical management. Unstable vital signs or excessive bleeding might require waiting until these problems can be temporized. Chronic medical conditions might preclude general anesthesia. If the sphenoid sinus is the underlying problem, however, decompression is beneficial [26].

Transseptal transsphenoidal approach: provides wider exposure of the entire anterior face of the sphenoid and allows the use of binocular vision. At our institution, the transseptal approach is most used for pituitary surgery, but it can be adapted for other processes involving the sphenoid sinus when necessary. It allows the use of both hands for dissection, which is especially helpful in the resection of vascular tumors or lesions and the repair of CSF leaks [27].

Transantral approach: this method has also been used to treat sphenoid disease. Make a sublabial canine fossa incision for this approach. Address any antral disease by opening the anterior maxillary sinus wall. Removing the nasoantral wall reveals the middle turbinate. Use the middle turbinate as a guide to the sphenoid ostium, which is superior and medial to the middle turbinate's posterior aspect. The anterior sphenoid wall should then be opened [28].

Intranasal approach: Decongest the nose as usual, then fracture the middle turbinate medially. Perform an ethmoidectomy, followed by lateralization of the middle turbinate's posterior attachment. Enter and enlarge the sphenoid ostium medially to the middle turbinate. To create a common cavity between the sphenoid sinus and the posterior ethmoid, remove the posterior ethmoid cells. Because an external incision is required, external sphenoidotomy is performed infrequently [27].

Endoscopic approach: Endoscopic transnasal sphenoidotomy is acknowledged as the gold standard for surgical treatment of chronic sphenoid rhinosinusitis. In comparison to external approaches, endoscopic surgery provides better visualization and thus allows for faster healing, better esthetic outcome, lower morbidity and higher success rate.[24]

Transethmoidal approach: should be performed when patients have pathology in ethmoid sinus or extensive tumor. A transethmoid approach may be considered in a narrow nose or if other sinuses are involved in the disease process or wider surgical exposure is required. A transethmoid approach may also be considered in patients with a complication of sphenoiditis to facilitate postoperative ventilation and debridement. For cases in which the ostium cannot be identified, the use of a reliable landmark is essential. Orbital walls are fixed anatomical landmarks used when the sphenoid sinus ostium is not clearly seen.[29] The level of orbital floor is always below the sphenoid roof, and this indicates the level of sphenoid ostium.[29] The medial orbital wall indicates the lateral

wall of the sphenoid sinus including the location of the optic nerve and the internal carotid artery. Traditionally, sphenoid sinus widening in an inferomedial fashion is widely suggested because it is safer when sphenoid face is resected away from vital structures. This may not be followed if the level of the sphenoid roof, optic nerve and internal carotid artery are clearly indicated by the inferior and medial orbital walls. Maximal opening of the sphenoid sinus can be achieved when it is widened superiorly and laterally.

Transnasal approach: this approach can be used if isolated sphenoid disease is present. Displace the middle turbinate laterally and move the endoscope along the septum until the superior turbinate is visible. Transect and remove the superior turbinate's superior aspect. Determine the location of the sphenoid ostium between the remnant and the septum. Enlarge the ostium inferiorly. After that, an endoscope can be inserted directly into the sphenoid sinus to determine the location of the carotid artery and optic nerve. The ostium can be expanded further once these structures have been identified. To reduce the likelihood of recurrent obstruction, a diameter of 5-10 mm is recommended [26].

Alternate approach to isolated sphenoid disease: Stankiewicz advocated fracturing the middle turbinate toward the septum as an alternative treatment for isolated sphenoid disease. Remove the tissue by making incisions in the anterior superior and posterior inferior portions of the middle turbinate. The basal lamella survives as a landmark. Measure the distance to the sphenoid ostium with a probe, then enter the sphenoid [29].

Conclusion:

Surgical approaches to isolated sphenoid lesions include the endoscopic transnasal, the endoscopic transethmoid, the transseptal, and the endoscopic pterygoid fossa. Each of these may be used in conjunction with an extracranial approach if necessary. In cases involving an inflammatory process, transnasal endoscopic sphenoidotomy using the superior turbinate as a key landmark has been reported to be safe and effective. The transnasal approach is most useful in patients with spacious noses; otherwise, partial middle turbinate resection may be required.

References:

- 1- Lew D, Southwick FS, Montgomery WW, Weber AL, Baker AS. Sphenoid sinusitis. A review of 30 cases. *N Engl J Med* 1983;309:1149–54. 10.1056/NEJM198311103091904.
- 2- Marmura MJ, Silberstein SD. Headaches caused by nasal and paranasal sinus disease. *Neurol Clin* 2014;32:507–23. 10.1016/j.ncl.2013.11.001.
- 3-Rami K Batniji, MD Private Practice, Batniji Facial Plastic Surgery,Surgical Treatment of Acute Sphenoid Sinusitis,Updated: 2021
- 4- Lawson W, Reino AJ. Isolated sphenoid sinus disease: an analysis of 132 cases. *Laryngoscope* 1997;107:1590–5. 10.1097/00005537-199712000-00003.
- 5- Fujii K, Chambers SM, Rhoton AL Jr. Neurovascular relationships of the sphenoid sinus. A microsurgical study. *J Neurosurg* 1979;50:31–9. 10.3171/jns.1979.50.1.0031 .
- 6- Marseglia GL, Pagella F, Licari A, Scaramuzza C, Marseglia A, Leone M, et al. Acute isolated sphenoid sinusitis in children. *Int J Pediatr Otorhinolaryngol*. 2006;70:2027–31.
- 7- Tan HK, Ong YK. Acute isolated sphenoid sinusitis. *Ann Acad Med Singapore*. 2004;33:656–9.
- 8- Brook I (2007) Acute and chronic bacterial sinusitis. *Infect Dis Clin North Am* 21:421–448.
- 9- Marcolini T.R., Safraider M.C., Socher J.A., Lucena G.O. Differential diagnosis and treatment of isolated pathologies of the sphenoid sinus: retrospective study of 46 cases. *Int. Arch. Otorhinolaryngol*. 2015;19(2):124–129.
- 10- Proetz A.W. The sphenoid sinus. *Br. Med. J*. 1948;2(4569):243–245.
- 11- Nour YA, Al-Madani A, El-Daly A, Gaafar A. Isolated sphenoid sinus pathology: spectrum of diagnostic and treatment modalities. *Auris Nasus Larynx*. 2008;35(4):500–508.
- 12- Som PM, Lawson W, Fatterpekar GM, Zinreich SJ. Embryology, anatomy, physiology, and imaging of the sinonasal cavities. In: Som PM, Curtin HD, editors. *Head and Neck Imaging*. 5th ed. St Louis: Elsevier Health Sciences; 2011. pp. 102–165.
- 13- Ameet Singh, Conner J Massey, Arlen D Meyers, Arlen D Meyers ,Paranasal Sinus Anatomy,Updated: Dec 08, 2017

- 14 - O. O. Sijuwola, A. A. Adeyemo, and A. A. Adeosun, "Orbital complications of rhinosinusitis," *Annals of Ibadan Postgraduate Medicine*, vol. 5, no. 1, pp. 6–8, 2011. View at.
- 15- D. A. Conrad and H. B. Jenson, "Management of acute bacterial rhinosinusitis," *Current Opinion in Pediatrics*, vol. 14, no. 1, pp. 86–90, 2002. View at
- 16- Sethi DS (1999) Isolated sphenoid lesions: diagnosis and management. *Otolaryngol Head Neck Surg* 120:730–736. doi:[10.1053/hn.1999.v120.a89436](https://doi.org/10.1053/hn.1999.v120.a89436)
- 17- Herman P, Lot G, Guichard JP, Marianowski R, Assayag M, Tran Ba Huy P (1998) Mucocele of the sphenoid sinus: a late complication of transsphenoidal pituitary surgery. *Ann Otol Rhinol Laryngol* 107:765–768
- 18- - Cakmak O, Shohet MR, Kern EB Isolated sphenoid sinus lesions. *Am J Rhinol*. 2000;14:13-19.
- 19- Lawson WR, Reino AJ Isolated sphenoid sinus disease: an analysis of 132 cases. *Laryngoscope*. 1997;107:1590-1595.
- 20- Hayden RH, Luna MG, Goepfert H Hemangiomas of the sphenoid sinus. *Otolaryngol Head Neck Surg*. 1980;88:136-138.
- 21- Batra PS, Citardi MJ, Lanza DC (2005) Isolated sphenoid sinusitis after transsphenoidal hypophysectomy. *Am J Rhinol* 19:185–189
- 22- Turgut S, Ozcan KM, Celikkanat S, Ozdem C (1997) Isolated sphenoid sinusitis. *Rhinology* 35:132–135
- 23- Nour YA, Al-Madani A, El-Daly A, Gaafar A. Isolated sphenoid sinus pathology: spectrum of diagnostic and treatment modalities. *Auris Nasus Larynx*. 2008;**35**(4):500–508.
- 24- Pagella F, Matti E, De Bernardi F, et al. Paranasal sinus fungus ball: diagnosis and management. *Mycoses*. 2007;**50**(6):451–456.
- 25- Stankiewicz JA. The endoscopic approach to the sphenoid sinus. *Laryngoscope*. 1989;**99**(2):218–221.
- 26- Smith TL, Toohill RJ, Loehrl TA Subtleties in endoscopic surgery of the sphenoid sinus. In: Wackym PA, Rice DH, Schaefer SD, eds. *Minimally Invasive Surgery of the Head, Neck and Cranial Base*. Philadelphia, Pa: Lippincott Williams & Wilkins; 2002:259-269.

27- Metson RG, Gliklich RE. Endoscopic treatment of sphenoid sinusitis. *Otolaryngol Head Neck Surg.* 1996;114:736-744.

28- Loehrl TA, Smith TL. Computer-guided endoscopic sinus surgery. *Curr Opin Otolaryngol Head Neck Surg.* 2001;9:53-56.

29- Wuttiwongsanon C, Chaowanapanja P, Harvey RJ, et al. The orbital floor is a surgical landmark for the Asian anterior skull base. *Am J Rhinol Allergy.* 2015;29(6):e216–e219.

UNDER PEER REVIEW