

CASE STUDY

MIXED GERM CELL TUMOUR OF OVARY WITH CHEMOTHERAPY SIDE EFFECT

ABSTRACT:

Introduction: Mixed germ cell tumour is a very rare type of aggressive cancer, consisting of more than one type of germ cell components. The most common component reported was dysgerminoma, followed by endodermal sinus tumour, teratoma, choriocarcinoma and embryonal carcinoma respectively. This study focuses on the combination of dysgerminoma and endodermal sinus tumour (yolk sac tumour) along with the hearing loss as the side effect of chemotherapy.

Clinical findings:

Pain in the lower abdomen (lump is visible and has occupied hypogastrium along with bilateral iliac region extending 2-3 cm above the umbilicus), backache, fever (100.6 °F). Later after the third chemo cycle, it was found that the patient has progressive mild hearing loss.

Diagnostic Evaluation: HB= 9.7gm%, TLC= 10300/cumm, PLT= 5,49 lakhs/cumm, CA 125= 909 U/ML.

Histopathology report: Ascitic fluid along with thirteen containers containing right ovarian mass, right ovary with mass, right fallopian tube, bowel deposits as well as residual nodules and pelvic deposits were sent of which, the reports indicated mixed germ cell tumour of the ovary.

Therapeutic Intervention: Packed red blood cells transfusion, Pre-chemo and post-chemo hydration, Pre-chemo and post-chemo drugs, BEP Chemotherapy (Bleomycin, Etoposide, Cisplatin).

Conclusion: My patient aged 11 years old female was admitted to Gynaecology Ward No – 16, AVBRH on 27/12/2020 for the first cycle of chemotherapy with the complaints of lower abdominal pain, backache and fever. The patient was diagnosed as the case of mixed germ cell tumour, further had mild hearing loss as the side effect of chemotherapy. The patient is on chemo and is advised for follow up care once a month.

Keywords: Chemotherapy, Choriocarcinoma, Dysgerminoma, Embryonal carcinoma, Endodermal sinus tumour, Mixed Germ Cell Tumour and Teratoma.

Introduction:

Germ cell tumours by name suggest that it is the tumours of the egg cell in females and sperm cells in males. Mixed germ cell tumour is termed so, because of its characteristics of involving at least more than one type of germ cell tumours. To date, the most common combination of mixed germ cells reported is dysgerminoma and endodermal sinus tumour¹, whereas the rarest counts embryonal carcinoma and immature teratoma². It is primarily found in children and adolescent.

Among ovarian cancer, it is reported to be the second most common type of tumours constituting about 15-20%; of which, about 3% are the malignant ones.³ Usually, the book picture depicts that mixed germ cell tumours have symptoms of abdominal pain, constipation, lump over lower abdomen or back, puberty is attained at a very young age and severe pain.⁴

Patient Identification:

A female child of 11 years from Pusad, Yavatmal was admitted to Gynaecology Ward No – 16, AVBRH on 27/12/2020 diagnosed as the case of mixed germ cell tumour on 04/01/2021. She weighs 30 Kgs with a height of 150 cms.

Family history:

My patient's family comprises four members. She was diagnosed to have mixed germ cell tumours with no abnormal genetic history from her parents. The parents had a non-consanguineous type of marriage. Except for the patient admitted to the hospital, other family members don't have any complaints regarding their health. The family belongs to a middle class family, hence the nursing interventions were framed accordingly, along with helping their healthcare expenses by connecting them with health schemes via hospital's social worker.

Past medical history:

My patient has a history of fever 15 days before the admission, which the patient's parents reported as typhoid (document not available for the diagnosis of typhoid) and treated it at home. Tumour board discussion was done on 30/12/2020 and later her histopathological

report confirmed to have mixed germ cell tumour on 04/01/2021. Till that duration, she was admitted to the hospital from time to time for the packed red blood cells transfusion.

Past interventions and outcome:

Abdominal pain being the chief complaint of the patient, was suspected to have right ovarian mass from ultrasonography report, which was later diagnosed as mixed germ cell tumour through the histopathological report on 04/01/2021. Also, the patient had a 9.7gm% haemoglobin level at the time of admission, for which 2 units of packed red blood cells was transfused in corresponding days, which was found effective as the Hb% was noted as 13.2 gm% on 31/12/2020 from 9.7 gm% on 27/12/2020.

Present medical history:

The patient was brought to AVBRH on 27 December 2020 by her parents with complaints of lower abdominal pain, backache and fever for which she was admitted to Gynaecology Ward No – 16. She was a case of **ovarian tumour** and her haemoglobin level at the time of admission was 9.7 gm%. The child was weak and did not attain menarche to date.

Physical examination:

It was found that the patient had right ovarian mass from ultrasonography, on thorough examination from head to foot, a visible lump was noted over the lower abdomen, on further palpation it was found to occupy the hypogastrium region and bilaterally iliac region extending 2-3cm above the umbilicus. The child is thin, weak and has dull look. She is well oriented with the date, time, place and is cooperative.

Diagnostic assessment:

Blood test: Hb – 9.7gm%, TLC= 10300/cu mm, PLT= 5,49 lakhs/cu mm. **Tumour markers:** AFP= 520, CA 125= 909 U/ML. **Peripheral Smear:** RBCs - Normocytic mildly hypochromic RBCs seen. Platelets - Increased on smear. APC- 5,49,000 cells/mm³ as per cell counter. No haemoparasite seen.

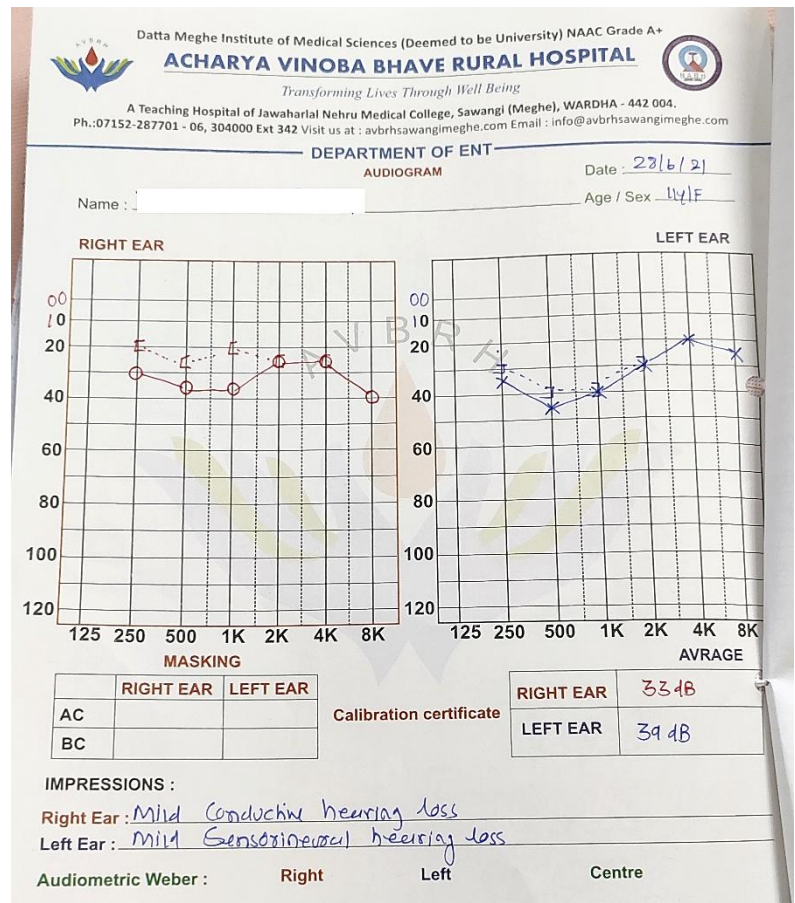
Radiology report: There were evidences of –

1. Free fluid in abdomen and pelvis.
2. Minimal right sided pleural effusion.

3. Large irregular nodular soft tissue mass lesion noted in the right sub-diaphragmatic space, taking minimal vascularity of size 5.8 cm × 3.4 cm, causing compression and infiltration of underlying liver parenchyma.
4. Large irregular heterogenous solid-cystic mass seen in the left adnexa of size 5.1 cm × 4 cm extending and invading the left lateral border of uterus (symptoms of neoplastic origin).
5. Multiple well defined homogenous nodular deposits (symptoms of metastatic deposits) noted in the omentum.

Histopathology report: Ascitic fluid along with thirteen containers containing right ovarian mass, right ovary with mass, right fallopian tube, bowel deposits as well as residual nodules and pelvic deposits were sent of which, the reports indicated features suggestive of mixed germ cell tumour of the ovary.

Audiogram report: Right ear: Mild conductive hearing loss, Left ear: Mild sensorineural hearing loss, as depicted in the Picture 1.



Picture 1: Audiogram report

Management:

Unlike other cases, surgeries were done before as an emergency, to remove the ascitic fluid. Hence, chemotherapy was followed after the surgical management. Also, the patient didn't receive radiation therapy.

Surgical management: The patient underwent her first surgery ever on 30/12/2021 as an, after consulting responsible physicians and paediatricians. The patient was prepared with antibiotic coverage for Pigtail procedure in order to drain around 500ml of ascitic fluid from peritoneal cavity. **Intra-operative notes:** During the procedure a yellow-white lump mass of

irregular, friable with solid consistency, and haemorrhagic yet necrotic areas were seen and palpated. Hence, further surgeries were carried out on need based. As a result, the patient had exploratory laparotomy with right ovarian mass removal with right sided salpingectomy with infra-colic omentectomy with partial supra-colic omentectomy with peritoneal biopsy. Meanwhile, the required samples were collected in 13 containers according to the protocol and was sent for histopathological examination.

Medical management: Packed red blood cells transfusion, Pre-chemo and post-chemo hydration (Inj. NS, Inj. KCl 5ml in NS and Inj. MgSO₄ 2ml in NS), Pre-chemo and post-chemo drugs (Inj. Avil, Inj. Dexamethasone, Inj. Hydrocortisone and Inj. Ondansetron), BEP Chemotherapy (Bleomycin 15 mg IV on Day 1 and Day 8; Etoposide 100 mg/m² Day 1 to Day 5 and; Cisplatin 20 mg/m² Day 1 to Day 5) in the stat, Tab. Limcee 500mg and tab. Zincovit OD x 9 days, Syrup Multivitamin 2tsp BD x 9 days. **Chemotherapy:** The first cycle of chemotherapy was given from 03/02/2021 to 10/02/2021. The second cycle of chemotherapy was administered from 03/04/2021 to 10/04/2021. The third cycle of chemotherapy was administered from 20/05/2021 to 27/05/2021 and the patient had her fourth cycle of chemo from 29/06/2021 to 06/07/2021. **Side-effects of chemotherapy:** As chemotherapy has numerous side effects, of which hearing loss is accounted to be rare but inevitable due to long term use chemotherapy drugs, especially in minor age group population.⁵ After the third cycle of chemotherapy, it was found that the patient had the difficulty to hear distant things or person. Hence as per the suspicion, Rinne and Weber tests was performed, of which the report is depicted in picture 1. It was suggestive that the precipitating amount of chemotherapy, especially in such a young age may be the causative factor.⁵

Nursing management: This case belonged to medical, surgical, oncology, gynaecology as well as paediatrics concerned department, therefore nursing care played a vital role in every aspect, which is framed below accordingly:

PRE-OPERATIVE:

A. Nursing diagnosis: Pain in abdomen related to gross ascites secondary related to lump in the abdomen.

Nursing Interventions	Rationale
1. Assess the level of pain then record and report it to doctor.	1. To know the level of pain and frame further interventions.
2. Consult and co-ordinate with health care team members of various department included in the case.	2. To confirm the final diagnosis with staging and prepare nursing diagnosis to provide effective care.
3. Administer the analgesics as prescribed by the doctors.	3. To provide symptomatic pain relief.

B. Nursing diagnosis: Low nutritional pattern less than body requirement related to pain perception secondary related to regurgitation.

Nursing Intervention	Rationale
1. Monitor the weight of the patient daily.	1. To collect the baseline data about weight loss with the pain perception.
2. Check the physician's order and administer antiemetic and supplementary medicines.	2. To avoid regurgitation and enhance the health of the patient.
3. Consult the dietician and provide a diet pattern to the patient's family to follow.	3. To provide the patient with a healthy diet in order to cope up with daily activities.

C. Nursing diagnosis: Fear and anxiety related to hospitalization secondary related to the consequences of surgical procedures.

Nursing Intervention	Rationale
1. Maintain rapport with the patient and her family.	1. To induce comfort so that they can share about the queries and problems.
2. Provide information about the disease condition and its management including treatment modalities.	2. To increase knowledge of the patient and family members regarding every aspect of the disease condition.
3. Counsel the patient regarding the mentioned fears and anxiety.	3. To prepare the patient for the surgery.

POST OPERATIVE:

A. Nursing diagnosis: Acute pain in abdomen related to surgical incision secondary related to insertion of pigtail catheter.

Nursing Intervention	Rationale
1. Obtain the level of pain on pain-scale	1. To prepare the post-operative nursing intervention on pain.
2. Provide non pharmacological therapies as well to the patient; like music therapy, massages or assigning them daily tasks like drawing pictures.	2. To minimize the level of pain by distracting the patient from pain perception.
3. Provide the patient with a position in which she feels comfortable and won't cause complications to the surgical site.	3. To induce comfort and rest.
4. Administer the prescribed medications by the physicians.	4. To help the patient cure fast and also to reduce pain.

B. Nursing diagnosis: Risk of infection related to surgical incision and catheter insertion secondary related to low immunity.

Nursing Intervention	Rationale
1. Assess the surgical site on every shift further record and report if any pus formation is seen.	1. To know the wound healing and to check for presence of any infection.
2. Provide Foley's catheter care to the patient.	2. To prevent urinary tract infection.
3. Check the physician's note and apply new dressing on the sutured site on day 5 and day 8 after the surgery.	3. To prevent infection on the incision site and promote healing.

C. Nursing diagnosis: Activity intolerance related to surgical procedures secondary to pain perception.

Nursing Intervention	Rationale
1. Encourage the patient to do drink plenty of water.	1. To hydrate the body of the patient.
2. Advice the patient to perform deep breathing and leg exercises like early walking.	2. To reduce the chances of blood clots and infections in the chest.
3.Explain the need of family assisted care to the family members.	3.To carry out day to day activity and avoid any further injuries.

Follow-up care:

The patient is advised to visit the hospital on Thursdays in case of emergency.

She has been prescribed to take:

- Tablet Pantoprazole 40 mg OD x 7 days,
- Tablet Paracetamol 500 mg BD x 7 days (SOS),
- Tablet Chymoral forte BD x 1 month,
- Tablet Limcee OD x 1 month,
- Protein powder 2tbsp BD x 1 month.

The patient was also advised:

1. To take adequate rest to avoid exhaustion,
2. To drink plenty of oral fluids to keep the body hydrated,
3. To eat high iron and fibre rich diet to enhance the haemoglobin level and immunity of the body,
4. To perform deep breathing and leg exercises or early walking as it reduces the probability of blood clots and infections in the chest.

Follow-up investigations:

Tumor markers: AFP = 466, CA 125 = 153 U/ML, **Peripheral Smear:** RBCs - Predominantly Normocytic Normochromic with moderate anisopoikilocytosis showing few pencil cells. Platelets – Seen in clumps. No Haemoparasite seen

Discussion:

Mixed germ cell tumours are an aggressive type of cancer because the TNM staging of my patient, noted on 04/01/2021 was pT2CpNXpMX (Stage IIC) but later it was found to be pT3CpNXpM1 (Stage IV), also it affects the germ cell, which is important to produce gametes. Hence, it calls attention for early diagnosis to cure completely and to preserve fertility.

A study on “Malignant Mixed Ovarian Germ Cell Tumour with Embryonal Component” about a 19 years old female, stated that Chemotherapy and fertility sparing surgical management can allow the female to bear child after regaining the normal functions of the ovaries.⁶

According to a published article of 2010 regarding clinical and pathological presentation and survival outcomes of malignant ovarian germ cell tumours concluded that, even after diagnosing the case on the basis of pathological and physiological reports, the treatment including chemotherapy, surgical management and radiation therapy, was effective to limited cases only. In addition to that, the fertility rate got decreased or diminished.⁷

Also, many studies have proven that Cisplatin has ototoxic effect in children and is accompanied with late onset hearing loss⁸, when the prescribed dose exceeds over $360\text{mg}/\text{m}^2$.⁹

The radiation therapy does not only impair the growth of uterus but also increases the chances of depletion of the ovarian follicles. Contrastingly, salpingo-oophorectomy reduces the risks of developing ovarian cancer among women aged 35 to 40 years by 85% - 95%^{10, 11, 12, 13, 14} and it is usually recommended to perform after the mother is done with childbearing^{14,15}, whereas, my patient is underaged, i.e., didn't even attain menarche and has been diagnosed with mild hearing loss of both ears being the side effect of chemotherapy. Thereby, claiming to be an exceptional case.

Overall, the above discussed studies provide a contradictory conclusion regarding the effect of treatment and recovery rates. Hence, the care of the patient should not only be limited to the medical or surgical management, but should also focus on psychological aspects of the patient as well as their caregiver. The willpower of the patient plays a major role in the recovery, therefore non-pharmacological therapies should also be prioritized by providing a positive and motivating atmosphere to the patient. It is also observed that cancer rehabilitation helps the patients to interact with people of similar diagnosis, which makes them enthusiastic and determined to live a quality life.

Conclusion:

A female patient aged 11 years old from Pusad, Yavatmal was admitted to Gynaecology Ward No – 16, AVBRH on 27 December 2020 with chief complaints of lower abdominal pain, backache and fever from 3 days. She is diagnosed as the case of mixed germ cell tumour through the histopathological report on 04/01/2021. As soon as the patient was admitted to AVBR hospital, all the required investigations were done and appropriate treatments were started. The patient is on symptomatic treatment and underwent surgeries as well, which is helping her to relieve the complaints. Since then, she has been readmitted for chemo cycles. Recently, the patient had been diagnosed with mild hearing loss associated with chemotherapy as side effect. The patient and her family underwent psychological stress, which was resolved to an extent by being an active listener and providing proper counselling.

Ethical Clearance: There were no ethical issues, as the patient informed consent was obtained from her parents.

Source of Funding: Self.

Conflict of Interest: Nil.

References:

1. Tiwary B, Sinha H, Pandey V. Malignant mixed germ cell tumour of ovary: a rare case report. *Int J Reprod Contracept Obstet Gynecol.* 2015;4(2):511-3.
2. Koshy M, Vijayanathan A, Vadiveloo V. Malignant ovarian mixed germ cell tumour: a rare combination. *Biomedical imaging and intervention journal.* 2005 Oct;1(2).
3. D.C. Dutta's Textbook of Gynaecology. 6th Edition. Edited by Hiralal Konar. Page: 365-367.
4. Germ Cell Tumors (Solid Tumor) - St. Jude Children's Research Hospital.
5. Sawamura Y, Ikeda J, Shirato H, Tada M, Abe H. Germ cell tumours of the central nervous system: treatment consideration based on 111 cases and their long-term clinical outcomes. *European journal of cancer.* 1998 Jan 1;34(1):104-10.
6. Moniaga NC, Randall LM. Malignant mixed ovarian germ cell tumor with embryonal component. *Journal of pediatric and adolescent gynecology.* 2011 Feb 1;24(1):e1-3.
7. Tangjitgamol S, Hanprasertpong J, Manusirivithaya S, Wootipoom V, Thavaramara T, Buhachat R. Malignant ovarian germ cell tumors: clinico-pathological presentation and survival outcomes. *ActaobstetriciaetgynecologicaScandinavica.* 2010 Feb;89(2):182-9.
8. Kolinsky DC, Hayashi SS, Karzon R, Mao J, Hayashi RJ. Late onset hearing loss: a significant complication of cancer survivors treated with Cisplatin containing

- chemotherapy regimens. *Journal of pediatric hematology/oncology*. 2010 Mar 1;32(2):119-23.
9. Schultz C, Goffi-Gomez MV, Liberman PH, Carvalho AL. Report on hearing loss in oncology. *Brazilian journal of otorhinolaryngology*. 2009;75:634-41.
 10. Rebbeck TR, Lynch HT, Neuhausen SL, et al. Prophylactic oophorec-tomy in carriers of BRCA1 or BRCA2 mutations. *N Engl J Med*. 2002;346:1616–1622.
 11. Kauff ND, Satagopan JM, Robson ME, et al. Risk-reducing salpingo-oophorectomy in women with a BRCA1 or BRCA2 mutation. *N Engl J Med*. 2002;346:1609–1615.
 12. Rutter JL, Wacholder S, Chetrit A, et al. Gynecologic surgeries and risk of ovarian cancer in women with BRCA1 and BRCA2 Ashkenazi founder mutations: an Israeli population-based case-control study. *J Natl Cancer Inst*. 2003;95:1072–1078.
 13. Domchek SM, Friebel TM, Neuhausen SL, et al. Mortality after bilateral salpingo-oophorectomy in BRCA1 and BRCA2 mutation carriers: a prospective cohort study. *Lancet Oncol*. 2006;7:223–229.
 14. Yarbro CH, Wujcik D, Gobel BH. *Cancer nursing: Principles and practice: Principles and practice*. Jones & Bartlett Publishers; 2010 Apr 21.
 15. National Comprehensive Cancer Network. 2008. http://www.nccn.org/professionals/physician_gls/PDF/genetics_screening.pdf. Accessed on February 2, 2009.