

## Original Research Article

### ASSOCIATION BETWEEN ENDOSCOPIC FINDINGS VS. SEROLOGY FINDINGS OF PATIENTS WITH SUSPECTED CELIAC DISEASE

#### ABSTRACT

**OBJECTIVE:** To determine the association between endoscopic findings vs. serology findings of patients with suspected celiac disease

**METHODS:** All the suspected cases (based on their clinical manifestations) of celiac disease were initially recruited having age >14 years and <40 years of both gender. Patients who do not willing to participate, patients already taking gluten diet for more than 3 months, patients with other causes of chronic diarrhea and alternate diagnosis like thyrotoxicosis, whipple's disease, giardiasis, patients with drug induced diarrhea, patients in whom we cannot perform endoscopy, pregnant women, and patients already diagnosed cases of celiac disease were excluded from this study. Celiac disease was confirmed based on positive anti-tTG antibodies. Endoscopic evaluation of duodenum was performed in all positive cases.

**RESULTS:** A total of 50 patients were recruited for final analysis. **Diagnostic accuracy of endoscopy was 34.6%**. Young population (31.14±6.07 years) with females predominance (72%, n=36) were more common than males. The most common symptoms were presence of chronic diarrhea (74%, n=37) followed by abdominal pain (52%, n=26), nausea & vomiting (34%, n=17), and least common was presence of constipation (2%, n=1). On endoscopic evaluation, out 50 positive anti-tTG antibodies cases, 24 had normal

mucosa while partial villous atrophy observed in 15 (30%) cases and total villous atrophy observed in 11 cases (22%).

**CONCLUSIONS:** Celiac disease is more prevalent in young females and patients usually presents with history of chronic diarrhea. Anti-tTG antibodies have more diagnostic value than duodenal endoscopy. Villous atrophy was found in more than 50% of the patients who were diagnosed with celiac disease.

**KEYWORDS:** Celiac disease, serology and endoscopic evaluation, adults, Pakistan

## **INTRODUCTION:**

Celiac disease is a rare autoimmune disorder which primarily affects mucosa of the small intestine in genetically predisposed individuals by causing inflammation the eventually leads to the development of intestinal villous atrophy. Patients with this disease have intolerance to gluten, the protein fraction found in wheat, barley and rye (1, 2).

The removal of gluten from the diet provides clinical and histological improvement, while its reintroduction results in recurrence of the disease. This disease is most commonly found in first and second degree relatives and risk of transfer ranges from 5% to 15%. The overall burden of this disease is 1% globally and among them 90% of the patients are unaware of their disease and remain undiagnosed throughout their life. In Pakistan, there are certain clinical studies conducted on clinical manifestations, complications, and management of this disease but unfortunately there is no single study conducted regarding its true burden in our region (3-5).

Adult celiac disease may present with classic clinical features including weight loss, diarrhea, and malabsorption of nutrients. However, there are reports of an increasing trend towards silent or subclinical

presentations i.e. presentation with subtle symptoms not clearly related to gastrointestinal system that is why screening of high risk population is done by serology testing with IgA anti-tissue transglutaminase antibody which is a single preferred test having a high sensitivity (85%) and specificity (92%) (6). However, duodenal biopsy is the gold standard investigation even if serology is negative, graded according to the modified Marsh classification with histological findings of villous atrophy, hyperplasia of crypts, and intraepithelial lymphocytosis (7, 8).

In diagnosing celiac disease still there are few challenges like interpretation of serologic tests, who and how to screen and is there any requirement of endoscopy, duodenal biopsy and histological investigation or not. Although IgA anti- tTG is mostly done because of the cost effectiveness and readily available. A number of studies shows that IgA anti- tTG is positively related with severe intestinal damage but questions arise that whether to do or not, biopsy and histology of those patients who present with positive serology reports (9).

Local studies in Pakistan lack the association between anti-tTG antibody titers and histological changes. Hence, we have decided to do a study will aim the association between anti-tTG antibody titers with the histological changes in duodenal biopsies.

#### **PATIENTS & METHODS:**

This clinical case series was conducted through a non-probability convenient sampling technique in the Department of General Medicine and Unit of Endoscopy of the Rawal Institute of Health Sciences (RIHS), Islamabad after the approval from the ethical committee of the hospital. All the suspected patients for celiac disease having age more than 14 years and less than 40 years of both genders with positive anti-tTG antibodies were included for this study. Patients who do not willing to participate, patients already taking gluten diet for more than 3 months, patients with other causes of chronic diarrhea and alternate diagnosis like thyrotoxicosis, whipple's disease, giardiasis, patients with drug induced diarrhea, patients in whom we

cannot perform endoscopy, pregnant women, and patients who already diagnosed cases of celiac disease were excluded from this study.

Confirmation of celiac disease was done based on the clinical manifestations and positive anti-tTG antibodies. Initially 117 suspected patients of celiac disease were scrutinized and informed consent was taken from them before commencement of the study. Among them, 67 patients did not meet the inclusion criteria and hence excluded from the study. A total of 50 patients were included for final analysis those who were anti-tTG antibodies positive.

Those patients who positive for anti-tTG antibodies were further evaluated through esophagogastroduodenoscopy (EGD). Examination of duodenum through endoscope was performed by the same researcher who had at least 5 years of experience in performing such procedures. Water-immersion technique and magnification was used to examine the duodenum in detail with possible changes related to celiac disease. The changes related to celiac disease were then categorized into three categories: (a) normal mucosa (b) partial villous atrophy (c) total villous atrophy. Duodenal atrophy findings further categorized into four sub-categorize (a) reduction or absence of duodenal folds, (b) scalloping of folds, (c) visible submucosal vessels, (d) mosaic pattern, and (e) mucosal fissures, crevices, or grooves.

Statistical analysis was performed using SPSS software, version 21.0 for data entry and analysis. Initially, baseline and clinical variables computed for descriptive analysis and percentage of positive anti-tTG antibodies were evaluated from suspected cases then these variables further evaluated to determine the common clinical manifestations related to celiac disease through endoscope.

## **RESULTS:**

A total of 50 patients with celiac disease were finally analysed who were positive for anti-tTG antibodies. Mean and SD of patients was  $31.14 \pm 6.07$  years with age ranging between 14 years to 45 years. Almost one third among them were females (72%, n=36). Half of the patients had normal BMI (50%, n=25) with mean and SD was  $23.08 \pm 8.26$  kg/m<sup>2</sup> while 32% of the patients were underweight. Table no. 1.

Table no. 2 shows common clinical manifestations observed in patient who were positive for anti-tTG antibodies. The most common symptoms were presence of chronic diarrhea (74%, n=37) followed by abdominal pain (52%, n=26), nausea & vomiting (34%, n=17), and least common was presence of constipation (2%, n=1).

**Diagnostic accuracy endoscopy was 34.6%.** All the positive anti-tTG antibodies patients were underwent duodenal endoscopic evaluation with the water-immersion technique and magnification showed a) normal duodenal mucosa in 24 cases (48%), b) partial villous atrophy in 15 (30%), c) total villous atrophy in 11 cases (22%). Further evaluation of signs of villous atrophy on endoscopy of 26 patients was a) visible submucosal vessels in 20 cases (76.92%), b) reduction or absence of mucosal folds in 17 cases (65.38%), c) scalloping folds in 17 cases (65.38%), d) mosaic pattern in 12 cases (46.15%), and mucosal fissures in 10 cases (38.46%) Figure no. 1 and Table no. 3.

## **DISCUSSION:**

Celiac disease is a permanent disorder to gluten intolerance and particularly damages mucosa of small intestine by an autoimmune mechanism in persons who are genetically susceptible to this disease. This disease has no age limitations and can occur at any age but higher prevalence observed in children and in young age group population. In our study, the most of the patients presented and diagnosed at young age ( $31.14 \pm 6.07$  years). A Pakistani study conducted by Abbas Z et al. (10) also observed same age group at the time of celiac disease diagnosis. While, most of the national and international studies are in contrast with

our study in which the most common age group was less than 30 years or more than 60 years at the time of diagnosis (11-13). The difference of age in our study from other studies could be due to late presentation and diagnosis of age group less than 30 years. Most of the patients left undiagnosed or diagnosed late due to non-specific gastrointestinal complain such as chronic diarrhea, abdominal pain, and bloating (14). Also, data is well established that autoimmune diseases are more common in females hence celiac disease is also more common in women with a female to male ratio of 3:1. The difference in male to female ratio could be different in other studies but both national and international studies have observed common occurrence of this disease in females (15-18).

The clinical manifestations of celiac disease widely depend upon the age. Adults with celiac disease diagnose late due to their non-specific symptoms. As celiac disease affects small intestine that is why most of the patients presents with symptoms related to gastrointestinal tract. Therefore, higher prevalence of chronic diarrhea was observed in our study (74%) at the time of their presentation. A study conducted by Barker JM and colleagues (19) also observed same findings but the percentage is less (50%) than ours (74%). Besides chronic diarrhea, iron deficiency anemia is also common in patients with celiac disease but its frequency is varied widely across the world. In a study conducted by Jones S (20) has observed iron deficiency anemia was the most common clinical presentation and found in 68% of the patients had iron deficiency anemia at the time of diagnosis. However, our study's findings are in contrast to the previously published study and only 18% had iron deficiency anemia. These differences could be because of age related and severity of disease related such as in severe forms of celiac disease the frequency of iron deficiency anemia and chronic diarrhea would be more common as compare to less severe forms.

Confirmation of suspected celiac disease is based on two commonly used methods i) serological (presence of anti-tTG antibodies) and ii) endoscopic findings. Overall sensitivity and specificity of serological test is

more than endoscopic evaluation of the duodenum, 93.2% and 96.5% vs. 89% and 95%, respectively (21). Similarly, same accuracy was observed in our study. That is why, all the suspected patients with celiac disease should be evaluated initially with serology testing with some exceptions such as those patients who are not on gluten free diet then these patients should undergo endoscopic evaluation for celiac disease (22). During endoscopic evaluation of celiac disease patients, most of them had normal duodenal mucosa in our study (48%) while 52% had villous atrophy. The same findings are observed in previously conducted studies (23-25). Therefore, invasive procedures (small intestine endoscopy) should be reserved for those patients who are positive for anti-tTG antibodies or limitations in performing anti-tTG antibodies.

Besides major observations, our study has certain limitations which should be encountered in future studies. First, the sample size of our study is small and the sample is collected from a single center. Secondly, risk factors for celiac disease were not identified and lastly, we have not included age group of more than 45 years.

#### **CONCLUSION:**

Celiac disease is more prevalent in young females and patients usually presents with history of chronic diarrhea. Anti-tTG antibodies have more diagnostic value than duodenal endoscopy. Villous atrophy was found in more than 50% of the patients who were diagnosed with celiac disease.

**TABLE NO. 1: BASELINE CHARACTERISTICS OF STUDY SUBJECTS****(N = 50)**

<b>Baseline Characteristics</b>	<b>N</b>	<b>%</b>
<b>Age – years</b>		
Mean±SD	31.14±6.07	
Range	14 – 40	
<b>Gender</b>		
Female	36	72
Male	14	28
<b>BMI - kg/m<sup>2</sup></b>		
Mean±SD	23.08±8.26	
Range	17.2 - 34.1	
Underweight (<18.5)	16	32
Normal (≥18.5 - 24.9)	25	50
Overweight (25.0 - 25.9)	7	14
Obese (≥30.0)	2	4
<b>Area of Residence</b>		
Urban	32	64
Rural	18	36
<b>Marital Status</b>		
Married	28	56
Single	22	44

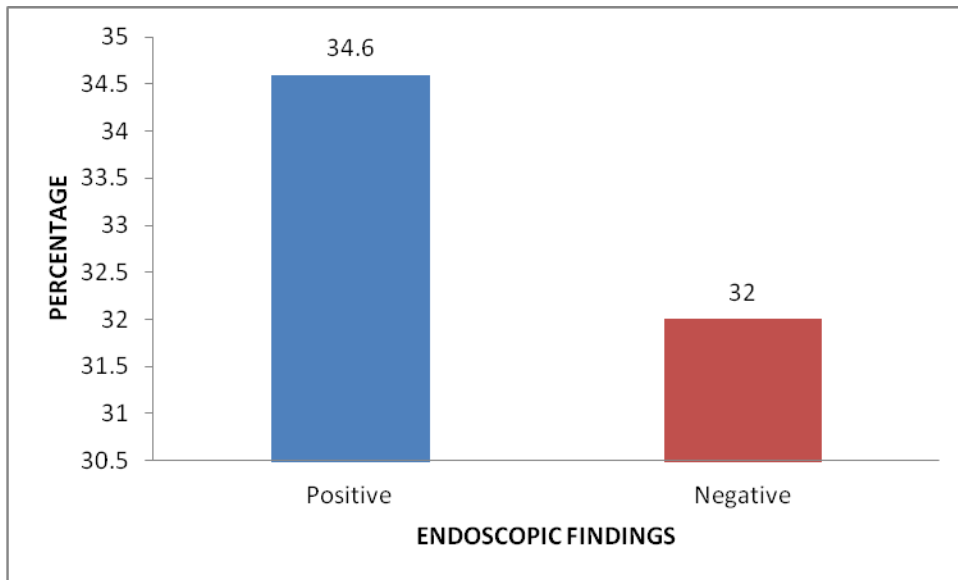
**TABLE NO. 2: CORRELATION OF CLINICAL MANIFESTATIONS WITH POSITIVE SEROLOGY FOR CELIAC DISEASE**

(N = 50)

Clinical Manifestation	Positive Anti-tTG Antibodies	
	N	%
Chronic Diarrhea	37	74
Abdominal Pain	26	52
Nausea and Vomiting	17	34
Weight loss	12	24
Iron Deficiency Anemia	9	18
Mouth Ulcer	5	10
Cutaneous Manifestations	4	8
Family History of Celiac Disease	3	6
Constipation	1	2

**FIGURE NO. 1: DIAGNOSTIC ACCURACY OF ENDOSCOPIC FINDINGS BY  
TAKING HISTOPATHOLOGY AS GOLD STANDARD**

(N = 50)



**TABLE NO. 3: ENDOSCOPIC ASSESSMENT OF DUODENAL VILLOUS ATROPHY IN PATIENTS WITH CELIAC DISEASE**

(N = 26)

Endoscopic Aspects	n	%
Visible submucosal vessels	20	76.92
Reduction or absence of submucosal folds	17	65.38
Scalloping of folds	17	65.38
Mucosal nodularity (mosaic pattern)	12	46.15
Mucosal fissures, crevices or grooves	10	38.46

### **REFERENCE LIST**

1. Lebwohl B, Rubio-Tapia A. Epidemiology, Presentation, and Diagnosis of Celiac Disease. *Gastroenterology*. 2021;160(1):63-75.
2. Al-Toma A, Volta U, Auricchio R, Castillejo G, Sanders DS, Cellier C, et al. European Society for the Study of Coeliac Disease (ESsCD) guideline for coeliac disease and other gluten-related disorders. *United European Gastroenterol J*. 2019;7(5):583-613.
3. Rashid M, Rashid H. Coeliac disease in Pakistan: A bibliographic review of current research status. *J Pak Med Assoc*. 2019;69(12):1883-8.
4. McAllister BP, Williams E, Clarke K. A Comprehensive Review of Celiac Disease/Gluten-Sensitive Enteropathies. *Clin Rev Allergy Immunol*. 2019;57(2):226-43.
5. Walker MM, Murray JA. An update in the diagnosis of coeliac disease. *Histopathology*. 2011;59(2):166-79.
6. Lock RJ, Pitcher MC, Unsworth DJ. IgA anti-tissue transglutaminase as a diagnostic marker of gluten sensitive enteropathy. *J Clin Pathol*. 1999;52(4):274-7.
7. Martin-Masot R, Nestares MT, Diaz-Castro J, Lopez-Aliaga I, Alferez MJM, Moreno-Fernandez J, et al. Multifactorial Etiology of Anemia in Celiac Disease and Effect of Gluten-Free Diet: A Comprehensive Review. *Nutrients*. 2019;11(11).

8. Elli L, Branchi F, Tomba C, Villalta D, Norsa L, Ferretti F, et al. Diagnosis of gluten related disorders: Celiac disease, wheat allergy and non-celiac gluten sensitivity. *World J Gastroenterol*. 2015;21(23):7110-9.
9. Castillo NE, Theethira TG, Leffler DA. The present and the future in the diagnosis and management of celiac disease. *Gastroenterol Rep (Oxf)*. 2015;3(1):3-11.
10. Abbas Z, Raza S, Yakoob J, Abid S, Hamid S, Shah H, et al. Varied presentation of celiac disease in Pakistani adults. *J Coll Physicians Surg Pak*. 2013;23(7):522-4.
11. Masood N, Ali Shaikh I. Clinical presentations and biochemical profile in adult celiac disease patients in Hyderabad: Pakistan. *Pak J Med Sci*. 2014;30(2):287-90.
12. Choung RS, Khaleghi S, Cartee AK, Marietta EV, Larson JJ, King KS, et al. Community-Based Study of Celiac Disease Autoimmunity Progression in Adults. *Gastroenterology*. 2020;158(1):151-9 e3.
13. Babio N, Alcazar M, Castillejo G, Recasens M, Martinez-Cerezo F, Gutierrez-Pensado V, et al. Risk of Eating Disorders in Patients With Celiac Disease. *J Pediatr Gastroenterol Nutr*. 2018;66(1):53-7.
14. Laurikka P, Salmi T, Collin P, Huhtala H, Maki M, Kaukinen K, et al. Gastrointestinal Symptoms in Celiac Disease Patients on a Long-Term Gluten-Free Diet. *Nutrients*. 2016;8(7).

15. Ludvigsson JF, Murray JA. Epidemiology of Celiac Disease. *Gastroenterol Clin North Am.* 2019;48(1):1-18.
16. Singh P, Arora A, Strand TA, Leffler DA, Catassi C, Green PH, et al. Global Prevalence of Celiac Disease: Systematic Review and Meta-analysis. *Clin Gastroenterol Hepatol.* 2018;16(6):823-36 e2.
17. Singh P, Arora S, Singh A, Strand TA, Makharia GK. Prevalence of celiac disease in Asia: A systematic review and meta-analysis. *J Gastroenterol Hepatol.* 2016;31(6):1095-101.
18. Khatoon S, Ahmed A, Yousaf S. Iron Deficiency Anaemia In Pakistan: Celiac Disease An Underlying Cause. *J Ayub Med Coll Abbottabad.* 2018;30(3):372-6.
19. Barker JM, Liu E. Celiac disease: pathophysiology, clinical manifestations, and associated autoimmune conditions. *Adv Pediatr.* 2008;55:349-65.
20. Jones S, D'Souza C, Haboubi NY. Patterns of clinical presentation of adult coeliac disease in a rural setting. *Nutr J.* 2006;5:24.
21. Seehusen DA. Comparative Accuracy of Diagnostic Tests for Celiac Disease. *Am Fam Physician.* 2017;95(11):726-8.
22. Charlesworth RP. Diagnosing coeliac disease: Out with the old and in with the new? *World J Gastroenterol.* 2020;26(1):1-10.

23. Balaban DV, Popp A, Vasilescu F, Haidautu D, Purcarea RM, Jinga M. Diagnostic yield of endoscopic markers for celiac disease. *J Med Life*. 2015;8(4):452-7.
24. Piazzì L, Zancanella L, Chilovi F, Merighi A, De Vitis I, Feliciangeli G, et al. Diagnostic value of endoscopic markers for celiac disease in adults: a multicentre prospective Italian study. *Minerva Gastroenterol Dietol*. 2008;54(4):335-46.
25. Koay DSC, Ghumman A, Pu L, Singh R. Narrow-band imaging with magnification and the water immersion technique: a case-finding, cost-effective approach to diagnose villous atrophy. *Singapore Med J*. 2019;60(10):522-5.