

**Prosthetic Management of Segmentally  
Resected Mandible and Partial  
Glossectomy: A Case Report**

UNDER PEER REVIEW

## ABSTRACT

The balance and symmetry of mandibular function gets destroyed by the loss of continuity of the mandible, which deviates the residual fragment towards the resected side thereby altering the mandibular movements. Physical therapy in combination with prosthodontic treatment can be used to reduce the mandibular deviation and hence it improves the masticatory efficiency. Many prosthetic methods are discovered to minimize deviation and provide masticatory efficiency. Some of these methods are mandibular guide flange prosthesis, implant supported prosthesis and palatal guidance restoration. Contact of Tongue with palate is important for the production of normal speech, also the proper place of the tongue during certain sounds is important. In partial glossectomy conditions, tongue to palate articulation gets affected during speech and patient faces difficulty to pronounce certain sounds. For the rehabilitation of such patient thorough knowledge of the production of different sounds can be useful for diagnosis and treatment planning.

*Keywords: Mandibulectomy, neck resection, tongue prosthesis, guiding flange, twin occlusal prosthesis, admix technique.*

## INTRODUCTION-

Tongue plays important role in sensing taste, pressure, heat, cold and touch. Tongue is one of the boneless movable organs in the body<sup>1</sup> which helps in basic oral functions like chewing, swallowing and speaking. Sensory nerve present in the tongue helps to distinguish the consistency and texture of the food. Mastication is crushing the food against the rugae of the hard palate. The muscle of tongue and cheek control and repositions the food bolus on the occlusal surfaces and push it against the hard palate at every chewing stroke after which saliva mixes into the bolus. When bolus is ready to be swallowed, tongue guides the food into the buccal vestibule and the floor of the mouth.<sup>2</sup> However, altered anatomy due to surgery of tumor resection makes patients inharmonious with prosthetic rehabilitation, unless and until some correction of soft tissue is done.<sup>3</sup> Tongue prosthesis is important for the rehabilitation of Glossectomy cases for establishing the contact of tongue and hard palate which is necessary for close to the normal functions. For the reshaping of hard and/or soft palate to establish the normal tongue-palatal seal to perform deglutition and speech, Palatal augmentation prosthesis (PAP) has proven very useful. This could be a complete denture or removable partial denture prosthesis. Thickness of the PAP affects the phonetics and pattern of swallowing of the patient.<sup>4</sup>

Mandibular tumors usually need surgical removal of the lesion and resection of the bone. Smaller lesions with continuity of the bone are relatively easy to restore with prosthesis where

as Large lesions which extend into the floor of the mouth even if the continuity of the mandible is maintained, will be more difficult to restore prosthetically. It's a complicated procedure to restore the function in partial or hemi-mandibulectomy along with disarticulation cases. Patient may manifest a reduction in the normal maximal vertical opening with deviation of the mouth. This abnormality can severely prevents the insertion of impression trays and fabrication of prosthesis. In the dentulous patients, prosthesis should be designed to effectively maintain the proper muscle balance with functional occlusion and must be inserted immediately after surgical procedure to prevent mandibular deviation.<sup>5</sup>

Combination of physical speech therapy and prosthodontic treatment can be useful to reduce mandibular deviation thereby improving the masticatory efficiency. Numbers of prosthetic methods are employed for minimizing deviation and to improve masticatory efficiency which includes mandibular guide flange prosthesis, twin occlusal prosthesis, implant supported prosthesis, and palatal augmentation restoration. This article describes the prosthetic management of segmentally resected mandible and partial glossectomy with the twin occlusal prosthesis and guiding flange both along with palatal augmentation tongue prosthesis.

## CASE REPORT-

A 58 year male patient reported to the prosthodontics department with the chief complaint of difficulty in deglutition, eating and

speaking. Patient gave a medical history of pain and swelling on the left side of the tongue two years ago which was histologically revealed as a "Moderately Differentiated Squamous Cell Carcinoma" with respect to the left side of the tongue. Due to above mentioned diagnosis,

segmental resection of the mandible from the second premolar region to the ramus along with partial resection of the tongue and neck on the left side was done [fig 1.1 and 1.2].

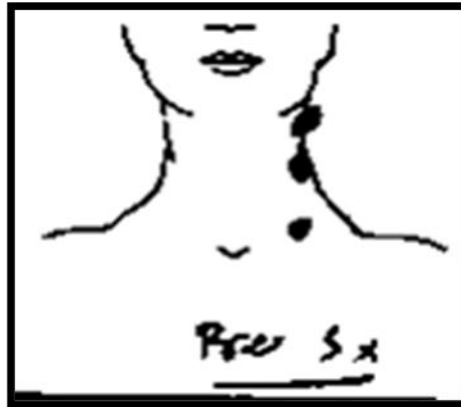
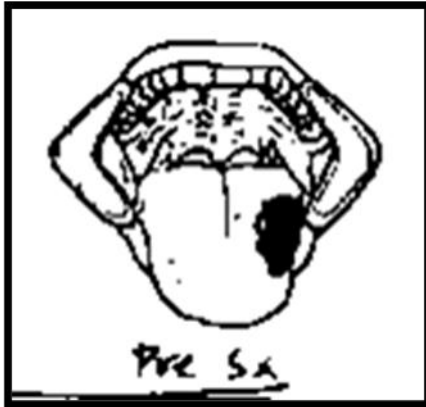
Figure 1.1 and 1.2 Pretreatment schematic representation of Squamous Cell Carcinoma.

Also maxillary teeth of affected side were extracted from premolar region to avoid trauma. Patient undertook radiotherapy for a period of one year and is still undergoing speech therapy. Patient was on a liquid diet since two years and was unable to chew food. He was also experiencing discomfort while speaking.

#### EXTRAORAL EXAMINATION-

Extra-oral examination revealed deviation of the mandible towards the affected (left) side. Scar mark noted extending from the middle of the chin to the neck region [fig 1.3].

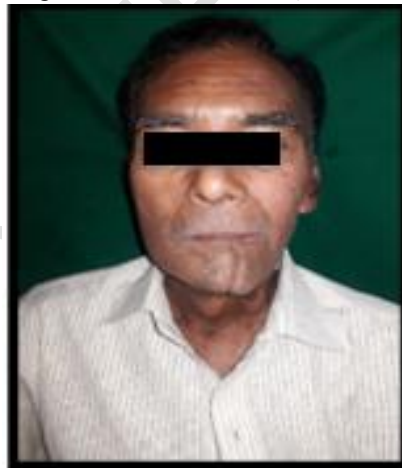

Figure 1.3 Extraoral front view

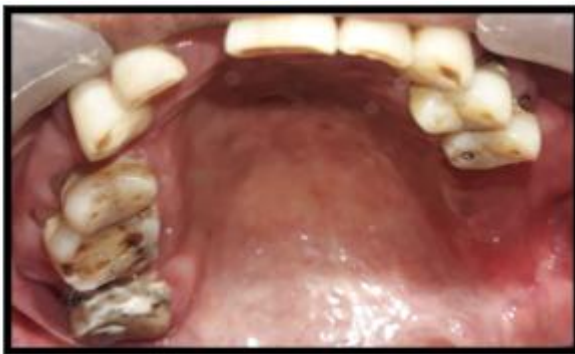
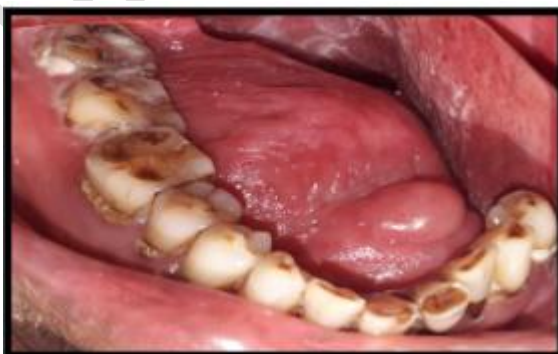
Figure 1.4 and 1.5 Intraoral view of mandibular and maxillary arch.

### INTRAORAL EXAMINATION-

Intraoral examination revealed generalized attrition with respect to the remaining teeth. Deviated bite seen towards the left side,

calculus and stains were noted with respect to present teeth. Partial Glossectomy along with the scar tissue seen on left side [fig 1.4, 1.5 and 1.6].

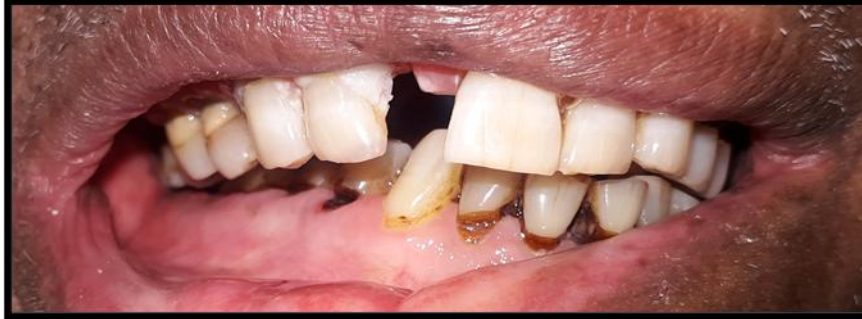

Figure 1.6 Deviated bite

### RADIOLOGICAL INTERPRETATION-

Radiological examination with OPG showed a

complete partial resection of the mandible along with ramus with respect to the left side starting from premolar region [fig 1.7].

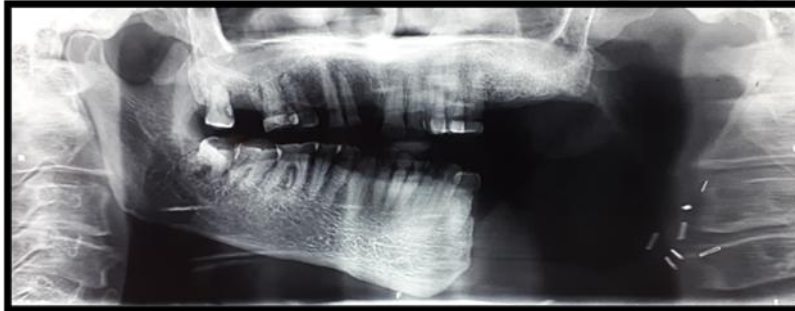


Figure 1.7 OPG

With all the above-mentioned diagnosis, according to Cantor and Curtis<sup>6</sup> this patient was classified as a class II and provisionally diagnosed as segmentally resected mandible with partial resection of the tongue along with neck resection with respect to the left side.

Considering the longevity and cost, heat cured acrylic resin was chosen.

First prosthesis includes- guiding flange with palatal augmentation tongue prosthesis. This will help to maintain the muscle balance and oppose the deviation of mandible

Second prosthesis includes - twin occlusal prosthesis with palatal augmentation tongue prosthesis, which will help for mastication and deglutition.

### TREATMENT PLAN-

The treatment plan aimed at providing prosthesis to correct the masticatory function, swallowing and speech by giving two different prostheses. To overcome masticatory difficulties, twin occlusal prosthesis and for deviation correction, guidance flange prosthesis was planned. Patient was instructed to wear twin occlusal prostheses during mastication only and guidance flange prosthesis for rest of the time.

### TREATMENT PROCEDURE-

To precede with the planned treatment an informed consent was obtained from the patient. Impression of the maxillary and mandibular arch made in the polyvinylsiloxane putty [DENSPLY, soft putty] with the help of sectional impression tray. Cast were poured in type III dental stone [KALSTONE, KALABHAI] [fig 1.8, 1.9].

Patient was informed about the different material for fabrication of tongue prosthesis.

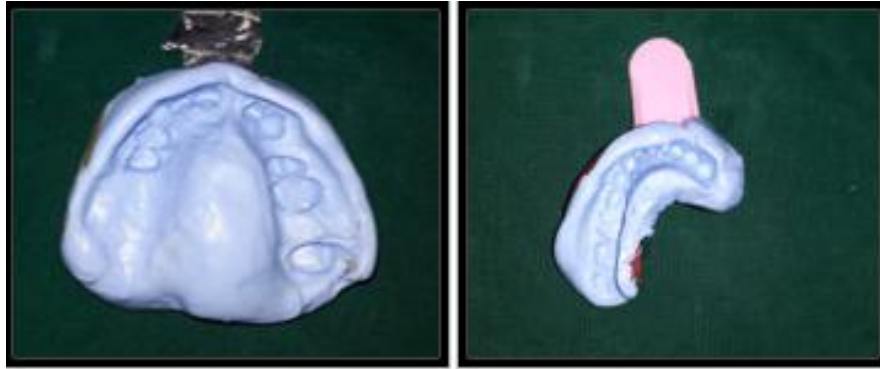


Figure 1.8 Intraoral impressions of maxillary and mandibular arch.

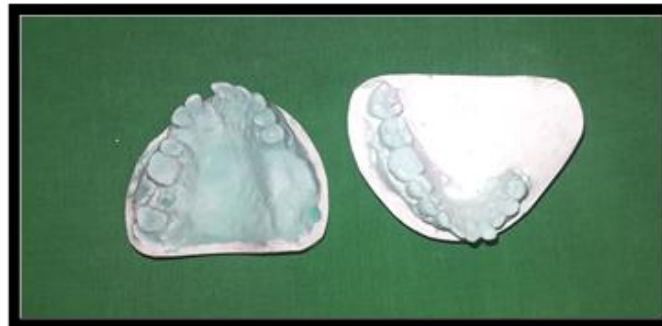

Figure 1.9 Maxillary and mandibular cast.

With the obtained cast, two base plates were fabricated on maxillary cast using self-cured pink acrylic and checked into the patient's mouth for any overextension and discomfort. On these record bases, wax rim were fabricated to record the jaw relation.

Jaw relations were recorded separately, with the corrected bite for construction of guiding flange and with the deviated bite to fabricate a twin occlusal prosthesis. These jaw relations

were mounted on the Hanau semi adjustable articulator separately [fig 1.10, 1.11].

On the corrected bite mounting, guiding flange with the replacement of missing teeth was fabricated using self-cured clear acrylic resin [DPI-RR cold cure][fig 1.12]. This was evaluated in the patient's mouth, finished and polished. Guiding flange delivered to the patient on the same appointment.

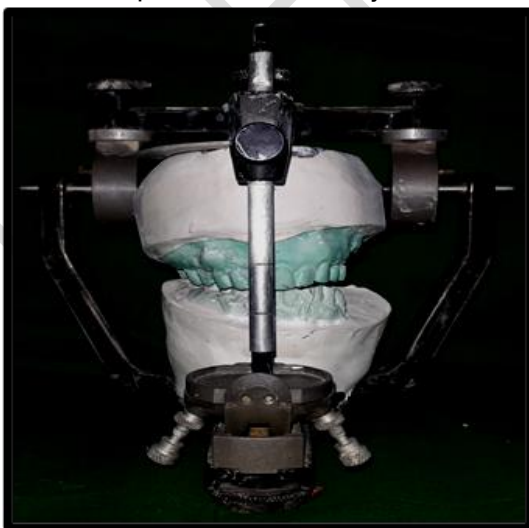


Figure 1.10 deviated bite mounting on Hanau articulator.



Figure 1.11 corrected bite mounting on Hanau articulator.

One the other hand, a base plate with self-cured pink acrylic resin was fabricated on deviated bite on which teeth arrangement was done for replacement of missing teeth and twin occlusal prosthesis using monoplane teeth. This was then verified in the patient's mouth for occlusion. After the try in for twin occlusal prosthesis, Next appointment was planned to make the impression for tongue prosthesis.

**PALATAL AUGMENTATION TONGUE PROSTHESIS-**

Admix technique<sup>7</sup> [impression compound and green stick compound in the ratio of 3:7, DPI PINNACLE tracing sticks, Y DENTS impression composition] was chosen for the impression making of tongue prosthesis because the viscous admix of impression compound and

green stick could allow the easy and fine recording of the lost tongue space. The guiding flange which was delivered to the patient was washed and disinfected thoroughly. The admix is applied on the left side of the guiding flange and inserted into the patients mouth. Patient is asked to perform vigorous tongue movement, close and open the mouth, swallow and was asked to try to speak. Impression is removed from the mouth and checked for the shiny surfaces which were indicative of non-contact with the tongue. More material is added on the shiny surfaces and reevaluated. Same steps were carried out until the non-shiny surface is obtained [fig 1.13, 1.14 and 1.15]. Patients comfort and ease for mastication, swallowing and speech was also evaluated.



Figure 1.12 guiding flange.

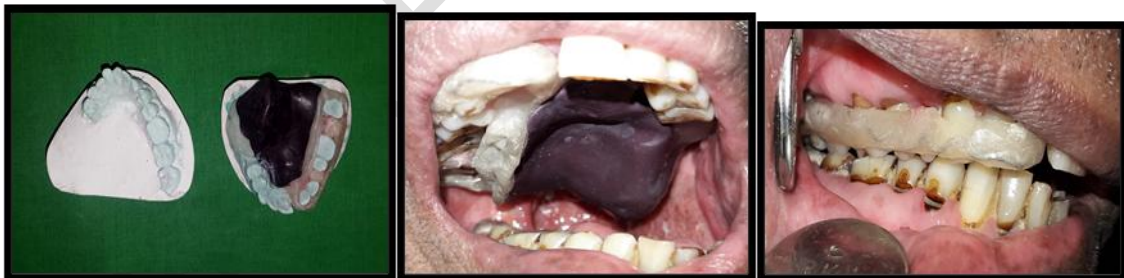

Figure 1.13, 1.14, 1.15 Guiding flange with recorded tongue space using Admix impression technique.

In the same manner tongue space impression was made with the twin occlusal prosthesis and evaluated in the patient's mouth [Fig 1.16, 1.17 and 1.18].

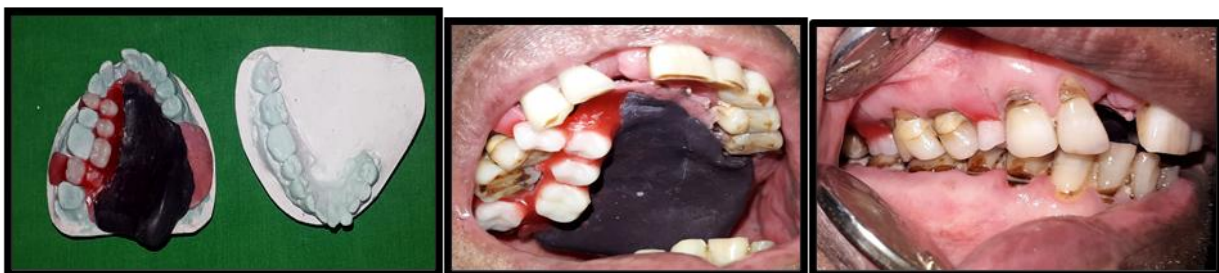

Figure 1.16, 1.17, 1.18 Twin occlusal prosthesis with tongue space impression.

**FABRICATION OF PROSTHESIS-**

Fabrication of the prosthesis was done with the help of heat cure pink acrylic resin [DPI-RR heat cure resin] for twin occlusal prosthesis and clear heat cure acrylic resin [DPI-RR heat cure clear resin] for guiding flange. Different shades of acrylic resin selected purposefully so that

patient would recognize easily which denture to wear when. Flasking of the denture done [fig 1.19], followed by dewaxing [fig 1.20] and packing. Final denture was finished, polished and evaluated in patient's mouth [fig 1.21 to 1.27].

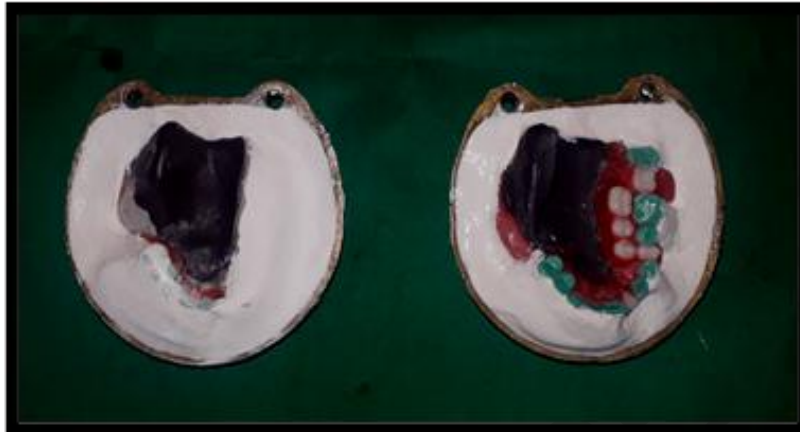

Figure 1.19 Flasking.

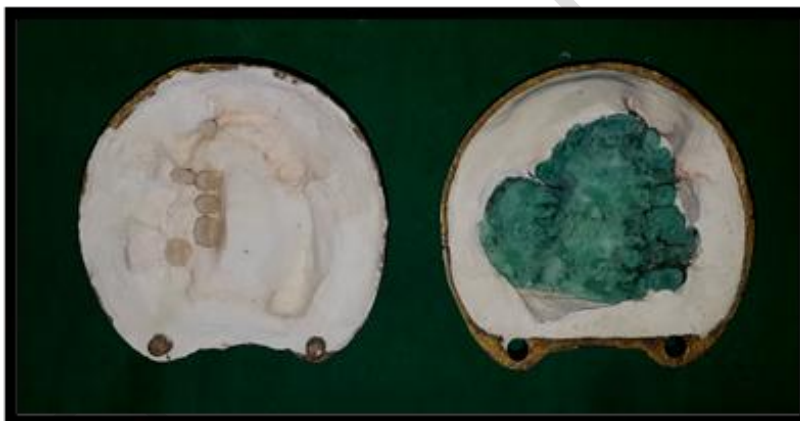

Figure 1.20 Dewaxing.

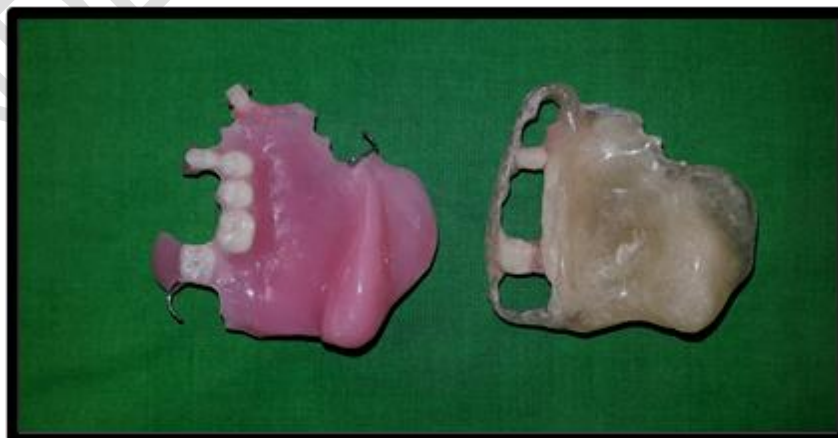

Figure 1.21 Final prosthesis.

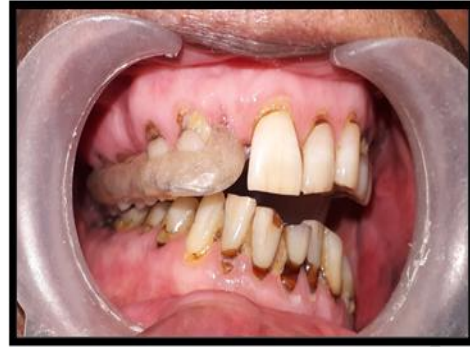
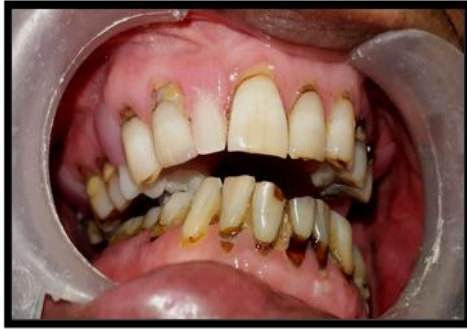
Figure 1.22, 1.23 Final prosthesis in patient's mouth.

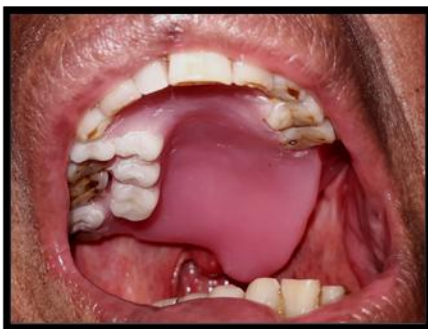

Figure 1.24 Deviated bite with twin occlusal and tongue prosthesis.

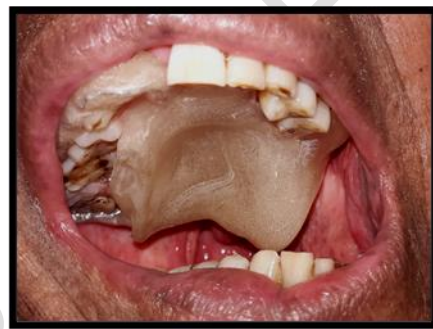

Figure 1.25 Corrected bite with guiding flange and tongue prosthesis.

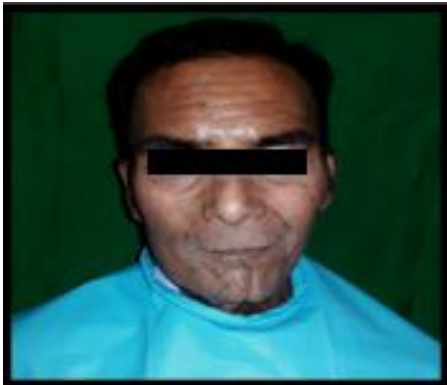

Figure 1.26 Extraoral view after insertion of twin occlusal prosthesis.

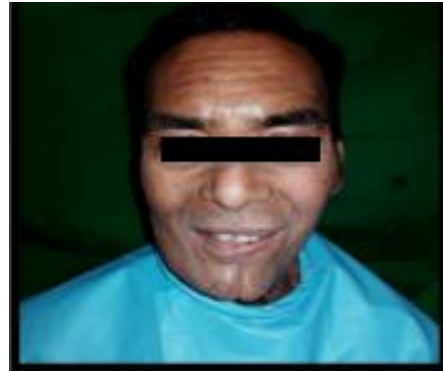

Figure 1.27 Extraoral view after insertion of guiding flange prosthesis.

## DISCUSSION-

According to the international literature data, oral cancer represents the eighth most common cancer worldwide, with a constantly higher incidence among men. Oral cancer patients often require a multidisciplinary approach, including surgical resection of the tumor and a series of complementary therapies aiming to full rehabilitation of the patients.<sup>3</sup>

Irradiated patients generally have xerostomia that may reduce the vacuum effect of the

protheses base to the soft tissues diminishing their retention. However, in this case report, despite the patient underwent to the radiotherapy the xerostomia was not clinically identified. This fact associated with a satisfactory amount of alveolar bone, an adequate occlusal adjustment and a good insertion of the protheses bases improved its retention.<sup>8</sup>

Choice of material was heat cure acrylic resin. Heat cure acrylic resin is used to make prosthesis which has long durability and worldwide used till date for denture fabrication. It has almost all properties of ideal denture base material as its strength is enough to withstand and distribute forces evenly to underlying tissues and got good dimensional stability for accurate fitting.<sup>9</sup>

It is impossible to restore the original function of the tongue either surgically or prosthetically. In patients with varying degrees of glossectomy, the capabilities of tongue movement may not be comparable from one case to another. Thus, the resulting limited functional outcome in speech and mastication of the prosthetically rehabilitated tongue defect is difficult to analyze as clinical research. However, the patient ultimately benefits from optimally created prostheses and can be ensured better function.<sup>2</sup> Scar tissue formation has occurred and guidance prosthesis was not possible because significant duration had elapsed after the surgical procedure. Success rate of prosthesis is higher in the patients with minimum destruction of floor of the mouth, tongue, and adjacent soft tissue structures. Considering all these above mentioned factors, we fabricated a conventional maxillary removable partial prosthesis with the twinned occlusion i.e. two rows of teeth.<sup>2</sup>

Tongue in coordination with cheeks helps to keep the food in contact with the occlusal surface of the teeth. Additionally, it helps in bolus formation and bolus propulsion into the pharynx. Decreased tongue mobility may leads to adherence of food particles to palate and unable to clean the food particles from the palatal vault. This results in alteration of speech due to lack of tongue contact with the alveolar ridge (lingualveolar), the hard palate (linguopalatal), teeth (linguodental), and the soft palate (lingualveolar).<sup>4</sup>

Surgical resection of tip of the tongue, lateral glossectomy, removal of the base of the tongue and total glossectomy affects its function. The degree of disability to swallow or speak is affected by size, location and extent of the defect. The ability to swallow, masticate and formulate consonants and vowels for speech sounds is severely altered after total or partial glossectomy. In 1972, Moore suggested tongue prosthesis as the treatment of choice in total glossectomy cases.<sup>1</sup>

The palatal augmentation prosthesis helps to improve tongue -palate contact during speech and swallowing by reshaping of the hard and or soft palate. This palatal augmentation prosthesis could be removable partial or complete denture prosthesis. Oral functions of the residual structures must be assessed while rehabilitating a glossectomy patient. Extent of the defect as well as factors such as neuromuscular co-ordination, mobility of the residual oral as well as paraoral structures and motivation determines the prognosis of the treatment.<sup>1</sup>

Guiding flange prosthesis must be inserted as soon as possible following an operation to prevent deviation of the mandible. If teeth are present, guiding flange prosthesis must be designed to effectively maintain functional occlusion and muscle balance. Guiding flange prevent palatal trauma, deviation of the mandible and enhanced flexibility of the facial skin and muscles.<sup>5</sup>

Tripathi et al found that percentage of deviation correction is inversely proportional to duration elapsed between surgical phase and prosthesis insertion and amount of initial deviation.<sup>10</sup>

Usually duration required for complete correction of deviation is vary for each patient so there is necessary to provide two prostheses so that mastication difficulties can be overcome along with deviation correction.

Two prosthesis was given to this patient purposefully so that he will have a benefit of tongue prosthesis while wearing guiding flange as well as while eating when he will use the twin occlusal prosthesis which will help to improve his speech also. With the help of tongue prosthesis, patient can swallow with the ease even if he will not be wearing a twin occlusal prosthesis so the drooping of saliva will be less.

#### Conclusion-

This article deals with the prosthetic treatment of segmentally resected mandible with partial resection of the tongue in terms of functional adaptability, deglutition, speech, mandibular movement and mastication. Though the prosthetic rehabilitation cannot fully establish the original function of lost structure, but it can help the patient to perform the basic functions which will improve patient's facial look, his life style and most importantly his confidence into the society.

## REFERENCES

1. Balasubramaniam MK, Chidambaranathan AS, Mugam GS, Tah R. Rehabilitation Of Glossectomy Cases With Tongue Prosthesis: A Literature Review. JCDR; 2016.
2. Jamayet N, Zai SZ, Hossain S. Palatal drop augmentation and tongue prosthesis: a case report. Volume10. City Dent. Coll. J; January2013.
3. Romeo U, Lollobrigida M, Palaia G, Laurito D, Cugnetto R, and Biase A. Soft Tissue Management and Prosthetic Rehabilitation in a Tongue Cancer Patient: A Case Report. Hindawi; October2013.
4. Kumar P, Hasti A, Jagadeesh H, Thoudam B. Rehabilitation of a partial glossectomy patient: Palatal augmentation prosthesis. JIPS; 2020.
5. Arora V, Singh K, Agrawal K, Alvi H. Management of Mandibular Deviation after Mandibulectomy by Simplified Approach: A case Report. BMJ Case Rep; 2013.
6. Cantor R, Curtis T. Prosthetic Management of Edentulous Mandibulectomy Patients: Part I. Anatomic, Physiologic, And Psychologic considerations. J. Prosth. Dent; April1971.
7. Cord F, Tyson W. A conservative prosthodontic option for the treatment of edentulous patients with atrophic (flat) mandibular ridges. 182:469-72. Br Dent J; 1997.
8. Coelho M, Medeiros R, Filho A, Silva E. Prosthetic Rehabilitation of a Patient After A Partial Mandibulectomy: A Case Report. j.amsu; 2015.
9. Nair C, Rao D, Sajjan MC, Manyam R. Manipulation of Heat Cure Acrylic Resin. IDRR; March 2018
10. Tripathi A, Gupta A, Gautam V, Anwar M, Arora V. The Efficacy of Guiding Flange Appliance in Correcting Mandibular Deviation in The Hemi-Mandibulectomy Patient. A Correlative Study. Journal of Prosthodontics 2015;121-126.