

Case Report on Benign Spindle Cell Tumour

Case Study

ABSTRACT

Introduction: It's an extremely uncommon cancer. First, the epidermis, soft tissues, and connective tissues are impacted. Breast benign spindle cell lesions include a wide range of tumor-like or malignant fibroblastic and myofibroblastic entities. They should be made up entirely of Spindle cells (pure spindle cell lesions) are defined as lesions with no mixed epithelial component.

Clinical Finding :

Most Common Symptoms Of Spindle Cell Sarcoma.

- Bone ache. The most frequent sign of spindle cell sarcoma is bone discomfort. The most often afflicted bones by spindle cell sarcoma are those of the...
- Swelling And Tenderness.
- Reduced Mobility.
- Fatigue And Malaise.
- Lump Or Mass.

Diagnostic Evaluation: HB-6.7, TLC:-16, 200, PLT:-15, 000, MCV:-67.0, SR. BILIRUBIN:-0.7

Therapeutic Intervention – Tab. Allopuraznol 300mg BD, Inj. Emset:- 1.8mg TDS. Inj. Pantop 12mg BD, Inj. Ceftraxon 20ml NS 1 mg BD.

Outcome- Spindle cell tumours are uncommon cancers that develop in the peripheral and deep tissues of the body. According to a CT scan, a massive tumour encompassed the whole abdomen and pelvis. According to a CT scan, a massive tumour encompassed the whole abdomen and pelvis.

Conclusion : The patient is admitted to Acharya vinoba bhawe rural hospital sawangi (meghe) wardha, under the USG department, where he will get ongoing medical and nursing care, and his health is currently stable and under monitoring.

Keywords: USG abdomen; benign spindle cell tumour; paratoid area; tumour; fever.

1. INTRODUCTION

First, the epidermis, soft tissues, and connective tissues are impacted.

The name spindle cell sarcoma comes from the shape of the cancer cells. It starts with a little lump and inflammation, and as the cancer develops through the stages, the symptoms get worse. Spindle cell sarcoma is a malignancy of the soft tissues that begins in the bones. The size, location, and stage of the tumour define the type and severity of symptoms associated with spindle cell sarcoma.

Spindle cell sarcomas are a type of bone sarcoma that commonly affects the arms, legs, and pelvis. They're most frequent in adults over 40, and they're incredibly uncommon, accounting for only 2-5 percent of all primary bone cancer cases. Spindle cell sarcoma is a cancerous tumour that can arise in bone or soft tissue. It can appear everywhere on the body, although it's most frequent in the limbs (arms and legs). Spindle cell carcinoma is an uncommon kind of cancer that manifests itself as a polypoid exophytic tumour. Carcinosarcoma, pseudosarcoma, polypoid carcinoma, sarcomatoid carcinoma, and the spindle cell variation of squamous cell carcinoma are some of the other names for it.

2. CAUSES

The cause of a benign tumour is frequently unknown. When the body's cells reproduce and expand at an unusually fast rate, it's called cancer. The human body is capable of balancing cell division and growth in normal circumstances. When cells die or become damaged, they are naturally replaced by new, healthy cells. It can affect any area of the body, including the brain, but it is most common in the limbs (arms and legs). This does not have a one-size-fits-all explanation. This type of tumour is uncommon, however it can occur as a result of previous irradiation. Spindle cell sarcoma can affect anyone at any age, however it is more common in people over 50.

2.1 Signs and Symptoms

-Bone pain might last for a long time or come and go.

-A pathological fracture may occur*– this is a fracture that occurs as a result of a disease

The presence of a lump or bulk is referred to as swelling.

-There is a lot of tenderness in the area.

-Parotid swelling

2.2 Present History

A 2-year-old boy patient was admitted to Acharya vinoba bhawe rural hospital sawangi(meghe) wardha in May 2021 with complaints of edoema, nausea, and vomiting, and his family stated that he was unable to walk because of his obesity.

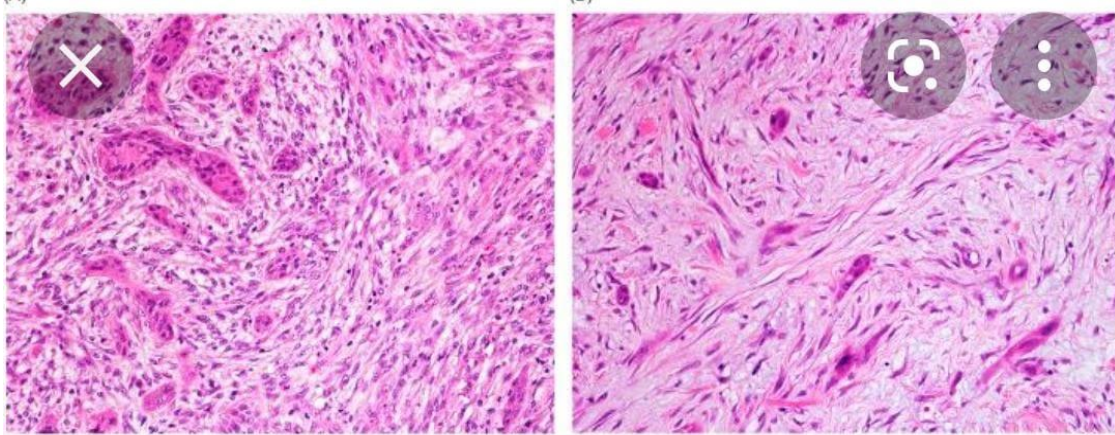


Fig. 1. Spindle cell carcinoma overview

2.3 Family History

The family consists of four members. A benign spindle cell tumour was discovered in my patient. Except for my patient, who was admitted to the hospital, none of the other members had any health issues.

2.4 Past History

The patient has no major medical history.

3. CLINICAL FINDING

Spindle cells are mesenchymal cells that make up the connective tissue of the body. Spindle cell neoplasms in soft tissues can range from reactive lesions to benign and malignant tumours. The lesions in this diverse group

include neural, fibroblastic, myofibroblastic, myogenic, and epithelial tumours.

3.1 Etiology

In people who are susceptible to such tumours, spindle cell sarcoma can form for a variety of reasons, including genetic predisposition, but it can also be generated by a combination of other factors, such as injury and inflammation.

3.2 Physical Examination

My patient has stomach pain and edoema, paratoid swelling, and soreness in the area.

3.3 Diagnostic Assessment

HB-6.7%,total protein-6.9, total platelets count-15,000

3.4 Therapeutic Intervention

Inj. Emset: 1.8mg TDS, Tab. Allopuraznol 300mg BD Inj. Pantop 12mg BD, Inj. Ceftraxon 20ml NS 1 mg BD, Inj. Pantop 12mg BD, Inj. Pantop 12mg BD, Inj. Pantop 12mg BD, Inj.

4. DISCUSSION

A male patient of 2 yrs was admitted to pediatric ward, Acharya vinoguybabhave rural hospital sawangi (meghe) wardha on 30 may, 2021 with complaint of, pallor, edema. A spindle cell tumour of the is described as a separate, benign tumour. Each tumour had islands of spindle or stellate cells embedded in a collagenous matrix on histology. The lesion was found in the stroma of the female breast, displacing but not including the epithelial components. Two tumours were studied ultrastructurally, and different populations of cells were discovered. Ultrastructural analysis of two tumours revealed fibroblasts, myofibroblasts, smooth muscle cells, and undifferentiated mesenchymal cells in various populations. The connection between these tumours and spindle cell lipomas is explored. The lesions were all clinically benign, and it's critical to recognise them as such carcinoma. The epithelial-mesenchymal transition is responsible for the neoplastic cells' distinctive spindle cell phenotype in SpCC. SpCC has been linked to cigarette smoking and alcohol intake in the same way as regular SCC has. Although it has been hypothesised that SpCC develops as a result of radiation exposure, some scientists feel this is not a significant etiologic component. The SCC component can be well-, moderately-, or poorly differentiated microscopically, keratinizing or nonkeratinizing, and the transition between the two might be sudden or slow. The spindle cell component of the tumour generally makes up the majority of the tumour. Pleomorphic spindle cells with big hyperchromatic nuclei, prominent nucleoli, and many mitoses are common. Only spindle cells are sometimes present. These tumours may resemble benign reactive lesions if they are less cellular. Patients who have previously been treated with radiation may have foci of osteosarcomatous, chondrosarcomatous, or rhabdosarcomatous differentiation. Spindle cell carcinoma (SpCC), also known as sarcomatoid carcinoma, is a biphasic tumour that includes both benign and malignant spindle cells. The epithelial-mesenchymal transition is responsible for the neoplastic cells' distinctive

spindle cell phenotype in SpCC. SpCC, like conventional SCC, has been linked to cigarette smoking and alcohol use. Although it has been claimed that SpCC develops after exposure to radiation, some scientists feel this is not a key etiologic component.

5. CONCLUSION

The patient is admitted to Acharya vinoba bhav rural hospitalsawangi (meghe) wardha .under the USG department, where he will get ongoing medical and nursing care, and his health is currently stable and under monitoring.

DISCLAIMER

The products used for this research are commonly and predominantly use products in our area of research and country. There is absolutely no conflict of interest between the authors and producers of the products because we do not intend to use these products as an avenue for any litigation but for the advancement of knowledge. Also, the research was not funded by the producing company rather it was funded by personal efforts of the authors.

CONSENT AND ETHICAL APPROVAL

As per university standard guideline, participant consent and ethical approval have been collected and preserved by the authors.

COMPETING INTERESTS

Authors have declared that no competing interests exist.

Please mention reference [1-11] inside the text

REFERENCES

1. Chan KW, Ghadially FN, Alagaratnam TT. Benign spindle cell tumour of breast—a variant of spindle cell lipoma or fibroma of breast?. Pathology. 1984 Jan 1;16(3):331-6.
2. Magro G, Michal M, Bisceglia M. Benign spindle cell tumors of the mammary stroma: diagnostic criteria, classification, and histogenesis. Pathology-Research and Practice. 2001 Jan 1;197(7):453-66.
3. Lew WY. Spindle cell lipoma of the breast: a case report and literature review. Diagnostic cytopathology. 1993 Jul;9(4):434-7.

4. Gaetano M, Giuseppe A, Saveria S, Rosalia R, Righi A, Enrico O. Fibroma of the breast: A rare tumour in the spectrum of the benign spindle cell tumours of the mammary stroma. *Polish Journal of Pathology*. 2018;69(2):189.
5. Ding J, Hashimoto H, Imayama S, Tsuneyoshi M, Enjoji M. Spindle cell haemangioendothelioma: probably a benign vascular lesion not a low-grade angiosarcoma. *Virchows Archiv A*. 1992 Jan;420(1):77-85.
6. Magro G. Differential diagnosis of benign spindle cell lesions. *Surgical pathology clinics*. 2018 Mar 1;11(1):91-121.
7. Naso JR, Chiu CG, Goecke ME, Chang D, Shiau CJ. Benign spindle cell lesions of the breast: a diagnostic approach to solitary fibrous tumour, nodular pseudoangiomatous stromal hyperplasia and nodular fasciitis. *Journal of clinical pathology*. 2019 Jun 1;72(6):438-42.
8. McMenamin ME, Fletcher CD. Mammary-type myofibroblastoma of soft tissue: a tumor closely related to spindle cell lipoma. *The American journal of surgical pathology*. 2001 Aug 1;25(8):1022-9.
9. Cui W, Fowles DJ, Bryson S, Duffie E, Ireland H, Balmain A, Akhurst RJ. TGF β 1 inhibits the formation of benign skin tumors, but enhances progression to invasive spindle carcinomas in transgenic mice. *Cell*. 1996 Aug 23;86(4):531-42.
10. Hoeger PH, Colmenero I. Vascular tumours in infants. Part I: benign vascular tumours other than infantile haemangioma. *British Journal of Dermatology*. 2014 Sep;171(3):466-73.
11. WWW.Wikipedia.com.

© 2021 Mam and Mandaokar; This is an Open Access article distributed under the terms of the Creative Commons Attribution License (<http://creativecommons.org/licenses/by/4.0>), which permits unrestricted use, distribution, and reproduction in any medium, provided the original work is properly cited.