

Original Research Article

NEPHROPROTECTIVE ACTIVITY OF ETHANOLIC EXTRACT OF *CARISSA CARANDAS* LEAVES AGAINST GENTAMICIN-INDUCED ACUTE KIDNEY INJURY IN WISTAR ALBINO RATS

ABSTRACT

The present study was aimed to evaluate the nephroprotective activity of ethanolic extract of *Carissa carandas* Linn. Leaves (EECC) in Gentamicin-induced nephrotoxicity in Wistar albino rats. The renal damage was induced by Gentamicin (80mg/kg body weight, i.p.). Nephroprotective activity was investigated by the administration of EECC at two different doses (100 and 200mg/kg body weight, p.o) for 28 days and by assessing serum parameters, renal oxidative stress markers and histopathological studies. Gentamicin-treated animals showed an increase in serum creatinine, uric acid, urea, and malondialdehyde (MDA) levels and decrease in total protein, reduced glutathione (GSH), and catalase (CAT) compared to normal control animals, which indicates severe nephrotoxicity. Histopathological studies of kidney Gentamicin-treated animals showed extensive acute tubular necrosis and peri-tubular inflammation. Administration of EECC showed a significant improvement ($p < 0.05$) in biochemical and oxidative stress markers compared to the disease group. EECC treated groups showed better histological appearance when compared to the disease group. Ethanolic extract of *Carissa carandas* Linn. Leaves showed significant nephroprotective activity against gentamicin-induced acute kidney injury.

Keywords: *Carissa carandas* Linn. Gentamicin, Acute kidney injury, Nephroprotective activity, Anti-oxidant activity.

1. INTRODUCTION

Acute kidney injury (AKI) or acute renal failure (ARF) is a clinical condition where suddenly kidneys will be unable to filter wastes and toxic substances from the blood properly. It is mainly caused due to exposure of kidneys to nephrotoxic agents like drugs, diagnostic agents like radiocontrast agents, biological agents such as Recombinant leucocyte and interferon's, and some chemicals like heavy metals. It involves reduced GFR which leads to increased concentrations of creatinine, urea, uric acid, BUN, etc. and decreased concentrations of

proteins and urine which is toxic [1, 2]. ARF is also caused by altered blood circulation to the kidneys, low blood pressure, direct kidney damage, muscle breakdown, hemolytic uremic syndrome, and blockade of the urinary tract.

Need of the present investigation is Acute renal failure (ARF) is a life-threatening disease with high mortality percentage. Two important mechanisms of ARF are inflammation and oxidative stress. Plants are rich source of antioxidant compounds and have a strong anti-inflammatory activity, so they may be useful for the treatment of ARF. Some herbal medicines are effective against different models of experimentally induced ARF such as cisplatin, gentamicin, glycerol, and ischemia–reperfusion injury.

Carissa carandas Linn. is an evergreen, hardy, drought-tolerant, sprawling, semi-vine, flowering shrub belonging to the dogbane family Apocynaceae. It produces berry-sized fruits that are commonly used as condiments in Indian pickles and spices. The plant is commonly grown from seeds. It is native of and commonly seen in warmer areas like most of the parts of India, Srilanka, Malaysia, and Myanmar. It mostly grows in tropical and sub-tropical climates. In India, it grows well in a wide range of soils like saline, rocky and sodic soils [3]. Common names include Bengal currant, Christ's thorn, Cranberry, Vakkaya, Karanda, Carandas plum, Karonda, etc [4]. Leaves of *Carissa carandas* Linn. Contain various chemical constituents like flavonoids, phenolic compounds, triterpenoids, tannins, saponins, alkaloids, carbohydrates, carissic acid, carandinol, betulinic acid, ursolic acid, oleanolic acid, 4-hydroxybenzoic acid, and β -sitosterol [5-8] the leaves of *Carissa carandas* Linn. was proven to have analgesic[9], anti-inflammatory[9], anti-diabetic[10], anti-microbial[11], anti-oxidant[12], anti-cancer[13], neuropharmacological [14], diuretic [14], and hepatoprotective activity [15] and they were traditionally used to treat diarrhea, otalgia, pyrexia, and anorexia nervosa.

In the present study, Nephroprotective activity of ethanolic extract of *carissa carandas* leaves against gentamicin-induced acute kidney injury in wistar albino rats was investigated.

2. MATERIALS AND METHODS

2.1 Materials

Ethanol, Distilled water, Vitamin E, Sodium hydroxide, Lead acetate, Magnesium turnings, α -naphthol, Ferric chloride, Hematoxylin-eosin stain, DPPH, Aluminum chloride, Sulfosalicylic acid, TCA, TBA, Hydrogen peroxide, Sulfuric acid, Hydrochloric acid, Carboxy methylcellulose(CMC), Mayer's reagent, Molisch reagent, Tollen's reagent, FC reagent, DTNB, Fehling's A and B solution obtained from SD Fine-Chem, Mumbai. Albumin

kit, Urea kit, Uric acid kit, Total protein kit from Coral Clinical Systems, and Creatinine kit from M/s Excel Diagnostics Pvt. Ltd.

2.2 Plant material and preparation of extract:

Carissa carandas Linn. Leaves were obtained from the local places of Tirupati, AP. The plant was authenticated by Dr. K. Madhava Chetty M.Sc., M.Ed., M.Phil., Ph.D., PG DPD., Department of Botany, SVU, Tirupati, AP. Fresh leaves washed with water, shade-dried, ground to get a uniform, coarse powder. Powdered plant material was weighed (1Kg) and is immersed in 95% ethanol [16] and kept for maceration [17] for 7 days with occasional stirring. On the 8th day, the solvent was filtered by pressing with a muslin cloth and was evaporated in a rotary evaporator at 40°C. The resultant extract was put in a desiccator for further drying. The dried ethanolic extract of *Carissa carandas* Linn. (EECC) was preserved for further studies.

2.3 Phytochemical Evaluation

The EECC was screened for the presence of various phytochemicals like carbohydrates, proteins, flavonoids, polyphenolic compounds, saponins, tannins, triterpenoids, etc [18].

2.4 Experimental animals

Institutional Animal Ethical Committee (IAEC) has given its approval to the experimental protocol on 10th November 2018 with ethical clearance No: CPCSEA/1657/IAEC/CMRCP/COL-18/65. Adult, healthy, male Albino-Wistar rats with an average weight of 150-200gms were acquired. Animals have been provided with 24-hour access with water and standard nutritional pellets, prior to and during the treatment. They were acclimatized under a period of one week under approved laboratory environment, i.e., 25°C±1°C temperature, 45-55% RH and also free access to food and water, after which they were employed in the experiment.

2.5 Evaluation of Nephroprotective activity

The animals were divided into five groups with six animals in each group (n=6) and the treatment is as follows.

- **Group I-Normal Control:** Normal saline (10ml/kg), p.o, OD for 28 days.
- **Group II-Disease Control:** Gentamicin (80mg/kg), i.p, OD for 8 days.
- **Group III-Standard Control:** Vitamin E (250mg/kg), p.o, OD for 28 days + Gentamicin (80mg/kg), i.p, OD during the last 8 days.
- **Group IV-Test Control (100mg/kg):** EECC (100mg/kg), p.o, OD for 28 days + Gentamicin (80mg/kg), i.p, OD during the last 8 days.
- **Group V-Test Control (200mg/kg):** EECC (200mg/kg), p.o, OD for 28 days + Gentamicin (80mg/kg), i.p, OD during the last 8 days [19].

24 hr post final dose administration, body weights were measured and the blood was collected into Eppendorf tubes via the retro-orbital route. Serum samples were prepared by the centrifugation the blood samples at 3000rpm for a period of 10mins and were used to evaluate the biochemical parameters like creatinine, urea, uric acid, total protein, BUN, albumin, and globulin, etc. After collecting blood samples, animals sacrificed by the cervical dislocation technique, dissected and the kidneys isolated from each animal where one kidney kept in 10% Formalin for preparing histopathological slides and the other one homogenized using ice-cold KCl to prepare tissue homogenate to evaluate the *in vivo* antioxidant parameters [20].

2.6 Histopathological studies

The isolated kidneys preserved in 10% formalin were embedded in paraffin wax and longitudinally sliced by the use of a microtome. They were stained using hematoxylin and eosin (H&E) stain and observed under a trinocular microscope [20].

2.7 *In vivo* antioxidant studies

Lipid per oxidation (LPO) was determined by using TBARS method and malondialdehyde, which is the final product of lipid peroxidation pathway was measured at 532nm [21]. Reduced glutathione (GSH) was estimated by reaction with DTNB (5'5-dithiobis (2-nitrobenzoic acid)) according to Ellman's method [22] and Catalase (CAT) was estimated by reaction with hydrogen peroxide [23].

2.8 Statistical analysis

All the results were analyzed by using one-way ANOVA followed by Dunnett's multiple comparison tests [24].

3. RESULTS

3.1 Preliminary phytochemical screening

The preliminary phytochemical screening showed the presence of various phytochemicals like flavonoids, phenolic compounds, triterpenoids, tannins, saponins, amino acids, proteins, and carbohydrates in EECC

3.2 Kidney weights

Kidney weights of animals on Day 29 were elucidated in Table1. There is a significant decrease in kidney weights of animals treated with EECC 100mg/Kg and 200mg/Kg when compared to disease and normal control.

Table 1. Kidney Weights on the 29th Day

S.No	Group	Kidney weight on day 29(in grams)
1.	Normal control	1.293±0.04287
2.	Disease control	2.145±0.06059
3.	Standard control	1.730±0.04131 ^{***}
4.	EECC 100mg/Kg	1.910±0.05391 ^{**}
5.	EECC 200mg/Kg	1.855±0.04357 ^{**}

Values are represented as Mean ± SEM. Statistical analysis was done by one way ANOVA followed by post hoc Dunnett's multiple comparison tests. ^{***} $p < 0.0001$, ^{**} $p < 0.001$, and ^{*} $p < 0.05$ vs Disease control.

3.3 Serum parameters

The serum levels of creatinine, uric acid, urea, BUN, total protein, albumin, and globulin were elucidated in Table 2.

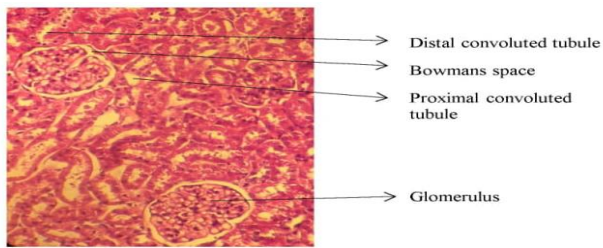
Table 2. Effect of EECC on Serum Parameters

S.No	Group/ parameter	Creatinine (mg/dl)	Uric acid (mg/dl)	Urea (mg/dl)	BUN (mg/dl)	Total protein (g/dl)	Albumin (g/dl)	Globulin (g/dl)
1.	Normal control	0.652±0.04 13	3.180± 0.0298	36.460 ±4.023	17.030± 1.880	17.200± 0.564	9.028±0. 204	8.167±0. 450
2.	Disease control	1.480±0.04 16	5.790± 0.3160	121.90 ±4.993	56.950± 2.331	4.827±0. 448	3.583±0. 304	1.243±0. 208
3.	Standard control	0.702±0.04 44 ^{***}	3.320± 0.215 ^{**} *	46.640 ±4.010 ***	21.780± 1.873 ^{***}	9.743±0. 483 ^{***}	5.898±0. 340 ^{***}	3.845±0. 418 ^{***}
4.	EECC 100mg/ kg	0.752±0.03 80 ^{***}	3.815± 0.268 ^{**} *	50.010 ±5.878 ***	23.35±2. 745 ^{***}	9.385±0. 582 ^{***}	5.768±0. 483 ^{***}	3.617±0. 466 ^{***}
5.	EECC 200mg/ kg	0.723±0.02 8 ^{***}	3.650± 0.1901 [*] **	50.721 ±3.149 ***	23.690± 1.470 ^{***}	8.867±0. 486 ^{***}	5.285±0. 254 ^{**}	3.582±0. 351 ^{***}

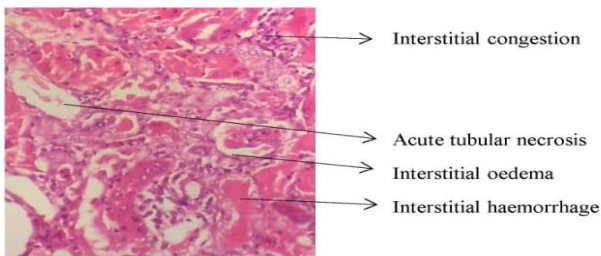
Values are represented as Mean \pm SEM. Statistical analysis was done by one way ANOVA followed by post hoc Dunnett's multiple comparison tests. *** $p < 0.0001$, ** $p < 0.001$, and * $p < 0.05$ vs Disease control.

3.4 Histopathological studies

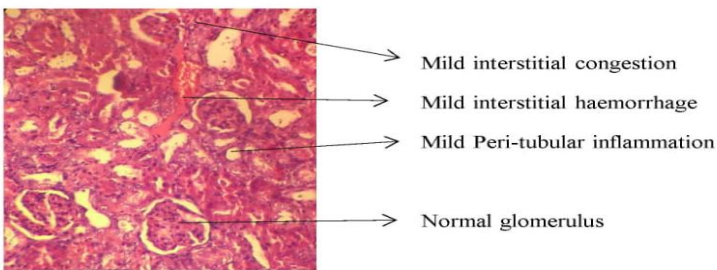
The results of histopathological studies were shown in **Figure 1**. In normal control group, kidney showed normal glomeruli, normal proximal and distal convoluted tubules. Severe distortion of glomeruli, and apical blebbing of proximal and distal convoluted tubules, interstitial oedema and interstitial haemorrhages were seen in disease control group. In 100 and 200 mg/kg of EECC treated group animals showed moderate reduction in the tubular damage and glomerular distortion, interstitial oedema, interstitial haemorrhages compared to disease control group. No significant changes were found in standard treated group.



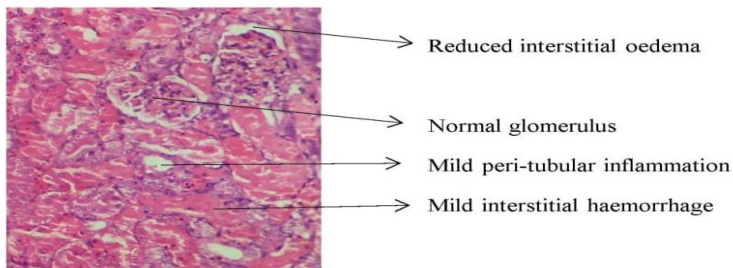
A) Group I-Normal control(Saline 10ml/kg)



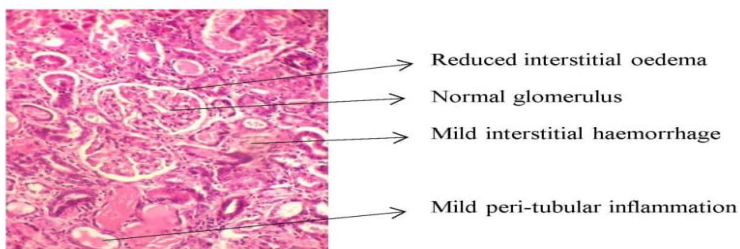
B) Group II-Disease control(80mg/kg)



C) Group III-Standard control(Vit E 250mg/kg)



D) Group IV-Test control(EECC 100mg/kg)



E) Group V-Test control(EECC 200mg/kg)

Fig. 1: Light microscopic study (H&E) of renal tissue in various experimental groups.

3.5 Antioxidant studies

The significant values of LPO, GSH, and CAT were elucidated in Table 3.

Table 3. Effect of EECC on LPO, GSH, and CAT

S.No	Group	Lipid peroxidation (in $\mu\text{M}/\text{mg}$ tissue)	Reduced glutathione (in μM of GSH/mg tissue)	Catalase (in units/mg protein)
1.	Normal control	2.853 \pm 0.0897	4.227 \pm 0.1054	0.720 \pm 0.0429
2.	Disease control	5.233 \pm 0.2124	2.907 \pm 0.1336	0.450 \pm 0.0341
3.	Standard control	2.965 \pm 0.1684 ^{***}	3.610 \pm 0.0823 ^{***}	0.636 \pm 0.0261 ^{**}
4.	EECC 100mg/Kg	3.303 \pm 0.0892 ^{***}	3.550 \pm 0.1029 ^{***}	0.598 \pm 0.0301 [*]
5.	EECC 200mg/Kg	3.590 \pm 0.0885 ^{***}	3.410 \pm 0.0823 ^{**}	0.603 \pm 0.0512 [*]

Values are represented as Mean \pm SEM. Statistical analysis was done by one way ANOVA followed by post hoc Dunnett's multiple comparison tests. ^{***} $p < 0.0001$, ^{**} $p < 0.001$, and ^{*} $p < 0.05$ vs Disease control.

4. DISCUSSION

The present study indicates phytochemical and pharmacological evaluation of nephroprotective action of ethanolic extract of *Carissa carandas* Linn. in the doses of 100 and 200 mg/kg body weight. Preliminary phytochemical screening of EECC indicated the presence of alkaloids, flavonoids, saponins, carbohydrates, proteins, amino acids, tannins, and phenolic compounds.

Gentamicin (GM) which is widely used aminoglycosides antibiotic, is recognized as possessing significant nephrotoxic potential in man and experimental animals. GM-induced nephrotoxicity is characterized by elevated levels of urea, creatinine, uric acid, and BUN in plasma. The nephroprotective study was carried out and the serum and parameters like creatinine, uric acid, urea, BUN, total protein, albumin, and globulin were measured to assess the nephroprotective activity of EECC. There are two factors on which serum and urine parameters depend. One is the glomerular filtration rate (GFR) and other is the degree of tubular re-absorption. The observed effect may be attributed to a mechanism like increasing the renal blood flow and the attendant increase in GFR. The present study demonstrates that EECC significantly increased the GFR compared to disease control animals. EECC reduced the serum creatinine, uric acid, urea, and BUN and increased serum protein, albumin, and globulin. These observations indicate an improved renal function by EECC.

In the phytochemical evaluation EECC contains tannins and flavonoids. Flavonoids are known to be anti-inflammatory action and Tannins proved as vasodilatory activity [25]. Renal vasodilatation can improve the GFR and urine output. This could be for a reason using decreased accumulation of Creatinine, urea and uric acid. Hence terpenoids, tannins and flavonoids present in the EECC may have contributed to the protection from renal damage induced by gentamicin by their anti-inflammatory, antioxidant and vasodilatory actions.

Antioxidant parameters like LPO, GSH, and CAT were also evaluated. Reduced activity of CAT and levels of GSH after treatment with gentamicin suppresses endogenous enzymatic antioxidant machinery. Treatment with EECC increased the activity of CAT and levels of GSH significantly compared to the disease control animals. It was also observed that an increase in LPO in the disease group is due to altered antioxidant machinery and higher susceptibility towards oxidative damage. However, EECC lowered LPO levels in EECC treated groups. As per the findings, the secondary metabolite, flavonoids is present in the plant which is antioxidant in nature.

Oxidative stress activation and inflammatory process constitute a major part of gentamicin nephrotoxicity. In fact, nephrotoxicity induced by gentamicin is associated with the mitochondrial dysfunction in renal tubular cells. It causes a marked impairment in the activity of mitochondrial respiratory enzymes including NADH dehydrogenase resulting in the excessive ROS generation [26]. Furthermore, gentamicin has been reported to stimulate O_2^- and NO^\bullet generation through activation of inducible isoform of NO^\bullet synthase (iNOS) in kidney tissue [27]. Reactive free radicals result in the lipid peroxidation, leading to the alteration of membrane lipid bilayer arrangement and reduction in antioxidant defense mechanisms, causing cellular damage and necrosis [28]. AECZ significantly reduced the oxidative/nitrosative stress markers such as MDA and NO^\bullet and further boosted the endogenous antioxidant parameters including SOD, catalase, and GSH, suggesting its *in vivo* antioxidant effects. This antioxidant effect of AECZ might contribute to its nephroprotective activity. This may be responsible for kidney protective activity.

The histopathological results obtained correlated well with the biochemical results and standard and EECC treated groups showed significant improvement when compared to disease control.

5. CONCLUSION

The nephroprotective activity of EECC may be due to the single or combined effects of flavonoids, terpenoids, saponins, tannins, and phenolic compounds. But there is a high chance that flavonoids or tannins must have shown significant nephroprotective activity because as per literature flavonoids and tannins do possess good action on the urinary system. Thus we can conclude that *Carissa carandas* Linn. Possess nephroprotective activity.

ABBREVIATIONS

BUN: Blood Urea Nitrogen; **CAT:** Catalase; **DTNB:** 5'5-dithiobis (2-nitrobenzoic acid); **EECC:** Ethanolic extract of *Carissa carandas* Linn. Leaves; **GFR:** Glomerular filtration rate; **H&E:** Haematoxylin and Eosin; **LPO:** Lipid peroxidase; **GSH:** Reduced glutathione; **MDA:** Malondialdehyde.

REFERENCES

1. Vaya RK, Sharma A, Singhvi IJ, Agarwal DK. Nephroprotective Plants: A Review. Journal of Bioscience and Technology. 2017; 8:801-12.
2. Sandhu DS, Heinrich M. The use of health foods, spices and other botanicals in the Sikh community in London. Phytotherapy Research: An International Journal Devoted to Pharmacological and Toxicological Evaluation of Natural Product Derivatives. 2005 Jul; 19(7):633-42.
3. Mishra CK, Shrivastava B, Sasmal D. Pharmacognostical standardization and phytochemical identification of fruit and root of *carissa carandas linn*. Extraction. 2013; 9:10.
4. Singh A, Uppal GK. A review on *carissa carandas* ġ phytochemistry, ethnoġpharmacology, and micropropagation as conservation strategy. Asian J Pharm Clin Res. 2015; 8(3):26-30.
5. Naim Z, Khan MA, Nizami SS. Isolation of a new isomer of ursolic acid from fruits and leaves of *Carissa carandas*. Pak J Sci Ind Res 1988; 31(11):753.
6. Tesfaye T, Ravichadran Y. Traditional Uses, Pharmacological Action and Phytochemical Analysis of *Carissa carandas* Linn. A Review. Natural Products Chemistry & Research. 2018; 06(05).
7. Siddiqui BS, Ghani U, Ali ST, Usmani SB, Begum S. Triterpenoidal constituents of the leaves of *Carissa carandas*. Nat Prod Res 2003; 17(3):153-8.
8. Begum S, Syed SA, Siddiqui BS, Sattar SA, Choudhary MI. Carandinol: First isohopane triterpene from the leaves of *Carissa carandas* L. and its cytotoxicity against cancer cell lines. Phytochem Lett 2013; 6(1):91-5.
9. Hati M, Jena BK, Kar S, Nayak AK. Evaluation of anti-inflammatory and anti-pyretic activity of *Carissa carandas* L. leaf extract in rats. Journal of Pharmaceutical, Chemical and Biological Sciences. 2014; 1:18-25.
10. Swami G, Nagpal N, Rahar S, Preeti S, Porwal A, Nagpal MA, Kapoor R. Effect of aqueous leaves extract of *Carissa carandas* Linn. On blood glucose levels of normoglycemic & alloxan-induced diabetic wistar rats. Int J Curr Pharm Res. 2010;

- 2(3):65-7.
11. Shafeeq MH, Omar-Zahid LA, Sidkey BA. The antimicrobial activity of *Carissa carandas* L., *Ficus carica* L., and *Olea europaeae* L. leaves extracts on growth of some pathogenic microorganisms. Journal of Al-Nahrain University-Science. 2014; 17(4):144-53.
 12. Verma K, Shrivastava D, Kumar G. Antioxidant activity and DNA damage inhibition in vitro by a methanolic extract of *Carissa carandas* (*Apocynaceae*) leaves. Journal of Taibah University for Science. 2015 Jan 1; 9(1):34-40.
 13. Khatun M, Habib MR, Rabbi MA, Amin R, Islam MF, Nurujjaman M, Karim MR, Rahman MH. Antioxidant, cytotoxic and anti neoplastic effects of *Carissa carandas* Linn. Leaves. Experimental and toxicologic pathology. 2017 Sep 5; 69(7):469-76.
 14. Saha R, Hossain L, Bose U, Rahman AA. Europharmacological and diuretic activities of *Carissa carandas* linn. Leaf. Pharmacologyonline. 2010; 2:320-7.
 15. Bhati P, Shukla A, Sharma M. Hepatoprotective activity of leaves extracts of *Carissa carandas* Linn. American Journal of Pharm Research. 2014; 4(11):5185-92.
 16. Saxena K. Analytical and medicinal properties of ethanolic extract of leaves of *carissa carandas*. World Journal of Pharmacy and Pharmaceutical Sciences. 2016 Mar; 5(4):1683-1690.
 17. Bint-e-Sadek Y, Choudhury N, Shahriar M. Biological investigations of the leaf extracts of *Carissa Carandas*. International Journal of Pharmaceutical Research and Technology. 2013; 5:97-105.
 18. Khandelwal K. Practical pharmacognosy. Pragati Books Pvt. Ltd.; 2008 Sep 7.
 19. Hamad EM, Mousa HM, Ashoush IS, Abdel-Salam AM. Nephroprotective Effect of Camel Milk and *Spirulina platensis* in Gentamicin-Induced Nephrotoxicity in Rats. Int J Pharmacol. 2018 Jan 1; 14:559-65.
 20. Sreedevi A, Saisruthi K. Attenuation of cisplatin-induced nephrotoxicity by ethanol extract of seeds of *Lens culinaris* medik. Ancient Science of Life. 2017 Oct 1; 37(2):74.
 21. Ohkawa H, Ohishi N, Yagi K. Assay for lipid peroxides in animal tissues by thiobarbituric acids reaction. Anal Biochem 1979; 95:351-8.
 22. Ellman GL. Tissue sulfhydryl groups. Arch Biochem Biophys 1959; 82:70-73.
 23. Sinha A. Calorimetric assay of catalase. Anal Biochem 1972; 47:389-94.
 24. Kanna S, Hiremath SK, Unger BS. Nephroprotective activity of Bilvādi agada in gentamicin induced nephrotoxicity in male Wistar rats. Ancient science of life. 2015; 34(3):126.
 25. Legssyer A., Ziyat A., Mekh H. Tannins and catechin gallate mediate the vasorelaxant

- effect of *Arbutus unedo* on the rat isolated aorta. *Phytother Res.* 2004; 18:889–894.
26. B. D. Sahu, S. Tatireddy, M. Koneru et al., “Naringin ameliorates gentamicin-induced nephrotoxicity and associated mitochondrial dysfunction, apoptosis and inflammation in rats: possible mechanism of nephroprotection,” *Toxicology and Applied Pharmacology*, 2014; 277(1): 8–20.
27. F. Paquette, A. Bernier-Jean, V. Brunette, “Acute kidney injury and renal recovery with the use of aminoglycosides: a large retrospective study,” *Nephron*, vol. 2015; 131 (3): 153–160.
28. E. Birben, U. M. Sahiner, C. Sackesen, S. Erzurum, and O. Kalayci, “Oxidative stress and antioxidant defense,” *World Allergy Organization Journal*, 2012; 5 (1): 9–19.

UNDER PEER REVIEW