

# Chronic Patellar Tendon Rupture Reconstructed with Hamstring Graft – A Case Report

## Case Report

### ABSTRACT

Neglected patella tendon rupture which are presented 6 weeks after injury are rare but it can be disabling. Aim of study is to determine the outcomes of chronic patellar tendon rupture reconstructed using hamstring graft.

This case report concerns a 26 year-old man who came with complaints of weakness of legs, difficulty in climbing stairs up and down, difficulty in getting up from squatting position. X-ray of Right knee showed high riding patella. MRI showed full thickness rupture of ACL. The patient was operated with a combination of Chen et al and ganga hospital SR Sundararajan<sup>7</sup>. Our outcome was also excellent with no extensor lag, Kujala score was 94.1, Lysholm score was 92.3. From our study it is found that even in chronic neglected cases of patellar tendon rupture, good functional results can be obtained by repair using hamstring graft.

*Keywords: Neglected patellar tendon injury; hamstring graft; chronic rupture; figure of 8.*

### 1. INTRODUCTION

Neglected patella tendon rupture which are presented 6 weeks after injury are rare but it can be disabling [1]. It occurs usually beneath the inferior pole of patella in younger population during sport related activities [2-5]. Patients are usually would have undergone native splinting. They are usually tough to repair [3,6]. Although different techniques have been described we have reconstructed using hamstring graft [7-9].

Neglected cases of Patellar tendon rupture are rare. Immediate post traumatic presentations are most common. So, Objective of this case study is to determine the outcomes of chronic patellar tendon rupture which is repaired using hamstring graft.

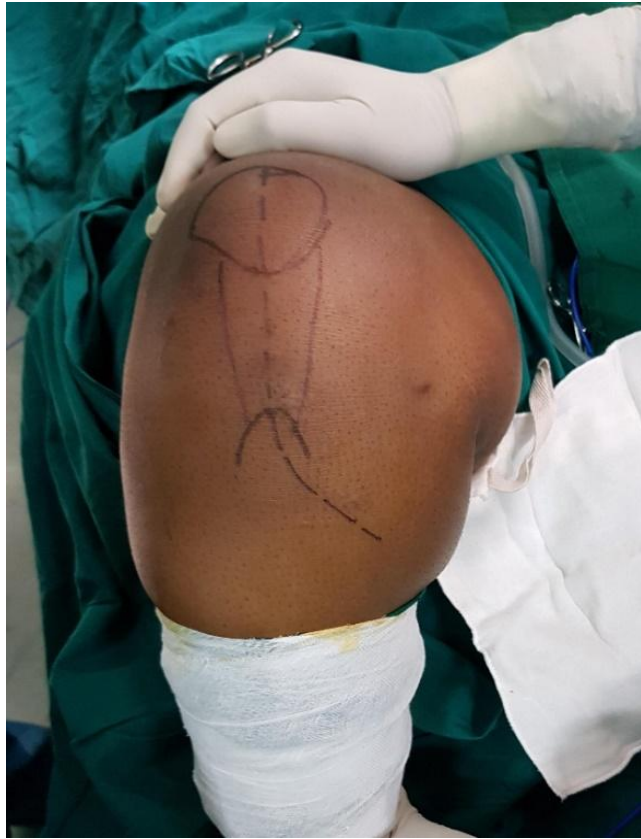### 2. CASE REPORT

26-year-old male came with complaints of weakness of legs, difficulty in climbing stairs up and down, difficulty in getting up from squatting position. Patient also complains of apprehension to fast walking or running due to buckling of

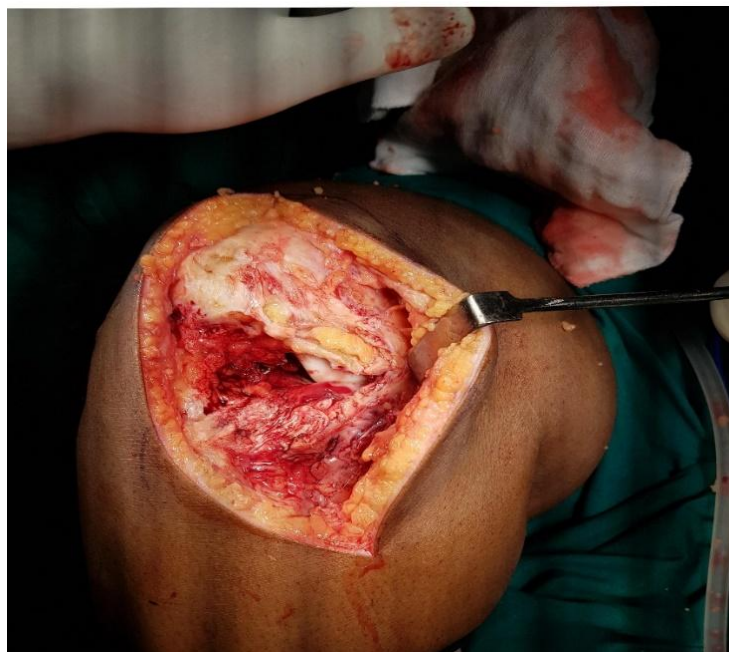knee. He had a past history of fall from motorcycle, over a flexed knee, 6 months ago, for which he underwent native splinting for 3 months, 6 splints each for 15 days. On examination patient could not do active extension. Passive ROM was full. Quadriceps power was 3/5. Quadriceps wasting of 1cm was present. A palpable defect was felt beneath the inferior pole patella. Knee X ray showed high riding patella. Pre operative MRI showed full thickness rupture of ACL.

### 3. OPERATIVE PROCEDURE

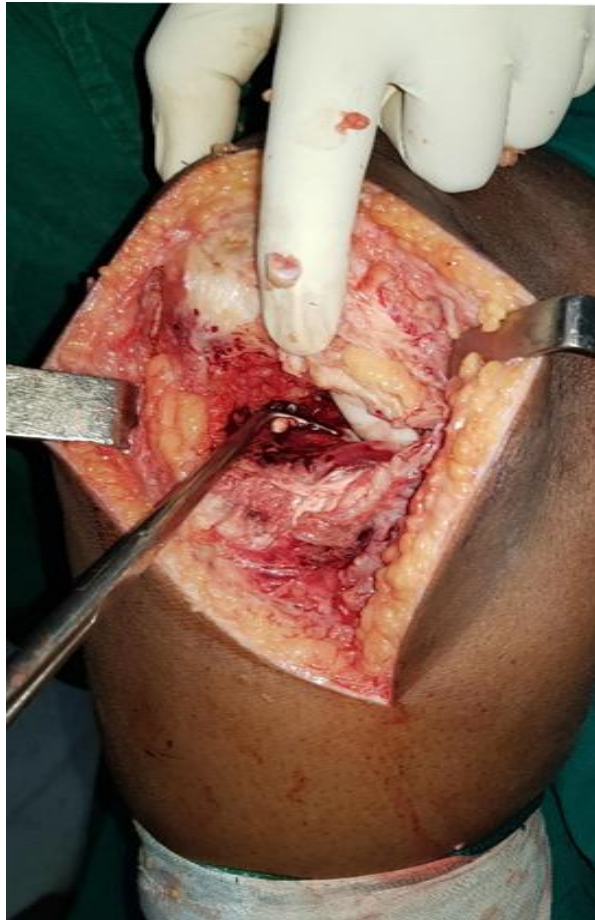
Under spinal anaesthesia, parts painted and draped, patella was marked, and tibial tuberosity was marked (Fig. 1), a midline anterior incision was made, we found complete rupture and degeneration of the tendon (Fig. 2), ACL ruptured end was visualised (Fig. 3). The upward migrated patella was tracked down without any difficulty. Two transverse tunnels were made within the patella (Fig. 4) by guide wire and another tunnel parallel to these was within the tibial tuberosity.



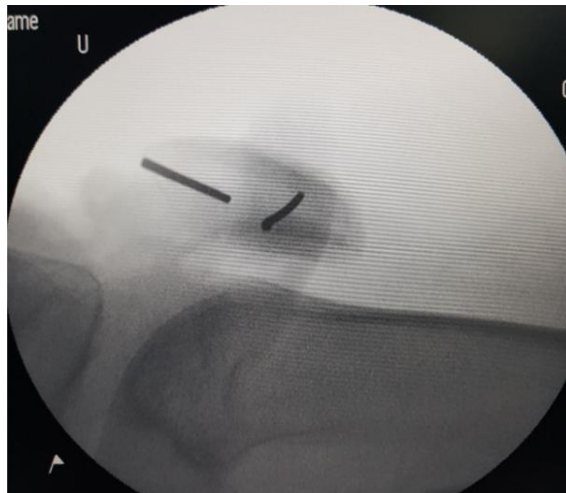**Fig. 1. Patella and tibial tuberosity is marked**



**Fig. 2. Complete rupture of patellar tendon with no residual tendon**



**Fig. 3. Complete rupture of patellar tendon**



**Fig. 4. Transverse tunnels created using guide wires**

Hamstring tendons, gracilis and semi tendinosis were harvested using open tendon stripper (Fig. 5), insertion on tibial tuberosity was not detached, muscle tissue were removed. Gracilis was passed from same side to upper tunnel of patella , semi tendinosis was passed in opposite

side of lower tunnel (Fig. 6) was brought out to like “ Fig. of 8” fashion within the tibial tunnel, both semi tendinosis and gracilis was sutured with 2-0 ethibond to complete the tendon reconstruction (Fig. 7,8). Fluoroscopy was used to confirm the position of the patella to maintain

Insall- salvati ratio at 30° of flexion. The strength of the construct was tested by flexing the knee to

90° (Fig. 9). Cerclage wire was put to maintain the stability of the construct.

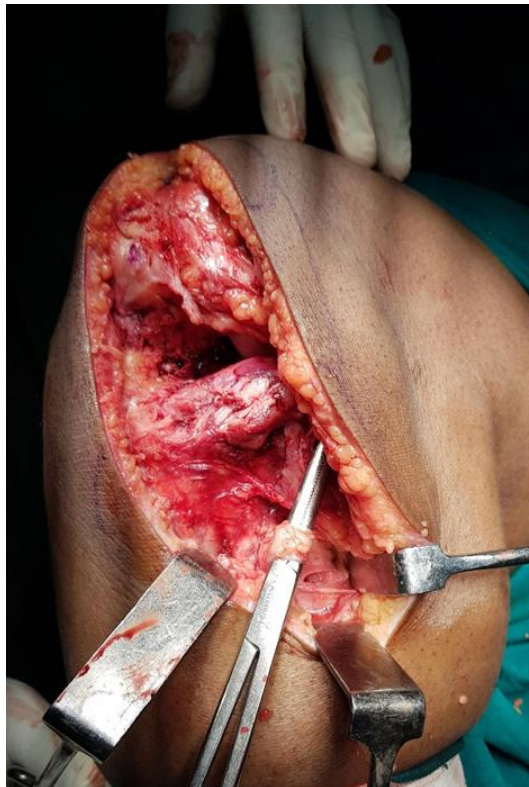

Fig. 5. Hamstring tendons harvested without detaching the insertion site with open tendon stripper

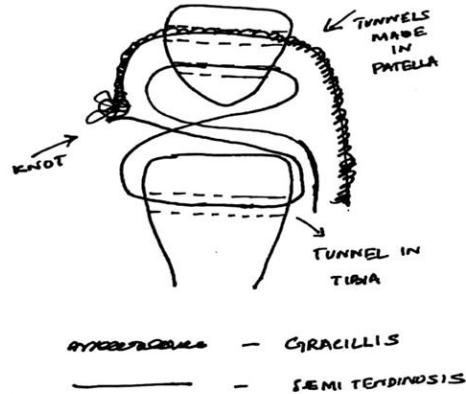
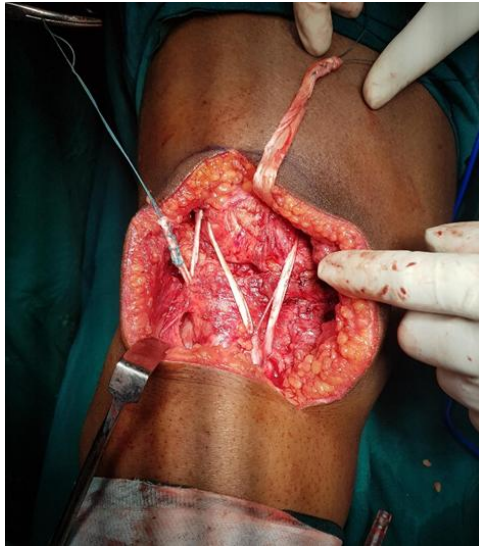
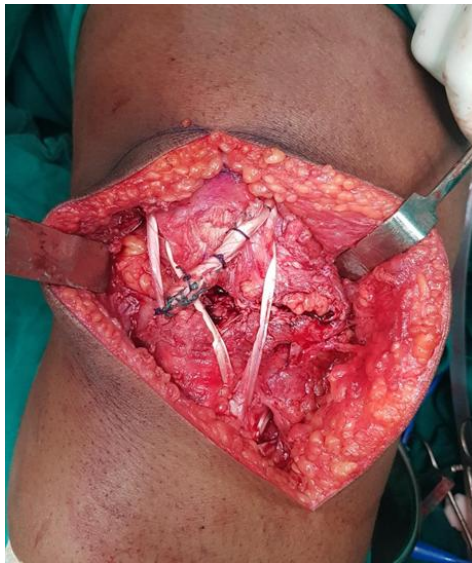

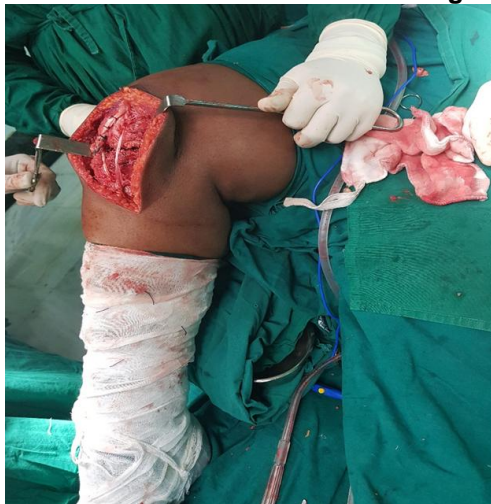Fig. 6. Schematic diagram of how tendons were passed through tunnels of patella and tibia



**Fig. 7. Sticking in tendons**



**Fig. 8. Construct was made with hamstring tendons**



**Fig. 9. Construct was checked with 90° of flexion**

#### **4. POST OPERATIVE CARE AND REHABILITATION**

Patient was immobilised in long knee brace and was started on static quadriceps exercises for 4 weeks. Cerclage wire was removed at 4<sup>th</sup> week, was started on ROM exercises with continuous passive motion, touch weight bearing was started on 6 weeks period, full weight bearing was started on 10 weeks period.

#### **5. RESULTS**

One year postoperatively patient was able to gain active flexion of 130° with no extensor lag, quadriceps power regained to 4/5, insall salvati ratio maintained to 1.07, outcome was evaluated by rao criteria [1] was excellent, kujula score was 94.1, lysholm score was 92.3.

#### **6. DISCUSSION**

Neglected patella tendon rupture which are presented 6 weeks after injury are rare but it can be disabling [1]. It occurs usually beneath the inferior pole of patella in younger population during sport related activities [2-5]. Neglected cases of patellar tendon rupture or patients who underwent native splinting are usually tough to repair [3]. Ecker et al. [10] in 1979 reported four cases of late patellar tendon reconstruction using both the gracilis and semitendinosus tendons. Each tendon was passed through separate tunnels in patella and was sutured together. A cerclage ss wire was used to give stability. Dejour et al. [11] in 1992 reported tendon ruptures of patella operated with opposite leg autograft with tibial bone block, one-third of patellar ligament, Patella block and quadriceps tendon, although it caused morbidity to the normal leg. In 2007 Van der zaal [12] reported cases fixed with bio screws and staples. Chen et al used [13] similar to our procedure preserving the distal attachments for vascularity. Similarly many materials like Achilles tendon [14-17], synthetics like carbon fibre [18], Dacron [18], lars [19] were used. We used a method similar to Chen et al and method adopted in Ganga hospitals [20]. Our outcome was good with active flexion of 130° with no extensor lag, quadriceps power regained to 4/5, insall salvati ratio maintained to 1.07, outcome was evaluated by rao criteria [1] was excellent, kujula score 94.1, lysholm score 92.3. However it is imperative to maintain normal length of patella tendon to

prevent alta and baja, can hamper knee function, and reduce pressure of patella over trochlea which can accelerate patellofemoral arthritis.

#### **7. CONCLUSION**

Our operative procedure was a combination of Chen et al and ganga hospital SR Sundararajan, our outcome was also excellent with no extensor lag after 1 year of follow-up, good rao, kujala, lysholm scores. From our study it is found that even in chronic neglected cases of patellar tendon rupture, good functional results can be obtained by repair using hamstring graft.

#### **CONSENT**

All the necessary investigations and procedures were done after obtaining written and informed consent from the patient.

#### **ETHICAL APPROVAL**

As per international standard or university standard written ethical approval has been collected and preserved by the author(s).

#### **COMPETING INTERESTS**

Authors have declared that no competing interests exist.

#### **REFERENCES**

1. Siwek CW, Rao JP Ruptures of the extensormechanism of the knee joint. *J Bone Joint Surg Am.* 1981;63:932–9372.
2. Matava MJ. Patellar tendon ruptures. *J Am Acad Orthop Surg.* 1996;4:28796
3. Bek D, Demiralp B, Kömürçü M, Sehirlioğlu A. Neglected patellar tendon rupture: A case of reconstruction without quadriceps lengthening. *J Orthop Traumatol.* 2008;9(1):39–42.
4. Lewis PB, Rue JP, Bach BR Jr. Chronic patellar tendon rupture: Surgical reconstruction technique using 2 Achilles tendon allografts. *J Knee Surg.* 2008;21(2):130–135.
5. Nguene-Nyemb AG, Hutten D, Ropars M. Chronic patellar tendon rupture reconstruction with a semitendinosus autograft. *Orthop Traumatol Surg Res.* 2011;97(4):447–450.
6. Gries PE, Lahav A, Holmstrom MC. Surgical treatment options for patella

- tendon rupture, part II: chronic. *Orthopedics*. 2005;28(8):765–769.
7. Milankov MZ, Miljkovic N, Stankovic M. Reconstruction of chronic patellar tendon rupture with contralateral BTB autograft: A case report. *Knee Surg Sports Traumatol Arthrosc*. 2007;15(12):1445–1448
  8. Mittal R, Singh DP, Kapoor A. Neglected patellar tendon rupture: Preserve the fat pad. *Orthopedics*. 2011;34(2):134.
  9. Magnussen RA, Lustig S, Demey G, Masdar H, ElGuindy A, Servien E, et al. Reconstruction of chronic patellar tendon ruptures with extensor mechanism allograft. *Tech Knee Surg*. 2012;11(1):34–40.
  10. Ecker ML, Lotke PA, Glazer RM. Late reconstruction of the patella tendon. *J Bone Joint Surg Am*. 1979;61:884–886.
  11. Dejour H, Denjean S, Neyret P. Treatment of old or recurrent ruptures of the patellar ligament by contralateral autograft. *Rev Chir Orthop Reparatrice Appar Mot*. 1992;78:58–62.
  12. Van der Zwaal P, Van Arkel ERA. Recurrent patellar tendon rupture: Reconstruction using ipsilateral gracilis and semitendinosus tendon autografts. *Injury*. 2007;38:320–323.
  13. Chen B, Li R, Zhang S. Reconstruction and restoration of neglected ruptured patellar tendon using semitendinosus and gracilis tendons with preserved distal insertions: Two case reports. *Knee*. 2012;19(4):508–512.
  14. McNally PD, Marcelli EA. Achilles allograft reconstruction of a chronic patellar tendon rupture. *Arthroscopy*. 1998;14:340–344.
  15. Labib SA, Wilczynski MC, Sweitzer BA. Two-layer repair of a chronic patellar tendon rupture: A novel technique and literature review. *Am J Orthop*. 2010;39(6):277–282.
  16. Falconiero RP, Pallis MP. Chronic rupture of a patella tendon: A technique for reconstruction with Achilles allograft. *Arthroscopy*. 1996;12:623–626.
  17. Evans PD, Pritchard GA, Jenkins DH. Carbon fibre used in the late reconstruction of rupture of the extensor mechanism of the knee. *Injury*. 1987;18:57–60.
  18. Levin PD. Reconstruction of the patellar tendon using a Dacron graft: A case report. *Clin Orthop*. 1976;118:70–72.
  19. Naim S, Gougoulias N, Griffiths D. Patellar tendon reconstruction using LARS ligament: Surgical technique and case report. *Strateg Trauma Limb Reconstr*. 2011;6(1):39–41.
  20. Neglected patellar tendon rupture—a simple modified reconstruction using hamstring tendon graft. Sr sundaraja, kp srikanth, s rajasekran. *Int Orthop*; 2013.