

# OUTCOME OF PROXIMAL HUMERUS FRACTURE

## ABSTRACT

Introduction: Proximal fractures of the humerus account for about 4 to 5% of all fractures. They are the most common fractures in elderly population. Treatment of unstable, displaced, and comminuted fractures of the proximal humerus remains challenging.

Objectives: The present study is undertaken to evaluate the functional outcome of proximal humerus fractures treated by locking compression plate in 3 patients. Materials and methods: Prospective study was done involving 3 adult patients with proximal humerus fractures admitted. Results: In our series, the majority of the patients were 40 to 50 years of age. After reduction and application of PHILOS plating, patient symptomatically improved after series follow up with physio and mobilization was done Conclusion: In conclusion, securing density plate is an advantageous implant in proximal humerus fractures due to angular stability, which allows their early mobilization.

Keywords: Locking compression plate, Open reduction and internal fixation, Proximal humerus fractures,

## INTRODUCTION

Proximal humerus fracture is most commonly seen in people due to violent trauma at the proximal site of humerus.<sup>1</sup> Most of these fractures are due to fall and sustained injury directly to the proximal humerus.<sup>2</sup> Radial nerve injury and brachial artery injury are sometimes encountered due to the trauma. Proximal humeral fractures are powerfully connected to osteoporosis and shared between older patients. The aim of treatment is to decrease pain and regain function. Patient comorbidity and poor bone excellence appear to influence the complete outcome, as well as deteriorating changes in the rotator cuff. The organizational excellence of scientific educations has factually been low, but inside the previous periods randomized scientific educations must gained ground, which confidently authorities an era of evidence-based and tested treatment algorithms.<sup>5-10</sup>

## CLASSIFICATION-

Proximal humerus fractures are classified on NEER classification based on the truma.

## TYPE 1- 1 PART FRACTURE

TYPE 2- 2 PART FRACTURE

TYPE 3- 3 PART FRACTURE

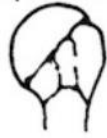TYPE 4- 4 PART FRACTURE

Fig 1: Displaced Fracture

UNDER PEER REVIEW

I  
Minimal  
displacement

DISPLACED FRACTURES



2  
Part

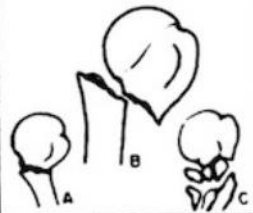
3  
Part

4  
Part

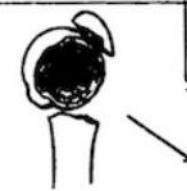II  
Anatomical  
neck



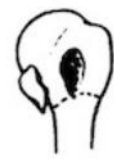III  
Surgical  
neck



IV  
Greater  
tuberosity



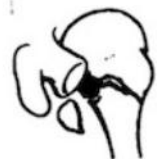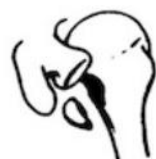V  
Lesser  
tuberosity



VI  
Fracture-  
dislocation



Anterior  
Posterior



Articular  
surface



## METHODS

There are 3 patients with an age group of 40 to 50 years of age. Fracture are classified based on neer and treatment is then processed. Out of these 2 where 3-part fracture and treatment followed up was PHILOS PLATING. Patient was comfortable. Peripheral nerve examinations were done and intact and patient symptomatically improved.

### Non-operative treatment

In greatest cases non-operative managing is used since the shape of the fracture is stable and it is likely to heal with a good outcome.

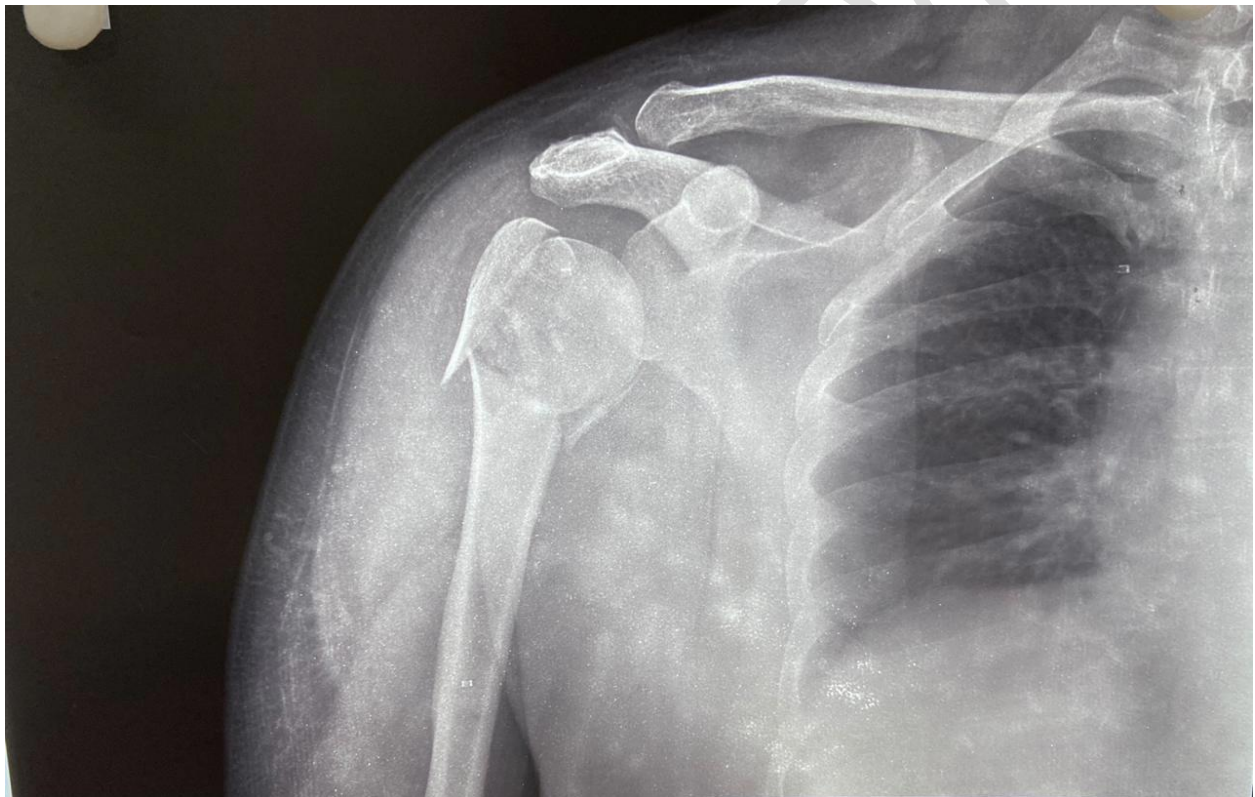


Fig 2: X-ray image

## RESULT

After reduction and application of PHILOS plating, patient symptomatically improved after series follow up with physio and mobilization was done. ORIF with PHILOS PLATING is the

best modality of treatment for proximal humerus fracture. Then patient symptomatically improved then discharged and asked for regular follow up.

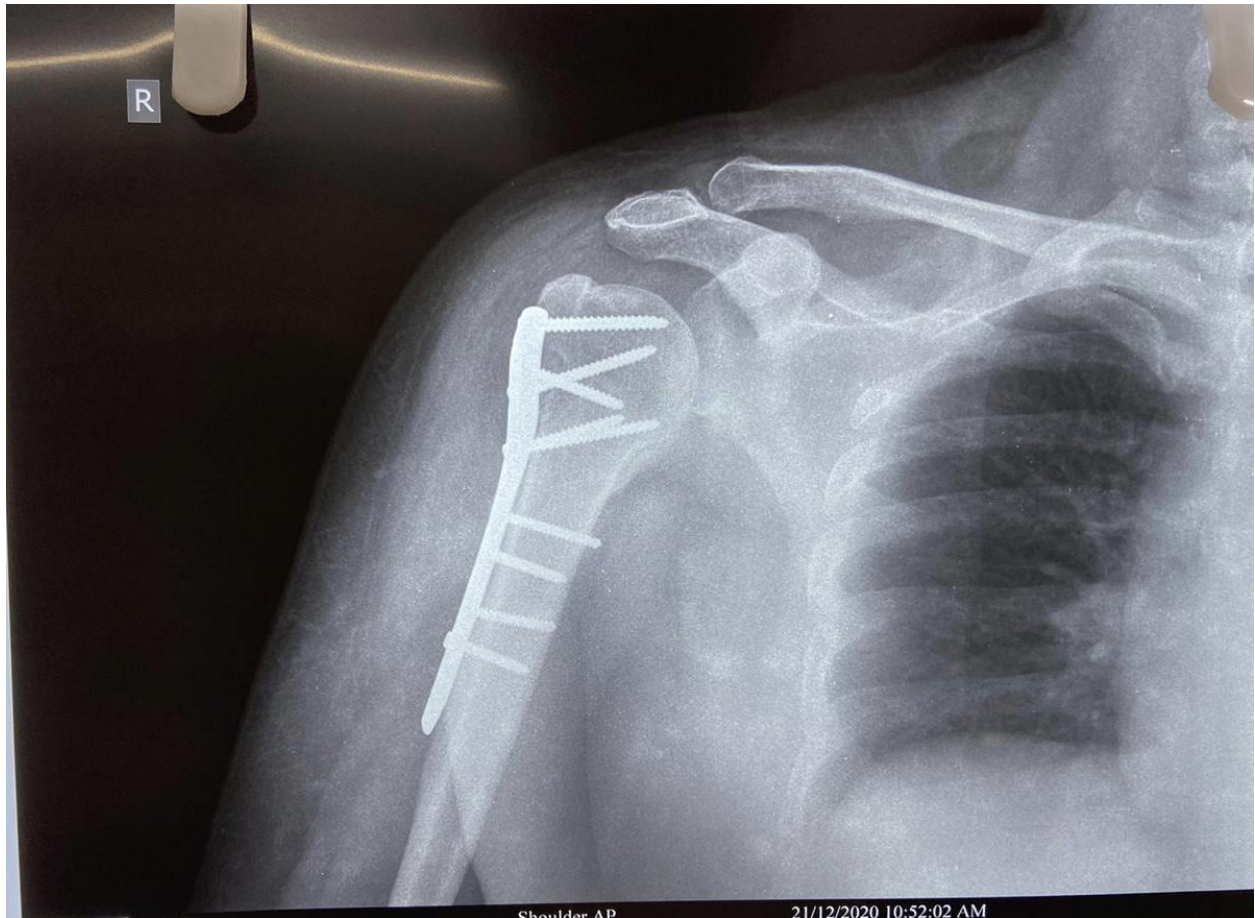


Fig 3: proximal humerus fracture

## DISCUSSION

Treatment of proximal humerus fracture is very important or else may lead to movement abnormalities with nerve and artery injuries may be present. This study is done in such a way that all the patient treated well with the treatment of choice and patient was symptomatically improved. After this patient mobilized well and started doing regular activities. The appropriate type of treatment, either operative or nonoperative in the elderly, low-demand patient, also remains unsolved.<sup>3</sup> Our study is in agreement with other studies, with more than 75% patients having excellent to satisfactory results.<sup>4</sup>

## CONCLUSION

The present study was done to assess functional outcome and difficulty ensuing surgical management of proximal humerus fracture by locking compression plate.

#### Consent

As per international standard or university standard, patients' written consent has been collected and preserved by the author(s).

#### REFERENCE

1. Chen CT, Lin SJ, Kuo LT, Chen TH, Hsu WH, Chen CL, Yu PA, Peng KT, Tsai YH. Effect of chronic kidney disease on outcomes following proximal humerus fragility fracture surgery in diabetic patients: A nationwide population-based cohort study. *PloS one*. 2021 Oct 8;16(10):e0258393.
2. Audigé L, Brorson S, Durchholz H, Lambert S, Moro F, Joeris A. Core set of unfavorable events of proximal humerus fracture treatment defined by an international Delphi consensus process. *BMC musculoskeletal disorders*. 2021 Dec;22(1):1-8.
3. Bjorkenheim JM, Pajarinen J, Savolainen V. Internal fixation of proximal humeral fractures with a locking compression plate. *Acta Orthop Scand* 2004 Dec;75(6):741-745.
4. Owsley KC, Gorczyca JT. Fracture displacement and screw cutout after open reduction and locked plate fixation of proximal humeral fracture. *J Bone Joint Surg Am* 2008 Feb;90(2):233-240
5. Slobogean GP, Johal H, Lefaiivre KA, MacIntyre NJ, Sprague S, Scott T, Guy P, Cripton PA, McKee M, Bhandari M. A scoping review of the proximal humerus fracture literature. *BMC musculoskeletal disorders*. 2015 Dec;16(1):1-0.
6. Handoll HH, Brorson S. Interventions for treating proximal humeral fractures in adults. *Cochrane Database of Systematic Reviews*. 2015(11).
7. Kannus, P., Niemi, S., Sievänen, H. and Parkkari, J., 2017. Stabilized incidence in proximal humeral fractures of elderly women: nationwide statistics from Finland in 1970–2015. *Journals of Gerontology Series A: Biomedical Sciences and Medical Sciences*, 72(10), pp.1390-1393.
8. Brorson S. Fractures of the proximal humerus: history, classification, and management. *Acta Orthopaedica*. 2013 Oct 1;84(sup351):1-32.
9. Launonen, A.P., Sumrein, B.O., Reito, A., Lepola, V., Paloneva, J., Jonsson, K.B., Wolf, O., Ström, P., Berg, H.E., Felländer-Tsai, L. and Jansson, K.Å., 2019. Operative versus non-operative treatment for 2-part proximal humerus fracture: A multicenter randomized controlled trial. *PLoS medicine*, 16(7), p.e1002855.
10. Brorson S, Alispahic N, Bahrs C, Joeris A, Steinitz A, Audigé L. Complications after non-surgical management of proximal humeral fractures: a systematic review of terms and definitions. *BMC musculoskeletal disorders*. 2019 Dec;20(1):1-7.