

A CASE REPORT OF CAPITELLUM FRACTURE TREATED USING HERBERT SCREW.

ABSTRACT:

Capitellar fractures are intra-articular elbow injury & it is an uncommon type of elbow injuries that can cause and affect severe functional limitation if not treated correctly. Various treatment options have evolved over the years, from cast immobilization to closed reduction fixation and now finally open reduction fixation is used as a better treatment option. Open reduction internal fixation provides excellent fixation to the fracture site and helps in achieving a stable joint that help in early mobilization of the elbow joint after trauma. Which also prevents late complications such as myositis ossificans. This is a case report of capitellar fracture, a typical type -1 Hahn-Steinthal fracture of left elbow joint in a 14 year old adolescent male treated using Herbert's screw fixation. Here after three months of post-op follow-up it shows good interfragmental compression, early mobilization, excellent recovery & Implant removal is rarely necessary.

INTRODUCTION:

Capitellar fractures are uncommon type of fractures that represent only 1% of all elbow injuries. These types of fractures are less common under the age of 12; since it is formed by cartilaginous composition makes it resistant to stress^{1,2}. Whereas in older children it become prominent to shear injuries. Capitellum fractures are intra-articular fracture where it does not involve the growth plate or condyles³. This kind of fractures are often get confused with fracture of lateral humeral fracture. So it is important diagnosis correctly and plan for surgery accordingly.

CASE REPORT:

This is a case of 14years old adolescent male presented with complaints of pain and swelling over the left elbow joint. Patient had alleged H/O Trauma after which he developed pain & swelling around the joint. Patient had restriction of motion due to severe pain, without any neurovascular deficit.

ON RADIOGRAPHIC EXAMINATION:

X-Ray shows left capitellum fracture (Bryan and morrey classification type -1 (Hahn-steinhal) fracture. CT study of left elbow shows – Displaced fracture of capitellum of humerus with ulno-humeral and proximal radio-ulnar joint alignment grossly maintained surrounding fat tissue edematous changes around the elbow joint noted.

Fig 1: X-RAY LEFT ELBOW AP & LATERAL VIEW SHOWING TYPE -1 (Hahn-steinhal) CAPITELLUM FRACTURE.

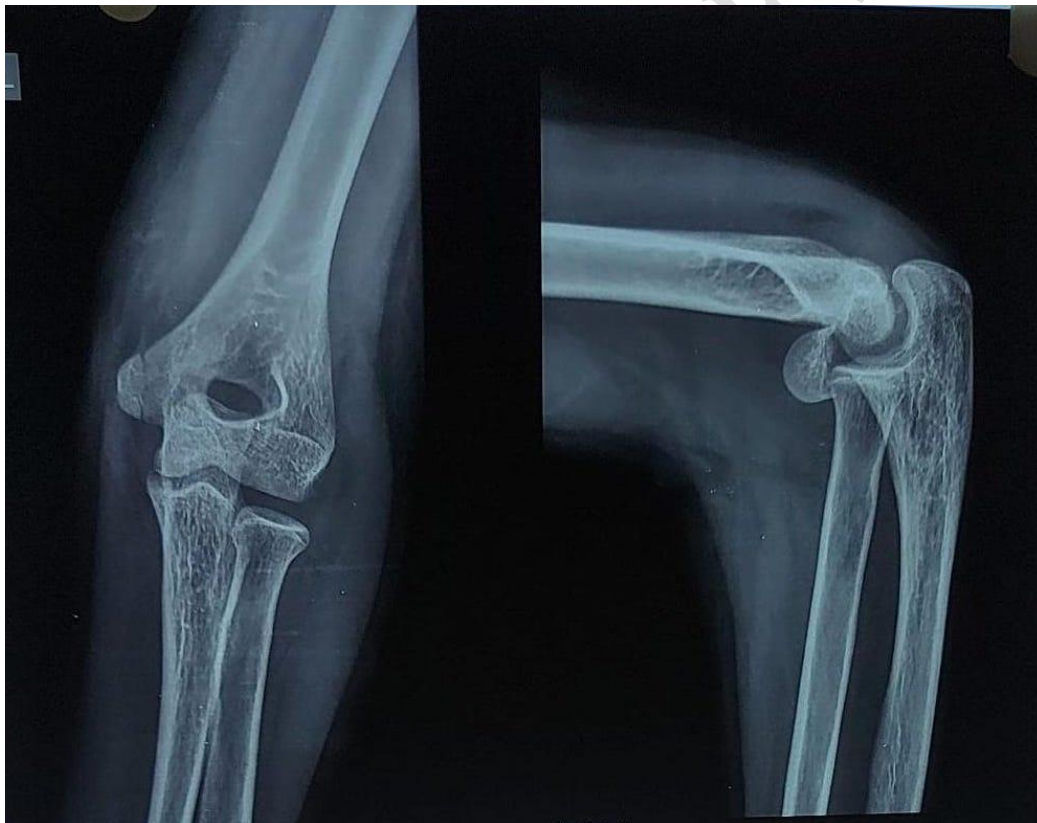


FIG -2 CT OF LEFT ELBOW

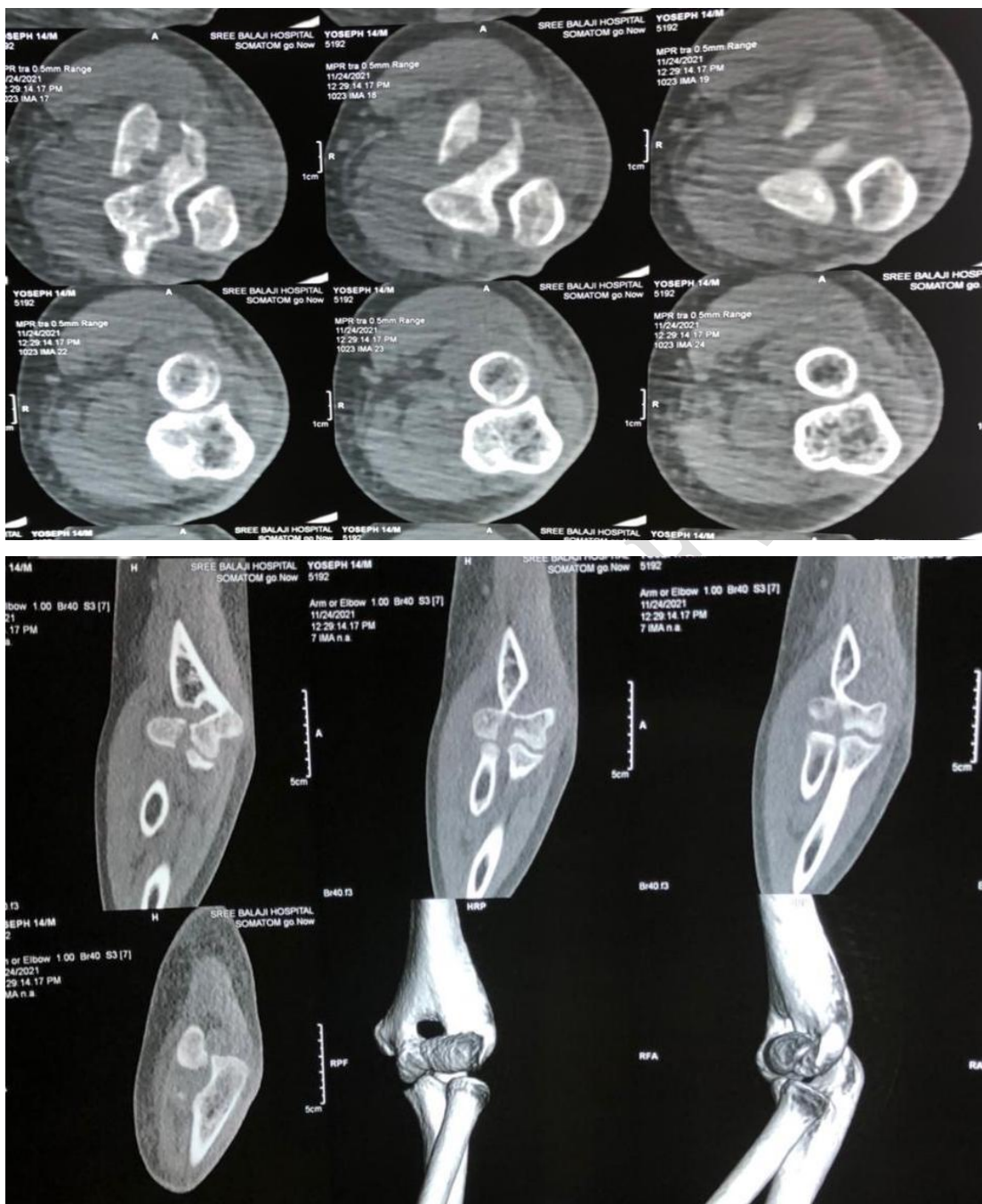
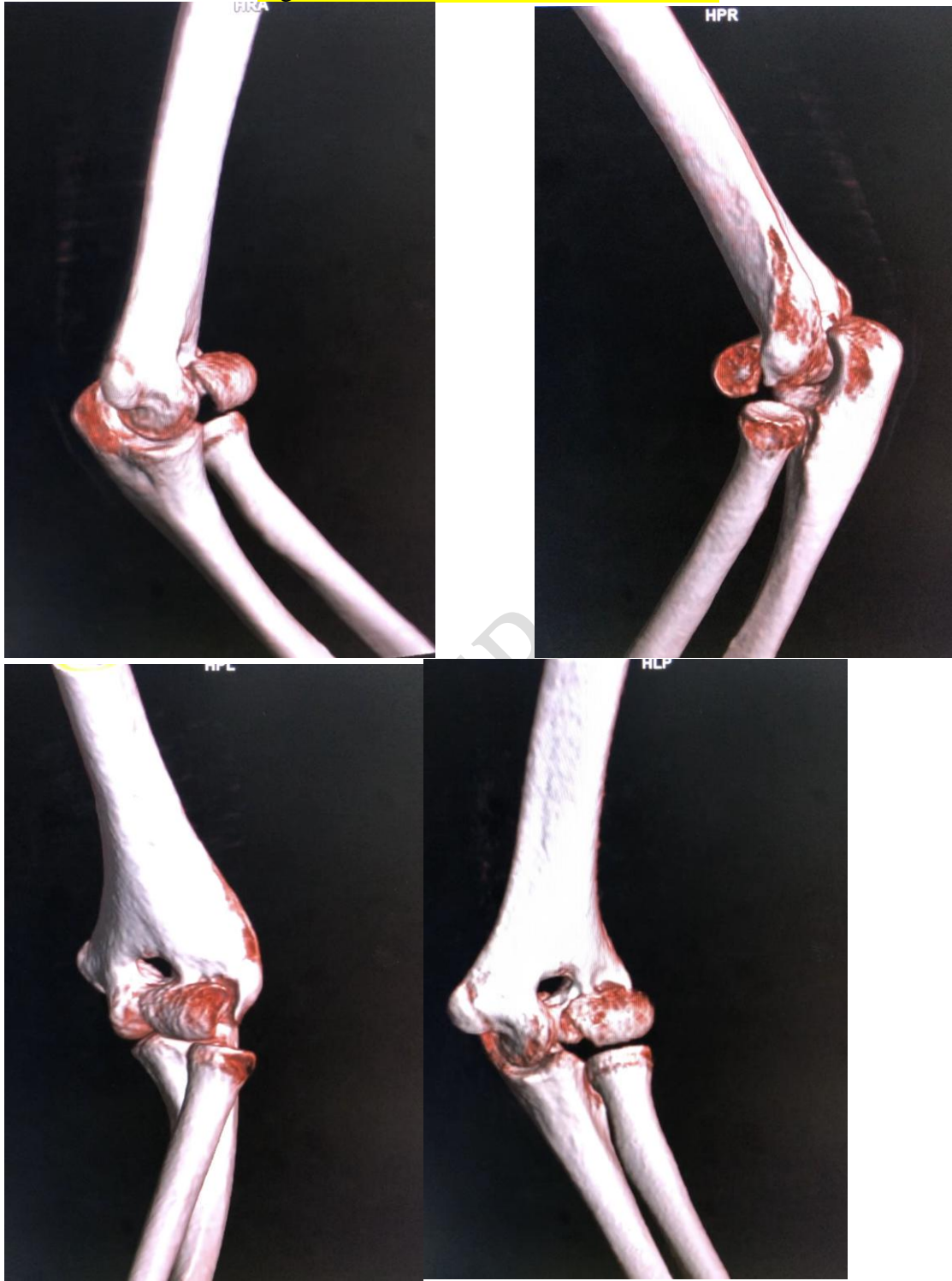


Fig 3 : 3D RECONSTRUCTION IMAGE



Since the x-ray and CT images are consistent with diagnosed of Capitellum fracture. Patient was performed open reduction internal fixation with Herbert's screw fixation. Patient in supine position, approach – posterolateral (KOCHER'S), Incision of size 10cm made over the lateral epicondyle. Proximally extending along the lateral supracondylar ridge distally extending in the line of radial head. Skin & subcutaneous tissue cut and retracted, Anconeus and extensor carpi ulnaris muscles are identified , cut and retracted. Fracture site identified & annular ligament is surgically dissected, fracture site reduced using Guide wire & Herbert screw of size 2.5 x 22mm & 2.5 x 28mm placed in position. Fracture site reduced. Annular ligament tied and suture. Wound closed in layers. Above elbow slab applied.

Image 1: INTRA-OP PICTURES – Fracture noted in capitellum

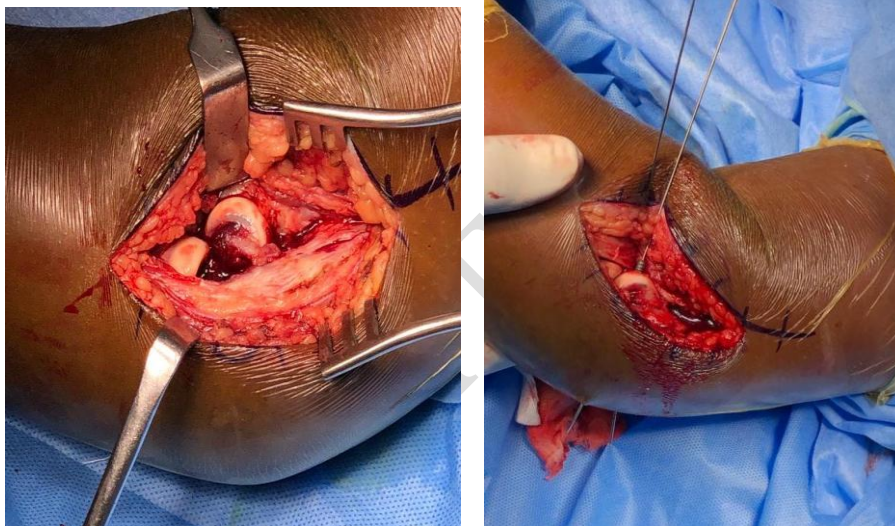


Image 2 – intra-op Fracture fixed using Herberts screw of size 2.5 x 22mm & 2.5 x 28mm

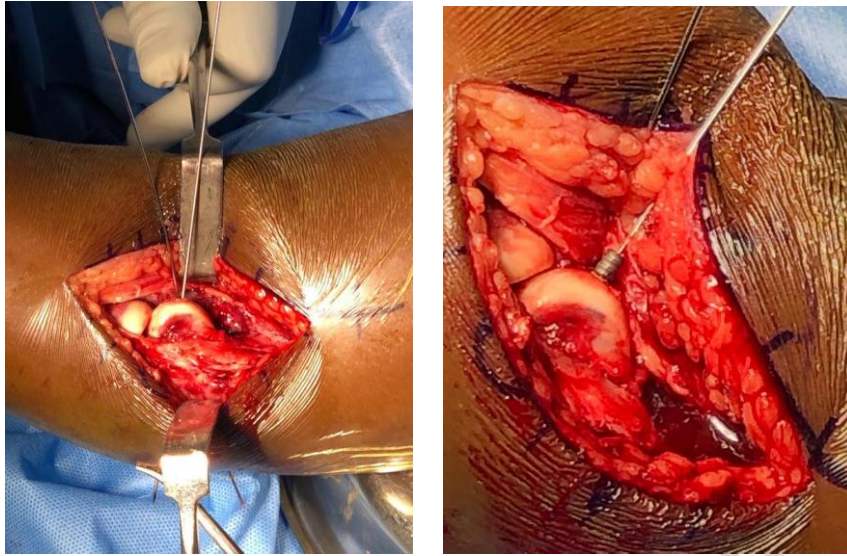


Image 3 C-ARM PICTURE :

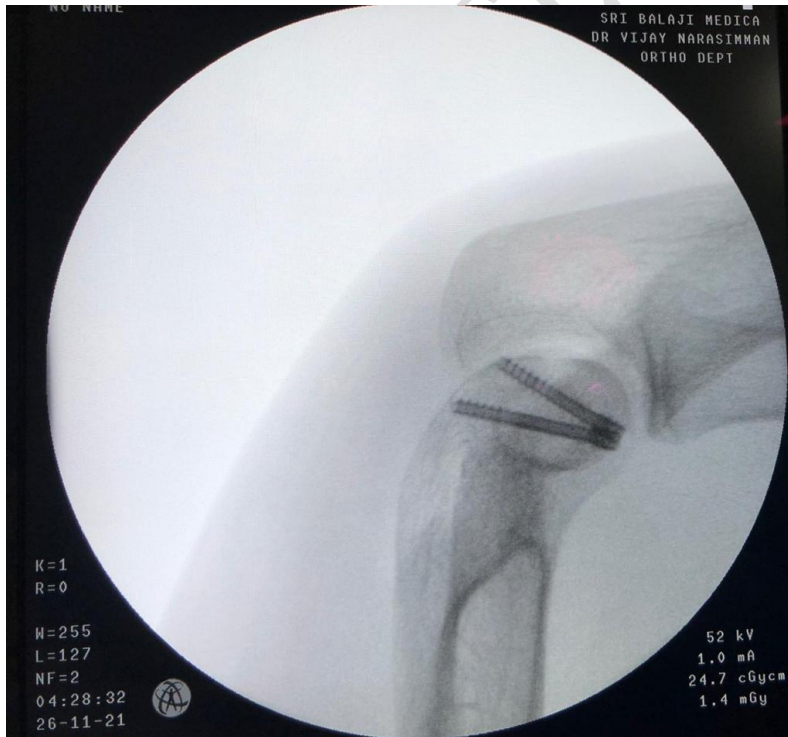
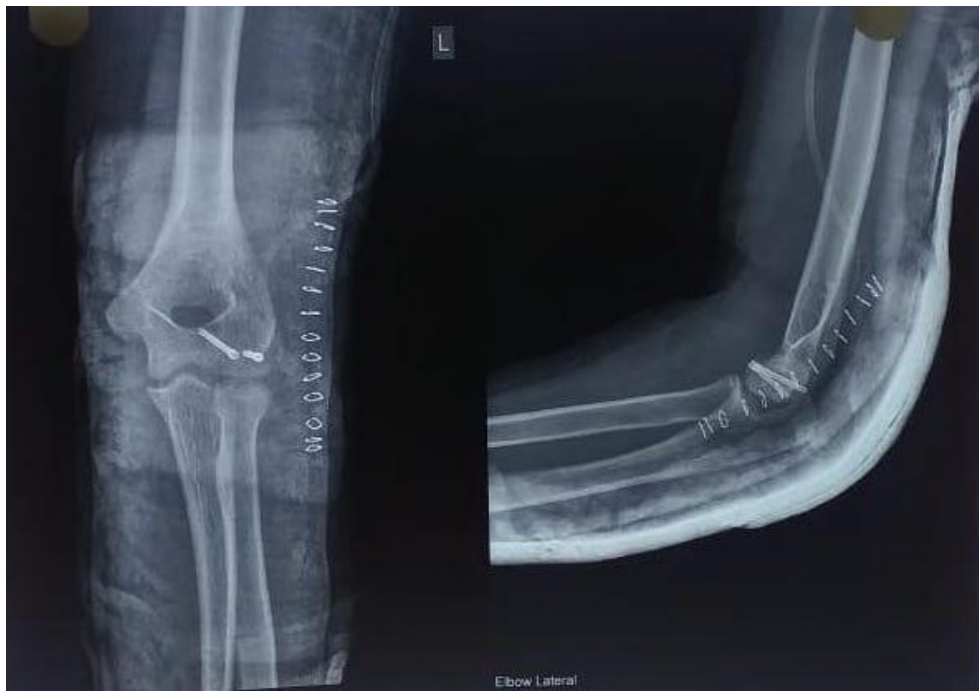
Image 4 Post-op x-ray: of left elbow



DISCUSSION :

Capitellar fractures are uncommon type of fractures that represent only 1% of all elbow injuries type -1 Hahn-Steinthal fracture is uncommonly seen in children below the age of 12years. It is important to diagnosis correctly because its often get mis-diagnosed due to its fracture pattern, that can lead to significant joint instability and restriction of motion. So it's always significant to do CT scan with 3D reconstruction to find out the fracture pattern, articular impaction & whether any condylar comminution is associated or not⁶.

There are various treatment options like Closed reduction internal fixation that can be used to reduced the fracture fragment but it is difficult to achieve fracture reduction correctly and may lead to poor union, reduced range of motion and joint instability, whereas in internal fixation with K-wire is one of the preferable method but however it penetrate the articular surface & also does not provide stable fixation⁵. So, Open reduction with internal fixation with Herbert screw fixation provides absolute fracture fixation and early mobilization of the elbow joint.

In our case, it is a capitellum fracture - Bryan and Morrey (type-1), the treatment option chosen was open reduction internal fixation with Herbert screw fixation. Which allow accurate inter-fragmentally compression & stability. Which provide excellent recovering phase by allowing early mobilization & achieve full range of motion⁷. Early fixation also reduced the chance of avascular necrosis & other complications like heterotopic ossification that can be caused due to prolonged immobilization⁸ & **Implant removal is rarely necessary.**

CONCLUSION :

Type -1 Hahn-steinthal capitellar fracture must be fixed anatomically to regain the articular congruity and achieve full range of motion of the elbow joint. This goal is achieved by fixing the fracture using ORIF with Herbert screw fixation. The main advantages being providing excellent interfragmental compression and early joint motion & the implant need not to be removed. Thus early surgical intervention and Herbert screw fixation help to achieve excellent functional outcomes among this age group.

Disclaimer regarding Consent and Ethical Approval:

As per university standard guideline, participant consent and ethical approval have been collected and preserved by the authors

REFERENCES:

1. Bryan RS, Morrey BF; fractures of distal humerus. The elbow and its disorders by Morrey BF. Philadelphia.
2. Poynton AR, Kelly IP, O'Rourke SK; fractures of the capitellum; a comparison of two fixation methods. Injury.1998.
3. Pradhan B, Bhasin D, Krom W: Capitellar fracture in a child; the value of an oblique radiograph. A Case report.
J Bone joint surg Am.
4. Pogliacomi F, Concari G, Vaienti E: Hahn-steinthal Fracture: report of two cases. Acta Biomed. 2005.
5. Boeck H, Pouliart N: fractures of the capitellum humeri

In adolescents. Int Orthop. 2000

6. Johansson J, Rosman M: fracture of the capitellum
Humerus in children: a rare injury, often misdiagnosed.
Clin Orthop.1980.
7. Herring JA: Tachdjian's pediatric orthopaedics.2008,
Philadelphia: saunders Elsevier.
8. Mckee MD, Jupiter JB, Bamberger HB; Coronal shear
Fractures of the distal end of the humerus. J bone joint surg AM.1996.

UNDER PEER REVIEW